

Review article

Cleidocranial dysplasia: clinical and molecular genetics

Stefan Mundlos

Abstract

Cleidocranial dysplasia (CCD) (MIM 119600) is an autosomal dominant skeletal dysplasia characterised by abnormal clavicles, patent sutures and fontanelles, supernumerary teeth, short stature, and a variety of other skeletal changes. The disease gene has been mapped to chromosome 6p21 within a region containing CBFA1, a member of the runt family of transcription factors. Mutations in the CBFA1 gene that presumably lead to synthesis of an inactive gene product were identified in patients with CCD. The function of CBFA1 during skeletal development was further elucidated by the generation of mutated mice in which the *Cbfa1* gene locus was targeted. Loss of one *Cbfa1* allele (+/-) leads to a phenotype very similar to human CCD, featuring hypoplasia of the clavicles and patent fontanelles. Loss of both alleles (-/-) leads to a complete absence of bone owing to a lack of osteoblast differentiation. These studies show that haploinsufficiency of CBFA1 causes the CCD phenotype. CBFA1 controls differentiation of precursor cells into osteoblasts and is thus essential for membranous as well as endochondral bone formation.

(J Med Genet 1999;36:177-182)

Keywords: cleidocranial dysplasia; CBFA1

Heritable diseases of the skeleton are a diverse and complex group of genetic disorders. The different clinical manifestations reflect the basic mechanisms of skeletal development, patterning, bone and cartilage formation, growth, and homeostasis. The recent identification of the genetic basis for several skeletal disorders has yielded significant insights into these processes.^{1,2} Cleidocranial dysplasia (CCD) is a well defined skeletal disorder with characteristic clinical findings and autosomal dominant inheritance. Reports of clavicular defects appeared as early as 1765,³ but Scheuthauer⁴ was probably the first to describe the syndrome accurately. Marie and Sainton⁵ in 1898 coined the name "dysostose cléidocrânienne héréditaire" for this condition. One of the most colourful families, descendants of a

Chinese named Arnold, was probably described by Jackson.⁶ He was able to trace 356 members of this family of whom 70 were affected with the "Arnold Head". CCD was originally thought to involve only bones of membranous origin. More recent and detailed clinical investigations have shown that CCD is a generalised skeletal dysplasia affecting not only the clavicles and the skull but the entire skeleton. CCD was therefore considered to be a dysplasia rather than a dysostosis.⁷ Skeletal abnormalities commonly found include clavicular aplasia/hypoplasia, bell shaped thorax, enlarged calvaria with frontal bossing and open fontanelles, Wormian bones, brachydactyly with hypoplastic distal phalanges, hypoplasia of the pelvis with widened symphysis pubis, severe dental anomalies, and short stature. The changes suggest that the gene responsible is not only active during early development, as implied by changes in the shape or number of bones, but is also important during fetal and postnatal growth.

Clinical and radiological features

The clinical and radiological features have been reviewed by several authors.⁸⁻¹² Table 1 summarises the clinical and radiological findings. Typical clinical findings are shown in fig 1. Craniofacial growth is affected in many ways.^{13,14} Head circumference is usually at the upper limit without being macrocephalic. There is a broad forehead with frontal bossing and some degree of hypertelorism. The mid-frontal area is poorly developed and shows a frontal groove owing to incomplete ossification of the metopic suture. Closure of the anterior fontanelle and sagittal and metopic sutures is delayed, often for life. In infants, a generalised delay in ossification of the skull can be observed and in extreme cases the parietal bones are not present at birth. With increasing age the unossified areas become smaller and true Wormian bones form, particularly around the lambdoid suture. Frontal and paranasal sinuses are frequently absent or reduced in size. Other changes of the skull include small or absent nasal bones, segmental calvarial thickening, underdevelopment of the maxilla, delayed union of the mandibular symphysis, and a small cranial base with reduced sagittal diameter and a large foramen magnum. The skeletal

Table 1 Clinical and radiological features of cleidocranial dysplasia

Clinical	Radiological
<i>Skull</i>	
Brachycephaly	Multiple wormian bones
Frontal and parietal bossing	Segmental calvarial thickening
Open sutures and fontanelles	Unossified sutures and patent fontanelles
Delayed closure of fontanelles	Dysplastic changes in the basiocciput
Relative prognathism	Hypoplasia of maxilla
Soft skull in infancy	Delayed mineralisation
Depressed nasal bridge	Calcification of nasal bone delayed or missing
Hypertelorism	Hypoplastic sinuses (paranasal, frontal, mastoid)
<i>Thorax and shoulders</i>	
Ability to bring shoulders together	Hypoplastic, aplastic, or discontinuous clavicles
Narrow, sloping shoulders	Cone shaped thorax
Respiratory distress at early age	Cervical ribs, missing ribs
Increased mobility	Hypoplastic scapulae
<i>Pelvis and hips</i>	
Caesarean section	Delayed ossification of pubic bone
	Hypoplasia of iliac wings
	Widening of sacroiliac joints
	Large femoral neck, large epiphyses
<i>Spine</i>	
Scoliosis	Hemivertebrae, posterior wedging
Kyphosis	Spondylolysis and spondylolisthesis
	Spina bifida occulta
<i>Hands</i>	
Brachydactyly	Short middle phalanges and metacarpals/tarsals III–V
Tapering of fingers	Hypoplastic distal phalanges
Nail dysplasia/hypoplasia	Accessory epiphyses especially of 2nd metacarpal
Short, broad thumbs	Long 2nd metacarpal
Clinodactyly of 5th finger	Cone shaped epiphyses
<i>Dentition</i>	
Normal deciduous dentition	
Supernumerary teeth	Impacted, supernumerary teeth
Delayed eruption	
Crowding, malocclusion	

changes result in subtle but characteristic facial features (fig 1A) that include a large, brachycephalic head with parietal and marked frontal bosses separated by a metopic groove, a depressed nasal bridge, hypertelorism with possible exophthalmos, and a small maxilla, which gives the face a small, flattened appearance with mandibular prognathism.

Many patients with hypoplastic or even absent clavicles have gone through life, even working as manual labourers, without disability resulting from this defect. Depending on the degree of clavicular hypoplasia, appearance can range from a dimple in the skin to sloping, almost absent shoulders and the ability to voluntarily bring the shoulders together. According to our observations and those of others,^{9 15} a complete absence of the clavicle(s) is rare, whereas hypoplasia of the acromial end is common. Other less common forms of clavicular involvement include the occurrence of two separate fragments, or the absence of the sternal end with the acromial end present. Bilaterality is the rule but not always the case. The missing segment may be represented by fibrous pseudarthrosis or by a fibrous tether or cord. Thus, patients that appear normal on clinical examination with regularly shaped shoulders and palpable clavicles may have small defects at the acromial ends or fibrous cords that can only be identified on *x* ray. Occasionally, patients with normal clavicles have been described.^{10 15} The thoracic cage is small and bell shaped with short, oblique ribs. The narrow thorax may lead to respiratory distress in early infancy.¹² Abnormalities in the number of ribs such as cervical or absent ribs are not uncommon. The scapulae are often hypoplastic with deficiencies in the supraspinatus fossae and acromial facets.

As expected, there is often an associated deficiency of the musculature.

The pelvis is invariably involved and shows characteristic changes (fig 1C). The name “forme cleido-pelviennne” was proposed for this deformity by Crouzon and Buttier.¹⁶ The widened symphysis pubis (distance between pubic bones) results from a delay in ossification during adulthood. Other changes include hypoplasia and anterior rotation of the iliac wings and wide sacroiliac joints. The femoral epiphyses are large, the femoral necks broad, and there is frequently coxa vara. The dysplastic pelvis often necessitates caesarean section in the pregnant female.

A relatively constant abnormality is the presence of both proximal and distal epiphyses in the second metacarpals and metatarsals leading to excessive growth and length (fig 1D).^{9 17} All other bones of the hands and feet, especially the distal phalanges and the middle phalanges of the second and fifth fingers are unusually short. Cone shaped epiphyses and premature closure of epiphyseal growth plates are frequently observed and lead to shortening of other bones. The poorly developed terminal phalanges give a tapered appearance to the digit. The nails are sometimes hypoplastic/dysplastic or may even be absent.

Final height is significantly reduced in patients with CCD. Previous investigations indicate that birth length is normal but that height drops below or around the 2nd centile between the ages of 4 and 8.^{18 19} In a study by Jensen,¹⁷ female patients were more affected than male patients. Patients usually have a mildly disproportionate short stature with short limbs compared to the trunk, more apparent in the upper limbs than the lower.

The palate is often highly arched and clefts involving the hard and soft palates have been described. Dental changes occur frequently and are very characteristic of CCD (fig 1E).²⁰ Retention of the deciduous dentition with delayed eruption of the permanent teeth is a relatively constant finding. Dental disability begins in late youth with the progressive morbidity and loss of the deciduous dentition. Many patients remember living “without teeth” for some years until the permanent teeth eventually erupted. Permanent teeth show a delay of root development and a lessened but not entirely absent eruptive potential. Surgical procedures to promote eruption include the extraction of all deciduous teeth and the removal of bone overlying the crypts of the unerupted teeth. The situation is further complicated by the presence of multiple supernumerary teeth that displace the developing permanent teeth and obstruct their eruption. The large number of supernumerary teeth that form a more or less complete third dentition (up to 30 extra teeth in some cases) is one of the most striking findings in CCD. Morphologically and functionally, supernumerary teeth resemble their normal counterparts. Dentine formation is normal but cellular root cementum is lacking.²¹ Abnormal bone morphology has been reported.²² Long term orthodontic and surgical treatment is usually necessary with

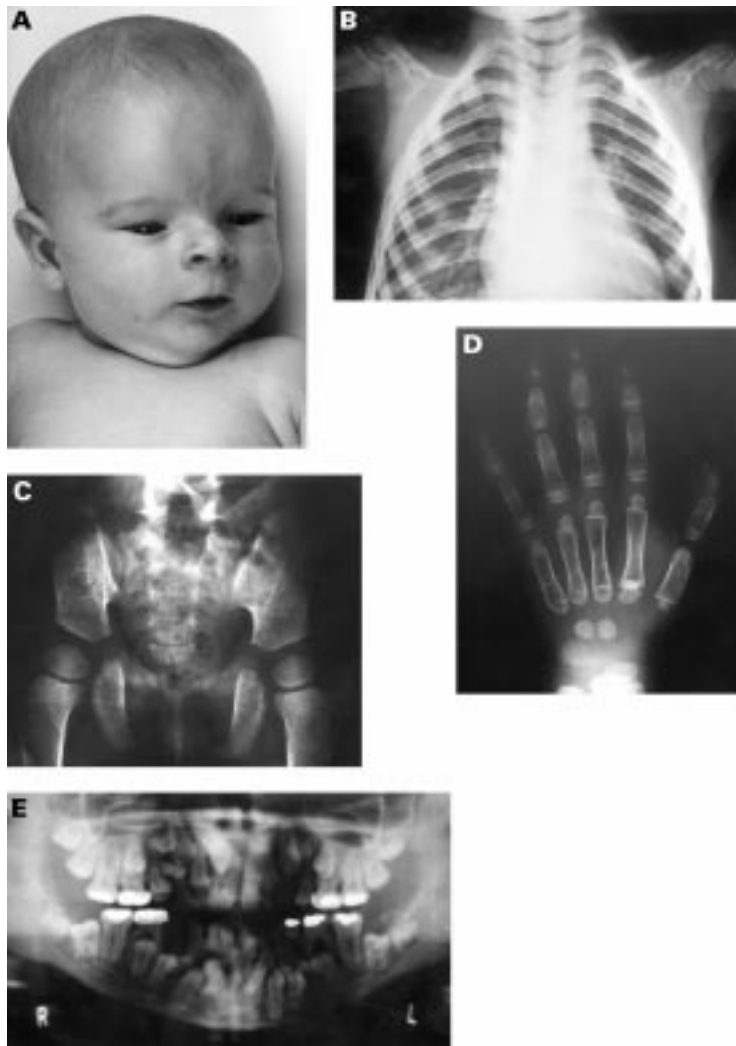

Figure 1 Typical clinical and radiological findings in CCD. (A) Facial appearance in a 6 month old boy. Note large, brachycephalic skull, frontal and parietal bossing with large anterior fontanelle, and the appearance of a small face. Other characteristic features include widely spaced eyes, low nasal bridge, reduced nasal length, but increased nasal width and protrusion. (B) Chest radiograph showing cone shaped thorax and left clavicular hypoplasia and aplasia on the right side. (C) Pelvic abnormalities in a 4 year old girl. Note hypoplasia of the iliac wings, broad femoral necks with large epiphyses, and unossified symphysis pubis. (D) Hand radiograph of a 2½ year old female showing hypoplastic distal phalanges, accessory epiphyses of the second metacarpal, and long second metacarpal. (E) Pantomographic view of the permanent dentition of a 16 year old female. Note multiple, unerupted, supernumerary teeth.

the aim of actively erupting and aligning the impacted permanent teeth.^{23–25}

Differential diagnosis

In a patient with hypoplastic clavicles, open fontanelles, and supernumerary teeth the diagnosis is evident and few other conditions need to be considered. However, the clinical picture is variable, even within families, and frequently the phenotype is incomplete, lacking one or two signs of the characteristic triad. Hall²⁶ has drawn attention to a range of other syndromes with congenital clavicular hypoplasia or agenesis. Congenital pseudarthrosis of the clavicle (MIM 118980) is probably among the most common conditions to be considered. In the great majority of cases involvement is unilateral with a marked predominance of the right side. The cases are sporadic, there is no other bone involvement, and most cases presumably heal

by themselves. Pyknodysostosis is a rare defect of osteoclast function (MIM 265800) with osteosclerosis (increased bone density and fractures), delayed closure of sutures and fontanelles, Wormian bones, hypoplasia of the clavicles (dysplasia to loss of acromial end), acro-osteolytic dysplasia of the distal phalanges, and irregular permanent teeth with anodontia and delayed eruption. While many of the clinical findings resemble CCD, the increased bone density on x ray and the absence of supernumerary teeth should readily distinguish between the two. Hypoplastic clavicles, persistently wide sutures, and multiple Wormian bones are also a feature of mandibuloacral dysplasia (MIM 248370). However, this condition is mainly characterised by acro-osteolysis with progressive loss of bone from the distal phalanges. Eckstein and Hoare reported a mother and son with parietal foramina and clavicular hypoplasia (MIM 168550). Again this was an isolated finding and no other bones were involved. Yunis-Varon syndrome (MIM 216340) in many ways resembles severe CCD. This recessively inherited, usually lethal condition is characterised by prenatal growth deficiency and failure to thrive, wide calvarial sutures and enlarged fontanelles, agenesis/hypoplasia of the thumbs and big toes, absence or hypoplasia of the clavicles, and pelvic dysplasia. The severity of the syndrome, together with limb malformations and a patchy, sometimes sclerotic bone structure, should make distinction from CCD easy. Hypoplasia of the clavicles has been reported in association with various cytogenetic anomalies. These include arrangements involving translocations and duplications of chromosome 8q22,²⁷ partial trisomy 11q,²⁸ partial trisomy 11q/22q,²⁹ and trisomy 20p.³⁰ However, none of these patients had the full CCD phenotype.

Like clavicular hypoplasia, delayed closure of fontanelles/sutures is a rather non-specific sign and by no means diagnostic of CCD. Wide cranial sutures can be an indication of increased intracranial pressure or craniosynostosis in another part. They may also be present in syndromes with impaired bone growth, including those with increased bone density (Kenny-Caffey syndrome, pyknodysostosis, and others), decreased mineralisation (osteogenesis imperfecta, hypophosphatasia, and others), or generalised growth deficiency/bone maturation (athyrotic hypothyroidism, Silver-Russell syndrome, and others). In addition, irregular sutures have been observed in association with cytogenetic anomalies such as deletions of the distal end of chromosome 6p.³¹

The combination of normal deciduous teeth, delayed eruption of permanent teeth, and multiple impacted supernumerary teeth is practically diagnostic of CCD. However, delayed eruption of teeth (deciduous as well as permanent) without supernumerary teeth is frequently observed in conditions with abnormal bone remodelling, such as osteopetrosis or pyknodysostosis. Failure of eruption of most permanent teeth has also been reported as an autosomal dominant trait (MIM 125350).

Multiple extra teeth have been described in Gardner syndrome (MIM 175100).

CCD is generally considered to be inherited in a dominant fashion with complete penetrance. Goodman *et al*³² described three subjects from two families with a severe form of CCD. The family setting, the distribution of the affected members, and the severity of the involvement suggested to the authors that this may represent a recessive form of CCD. Recent molecular findings make this assumption rather unlikely and argue in favour of the presence of mosaicism in one of the parents or the occurrence of new mutations.

Molecular genetics

A CCD-like phenotype has been reported in association with cytogenetic abnormalities of chromosome 8q22.²⁷ While the patients described by Brueton *et al*²⁷ had some clavicular involvement, abnormally wide sutures, hypertelorism, and micrognathia in one case, there were no signs of a generalised bone dysplasia or tooth involvement. In contrast, Nienhaus *et al*³³ described a patient with mild mental retardation, classical CCD, and a paracentric inversion of chromosome 6 involving bands p11 and q16. Shortly thereafter, CCD was mapped to chromosome 6p21 proximal to the HLA region,³⁴ a finding that was subsequently confirmed by others.³⁵⁻³⁷ Within the different families tested there was no evidence for locus heterogeneity. Evidence for a submicroscopic deletion was shown in one family suggesting that the CCD phenotype is caused by haploinsufficiency.³⁴ The deletion in this family and deletions in two other subjects with rearrangement of chromosome 6p (one of them the patient described by Nienhaus *et al*³³) narrowed the critical region containing the CCD gene to a 2 Mb interval between the genes TCTE1 and MUT. CBFA1, a transcription factor of the runt domain gene family, maps within this interval. Deletions, insertions, and missense mutations were identified in several patients with CCD.³⁸ In a paper by Lee *et al*,³⁹ two nonsense mutations were shown to interfere with the function of the putative DNA binding domain. Like many transcription factors, the amino terminal portion of CBFA1 contains a polyglutamine and a polyalanine stretch. In one CCD family with mild craniofacial features and a specific form of brachydactyly, affected persons were found to harbour 27 alanines instead of the usual 17.³⁸ It is to be expected that this expansion of alanines has a dominant negative effect on protein function. A very similar type of mutation has been described in synpolydactyly and HOXD13⁴⁰ and, recently, in the PABP2 gene⁴¹ where an expansion from six alanines to between eight and 13 alanines leads to oculopharyngeal muscular dystrophy. With the possible exception of the in frame expansion of alanines, all mutations identified so far can be predicted to lead to a partial or complete loss of CBFA1 protein function. The data indicate that CBFA1 mutations segregate with the CCD phenotype and that heterozygous loss of function is sufficient to produce the characteristic clinical findings.

Mouse model

These data were further substantiated by the finding of Otto *et al*⁴² that mice lacking only one *Cbfa1* allele (+/-) display a phenotype very similar to CCD with absent clavicles and defective skull formation. Furthermore, *Cbfa1* was shown to be deleted in the mouse mutant *cleidocranial dysplasia* (*Ccd/+*). This radiation induced mutant was recognised by Silience *et al*⁴³ to be a phenocopy of CCD. Genetic analysis of *Ccd* mice showed a 2 cM deletion on chromosome 17 in an area of synteny to human 6p.⁴⁴ By analogy to the human syndrome, the deletion is flanked on one side by the *Tcte1* gene, involves *Cbfa1*, but extends further proximally, deleting *Mut*.⁴² The localisation and extent of this deletion is thus very similar to the deletion observed in the patient described by Nienhaus *et al*.³³ These results indicate that the murine and human conditions are not only identical phenotypically, but also share a common molecular basis.

Pathobiology

CBFA1 belongs to the core binding factor (CBF) transcription factors, a family of heterodimeric proteins of two unrelated subunits comprising a DNA binding α subunit and a non-DNA binding β subunit. The β subunit is encoded by the CBF β gene and binds to the α subunit. The mammalian CBF α subunits are encoded by three distinct genes (*Cbfa1*, *Cbfa2*, and *Cbfa3*) that share a conserved 128 amino acid domain, called the runt domain because of its homology to the *Drosophila* pair-rule gene *runt*. CBFA2 is frequently involved in chromosomal translocations in acute leukaemia⁴⁵ and the gene was shown to be crucial for normal liver haematopoiesis.⁴⁶

The role of *Cbfa1* in development has been elucidated by the generation of mutated mice in which the *Cbfa1* gene locus was targeted.⁴²⁻⁴⁷ Mice completely deficient in *Cbfa1* (-/-) died immediately after birth owing to a complete absence of bone. Further histological analysis showed an arrest in endochondral as well as membranous bone formation. *Cbfa1* (-/-) mice develop normal cartilage anlagen but there is no differentiation of mesenchymal stem cells into osteoblasts, no ossification, and no vascular invasion of cartilage. In wild type mice, expression of *Cbfa1* was shown by in situ hybridisation in all mesenchymal condensations of the skeleton, and in cells of the osteoblastic lineage at later stages of development.⁴⁷⁻⁴⁸ Stimulation of cells that normally do not express *Cbfa1* with BMP7 (a member of a family of secreted molecules that can induce bone formation) leads to expression of *Cbfa1* before the expression of any other osteoblast marker genes suggesting that *Cbfa1* is part of the BMP signalling cascade. Furthermore, transient transfection of C3H10T1/2 cells (pluripotent fibroblasts that are not committed to the osteoblast lineage) with *Cbfa1* cDNA led to the expression of bone specific genes, such as osteocalcin and bone sialoprotein.⁴⁸ These experiments identify *Cbfa1* as an inducer of osteoblast differentiation.

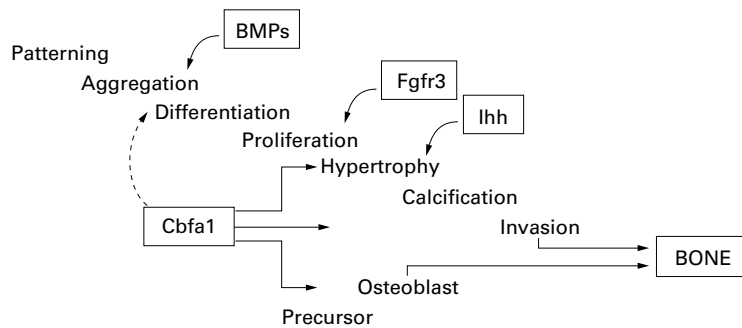


Figure 2 Role of *Cbfa1* in bone formation. The different steps of endochondral bone formation are listed. Patterning genes regulate the shape and number of the individual skeletal elements. Precursor cells aggregate and subsequently differentiate into chondrocytes. Chondrocytes proliferate, hypertrophy, and calcify before they are replaced by bone. Some of the factors that are known to regulate this process are shown on the right. *Cbfa1* controls the differentiation of precursor cells into osteoblasts, regulates chondrocyte differentiation towards hypertrophy, and is necessary for the invasion of calcified cartilage. *Cbfa1* controls differentiation of aggregated precursor cells of the clavicular anlage (dotted arrow).

Very recent findings suggest that *Cbfa1* is not only essential for osteoblast formation, but also a major regulator of chondrocyte differentiation. During endochondral bone formation (all long bones, vertebrae) a temporary cartilaginous template (anlage) is subsequently replaced by bone. Chondrocytes within this cartilaginous model proliferate and then differentiate to hypertrophy. In *Cbfa1* (-/-) mice hypertrophy does not take place, indicating a role for *Cbfa1* in the regulation of chondrocyte differentiation.⁴⁹ In addition, vascular invasion of calcified cartilage does not take place. This may be caused by a lack of interstitial collagenase expression in *Cbfa1* (-/-) mice. Interstitial collagenase (collagenase-3) was recently shown to be regulated by *Cbfa1*.⁵⁰

Clavicular hypoplasia is one of the hallmarks of CCD. Huang *et al*⁵¹ studied the development of the clavicle in *wt* and *cleidocranial dysplastic* (*Ccd/+*) mice. In *Ccd* mice the initial condensation of mesenchymal stem cells takes place but there is no differentiation into precursor cells, resulting in absence of the clavicular anlage. *Cbfa1* is thus a crucial factor regulating the differentiation of mesenchymal stem cells in bone and cartilage precursors. Fig 2 summarises the different functions of *Cbfa1* during skeletal development.

In summary, CBFA1 was identified as the culprit gene underlying CCD. *Cbfa1* controls the differentiation of precursor cells into osteoblasts, the cells that actually secrete bony matrix and thereby form bone. In addition, *Cbfa1* plays a role in the regulation of chondrocyte differentiation during endochondral bone formation. Understanding this new “master gene” will provide insight into the pathobiology of CCD as well as into the basic mechanisms of bone formation.

- 1 Mundlos S, Olsen BR. Heritable diseases of the skeleton. Part I. Molecular insights into skeletal development - transcription factors and signaling pathways. *FASEB J* 1997;11:125-32.
- 2 Mundlos S, Olsen BR. Heritable diseases of the skeleton. Part II. Molecular insights into skeletal development - matrix components and their homeostasis. *FASEB J* 1997; 11:227-33.
- 3 Martin. Sur un déplacement naturel de la clavicule. *J Med Chir Pharmacol* 1765;23:456-60.

- 4 Scheuthauer G. Kombination rudimentärer Schlüsselbeine mit Anomalien des Schädels beim erwachsenen Menschen. *Allg Wien Med Ztg* 1871;16:293-5.
- 5 Marie P, Sainton P. Sur la dystosose cléido-cranienne héréditaire. *Rev Neurol* 1898;6:835-8.
- 6 Jackson WPU. Osteo-dental dysplasia (cleido-cranial dysostosis). The “Arnold Head”. *Acta Med Scand* 1951;139:292-307.
- 7 Rimoin DL. International nomenclature of constitutional diseases of bone. *J Pediatr* 1978;93:614-18.
- 8 Schuch P, Fleischer-Peters A. Zur Klinik der Dystosose cleidocranialis. *Z Kinderheilkd* 1967;98:107-32.
- 9 Jarvis JL, Keats TE. Cleidocranial dysostosis. A review of 40 new cases. *AJR* 1974;121:5-16.
- 10 Cole WR, Levine S. Cleidocranial dysostosis. *Br J Radiol* 1951;24:549-55.
- 11 Gorlin RJ, Cohen MM, Levin LS. Syndromes affecting bone: other skeletal disorders. In: *Syndromes of the head and neck*. 3rd ed. Oxford: Oxford University Press, 1990:249-53.
- 12 Chitayat D, Hodgkinson, KA, Azouz EM. Intrafamilial variability in cleidocranial dysplasia: a three generation family. *Am J Med Genet* 1992;42:298-303.
- 13 Jensen BL, Kreiborg S. Craniofacial growth in cleidocranial dysplasia - a roentgencephalometric study. *J Craniofac Genet Dev Biol* 1995;15:35-43.
- 14 Jensen BL, Kreiborg S. Craniofacial abnormalities in 52 school-age and adult patients with cleidocranial dysplasia. *J Craniofac Genet Dev Biol* 1993;13:98-108.
- 15 Stocks P, Barrington A. Cleidocranial dysostosis. In: *The treasury of human inheritance*. Vol III, part I. London: Cambridge University Press, 1981:121-39.
- 16 Crouzon O, Buttier H. Sur une forme particuliere, de la dystosose cleidocranienne de Pierre Marie et Sainton (forme cleido-cranio-pelviennne). *Bull Mem Soc Dilala Hop* 1921;45:972-1099.
- 17 Jensen BL. Somatic development in cleidocranial dysplasia. *Am J Med Genet* 1990;35:69-74.
- 18 Kempfle B. Dystosose cleidocranialis. *Dtsch Zahnartz Z* 1965;20:1364-9.
- 19 Levin EJ, Sonnenschein H. Cleidocranial dysostosis. *N Y State J Med* 1963;63:1562-6.
- 20 Jensen BL, Kreiborg S. Development of the dentition in cleidocranial dysplasia. *J Oral Pathol Med* 1990;19:89-93.
- 21 Hitchin AD. Cementum and other root abnormalities of permanent teeth in cleidocranial dysostosis. *Br Dent J* 1975;139:313-18.
- 22 Lukinmaa PL, Jensen BL, Thesleff I, Andreassen JO, Kreiborg S. Histological observations of teeth and peridental tissues in cleidocranial dysplasia imply increased activity of odontogenic epithelium and abnormal bone remodeling. *J Craniofac Genet Dev Biol* 1995;15:212-21.
- 23 Becker A, Shteyer A, Bimstein E, Lustmann J. Cleidocranial dysplasia. Part 2. Treatment protocol for the orthodontic and surgical modality. *Am J Orthod Dentofacial Orthop* 1997;111:173-83.
- 24 Becker A, Lustmann J, Shteyer A. Cleidocranial dysplasia. Part 1. General principles of the orthodontic and surgical treatment modality. *Am J Orthod Dentofacial Orthop* 1997; 111:28-33.
- 25 Jensen BL, Kreiborg S. Dental treatment strategies in cleidocranial dysplasia. *Br Dent J* 1992;172:243-7.
- 26 Hall BD. Syndromes and situations associated with congenital clavicular hypoplasia or agenesis. In: Papadatos CJ, Bartsocas CS, eds. *Skeletal dysplasias*. New York: Alan R Liss, 1982:279-88.
- 27 Brueton LA, Reeve A, Ellis R, Husband P, Thompson EM, Kingston HM. Apparent cleidocranial dysplasia associated with abnormalities of 8q22 in three individuals. *Am J Med Genet* 1992;43:612-18.
- 28 Francke U, Weber F, Sparkes RS, Mattson PD, Mann J. Duplication 11(q21-23-qter) syndrome. *Birth Defects* 1977; 13:167-86.
- 29 Nakai H, Yamamoto Y, Kuroki Y. Partial trisomy of 11 and 22 due to familial translocation t(11;22)(q23;q11), inherited in three generations. *Hum Genet* 1979;51:349-55.
- 30 Schinzel A. Trisomy 20pter-q11 in a malformed boy from a t(13;20)(p11;q11) translocation carrier mother. *Hum Genet* 1980;53:169-72.
- 31 Palmer CG, Bader P, Slovak ML, Comings DE, Pettenati MJ. Partial deletion of chromosome 6p: delineation of the syndrome. *Am J Med Genet* 1991;39:155-60.
- 32 Goodman RM, Tadmor, R, Zaritsky A, Becker SA. Evidence for an autosomal recessive form of cleidocranial dysostosis. *Clin Genet* 1975;8:20-9.
- 33 Nienhaus H, Mau U, Zang KD, Henn W. Pericentric inversion of chromosome 6 in a patient with cleidocranial dysplasia. *Am J Med Genet* 1993;46:630-1.
- 34 Mundlos S, Mulliken JB, Abramson DL, Warman ML, Knoll JH, Olsen BR. Genetic mapping of cleidocranial dysplasia and evidence of a microdeletion in one family. *Hum Mol Genet* 1995;4:71-5.
- 35 Feldman GJ, Robin NH, Brueton LA, *et al*. A gene for cleidocranial dysplasia maps to the short arm of chromosome 6. *Am J Hum Genet* 1995;56:938-43.
- 36 Gelb BD, Cooper E, Shevell M, Desnick RJ. Genetic mapping of the cleidocranial dysplasia (CCD) locus on chromosome band 6p21 to include a microdeletion. *Am J Med Genet* 1995;58:200-5.
- 37 Ramesar RS, Greenberg J, Martin R, *et al*. Mapping of the gene for cleidocranial dysplasia in the historical Cape Town (Arnold) kindred and evidence for locus homogeneity. *J Med Genet* 1996;33:511-14.

- 38 Mundlos S, Otto F, Mundlos C, *et al.* Mutations involving the transcription factor *CBFA1* cause cleidocranial dysplasia. *Cell* 1997;**89**:773-9.
- 39 Lee B, Thirunavukkarasu K, Zhou L, *et al.* Missense mutations abolishing DNA binding of the osteoblast-specific transcription factor *OSF2/CBFA1* in cleidocranial dysplasia. *Nat Genet* 1997;**16**:307-10.
- 40 Muragaki Y, Mundlos S, Upton J, Olsen BR. Altered growth and branching pattern in synpolydactyly caused by mutations in *HOXD13*. *Science* 1996;**271**:548-51.
- 41 Brais B, Bouchard JP, Xie YG, *et al.* Short GCG expansions in the *PABP2* gene cause oculopharyngeal muscular dystrophy. *Nat Genet* 1998;**18**:164-7.
- 42 Otto F, Thornell AP, Crompton T, *et al.* *CBFA1*, a candidate gene for cleidocranial dysplasia syndrome, is essential for osteoblast differentiation and bone development. *Cell* 1997;**89**:765-71.
- 43 Sillence DO, Ritchie HE, Selby PB. Animal model: skeletal anomalies in mice with cleidocranial dysplasia. *Am J Med Genet* 1987;**27**:75-85.
- 44 Mundlos S, Huang LF, Selby P, Olsen BR. Cleidocranial dysplasia in mice. *Ann N Y Acad Sci* 1996;**785**:301-2.
- 45 Miyoshi H, Shimizu K, Kozu T, Maseki N, Kaneko Y, Ohki M. *t*(8,21) breakpoints on chromosome 21 in acute myeloid leukemia are clustered within a limited region of a single gene, *AML1*. *Proc Natl Acad Sci USA* 1991;**88**:10431-4.
- 46 Okuda T, van Deursen J, Hiebert SW, Grosveld G, Downing JR. *AML1*, the target of multiple chromosomal translocations in human leukemia, is essential for normal fetal liver hematopoiesis. *Cell* 1996;**84**:321-30.
- 47 Komori T, Yagi H, Nomura S, *et al.* Targeted disruption of *CBFA1* results in a complete lack of bone formation owing to maturational arrest of osteoblasts. *Cell* 1997;**89**:755-64.
- 48 Ducy P, Zhang R, Geoffroy V, Ridall AL, Karsenty G. *Osfr2/CBFA1*: a transcriptional activator of osteoblast differentiation. *Cell* 1997;**89**:747-54.
- 49 Kim IS, Otto F, Zabel BU, Mundlos S. Regulation of chondrocyte differentiation by *Cbfa1*. *Mech Dev* (in press).
- 50 Porte D, Tuckermann J, Becker M, *et al.* Both *AP-1* and *Cbfa1*-like factors are required for the induction of interstitial collagenase by parathyroid hormone. *Oncogene* (in press).
- 51 Huang LF, Fukai N, Selby PB, Olsen BR, Mundlos S. Mouse clavicular development: analysis of wild type and cleidocranial dysplasia mutant mice. *Dev Dyn* 1997;**210**:33-40.