

Disruption of heart sarcoglycan complex and severe cardiomyopathy caused by β sarcoglycan mutations

Rita Barresi, Claudia Di Blasi, Tiziana Negri, Raffaella Brugnoli, Andrea Vitali, Giorgio Felisari, Antonio Salandi, Sergio Daniel, Ferdinando Cornelio, Lucia Morandi, Marina Mora

Abstract

Two young males with limb-girdle muscular dystrophy (LGMD) resulting from sarcoglycan deficiency died at 27 (patient 1) and 18 years (patient 2) of severe cardiomyopathy. Genetic analysis showed that they were compound heterozygotes for mutations in the β sarcoglycan gene. One of these mutations, an 8 bp duplication in exon 3, was common to both patients. The second mutation in patient 2 was a 4 bp deletion at the splice donor site of intron 2, not reported previously. Patient 2 had more severe heart and skeletal muscle defects with faster deterioration; no sarcoglycans were detected in his skeletal muscle. The second mutation in patient 1, inferred because the unaffected father carries the 8 bp duplication, was not found. In patient 1, both heart and skeletal muscle were analysed and showed reduction of all sarcoglycans in both tissues and incorrect localisation of α and γ sarcoglycans in heart. Therefore mutations in one sarcoglycan gene can disrupt the entire sarcoglycan complex in both skeletal and cardiac muscle. Differing expression patterns of sarcoglycan components in heart and skeletal muscle could be the result of alternatively spliced transcripts in these tissues. By sequencing an alternative transcript, highly expressed in the heart and skeletal muscle of patient 1, we found an 87 bp cryptic exon not previously reported. Although cardiomyopathy can result from mutations in α and γ sarcoglycans, we show for the first time that the condition can also be caused by mutations in the β sarcoglycan gene. This report therefore expands the phenotype of sarcoglycanopathies and suggests that cardiac function in LGMD patients with defective sarcoglycan expression should be monitored.

(*J Med Genet* 2000;37:102-107)

Keywords: limb-girdle muscular dystrophy; sarcoglycans; dystrophin associated proteins; cardiomyopathy

Sarcoglycans are glycosylated transmembrane components of the large dystrophin associated glycoprotein complex isolated following the biochemical and molecular characterisation of dystrophin.^{1,2} The sarcoglycan subcomplex³ consists of at least four proteins: α sarcoglycan

of 50 kDa, β sarcoglycan of 43 kDa, and γ and δ sarcoglycan, both of 35 kDa. Alpha, γ , and δ sarcoglycans are expressed exclusively in striated and smooth muscle, while β sarcoglycan is expressed ubiquitously, although mainly in skeletal and cardiac muscle. The genes encoding all four sarcoglycans have been identified and mutations in each have been found among patients with limb-girdle muscular dystrophies (LGMD) of variable severity.⁴⁻¹⁰

Sarcoglycans are tightly bound to each other so that mutation in one normally results in partial or total deficiency of all of them.^{4-7,11} This has been shown in skeletal muscle but not in heart except in a single patient. This patient had cardiomyopathy and lacked adhalin (α sarcoglycan) and a 35 kDa dystrophin associated protein (presumably γ sarcoglycan) in the heart, but genetic analysis was not performed.¹²

Cardiomyopathy has been reported in patients with LGMD resulting from sarcoglycan deficiency. Some of these patients had mutations in the α sarcoglycan gene,⁸ while Tunisian patients with cardiomyopathy have been linked to the chromosome 13 locus of γ sarcoglycan.¹³ Following the discovery of a δ sarcoglycan mutation in the Syrian cardiomyopathic hamster,¹⁴ a δ sarcoglycan mutation was suspected to be the main cause of cardiomyopathy in humans with sarcoglycanopathies. No β sarcoglycan mutations causing cardiomyopathy have so far been reported.

Review of our sarcoglycan deficient patients showed cardiomyopathy in a few of them. We analysed the sarcoglycan genes from these patients and in the two with the most severe cardiomyopathy (causing death) we found mutations in the β sarcoglycan gene. In one of these patients we were able to analyse a sample of heart.

Subjects and methods

PATIENT 1

This 27 year old male, born to non-consanguineous parents (fig 1), was first seen at the age of 15 for mild weakness of the proximal leg muscles. Plasma CK was 2540 U/l (normally <200 U/l). Neurological examination showed proximal leg muscle hypotrophy and pelvic girdle muscle weakness. Muscle biopsy (after informed consent) showed dystrophic features with increased perimysial and endomysial connective tissue, central nuclei, splittings, and a few degenerating fibres. He was initially diagnosed as BMD, but successive dystrophin and dystrophin gene analyses were

Department of
Neuromuscular
Diseases, Istituto
Nazionale Neurologico
"C Besta", Via Celoria
11, 20133 Milano, Italy
R Barresi
C Di Blasi
T Negri
R Brugnoli
S Daniel
F Cornelio
L Morandi
M Mora

Department of
Rehabilitative
Cardiology, Ospedale
Generale
"Moriggia-Pelascini",
Gravedona, Como,
Italy
A Vitali

Istituto Scientifico
"Eugenio Medea",
Bosisio Parini, Lecco,
Italy
A Salandi
G Felisari

Correspondence to:
Dr Mora

Revised version received
4 August 1999
Accepted for publication 27
August 1999

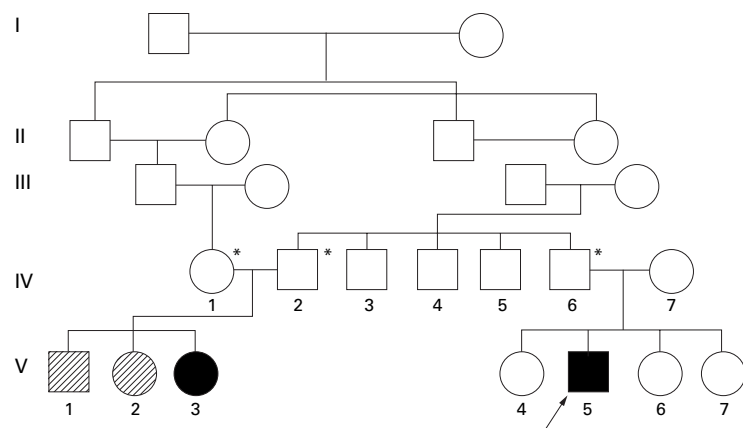


Figure 1 Pedigree of patient 1 (V.5). V.1 and V.2 died suddenly at the ages of 6 and 13 months respectively. Asterisks indicate family members with heterozygous 383'384ins376-383 duplication.

normal. His condition worsened slowly. Echocardiogram at 23 years showed dilated cardiomyopathy with hypokinetic left ventricle and mitral valve insufficiency. Immunohistochemical analysis showed reduced expression of α sarcoglycan.

Three years later, three episodes of ventricular fibrillation required intensive care, following which he lost the ability to walk by himself. He was referred for heart transplantation, but died of acute cardiac insufficiency. The heart was sampled shortly after death, after obtaining the consent of the family.

A paternal female cousin (aged 28) of patient 1, daughter of consanguineous parents (fig 1), had severe myopathy from early infancy which confined her to a wheelchair at the age of 15. She has no symptoms or signs of cardiomyopathy. Muscle biopsy at the age of 7 years had disclosed severe dystrophic features. Unfortunately the muscle specimen is no longer available. The father, two sisters, brother, and a paternal uncle and aunt (father and mother of the affected cousin) of patient 1 were all clinically normal, had normal CK levels, and normal muscle biopsy. The mother of patient 1 was also normal on clinical examination and had normal CK levels.

PATIENT 2

This was an 18 year old male, unrelated to patient 1, born to non-consanguineous parents, and first diagnosed with LGMD at the age of 10. Disease onset at 4 years manifested as mild weakness of the pelvic girdle and proximal leg muscles. CK was 3450 U/l. At the age of 10 a muscle biopsy (after informed consent) showed dystrophic features, including peri- and endomysial connective tissue proliferation. At the same age the patient underwent Achilles tendon tenotomy and subsequently used calipers for walking. Digitalis therapy was also introduced for defective left ventricle function (ejection fraction 40%). At the age of 15, cardiac arrhythmia was detected after cycling exercise; vital capacity was reduced (50% of

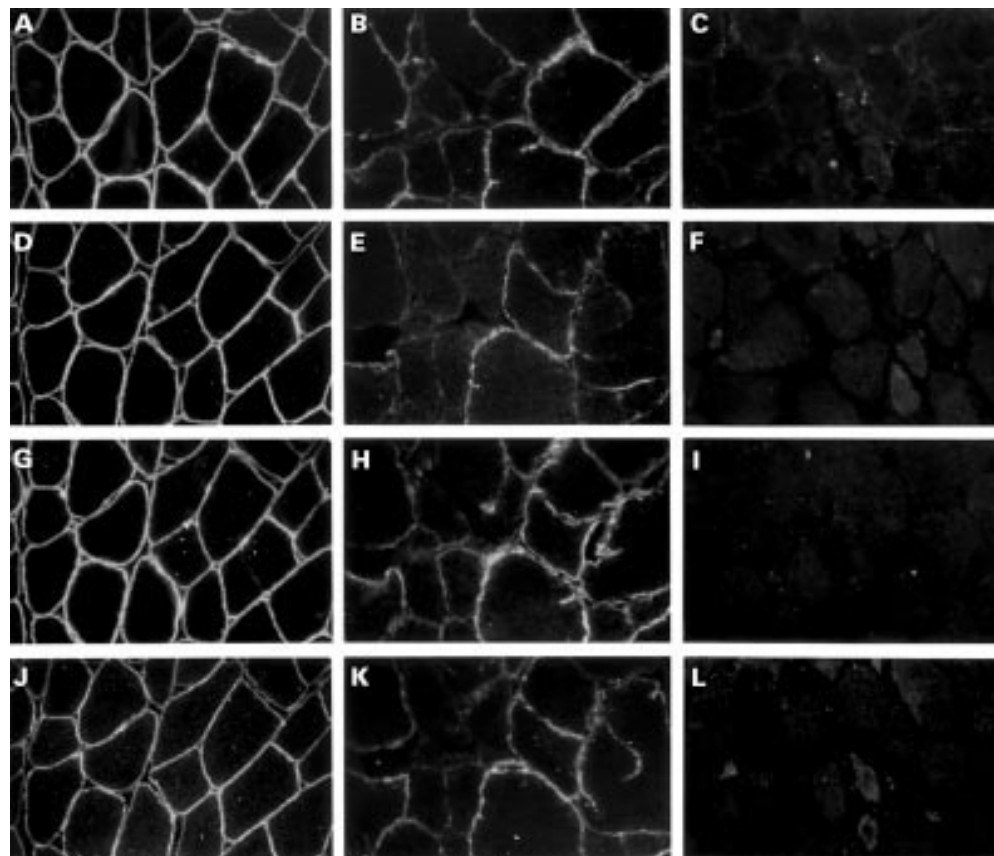


Figure 2 α (A, B, C), β (D, E, F), γ (G, H, I), and δ sarcoglycan (J, K, L) immunostaining in skeletal muscle from a control (A, D, G, J), patient 1 (B, E, H, K), and patient 2 (C, F, I, L) showing reduced expression of all sarcoglycans in patient 1 and absence of all sarcoglycans in patient 2.




Figure 3 Immunoblot of α , β , and γ sarcoglycans and α , β , and δ sarcoglycans from heart of control and patient 1 and from skeletal muscle of patient 1, patient 2, and normal control.

predicted value for this age). The cardiomyopathy worsened progressively and at 18 years the ejection fraction was 18%. The patient did not respond to therapy and was referred for heart transplantation. A few months later he died of cardiac insufficiency and pulmonary oedema. A heart sample was not available.

IMMUNOHISTOCHEMISTRY

Heart from patient 1 and a control and quadriceps muscle biopsies from patients 1 and 2 were frozen in isopentane/liquid nitrogen and stored in liquid nitrogen until use. Control heart samples were from a patient with cardiomyopathy unrelated to muscular dystrophy who underwent heart transplantation. Immunohistochemical analysis of dystrophin used polyclonal antibodies as described previously.¹⁵ β dystroglycan and α , β , γ , and δ sarcoglycans were analysed immunohistochemically on 6 μ m cryostat sections using commercial monoclonals (Novocastra, Newcastle upon Tyne, UK); dilutions were 1:50, 1:25, 1:100, 1:25, and 1:25 in PBS containing 10% horse serum. Antibodies were detected with biotinylated horse anti-mouse IgG (Vector Labs, Burlingame, CA, USA), followed by rhodamine avidin D (Vector).

IMMUNOBLOTTING

Cryosections from skeletal muscle and heart biopsies were homogenised in 50 vol SDS extraction buffer (80 mmol/l Tris-HCl, pH 6.8, 10% SDS, 0.115 mol/l sucrose, 1% β mercaptoethanol, 1 mmol/l PMSF, 1 mmol/l benzamidine, and 1 mmol/l EDTA) and incubated at 50°C for 10 minutes. Samples were then centri-

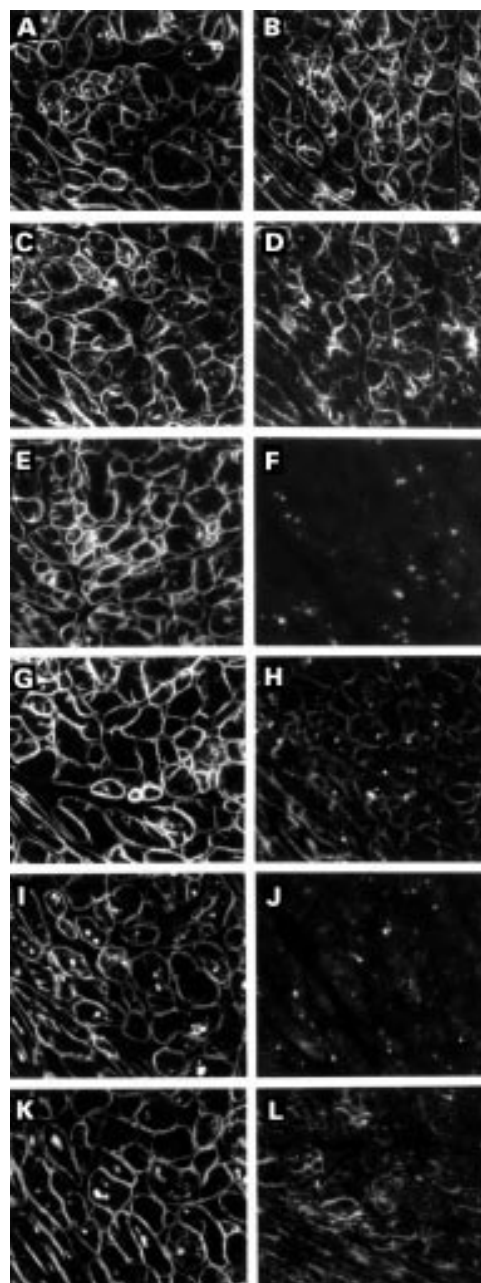


Figure 4 Dystrophin (A, B), β dystroglycan (C, D), α (E, F), β (G, H), γ (I, J), and δ sarcoglycan (K, L) immunostaining in heart of control (left column) and patient 1 (right column) showing slightly reduced β dystroglycan, greatly reduced β sarcoglycan, traces of δ sarcoglycan, and absence of α and γ sarcoglycans. Spots inside fibres are autofluorescent lipofuscin granules.

fuged and separated on 10% SDS-PAGE, transferred to nitrocellulose membranes, and immunostained with a mixture of antibodies to α , β , and γ or δ sarcoglycans (Novocastra) diluted respectively 1:20, 1:10, 1:20, and 1:50.

MOLECULAR ANALYSIS

Genomic DNA extracted from blood (QIAamp Blood Kit, QIAGEN GmbH, Germany) was analysed by PCR using oligonucleotide primers flanking the intron-exon junctions of the β sarcoglycan gene according to Bönne-mann *et al.*¹⁶ A total of 100 ng of genomic DNA was amplified in a 50 μ l reaction. After

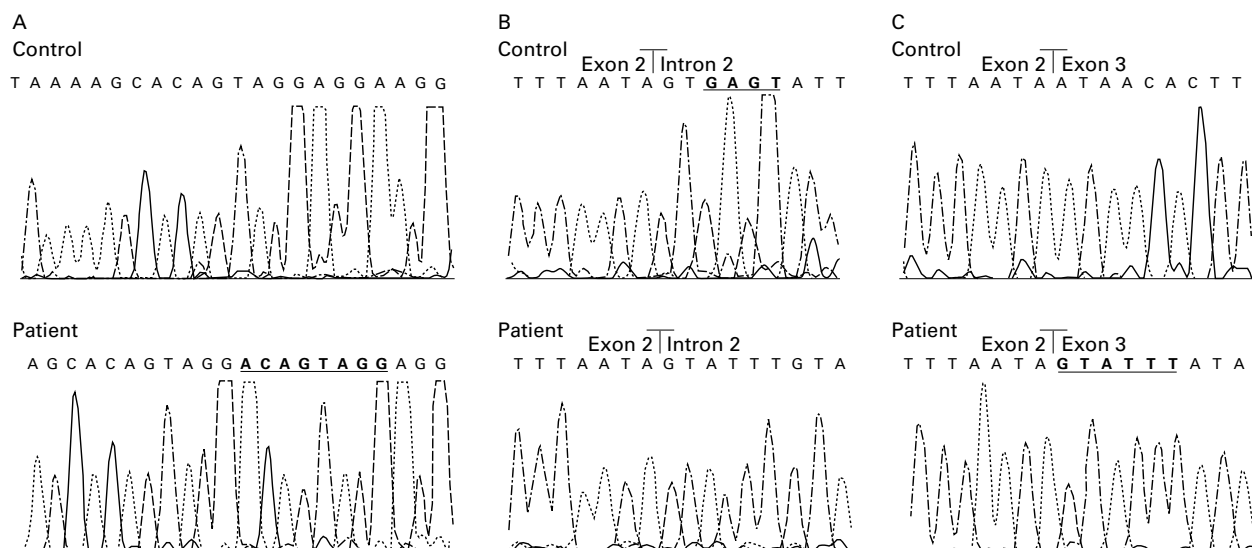


Figure 5 Sequence analysis in patients 1 and 2 showing an 8 bp duplication 383^384ins376-383 (A) on one allele of both patients. (B) and (C) show respectively a 4 bp deletion at position 243+3 (at the splice donor site of intron 2) of genomic DNA on the second allele of patient 2, and a 6 bp insertion, resulting from the deletion, at position 243 of cDNA in the same patient.

denaturation at 94°C for 2.5 minutes, 35 amplification cycles were carried out as follows: 40 seconds denaturation at 94°C, one minute annealing at 55°C, 30 seconds extension at 72°C. For amplification of exon 1, DNA was subjected to touchdown PCR in a reaction mix containing 8% dimethylsulphoxide. The amplification products were analysed by agarose gel electrophoresis and purified by QIAquick PCR Purification Kit (QIAGEN). An aliquot of the PCR product was mixed with 9 μ l of stop solution, denatured at 94°C for three minutes, rapidly cooled on ice, and loaded onto 0.5 \times MDE/0.6 \times TBE non-denaturing gel for single strand conformation polymorphism analysis. Electrophoresis was performed at 80 V for 16 hours in 0.6 \times TBE. Aberrant conformers were sequenced on both strands using the same primers as for the PCR amplification using an Applied Biosystems automated sequencer. Purified PCR products were subcloned into a pMOSBlue vector and DNA was sequenced using T7 promoter and U19 primers (Amersham Pharmacia, Rainham, Essex, UK). cDNA, obtained from RNA extracted from skeletal muscle and heart by the phenol-chloroform method, was analysed as for genomic DNA using primers according to Bönemann *et al.*⁵

Results

SKELETAL MUSCLE

Immunohistochemistry showed normal or almost normal dystrophin and β dystroglycan expression in both patients; expression of all four sarcoglycans was reduced in patient 1 and absent in patient 2 (fig 2). All four sarcoglycans were normally expressed in the muscle biopsies of the family of patient 1.

Immunoblotting showed reduced intensity of all sarcoglycan bands in patient 1 and absence of sarcoglycans in patient 2 (fig 3).

HEART

Analysis of H&E stained sections from the heart of patient 1 showed normal cardiac mor-

phology. Immunohistochemistry showed normal expression of dystrophin, slight reduction of β dystroglycan, major reduction of β sarcoglycan, traces of δ sarcoglycan, and absence of α and γ sarcoglycans (fig 4). On immunoblotting, all sarcoglycan bands were present but at greatly reduced intensity (fig 3).

MOLECULAR ANALYSIS

In patient 1 we found an 8 bp duplication 383^384ins376-383 (fig 5), producing a frameshift and an immediate stop codon; no mutations were found in the second allele. The affected cousin (V.3, fig 1) was homozygous, and her parents and the father of patient 1 were heterozygous for the same mutation. By sequencing an alternative transcript detected by PCR both in skeletal muscle and heart from patient 1, we found a cryptic exon of 87 bp at position 13281 of the genomic DNA (Accession No Y09781) not previously reported.

A new neutral polymorphism 244-21c>t was detected (on one or both alleles) in the intronic region flanking exon 3 in several members of the family of patient 1 and in unrelated subjects.

In patient 2 the same mutation as in patient 1 was found on one allele, and a 4 bp (GAGT) deletion was detected at the splice donor site of intron 2 (at position 243+3) on the second allele, causing aberrant splicing and a consequent 6 bp insertion (243^244insGTATTT) between exons 2 and 3 (fig 5). The patient's father was heterozygous for the duplication and the mother was heterozygous for the deletion.

Discussion

Cardiomyopathy has been reported in patients with mutations in the α sarcoglycan gene⁸ and in Tunisian patients with sarcoglycan deficiency linked to the γ sarcoglycan locus.¹³ Delta sarcoglycan mutation causes cardiomyopathy in the Syrian BIO 14.6 hamster¹⁴ and is suspected to cause cardiomyopathy in LGMD patients. Several other patients with cardiomyopathy and

altered α sarcoglycan expression have been reported but molecular analysis was not done.^{12 17 18} We describe for the first time severe fatal cardiomyopathy in two young patients owing to mutations in the β sarcoglycan gene. One of these mutations has not previously been reported. We also detected a new β sarcoglycan polymorphism.

The 8 bp duplication 383~384ins376-383 produces a truncated β sarcoglycan (at aa 129) lacking most of the extracellular region. The 4 bp deletion causes aberrant splicing and a 6 bp insertion coding for valine and phenylalanine in the transmembrane region, which is important for membrane localisation. Unfortunately, it is not possible to draw conclusions about the specific role of each mutation in the protein product or clinical phenotype, since in both our patients another β sarcoglycan mutation was present, although we only have indirect evidence for this in patient 1; the father and other relatives, carrying the 8 bp duplication on one allele, were unaffected. We cannot completely exclude that a mutation in another sarcoglycan may be responsible for the disease in patient 1; however, SSCP analysis of the other sarcoglycans failed to show any abnormal product. We suppose that the second mutation in the β sarcoglycan gene of this patient may be in some untranslated regulatory region.

The myopathic cousin of patient 1, who does not have cardiomyopathy, is homozygous for the 8 bp duplication, which cannot therefore be a major cause of cardiomyopathy. This mutation has also been reported in other patients without cardiomyopathy.¹⁹ However, a role of this duplication in cardiomyopathy cannot be completely excluded at present since two sibs of the homozygous cousin of patient 1 died suddenly (fig 1).

LGMD2E,²⁰ as a result of β sarcoglycan, is characterised by a severe phenotype,^{5 16 19} although milder involvement is known.^{6 21 22} Patient 1, with partial expression of β sarcoglycan (and of the other sarcoglycans) in skeletal muscle, had milder muscle involvement than patient 2 who essentially did not express sarcoglycans. This indicates a possible correlation in skeletal muscle between disease severity and protein quantity, as also suggested by others.²³

We also found altered expression of all sarcoglycan components in the heart of patient 1. This indicates that, in heart as in skeletal muscle, mutations in one of the sarcoglycan genes can cause disruption of the entire complex. Such disruption has been hypothesised in sarcoglycan deficient LGMD patients with cardiomyopathy, but not clearly proven, owing to the difficulty of obtaining heart samples for analysis. Altered adhalin and 35 kDa dystrophin associated glycoprotein expression in the heart was found, but not characterised at the molecular level, in the patient reported by Fadic *et al.*¹² Reduction of dystrophin associated glycoproteins in the heart, secondary to absence of dystrophin, has also been reported in patients with cardiomyopathy caused by mutations in the dystrophin gene.²⁴

The immunohistochemical expression of the sarcoglycan complex in the cardiac muscle of patient 1 differed from that in his skeletal muscle, with lack of α and γ sarcoglycans in heart, and reduced expression of all sarcoglycans in skeletal muscle. However, immunoblotting showed that all four sarcoglycans were present in both tissues, although in greatly reduced quantities, indicating incorrect localisation of α and γ sarcoglycans in the heart. Alternatively spliced β sarcoglycan transcripts have been reported in several tissues, including heart and skeletal muscle,^{5 6} and at least two additional exons of the β sarcoglycan gene have been predicted from sequence analysis,²² which may contribute to different tissue specific transcripts. We have found a new cryptic exon of 87 bp by sequencing an alternative transcript in skeletal muscle and heart from patient 1. It may be that β sarcoglycan mutations affect heart and skeletal muscle transcripts differently and that abnormal β sarcoglycan gene products have different effects on the localisation of the other sarcoglycans in these two tissues. Further studies are necessary to characterise β sarcoglycan transcripts in the heart better, in order to elucidate the role of β sarcoglycan and its interactions with other sarcoglycans, dystrophin, and dystrophin associated proteins, and to clarify the pathogenetic mechanisms of sarcoglycan mutations in cardiomyopathy. In this regard it is intriguing that most LGMD patients with sarcoglycan deficiency have dilated cardiomyopathy.

A recent hypothesis attributes idiopathic dilated cardiomyopathy to molecular defects in force transmitting proteins and hypertrophic cardiomyopathy to defects in force generating proteins²⁵; this has also been suggested to apply to sarcoglycanopathies.²⁶ Sarcoglycan disruption in the heart may reduce the capacity of the dystrophin associated glycoprotein complex to transmit force to the extracellular matrix. To verify this it would be of considerable interest to determine the genes responsible for the cardiomyopathy in other sarcoglycan deficient patients and it may also be profitable to search for cardiac alterations in patients with β sarcoglycan mutations.

In conclusion, this report expands the known phenotype of sarcoglycanopathies and indicates that LGMD patients with defective sarcoglycan expression should be monitored for cardiac function.

We thank Flavia Blasevich and Silvia Galbiati for technical assistance and Don Ward for help with the English.

- Campbell KP, Kahl SD. Association of dystrophin and an integral membrane glycoprotein. *Nature* 1989;338:259-62.
- Yoshida M, Ozawa E. Glycoprotein complex anchoring dystrophin to sarcolemma. *J Biochem* 1990;108:748-52.
- Yoshida M, Suzuki A, Yamamoto H, Noguchi S, Mizuno Y, Ozawa E. Dissociation of the complex of dystrophin and its associated proteins into several unique groups by n-octyl β -D-glucoside. *Eur J Biochem* 1994;222:1055-61.
- Roberds SL, Leturcq F, Allamand V, *et al.* Missense mutations in the adhalin gene linked to autosomal recessive muscular dystrophy. *Cell* 1994;78:625-33.
- Bönnemann CG, Modi R, Noguchi S, *et al.* β -sarcoglycan (A3b) mutations cause autosomal recessive muscular dystrophy with loss of the sarcoglycan complex. *Nat Genet* 1995;11:266-73.
- Lim LE, Duclos F, Broux O, *et al.* β -sarcoglycan: characterization and role in limb-girdle muscular dystrophy linked to 4q12. *Nat Genet* 1995;11:257-65.

- 7 Noguchi S, MacNally EM, Ben Othmane K, *et al.* Mutations in the dystrophin-associated protein γ -sarcoglycan in chromosome 13 muscular dystrophy. *Science* 1995;270:819-22.
- 8 Piccolo F, Roberds SL, Jeanpierre M, *et al.* Primary adhalinopathy: a common cause of autosomal recessive muscular dystrophy of variable severity. *Nat Genet* 1995;10:243-5.
- 9 Nigro V, Piluso G, Belsito A, *et al.* Identification of a novel sarcoglycan gene at 5q33 encoding a sarcolemmal 35 kDa glycoprotein. *Hum Mol Genet* 1996;5:1179-86.
- 10 Nigro V, de Sà Moreira E, Piluso G, *et al.* Autosomal recessive limb-girdle muscular dystrophy, LGMD2F, is caused by a mutation in the δ -sarcoglycan gene. *Nat Genet* 1996;14:195-8.
- 11 Barresi R, Confalonieri V, Lanfossi M, *et al.* Concomitant deficiency of β - and γ -sarcoglycans in 20 α -sarcoglycan (adhalin)-deficient patients: immunohistochemical analysis and clinical aspects. *Acta Neuropathol* 1997;94:28-35.
- 12 Fadic R, Sunada Y, Waclawik AJ, *et al.* Deficiency of a dystrophin-associated glycoprotein (adhalin) in a patient with muscular dystrophy and cardiomyopathy. *N Engl J Med* 1996;334:362-6.
- 13 Ben Hamida M, Ben Hamida C, Zouari M, Belal S, Hentati F. Limb-girdle muscular dystrophy 2C: clinical aspects. *Neuromusc Disord* 1996;6:493-4.
- 14 Nigro V, Okazaki Y, Belsito A, *et al.* Identification of the Syrian cardiomyopathy gene. *Hum Mol Genet* 1997;6:601-6.
- 15 Morandi L, Mora M, Confalonieri V, *et al.* Dystrophin characterization in BMD patients: correlation of abnormal protein with clinical phenotype. *J Neurol Sci* 1995;132:146-55.
- 16 Bönemann CG, Passos-Bucno MR, McNally EM, *et al.* Genomic screening for β -sarcoglycan gene mutations: missense mutation may cause severe limb-girdle muscular dystrophy type 2E (LGMD 2E). *Hum Mol Genet* 1996;5:1953-61.
- 17 Towbin JA. The role of cytoskeletal proteins in cardiomyopathies. *Curr Opin Cell Biol* 1998;10:131-9.
- 18 van der Kooij AJ, de Voogt WG, Barth PG, *et al.* The heart in limb girdle muscular dystrophy. *Heart* 1998;79:73-7.
- 19 Duggan DJ, Gorospe JR, Fanin M, Hoffman EP, Angelini C. Mutations in the sarcoglycan genes in patients with myopathy. *N Engl J Med* 1997;336:618-24.
- 20 Bushby KMD, Beckmann JS. The limb-girdle muscular dystrophies. Proposal for a new nomenclature. 30th and 31st ENMC International Workshops, Naarden, The Netherlands. *Neuromusc Disord* 1995;5:337-43.
- 21 Bönemann CG, Wong J, Ben Hamida C, Ben Hamida M, Hentati F, Kunkel LM. LGMD2E in Tunisia is caused by a homozygous missense mutation in β -sarcoglycan exon 3. *Neuromusc Disord* 1998;8:193-7.
- 22 Duclos F, Broux O, Bourg N, *et al.* β -sarcoglycan genomic analysis and identification of a novel missense mutation in the LGMD2E Amish isolate. *Neuromusc Disord* 1998;8:30-8.
- 23 Eymard B, Romero NB, Leturcq F, *et al.* Primary adhalinopathy (α -sarcoglycanopathy): clinical, pathologic and genetic correlation in 20 patients with autosomal recessive muscular dystrophy. *Neurology* 1997;48:1227-34.
- 24 Muntoni F, Wilson L, Marrosu G, *et al.* A mutation in the dystrophin gene selectively affecting dystrophin expression in the heart. *J Clin Invest* 1995;96:693-9.
- 25 Olson TM, Michels VV, Thibodeau SN, Tai YS, Keating MT. Actin mutations in dilated cardiomyopathy, a heritable form of heart failure. *Science* 1998;280:750-2.
- 26 Lim LE, Campbell KP. The sarcoglycan complex in limb-girdle muscular dystrophy. *Curr Opin Neurol* 1998;11:443-52.