

11 Sobel E, Lange K. Descendent graphs in pedigree analysis: applications to haplotyping, location scores, and marker statistics. *Am J Hum Genet* 1996; 58:1323-37.

12 Vincent C, Kalatzis V, Abdelhak S, Chaib H, Compain S, Helias J, Vaneecloo FM, Petit C. BOR and BO syndromes are allelic defects of *EYA1*. *Eur J Hum Genet* 1997;5:242-6.

*J Med Genet* 2000;37:623-627

## Importance of clinical evaluation and molecular testing in the branchio-oto-renal (BOR) syndrome and overlapping phenotypes

EDITOR—The branchio-oto-renal (BOR) syndrome was first reported in the last century by Heusinger, but not clinically defined until 1976 by Melnick *et al.*<sup>1</sup> The major clinical features associated with the BOR syndrome are hearing loss, branchial defects, ear pits, and renal anomalies.<sup>1</sup> Hearing loss can be conductive, sensorineural, or mixed, ranging from mild to profound deafness.<sup>2</sup> Renal abnormalities are also variable, including renal aplasia, hypoplasia, and dysplasia, as well as anomalies of the collecting system.<sup>3</sup> Branchial defects including fistulas or cysts and ear pits are often observed, and minor features such as external ear abnormalities, ear tags, and lacrimal duct aplasia are sometimes present. The BOR syndrome is inherited in an autosomal dominant manner and penetrance is high, although expressivity can be extremely variable.<sup>3-5</sup>

The BOR syndrome gene was localised to 8q following the description of a person with an inherited rearrangement, *dir ins(8)(q24.11;q13.3;q21.13)* presenting with features of both the branchio-oto (BO) syndrome and trichorhinophalangeal syndrome.<sup>6</sup> Linkage analysis confirmed that the BOR syndrome mapped to 8q13.3.<sup>7,8</sup> Further fine mapping defined the BOR region to be a 450-650 kb interval.<sup>9-12</sup> In 1997, the gene was cloned by sequencing P1/PAC clones from a contig spanning the region, yielding sequences homologous to the *Drosophila* developmental gene *eyes absent (eya)*. Point mutations and deletions were subsequently detected in the human homologue, *EYA1*, in families with the BOR syndrome.<sup>13,14</sup>

*EYA1* consists of 16 coding exons and encodes a 559 amino acid protein. There are two additional *EYA1* isoforms and all show significant homology to the *Drosophila eya* gene, as well as to the murine homologue, constituting a novel gene family.<sup>14,15</sup> The *Drosophila eya* gene is essential in the formation of the fly compound eye

and the pathway has been shown to be conserved between flies and vertebrates.<sup>16-18</sup> Preliminary results indicate that *EYA1* is highly expressed in human fetal kidney and brain, as well as in adult heart and skeletal muscle. The murine homologue *Eya1* was found to be strongly expressed in the mouse ear and skeletal muscle, but not shown in mouse kidney or branchial tissues.<sup>15</sup> The product of *EYA1* contains a highly conserved region called the *eyes absent* homologous region (*eyaHR*). This is a 271 amino acid carboxy-terminal region encoded within exons 9-16 and is the site of most mutations identified to date.<sup>11,12,14,15</sup>

In this study, mutation detection of the *EYA1* gene was performed on a collection of cases with a probable diagnosis of the BOR syndrome and clinically overlapping disorders. We aimed to assess whether cases with overlapping phenotypes are allelic to the BOR syndrome at a molecular level.

The cases for the study were ascertained from several sources, with 16 cases (familial and sporadic) recruited for clinical and mapping studies before gene identification.<sup>4,13</sup> The remaining 16 cases were identified subsequently through the clinical genetics and nephrourology departments at Great Ormond Street Hospital, London, UK.

Thirty two cases were studied in total, of which 18 (11 familial, seven sporadic) exhibited at least three of the following major features: hearing loss, branchial defects, ear pits, and renal anomalies. These cases were classified as having classical BOR syndrome. Twelve cases (mostly sporadic) exhibited one or two major features, often associated with a minor feature (most commonly external ear anomalies). These were designated as having an atypical form of the disease. Two cases of otofaciocervical (OFC) syndrome were also included. This is an autosomal dominant condition in which there is hearing loss, ear pits, cervical fistulae, hypoplasia of the cervical musculature (sloping shoulders), facial abnormalities, short stature, and mild developmental delay. There is considerable phenotypic overlap between the OFC syndrome and the BOR syndrome.<sup>19</sup> A summary of the clinical features of the cases are given in tables 1 and 2.

Exons 1-3 and 5-16 were amplified from genomic DNA of affected subjects using published intronic primers.<sup>14</sup> Exon 4 was amplified using primers EYA1-4F-gtgatgtggttgaatcggt and EYA1-4R1-

Table 1 Mutations identified in *EYA1* in this study

BOR case	Type	Exon	Nucleotide change	Effect	Phenotype
<i>Nonsense</i>					
Subject 1	Sporadic	8	790 C→T	R265X	D, E, R, C
Family 7	Familial	8	790 C→T	R265X	D, B, E
Subject 2	Sporadic	8	732 C→A	Y244X	D, B, E, L
<i>Missense</i>					
Family 8	Familial	16	1680 A→C	X559Y	D, B, E, R, C, F
Subject 11	Sporadic	16	1649 T→C	L549P	D, B, E, R, F
<i>Frameshifts</i>					
Family 3*	Familial	13	1372 T→AGAGAC	1bp del/6bp insertion	D, B, E
Subject 6	Sporadic	5	387 ins T	1bp insertion	D, B, R
<i>Splice site</i>					
Family 4	Familial	9	868-1 G→A	Loss of acceptor site	D, B, E, R
Family 10	Familial	10	1041+1 G→T	Loss of donor site	D, B, E, R
Subject 9*	Sporadic	14	1498+2 T→G	Loss of donor site	D, B, E, R, C
Subject 5	Sporadic	11	1042-13 23bp inv	Loss of acceptor site	D, E, R, C, H

D = deafness, B = branchial defects, E = ear pits, R = renal anomalies, C = external ear abnormalities, F = facial asymmetry, L = lacrimal duct obstruction, H = sloping shoulders.

Nomenclature as previously described.<sup>14</sup>

\*Denotes previously published mutations.<sup>13</sup>

Table 2 Clinical details of cases with no mutation identified

BOR case	Type	Phenotype
<i>Classical BOR</i>		
Family 15	Familial	D, B, E, R
Family 21	Familial	D, B, E, R
Family 23	Familial	D, B, E, R
Family 25	Familial	D, B, E, R
Family 26	Familial	D, B, E, C, L
Family 27	Familial	D, B, E, R
<i>Atypical BOR</i>		
Subject 13	Sporadic	B
Subject 14	Sporadic	D, E, R, K
Subject 16	Sporadic	D, R
Subject 17	Sporadic	D, R, C, T, S
Subject 18	Sporadic	D, R
Subject 19	Sporadic	B, E, P, M
Subject 20	Sporadic	E, C, V, H
Family 22	Familial	D, E, C
Subject 29	Sporadic	D, R, C
Subject 30	Sporadic	D, R, C
Subject 31	Sporadic	D, R, C, S, U, A, I
Subject 32	Sporadic	D, R, C
<i>OFC</i>		
Subject 24	Sporadic	D, E, R, C, S, H, V, I
Subject 28	Sporadic	D, B, E, G, Y, H, V

D = deafness, B = branchial defects, E = ear pits, R = renal anomalies, C = external ear abnormalities, F = facial asymmetry, L = lacrimal duct obstruction, K = cataracts, T = skin tags, S = short neck, P = cleft palate, M = micrognathia, V = developmental delay, H = sloping shoulders, U = absent uterus, A = heart abnormalities, I = short stature, G = gustatory lacrimation, Y = dilatation of collecting system.

agaaggtgacaacacgttctaatt. All PCRs were carried out under standard conditions. In familial cases, one affected member was initially analysed and then confirmed in other family members where possible.

The PCR products from exons 1'-15 were denatured and run at 15 W overnight at 4°C on 1 × MDE gels (FMC Bio-Products) using 0.5 × TBE, with and without 10% glycerol. The gels were then silver stained as previously described.<sup>20</sup> Owing to its large size, exon 16 was digested with *DdeI* and run as above. Samples with SSCP mobility shifts were then sequenced using an ABI 377 DNA sequencer, using the rhodamine terminator cycle sequencing kit (PE Applied Biosystems). Subjects without SSCP shifts were then sequenced for all exons listed above. Exons 11/12 and 13/14 were sequenced together as the introns between them are 100 bp. Mutant alleles in family 3 and subject 5 were sequenced by excising small fragments of the resolved bands from the SSCP gel, adding straight to a PCR premix, and amplifying.

Of the thirty two cases analysed, twenty nine underwent SSCP analysis, yielding 10 mobility shifts that were not present in 50 normal controls. The remaining three cases who did not undergo SSCP analysis were sequenced for the entire gene. All SSCP shifts were then directly sequenced and subjects without mobility shifts were sequenced for the entire coding region of the gene. An eleventh mutation was identified by sequencing in family 10, which was not detected by SSCP. The mutations are listed in table 1. All mutations were confirmed using either a naturally occurring restriction enzyme site or by designing an artificially created restriction site (ACRS). This involved the use of a mismatched primer to introduce a restriction enzyme site in the presence of the mutation. The primers and enzymes used are shown in table 3.

Subject 1 and family 7, who are apparently unrelated, carried the same mutation, 790C→T, in exon 8. This

results in the creation of a stop codon, which is predicted to cause premature truncation of the protein. The parents of subject 1 were shown not to carry the mutation and non-paternity was excluded. Only one other relative was available for testing in family 7. Family 7 consisted of six affected subjects with deafness, cervical fistulas, and ear pits, but DNA was only available from one relative who was clinically unaffected and who was shown not to carry the mutation. A summary of the sequence and enzyme data is shown in fig 1.

Another nonsense mutation in exon 8, 732C→A, resulted in the substitution of a tyrosine residue for a termination codon. The parents were clinically unaffected, but unavailable for testing.

A missense mutation in exon 16, 1680A→C, in family 8 is predicted to destroy the final stop codon of the gene. The change creates a tyrosine residue, resulting in the addition of five extra amino acids at the end of the protein.

Another missense mutation in exon 16 was identified in subject 11. The change, 1649 T→C, results in a leucine to proline amino acid substitution at position 549 of the gene. No other mutations were found in subject 11 when the remaining coding exons were sequenced, and the change was not present in 85 normal controls tested. Her parents have yet to be tested.

Family 3 was previously reported as having a complex 5 bp substitution/insertion (1372T→AGAGC) in exon 13.<sup>13</sup> Resequencing of the mutant allele has shown the insertion to be 6 bp (AGAGAC). This combined with the loss of a thymine nucleotide at the same position resulted in an overall gain of 5 bp. This change is predicted to result in a frameshift leading to premature truncation of the protein. All three affected family members were heterozygous for the mutation, while those unaffected were not. Subject 6 was also heterozygous for a frameshift mutation which was the result of an insertion of a T at position 387 in exon 5.

Family 4, family 10, and subject 9 were heterozygous for mutations which are predicted to cause aberrant splicing in exons 9, 14, and 10 respectively. All affect conserved bases and would be predicted to be disease causing. Computer analysis involving a neural network program was used to analyse DNA sequences containing the mutated splice sites and surrounding sequence (50-100 bp). This predicted that the changes would result in the destruction of the consensus splice site and create no other donor/acceptor sites.<sup>21</sup>

A fourth splice site mutation was detected in subject 5, a 23 bp inversion starting at position 1042-13, across the intron/exon boundary of exon 11. This is predicted completely to disrupt the consensus acceptor site of exon 11 and was not present in the unaffected parents; non-paternity was excluded. This is shown in fig 2.

There have been seven exonic *EYA1* polymorphisms published to date. Sequencing of our cohort has confirmed the existence of published polymorphisms 510A→C, 1179C→T, 1233T→C, and 1656T→C.<sup>14</sup> We have identified a new polymorphism in exon 7, 714A→G. This sequence variant occurred in 4/32 of the branchial arch syndrome cases and in 3/20 normal controls.

Comprehensive mutation detection of our cohort has identified 11 mutations from 18 cases with classical BOR syndrome. These 11 cases exhibited at least three of the

Table 3 Primer sequences and enzyme information for ACRS tests

BOR case	ACRS primer	2nd primer	Enzyme
Subject 1/family 7	ccattaaagattcagattctgatcgataacgt	cactgctgtttacgtagcagg	<i>AcII</i>
Family 4	aagacacattgattctgtctctctttta	tgaataacagcttctcagcc	<i>DraI</i>
Family 8	gcaccatgcttggactggagtagccgga	gtggcagacacataacgctg	<i>KpnI</i>
Family 10	ggcagacacatttttttaagacttagac	accaacaaactcgtctcac	<i>AflII</i>

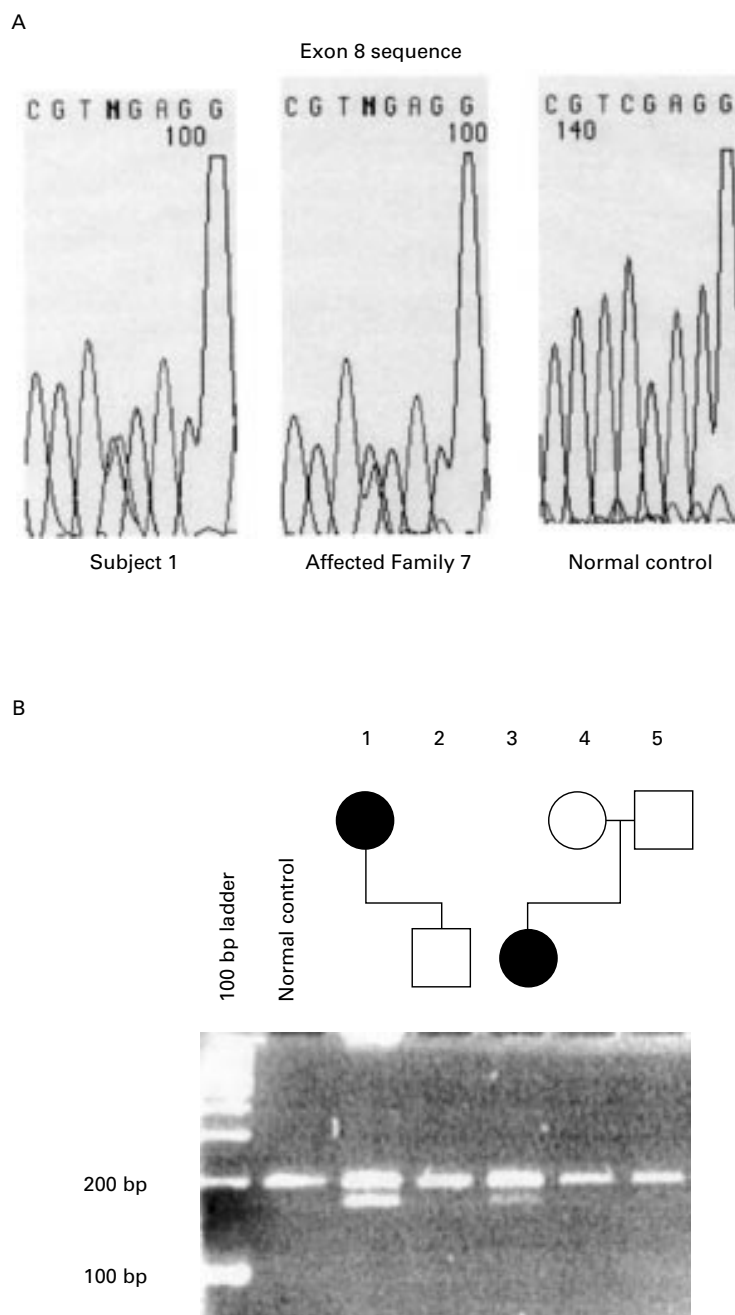


Figure 1 (A) Sequence data showing 790C→T mutation in subject 1 and family 7. (B) Restriction enzyme test confirming the mutation in subject 1 and family 7. The mutation results in a gain of an *AclI* site. Lane 1 is the affected mother in family 7, lane 2 is her unaffected son, lane 3 is subject 1, and lanes 4 and 5 are her unaffected parents.

following major clinical features: deafness, branchial defects, ear pits, and renal anomalies, and gives a detection rate of 61% which is higher than in previous studies.<sup>13 14 22 23</sup> There were no apparent clinical differences in phenotypic features between the 11 cases with mutations in *EYA1* and the seven classical cases without. It is possible that these seven cases may contain major rearrangements of the gene or mutations in the 3' untranslated or promoter region.

No mutations were detected in any subjects with atypical BOR syndrome or the OFC syndrome. Atypical BOR syndrome cases exhibited only one or two major features of the disease often associated with minor features, most commonly external ear abnormalities. Careful clinical evaluation is therefore essential before determining whether it is appropriate to embark upon mutation screening of the *EYA1* gene.

However, while sporadic cases of BOR syndrome may not fulfil these strict clinical diagnostic criteria, if similar affected members within large families have between them at least three major features, mutation screening would be deemed appropriate. It is therefore possible that such strict clinical diagnostic criteria would result in failure to screen sporadic cases presenting with one or two major features. However, we found no mutations in 13 such sporadic cases studied.

When the results of our mutation detection are combined with published data, the vast majority of mutations occur in exons within the *eyaHR*, that is, exons 9-16.<sup>13 14 22 23</sup> This region shows 69% identity with the *Drosophila eya* protein and appears essential for normal function of the gene product,<sup>13</sup> as almost all mutations are clustered in exons within or adjacent to it. Exons 8, 13, 14,





- 11 Gu JZ, Wagner MJ, Hann EA, Wells DE. Detection of a megabase deletion in a patient with branchio-oto-renal (BOR) syndrome and tricho-rhino-phalangeal syndrome (TRPS): implications for mapping and cloning the BOR gene. *Genomics* 1996;31:201-6.
- 12 Kalatzis V, Abdelhak S, Compain S, Vincent C, Petit C. Characterisation of a translocation-associated deletion defines the candidate region for the gene responsible for branchio-oto-renal syndrome. *Genomics* 1996;34:422-5.
- 13 Abdelhak S, Kalatzis V, Heilig R, Compain S, Samson D, Vincent C, Weil D, Cruaud C, Sahly I, Leibovici M, Bitner-Glindzic M, Francis M, Lacombe D, Vigneron J, Charachon R, Boven K, Bedbeder P, Van Regemorter N, Weissenbach J, Petit C. A human homologue of the drosophila eyes absent gene underlies branchio-oto-renal (BOR) syndrome and identifies a novel gene family. *Nat Genet* 1997;15:157-64.
- 14 Abdelhak S, Kalatzis V, Heilig R, Compain S, Samson D, Vincent C, Levi-Acobas F, Cruaud C, Le Merrer M, Mathieu M, König R, Vigneron J, Weissenbach J, Petit C, Weil D. Clustering of mutations responsible for branchio-oto-renal (BOR) syndrome in the eyes absent homologous region (eyaHR) of EYA1. *Hum Mol Genet* 1997;6:2247-55.
- 15 Xu PX, Woo I, Her H, Beier DR, Maas RL. Mouse Eya homologues of the Drosophila eyes absent gene require Pax6 for expression in lens and nasal placode. *Development* 1997;124:219-31.
- 16 Bonini NM, Leiserson WM, Benzer S. The eyes absent gene: genetic control of cell survival and differentiation in the developing drosophila eye. *Cell* 1993;72:379-95.
- 17 Pignoni F, Birong H, Kenton ZH, Xiao J, Garrity PA, Zipursky SL. The eye-specification proteins So and Eya form a complex and regulate multiple steps in drosophila eye development. *Cell* 1997;91:881-91.
- 18 Bonini NM, Bui QT, Gray-Board GL, Warrick JM. The *Drosophila* eyes absent gene directs ectopic eye formation in a pathway conserved between flies and vertebrates. *Development* 1997;124:4819-26.
- 19 Allanson J. Genetic hearing loss associated with external ear abnormalities. In: Gorlin RJ, Toriello HV, Cohen MM, eds. *Hereditary hearing loss and its syndromes*. 9th ed. Oxford: Oxford University Press, 1995.
- 20 Tyson J, Ellis D, Fairbrother U, King RHM, Muntoni F. Hereditary demyelinating neuropathy of infancy. A genetically complex syndrome. *Brain* 1997;120:47-63.
- 21 Brunak S, Engelbrecht J, Knudsen S. Prediction of human mRNA donor and acceptor sites from the DNA sequence. *J Mol Biol* 1991;220:49-65.
- 22 Kumar S, Deffenbacher K, Cremers CWRJ, Van Camp G, Kimberling WJ. Branchio-oto-renal syndrome: identification of novel mutations, molecular characterisation, mutation distribution, and prospects for genetic testing. *Genet Testing* 1997;8:1:243-51.
- 23 Kumar S, Kimberling WJ, Weston M, Shafer BG, Anne Berg M, Marres HAM, Cremers CWRJ. Identification of three novel mutations in human EYA1 protein associates with branchio-oto-renal syndrome. *Hum Mutat* 1998;11:443-9.
- 24 Vincent C, Kalatzis V, Abdelhak S, Chaib H, Compain S, Helias J, Vaneecloo FM. BOR and BO syndromes are allelic defects of EYA1. *Eur J Hum Genet* 1997;5:242-6.
- 25 Gorlin RJ, Toriello HV, Cohen MM. *Hereditary hearing loss and its syndromes*. 9th ed. Oxford: Oxford University Press, 1995.
- 26 Fraser GR. *The causes of deafness in childhood*. Baltimore: Johns Hopkins University Press, 1976.
- 27 Kumar S, Kimberling WJ, Kenyon JB, Smith RJH, Marres HAM, Cremers CWRJ. Autosomal dominant branchio-otic (BO) syndrome is not allelic to the Branchio-oto-renal (BOR) syndrome at 8q13. *Am J Med Genet* 1998;76:395-401.

*J Med Genet* 2000;37:627-629

## Equal expression of type X collagen mRNA from mutant and wild type *COL10A1* alleles in growth plate cartilage from a patient with metaphyseal chondrodysplasia type Schmid

EDITOR—Type X collagen is a short chain collagen consisting of three  $\alpha 1(X)$  chains encoded by the *COL10A1* gene. The  $\alpha 1(X)$  chains are composed of three structurally distinct domains, an amino-terminal globular domain (NC2), a triple helical region, and a carboxyl-terminal globular domain (NC1).<sup>1</sup> Type X collagen is predominantly synthesised by the hypertrophic chondrocytes of the vertebrate growth plate but its precise function during development remains unclear.<sup>2</sup> To date, 27 naturally occurring mutations within specific regions of *COL10A1* have been reported to cause the autosomal dominant human disorder metaphyseal chondrodysplasia type Schmid (MCDS), which is characterised by short stature, a waddling gait, and coxa vara.<sup>2</sup> Of these 27 *COL10A1* mutations, two occur within a single codon and cause single amino acid substitutions at the putative signal sequence cleavage site within NC2,<sup>3</sup> 12 mutations cause amino acid substitutions that map to two distinct regions of the predicted structure of the NC1 domain,<sup>4</sup> and the remaining mutations introduce stop codons or frameshifts plus premature stop codons that affect, at most, 40% of the carboxyl-terminal region of the NC1 domain. No mutations causing MCDS have yet been found altering the collagenous region of type X collagen, and in two unrelated families with MCDS we have not been able to find mutations in the entire coding region of *COL10A1* (unpublished data). The probability of all 27 MCDS mutations clustering within the NC1 and NC2 encoding portions of the gene by chance alone is approximately  $1$  in  $7.6 \times 10^8$  and for mutations predicted to truncate the  $\alpha 1(X)$  chains is approximately  $1$  in  $10^6$ . This restricted distribution of the *COL10A1* mutations causing MCDS strongly suggests that

these mutations alter specific function(s) of the encoded  $\alpha 1(X)$  chains.

The molecular mechanism(s) by which mutations in *COL10A1* cause MCDS remain under debate.<sup>5</sup> In vitro association of MCDS mutant and normal  $\alpha 1(X)$  chains has been reported, suggesting that dominant interference may be the underlying molecular mechanism.<sup>4-6</sup> These in vitro observations have yet to be proven in vivo primarily because of the difficulty of obtaining sufficient growth plate tissue from patients with MCDS for studies of type X collagen biosynthesis. In contrast to the in vitro data, in the only previously reported investigation of the biosynthesis of type X collagen in growth plate cartilage from a patient with MCDS, it has been shown that mRNA representing the mutant allele (which contained a single base pair substitution that introduced a premature termination codon in the NC1 encoding domain) was not present in the growth plate cartilage biopsy.<sup>7</sup> This finding was explained in that mRNA encoding premature termination codons has been shown to be rapidly degraded by the proof reading machinery of the cell in a number of inherited diseases.<sup>8</sup> This in vivo data implied that haploinsufficiency is the underlying mutation mechanism causing the MCDS phenotype in this patient and raised the question as to whether other mutations in the *COL10A1* NC1 encoding domain may alter mRNA stability and thereby explain the clustering of the mutations in that domain.

To investigate the mechanism of MCDS pathology fully, there is a clear necessity for direct analysis of the hypertrophic chondrocytes and growth plate cartilage in other cases of MCDS. Although samples of growth plate cartilage from MCDS patients are extremely rare, we were fortunate to acquire such tissue from an affected subject who was heterozygous for a single base pair mutation, T1894C, predicted to cause a single amino acid substitution (S600P) in the NC1 domain of type X collagen.<sup>5</sup> The patient had a phenotype entirely consistent with MCDS. Length at birth was normal (50 cm) and in the first year of life, the tentative diagnosis was hip dysplasia. In the second year, progressive coxa vara became apparent and at the age of 2½ years the definite diagnosis of MCDS was made. Clinical symptoms included short limbed short stature (80 cm), bowed legs, and waddling gait. Radiological findings consisted of coxa vara and metaphyseal changes including