

# A novel mutation in the thiamine responsive megaloblastic anaemia gene *SLC19A2* in a patient with deficiency of respiratory chain complex I

Curt Scharfe, Michael Hauschild, Thomas Klopstock, Antoon J M Janssen, Peter H Heidemann, Thomas Meitinger, Michaela Jaksch

## Abstract

**The thiamine transporter gene *SLC19A2* was recently found to be mutated in thiamine responsive megaloblastic anaemia with diabetes and deafness (TRMA, Rogers syndrome), an early onset autosomal recessive disorder. We now report a novel G1074A transition mutation in exon 4 of the *SLC19A2* gene, predicting a Trp358 to ter change, in a girl with consanguineous parents. In addition to the typical triad of Rogers syndrome, the girl presented with short stature, hepatosplenomegaly, retinal degeneration, and a brain MRI lesion. Both muscle and skin biopsies were obtained before high dose thiamine supplementation. While no mitochondrial abnormalities were seen on morphological examination of muscle, biochemical analysis showed a severe deficiency of pyruvate dehydrogenase and complex I of the respiratory chain. In the patient's fibroblasts, the supplementation with high doses of thiamine resulted in restoration of complex I activity. In conclusion, we provide evidence that thiamine deficiency affects complex I activity. The clinical features of TRMA, resembling in part those found in typical mitochondrial disorders with complex I deficiency, may be caused by a secondary defect in mitochondrial energy production.**

(*J Med Genet* 2000;37:669–673)

Keywords: TRMA syndrome; *SLC19A2* gene; complex I deficiency

The first description of thiamine responsive megaloblastic anaemia syndrome (TRMA, OMIM 249270) is attributed to Rogers *et al*<sup>1</sup> in 1969, who reported an 11 year old girl with megaloblastic anaemia, diabetes mellitus, and sensorineural deafness. Further reports on TRMA described congenital heart disease, arrhythmias, abnormalities of the retina and optic nerve, aminoaciduria, situs inversus, and stroke-like episodes in addition to the characteristic triad.<sup>2–7</sup> Thiamine treatment results in improvement of haematological and endocrine function, while neurological symptoms do not respond as well. Recently, the TRMA disease locus was localised to a 1.4 cM region on chromosome 1q23.3.<sup>5–8</sup> Three studies identified loss of function mutations in the TRMA causing gene *SLC19A2* in affected subjects in a

total of nine families.<sup>9–11</sup> *SLC19A2* encodes a putative transmembrane protein of 497 amino acids, with homology to members of the solute carrier family (fig 1). Functional characterisation indicates that this protein is a high affinity saturable transporter of thiamine.<sup>12–16</sup> Intracellular thiamine deficiency in TRMA leads to decreased activity of enzymes dependent on thiamine pyrophosphate (TPP), the active form of thiamine: the pentose phosphate shunt enzyme transketolase (TK) and three mitochondrial enzyme complexes, the pyruvate dehydrogenase complex (PDHC), alpha-ketoglutarate dehydrogenase (KGDH), and branched chain ketoacid dehydrogenase (BCKD).<sup>15–17</sup> Here we report a patient with TRMA carrying a novel homozygous stop mutation in the *SLC19A2* gene, who presented with additional clinical features compared to those previously described and a severe complex I deficiency in addition to PDHC deficiency.

## Patient and methods

### CASE REPORT

The 14 year old girl was born to first degree cousins of Turkish descent (fig 2). The parents and three older brothers are healthy. After an uneventful pregnancy she developed macrocytic anaemia and thrombocytopenia at 5 months. The megaloblastic anaemia was confirmed by bone marrow biopsy showing ringed sideroblasts up to 50%. She was found to be deaf at 18 months and diabetes mellitus presented at the age of 3 years. Additional findings were retinal degeneration, short stature (–2.6 standard deviation score, SDS), incomplete right bundle branch block of the heart, mild hepatomegaly, and a homogeneous enlargement of the spleen (12.3 cm in length). Brain MRI at 12 years showed a lesion of about 2 cm (area of left middle cerebral artery in the parietal lobe) but without any neurological correlates. Lactate levels were increased in serum (3.55 mmol/l, reference range <1.8 mmol/l) and in cerebrospinal fluid (2.3 mmol/l, reference range <1.8 mmol/l). The lactate/pyruvate ratio was increased twofold. Thiamine levels in plasma were in the normal range, whereas intracellular TPP (20.1 ng/ml, reference range 30–90 ng/ml) and TPP synthase activity of erythrocytes (7.5 nmol/h/g Hb, reference range 10–20 nmol/h/g Hb) were reduced. Automatic scanning of blood cells showed a mean MCV of 96.1 fl (reference range 80–94 fl), a low Hb concentration of 89

Department of Medical Genetics, Klinikum Innenstadt, Ludwig-Maximilians-University, Munich, Germany  
C Scharfe  
T Meitinger

I Klinik für Kinder und Jugendliche, Augsburg, Germany  
M Hauschild  
P H Heidemann

Department of Neurology, Klinikum Grosshadern, Ludwig-Maximilians-University, Munich, Germany  
T Klopstock

Department of Paediatrics, University Hospital, Nijmegen, The Netherlands  
A J M Janssen

Metabolic Disease Centre Munich-Schwabing, Molecular Diagnostics and Mitochondrial Genetics and Institute of Diabetes Research, Kölner Platz 1, 80804 Munich, Germany  
M Jaksch

Correspondence to: Dr Jaksch, Michaela.Jaksch@lrz.uni-muenchen.de

Revised version received 16 April 2000  
Accepted for publication 3 May 2000

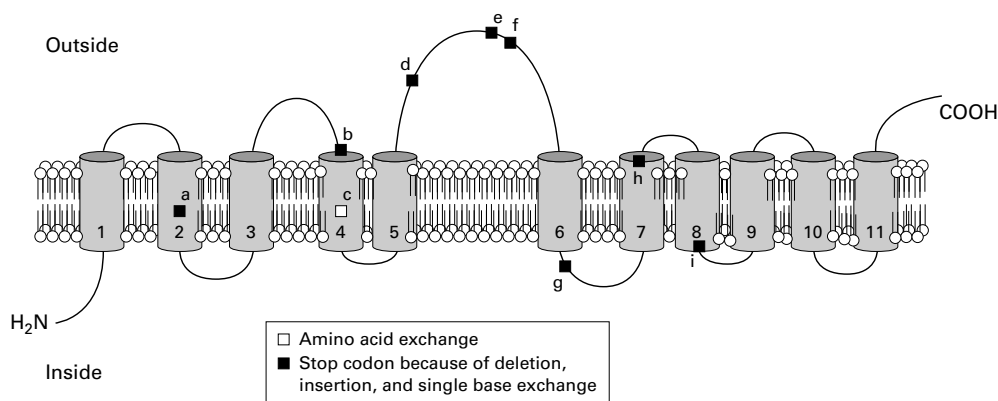


Figure 1 Schematic representation of the predicted topology of the *SLC19A2* protein across the cell membrane and the reported mutations. The amino acid sequence of *SLC19A2* was analysed for hydrophobicity with the prediction program SOSUI (<http://azusa.proteome.bio.tuat.ac.jp/sosui/submit.html>). Transmembrane domains 1 and 6 were not found from PSORT (<http://psort.nibb.ac.jp:8800/>). (a) *ins81/ter81*, (b) *del242fs/ter259*, (c) *gly172 to asp*, (d) *del144fs/ter229*, (e) *trp250 to ter*, (f) *arg162 to ter*, (g) *del295fs/ter313*, (h) *trp358 to ter*, (i) *del383fs/ter384*.

g/l (reference range 120-160 g/l), and a low reticulocyte index of 2.4 per 1000. A manual differential showed anisocytosis with micro- and macrocytes. Morphological and ultrastructural examination of skeletal muscle showed mild lipidosis and increased subsarcolemmal NADH reductase activity but no definite mitochondrial abnormalities. After one week of high dose thiamine supplementation ( $2 \times 100$  mg/day thiamine-HCL), reticulocytosis was observed (114 per 1000) followed by an almost complete resolution of anaemia within four weeks (2.6 reticulocytes per 1000, Hb 11.3 g/l, MCV 100.1 fl). TPP and TPP synthase activity were not verified after treatment. Insulin dosage could be reduced in the following six months from 1.8 to 0.7 U/kg/day. The serum lactate level dropped to 1.36 mmol/l. Retinal degeneration, deafness, and splenomegaly remained unchanged.

#### MUTATION DETECTION

DNA was extracted from skeletal muscle, skin fibroblasts, and leucocytes according to standard purification protocols (Qiagen, Hilden,

Germany). Polymerase chain reaction (PCR), Southern blot analysis, and single strand conformational polymorphism (SSCP) analysis for exclusion of mtDNA mutations were performed as previously described.<sup>18</sup> The entire *SLC19A2* coding sequence (GenBank AF135488), consisting of six exons, was amplified in the index patient with the forward and backward intronic primers as previously described.<sup>9, 10</sup> Cycle sequencing of gel purified fragments was performed using the Perkin-Elmer ABI PRISM Big Dye Termination kit. Sequences were determined with a Perkin-Elmer Applied Biosystems 377 automated sequencer. Restriction fragment length polymorphism analysis (RFLP) was done using exon 4 primers as previously described and *BclI* as restriction enzyme. Resulting fragments were separated on a 3% agarose gel and analysed after ethidium bromide staining.

#### SKIN FIBROBLAST CELL CULTURE AND THIAMINE SUPPLEMENTATION

Fibroblasts from skin were grown in high glucose Dulbecco's modified Eagle's medium

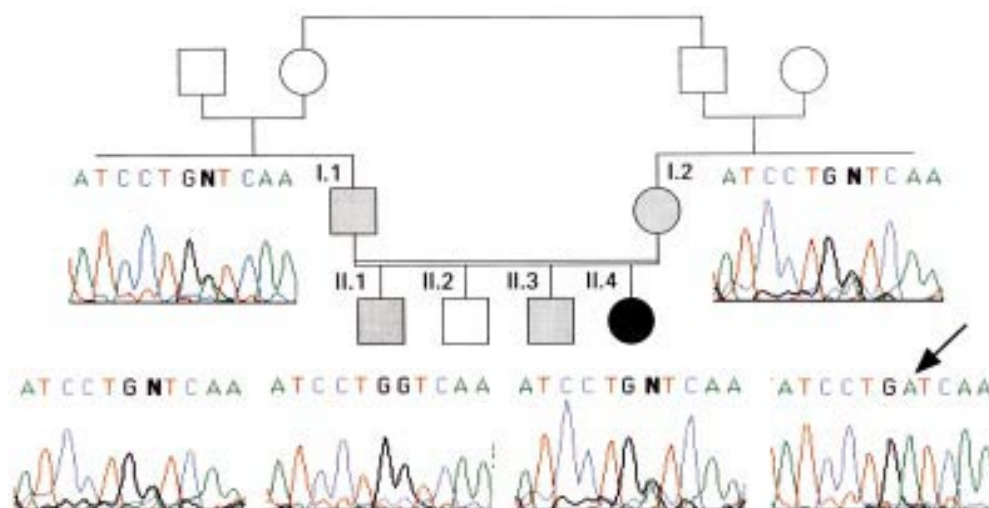


Figure 2 Pedigree of the TRMA family. The filled circle indicates the affected child (II.4), the double line the consanguineous marriage. DNA sequence electropherograms show homozygotes for the nonsense mutation (II.4), heterozygotes for the mutant allele (I.1, I.2, II.1, and II.3), and homozygotes for the normal allele (II.2). The "N" represents one allele with A and one with G (I.1, I.2, II.1, and II.3).

Table 1 Biochemical analysis of respiratory chain complexes I, II+III, and IV, and PDHC in muscle tissue

	Muscle activity (mU/U CS)	
	Patient	Control range
PDHC	9.3	20–52
NADH:Q1 oxidoreductase (CI)	60	170–560
Succinate:cyt C oxidoreductase (CII+III)	70	80–450
Cytochrome C oxidase (CIV)	1370	900–4700
Citrate synthase	75.0	45–105*

\*Citrate synthase (CS) in U/g NCP.

(DMEM, GIBCO BRL), supplemented with 10% fetal bovine serum (FBS, GIBCO BRL), with and without 3  $\mu\text{mol/l}$  thiamine as previously described<sup>15</sup> and incubated for at least 14 days.

#### BIOCHEMISTRY

Activities of PDHC, complexes I (rotenone sensitive NADH ubiquinone oxidoreductase), II + III (succinate cytochrome-c oxidoreductase), and IV (cytochrome-c oxidase) of the mitochondrial respiratory chain were determined spectrophotometrically in postnuclear supernatants of fresh frozen muscle biopsy specimens as described.<sup>19</sup> Complex I was measured by addition of 0.2 mmol/l NADH. Activities were related to the mitochondrial marker enzyme citrate synthase.

#### Results

##### MUTATION DETECTION

We performed genotyping of the affected girl, her healthy sibs, and their parents. Sequences obtained from the family members were compared with the *SLC19A2* sequence and with normal control chromosomes. Analysis of the complete *SLC19A2* gene in the index patient showed a novel homozygous G to A termination mutation at position 1074 in exon 4, predicting a premature truncation of the protein at codon 358. The parents (I.1 and I.2) and two brothers (II.1 and II.3) were heterozygous for the mutation and one brother (II.2) was homozygous for the wild type (fig 2). As the G1074A mutation creates a *BclI* restriction site, we confirmed the sequencing results in all family members by RFLP analysis using exon 4 primers (data not shown). Frequent mtDNA mutations associated with mitochondrial encephalomyopathies were excluded by standard RFLP SSCP analysis. No major mitochondrial rearrangements were found by Southern blot analysis.

##### BIOCHEMISTRY

Skeletal muscle and skin fibroblast biochemical analyses were performed before thiamine treatment. Respiratory chain activities showed marked deficiency of complex I with a residual activity of 35% in skeletal muscle. PDHC activity was reduced to 50% of the lower reference range in muscle tissue (table 1). Complexes II and III showed a minor reduction of about 10% only, and complex IV had normal activity. In order to investigate whether the decreased complex I activity was influenced by the thiamine deficiency, the patient's fibro-

blasts were cultured with and without thiamine. We found that supplementation with a high concentration of thiamine (3  $\mu\text{mol/l}$ ) resulted in a 2.5 fold increase in complex I activity compared to fibroblasts cultured without thiamine. Similarly, PDHC activity was within the normal range after thiamine supplementation.

#### Discussion

We have identified a novel loss of function mutation in the high affinity thiamine transporter gene *SLC19A2* in a child with TRMA. Biochemical measurement of muscle and fibroblasts before thiamine supplementation showed not only the expected deficiency of PDHC, but also a marked deficiency of complex I of the mitochondrial respiratory chain, which normalised after thiamine supplementation. Clinically, anaemia and diabetes improved within two weeks after thiamine treatment.

Thiamine is an ubiquitously occurring cofactor of four important enzymes (TK, PDHC, KGDH, and BCKD) of carbohydrate metabolism. Studies on human intestinal and erythrocyte thiamine absorption suggest that two uptake pathways exist, transport by a high affinity, low capacity carrier and passive intake by a low affinity/high capacity system.<sup>12–15</sup> Functional characterisation of the *SLC19A2* protein indicates that it is a high affinity, saturable transporter showing an amino acid identity of 55% with the reduced folate transporter RFC1 and the major part of thiamine is presumably absorbed via this pathway.<sup>15,16</sup> Labelling studies using <sup>3</sup>H-thiamine indicate that TRMA fibroblasts take up only 5–10% of wild type amounts.<sup>14</sup>

Correspondingly, thiamine responsive diseases may be classified as acquired diseases because of thiamine deficiency, inherited diseases because of defects of thiamine transport, and inherited diseases because of defects of thiamine dependent enzymes (table 2). Beriberi (Indonesian for sheep, because of the characteristic gait of the patients) is a sensorimotor neuropathy still endemic in Asia resulting from the low thiamine content of polished rice.<sup>20</sup> The most common cause for thiamine deficiency in Europe and North America is chronic alcoholism with malnutrition, less common are anorexia nervosa, parenteral nutrition, or chronic intestinal diseases. While alcoholic neuropathy is caused by the deficiency of several vitamins, Wernicke's encephalopathy and Korsakow's syndrome are mainly the result of thiamine deficiency alone, thus responding well to thiamine supplementation. Interestingly, there are also genetic diseases which involve thiamine metabolism and respond to thiamine therapy. Leigh disease (subacute necrotising encephalomyelopathy) resembles Wernicke's encephalopathy clinically, radiologically, and pathologically. The pathobiochemical link to thiamine metabolism is that about 15–20% of Leigh cases are caused by PDHC deficiency leading to decreased mitochondrial energy production. There may be several other clinical presentations of PDHC

Table 2 Thiamine responsive diseases

	Pathogenesis	Neurological symptoms	Other symptoms
<i>Acquired diseases resulting from thiamine deficiency</i>			
Beriberi	Endemic in Asia, owing to the low thiamine content of polished rice	Sensorimotor neuropathy, hypacusis, optic neuritis, cranial nerve lesions	Hoarseness, incontinence, cardiovascular decompensation
Neuropathy	Chronic alcoholism with malnutrition, anorexia nervosa, parenteral nutrition, intestinal diseases	Sensorimotor neuropathy	
Wernicke's encephalopathy	Chronic alcoholism with malnutrition, anorexia nervosa, parenteral nutrition, intestinal diseases	Eye muscle and gaze paresis, nystagmus, pupillary dysfunction, vegetative dysregulation, seizures, confusion, apathy, coma	
Korsakow's syndrome	Chronic alcoholism with malnutrition, anorexia nervosa, parenteral nutrition, intestinal diseases	Loss of short term and long term memory	
<i>Inherited diseases resulting from defects of thiamine transport</i>			
TRMA	Autosomal recessive; mutations in the thiamine transporter gene	Megaloblastic anaemia, diabetes and deafness, abnormalities of the retina and the optic nerve, stroke-like episodes	Congenital heart disease, arrhythmias, aminoaciduria, situs inversus
<i>Inherited diseases resulting from defects of thiamine dependent enzymes</i>			
Leigh syndrome (subgroup)	Mutations in <i>PDHC</i> genes	Ophthalmoplegia, nystagmus, ataxia, dystonia, optic atrophy, seizures, myoclonus, neuropathy, psychomotor retardation	Failure to thrive, respiratory insufficiency
Maple syrup urine disease (subgroup)	Mutations in <i>BCKD</i> genes	Acute episodes with vomiting, lethargy or coma, seizures, mental and physical retardation	Maple syrup urine odour
KGDH deficiency	Mutations in <i>KGDH</i> genes	Hypotonia and neurological deterioration, death in childhood	Metabolic acidosis, hyperlactataemia
Predisposition to Wernicke's encephalopathy	Mutations in <i>TK</i> genes		

PDHC = pyruvate dehydrogenase complex.

BCKD = branched chain alpha ketoacid dehydrogenase.

KGDH = ketoglutarate dehydrogenase.

TK = transketolase.

deficiency as well.<sup>21</sup> Mutations in BCKD are associated with a thiamine responsive variant of maple syrup urine disease (MUSD),<sup>22</sup> while mutations in the tricarboxylic acid cycle enzyme KGDH lead to an early fatal neurometabolic disease, KGDH deficiency.<sup>23</sup> TK mutations, finally, may cause a genetic predisposition to the development of Wernicke's and Korsakow's syndrome.<sup>24</sup>

In TRMA, congenital heart disease, arrhythmias, abnormalities of the retina and the optic nerve, aminoaciduria, situs inversus, and stroke-like episodes have been described in single cases in addition to megaloblastic anaemia, diabetes, and deafness. The patient presented here suffers from the typical triad and additional findings were retinal degeneration, short stature, incomplete right bundle branch block of the heart, and splenomegaly. Thus, we have expanded the clinical spectrum of TRMA by the symptoms short stature and splenomegaly. Moreover, brain MRI at 12 years of age showed a left parietal cortical lesion without clinical correlate. There is one published report of a cerebral infarction in TRMA.<sup>25</sup> In our patient, the lesion may represent a metabolic decompensation of the energy dependent cortex, as is seen in MELAS syndrome.<sup>26</sup>

Combining our data with results from other reports,<sup>9-11</sup> eight loss of function mutations and one missense mutation have now been described in the coding region of *SLC19A12* (fig 1). The nonsense mutation at position 1074 in our patient leads to a premature truncation of the protein at codon 358 in the predicted transmembrane domain 7. Thus, we can conclude that among the small number of patients examined there is no clustering of mutations.

Biochemically, we found not only the expected PDHC deficiency, but also a hitherto

unreported severe complex I deficiency. Complex I of the mitochondrial respiratory chain is well known to catalyse the transfer of electrons from NADH to ubiquinone and couples this reaction to proton translocation across the inner mitochondrial membrane.<sup>27</sup> The mechanism of the deficiency in TRMA is obscure. In humans, neither thiamine related proteins nor thiamine itself are known to be associated with the function of complex I. The only known cofactors of complex I are FMN, Fe/S clusters, and NADPH.<sup>28</sup> A pleiotropic effect resulting from deficiencies of PDHC and KGDH is also unlikely, since complex I was measured by addition of NADH. In the yeast *Saccharomyces cerevisiae*, 11 thiamine diphosphate dependent enzymes are known and none of them is related to the respiratory chain.<sup>29</sup> However, if Pda1p, a subunit of PDHC, is knocked out in yeast, respiratory deficient mutations are generated at high frequency. The reason for the instability of the mitochondrial genome in these mutants is not understood.<sup>30</sup> Frequent mtDNA mutations have been excluded in our TRMA patient as the cause for complex I deficiency. Moreover, a secondary mtDNA mutation is unlikely in view of normalisation of complex I activity after thiamine supplementation. However, we cannot exclude a second nuclear mutation affecting complex I in this single consanguineous patient with TRMA syndrome. One other report of respiratory chain activities in two independent TRMA patients showed normal activities, but thiamine was discontinued only one week before biopsy.<sup>17</sup>

In general, combined defects of the mitochondrial enzymes PDHC and complexes of the respiratory chain have been found in 5-10% of patients with impaired mitochondrial energy production in muscle tissue when examined systematically.<sup>31</sup> The molecular basis is not clear. Disturbed import or misassembly

of cytosolic synthesised mitochondrial proteins could be excluded by immunoblotting.<sup>31</sup> From a theoretical point of view, respiratory chain defects may lead to decreased activity of PDHC via increased levels of citric acid cycle substrates and acetyl-CoA, while there is no evidence that PDHC mutations can cause respiratory chain defects.

The importance of thiamine to the activity of complex I or associated proteins involved in function or assembly of the respiratory chain has not been reported previously. In addition to deficiencies of thiamine dependent mitochondrial enzymes, a defect of complex I of the respiratory chain would further impair mitochondrial energy production. The main symptoms of TRMA, sideroblastic anaemia, diabetes, and deafness, as well as many of the additional symptoms described here and by others, are frequently found in diseases with respiratory chain deficiency. It cannot be decided phenomenologically if they result from the PDHC defect, the complex I defect, or another consequence of the TRMA mutations. To address these questions, respiratory chain activities should be determined in other TRMA patients and correlations between genotype, biochemistry, and phenotype should be established.

We thank the patient and her family for their participation in this study. We thank Professor D Pongratz and Prof Dr W Müller-Felber for morphological examination of patient muscle biopsies. The excellent technical assistance of K Schulte is also greatly appreciated. This work was supported by the German Federal Ministry for Education, Research and Technology (BMBF01KW9605) and by the Deutsche Forschungsgemeinschaft (Ja 802/1-2).

- Rogers LE, Porter FS, Sidbury JB Jr. Thiamine-responsive megaloblastic anemia. *J Pediatr* 1969;74:494-504.
- Viana MB, Carvalho RI. Thiamine-responsive megaloblastic anemia, sensorineural deafness, and diabetes mellitus: a new syndrome? *J Pediatr* 1978;93:235-8.
- Mandel H, Berant M, Hazani A, Naveh Y. Thiamine-dependent beriberi in the thiamine-responsive anemia syndrome. *N Engl J Med* 1984;311:836-8.
- Abboud MR, Alexander D, Najjar SS. Diabetes mellitus, thiamine-dependent megaloblastic anemia, and sensorineural deafness associated with deficient alpha-ketoglutarate dehydrogenase activity. *J Pediatr* 1985;107:537-41.
- Neufeld EJ, Mandel H, Raz T, Szargel R, Yandava CN, Stagg A, Faure S, Barrett T, Buist N, Cohen N. Localization of the gene for thiamine-responsive megaloblastic anemia syndrome, on the long arm of chromosome 1, by homozygosity mapping. *Am J Hum Genet* 1997;61:1335-41.
- Raz T, Barrett T, Szargel R, Mandel H, Neufeld EJ, Nosaka K, Viana MB, Cohen N. Refined mapping of the gene for thiamine-responsive megaloblastic anemia syndrome and evidence for genetic homogeneity. *Hum Genet* 1998;103:455-61.
- Bazarbachi A, Muakkil S, Ayas M, Taher A, Salem Z, Solh H, Haidar JH. Thiamine-responsive myelodysplasia *Br J Haematol* 1998;102:1098-100.
- Banikazemi M, Diaz GA, Vossough P, Jalali M, Desnick RJ, Gelb BD. Localization of the thiamine-responsive megaloblastic anemia syndrome locus to a 14-cM region of 1q23. *Mol Genet Metab* 1999;66:193-8.
- Labay V, Raz T, Baron D, Mandel H, Williams H, Barrett T, Szargel R, McDonald L, Shalata A, Nosaka K, Gregory S, Cohen N. Mutations in SLC19A2 cause thiamine-responsive megaloblastic anemia associated with diabetes mellitus and deafness. *Nat Genet* 1999;22:300-4.
- Fleming JC, Tartaglino E, Steinkamp MP, Schorderet DF, Cohen N, Neufeld EJ. The gene mutated in thiamine-responsive anemia with diabetes and deafness (TRMA) encodes a functional thiamine transporter. *Nat Genet* 1999;22:305-8.
- Diaz GA, Banikazemi M, Oishi K, Desnick RJ, Gelb BD. Mutations in a new gene encoding a thiamine transporter cause thiamine-responsive megaloblastic anemia syndrome. *Nat Genet* 1999;22:309-12.
- Poggi V, Longo G, DeVizia B, Andria G, Rindi G, Patrini C, Cassandro E. Thiamin-responsive megaloblastic anemia: a disorder of thiamin transport? *J Inher Metab Dis* 1984;7(suppl 2):153-4.
- Rindi G, Ferrari G. Thiamine transport by human intestine in vitro. *Experientia* 1977;15:33:211-13.
- Laforenza U, Patrini C, Alvisi C, Faelli A, Licandro A, Rindi G. Thiamine uptake in human intestinal biopsy specimens, including observations from a patient with acute thiamine deficiency. *Am J Clin Nutr* 1997;66:320-6.
- Stagg AR, Fleming JC, Baker MA, Sakamoto M, Cohen N, Neufeld EJ. Defective high-affinity transporter leads to cell death in TRMA syndrome fibroblasts. *J Clin Invest* 1999;103:723-9.
- Dutta B, Huang W, Molero M, Kekuda R, Leibach FH, Devoe LD, Ganapathy V, Prasad PD. Cloning of the human thiamine transporter, a member of the folate transporter family. *J Biol Chem* 1999;274:31925-9.
- Barrett TG, Poulton K, Baines M, McCowen C. Muscle biochemistry in thiamin-responsive anemia. *J Inher Metab Dis* 1997;20:404-6.
- Jaksch M, Gerbitz KD, Kilger C. Screening for mitochondrial DNA (mtDNA) point mutations using nonradioactive single strand conformation polymorphism (SSCP) analysis. *Clin Biochem* 1995;28:503-9.
- Fischer JC. *Mitochondrial myopathies and respiratory chain defects*. Dissertation, University of Nijmegen, Nijmegen, The Netherlands, 1995.
- Burgess RC. Infantile beriberi. *Fed Proc* 1958;17(suppl 2):39-48.
- Brown GK, Otero LJ, LeGris M, Brown RM. Pyruvate dehydrogenase deficiency. *J Med Genet* 1994;31:875-9.
- Zhang B, Wappner RS, Brandt IK, Harris RA, Crabb DW. Sequence of the E1-alpha subunit of branched-chain alpha-ketoacid dehydrogenase in two patients with thiamine-responsive maple syrup urine disease. *Am J Hum Genet* 1990;46:843-6.
- Koike K. The gene encoding human 2-oxoglutarate dehydrogenase: structural organization and mapping to chromosome 7p13-p14. *Gene* 1995;159:261-6.
- Coy JF, Dubel S, Kioschis P, Thomas K, Micklem G, Delius H, Poustka A. Molecular cloning of tissue-specific transcripts of a transketolase-related gene: implications for the evolution of new vertebrate genes. *Genomics* 1996;32:309-16.
- Morimoto A, Kizaki Z, Konishi K, Sato N, Kataoka T, Hayashi R, Inoue F. A case of thiamine responsive megaloblastic anemia syndrome with nystagmus, cerebral infarction, and retinal degeneration. *J Jpn Pediatr Soc* 1996;2137-45.
- Hasuo K, Tamura S, Yasumori K, Uchino A, Goda S, Ishimoto S, Kamikaseda K, Wakuta Y, Kishi M, Masuda K. Computed tomography and angiography in MELAS (mitochondrial myopathy, encephalopathy, lactic acidosis and stroke-like episodes); report of 3 cases. *Neuroradiology* 1987;29:393-7.
- Hatefi Y. The mitochondrial electron transport and oxidative phosphorylation system. *Annu Rev Biochem* 1985;54:1015-69.
- Schulte U, Haupt V, Abelmann A, Fecke W, Brors B, Rasmussen T, Friedrich T, Weiss H. A reductase/isomerase subunit of mitochondrial NADH:ubiquinone oxidoreductase (complex I) carries an NADPH and is involved in the biogenesis of the complex. *J Mol Biol* 1999;292:569-80.
- Hohmann S, Meacock PA. Thiamin metabolism and thiamin diphosphate-dependent enzymes in the yeast *Saccharomyces cerevisiae*: genetic regulation. *Biochim Biophys Acta* 1998;1385:201-19.
- Wenzel TJ, van den Berg MA, Visser W, van den Berg JA, Steensma HY. Characterization of *Saccharomyces cerevisiae* mutants lacking the E1 alpha subunit of the pyruvate dehydrogenase complex. *Eur J Biochem* 1992;209:697-705.
- Sperl W, Ruitenbeek W, Sengers RC, Trijbels JM, Bentlage H, Wraith JE, Heilmann C, Stockler S, Binder C, Korenke GC. Combined deficiencies of the pyruvate dehydrogenase complex and enzymes of the respiratory chain in mitochondrial myopathies. *Eur J Pediatr* 1992;151:192-5.