

Electronic letter

## Two further cases of WHS with unbalanced de novo translocation t(4;8) characterised by CGH and FISH

**Institute of Human Genetics, Charité, Campus Virchow-Klinikum, Humboldt-University, Institut für Humangenetik, Chromosomendiagnostik, Molekulare Zytogenetik, Augustenburger Platz 1, D-13353 Berlin, Germany**  
 H Tönnies  
 L Neumann  
 H Neitzel

Holger Tönnies, Markus Stumm, Luitgard Neumann, Marianne Volleth, Uta Grumpelt, Jörg Müsebeck, Gisela Annuss, Heidemarie Neitzel

**Institute of Human Genetics, University Hospital, Otto-von-Guericke University, Magdeburg, Germany**  
 M Stumm  
 M Volleth  
 J Müsebeck

**Children's Hospital, Harz-Klinikum Wernigerode GmbH, Wernigerode, Germany**  
 U Grumpelt

**Human Genetics, Klinikum Buch, Berlin, Germany**  
 G Annuss

Correspondence to:  
 Dr Tönnies,  
 Holger.Toennies@charite.de

EDITOR—In the October 2000 issue of the journal, five new cases of unbalanced translocations with partial monosomy 4p and partial trisomy 8p were described by Wieczorek *et al*<sup>1</sup> and the authors concluded that de novo translocations causing Wolf-Hirschhorn syndrome (WHS) are more frequent than previously estimated. In particular, unbalanced de novo translocations involving the short arms of

chromosomes 4 and 8 seem to be frequent in WHS patients. Furthermore, because of the limited resolution of cytogenetic techniques, some cryptic translocations can be missed by routinely performed cytogenetic differential diagnosis. Therefore, the authors emphasised the necessity of investigating all patients with WHS and visible chromosomal imbalances in chromosome 4p by fluorescence in situ hybridisation (FISH), using a chromosome 4 specific painting probe (whole chromosome painting, wcp) to detect possible translocations. Here we report on two further cases with unbalanced de novo translocations t(4;8). The unbalanced translocation was not detectable by conventional cytogenetics alone and was also not detectable just by painting with a chromosome 4 specific library. We have chosen a different strategy using the comparative genomic hybridisation (CGH) technique as a straightforward molecular cytogenetic assay to unravel unbalanced chromosomal translocations. Subsequently, the CGH results were confirmed by FISH.

Table 1 Clinical findings of both patients

	Patient 1	Patient 2
<i>Birth</i>		
Gestational weeks	42	42
Weight (g)	3320	2070
Length (cm)	52	44
OFC (cm)	34	33
Apgar score	9/9/8	1/1/5
<i>Age at examination (mth)</i>		
Weight (g)	9900	
Height (cm)	74	
OFC (cm)	45.5	
Hypertelorism	+	+
Strabismus	-	-
Large, broad mouth	+	-
Downturned corners of mouth	+	+
Micrognathia	+	+
Cleft lip/palate	+	-
Dysplastic ears	+	-
Preauricular tag	-	-
Heart defect	+	-
Genital anomalies	Hypospadias	Hypospadias
Seizures	+	+
Additional findings	Orbital cysts	Iris coloboma

### Case reports

Patient 1 was the first child born to a 25 year old mother and a 30 year old father. The boy was born spontaneously in the 42nd week of gestation after an uncomplicated pregnancy. Birth measurements were in the lower range, weight 3320 g (10th-25th centile), length 52 cm (25th-50th centile), and occipitofrontal circumference (OFC) 34 cm (3rd-10th centile). Apgar scores were 9/9/8. In addition to the clinical manifestations listed in table 1, the child presented with microphthalmia on the right side and incomplete anophthalmia on the left side, with bluish swellings of the lower lids. Bilateral orbital cysts were histopathologically proven as gliopendymal. They were excised at the age of 8 months and orbital prostheses were implanted. Ophthalmological examination further showed atrophy of the optic nerves and the child has no light vision. At the age of 18 months he showed growth delay (height 74 cm, <3rd centile; weight 9900 g, 10th-15th centile; microcephaly, OFC 45.5 cm, <3rd centile), and general muscular hypotonia with poor head control.

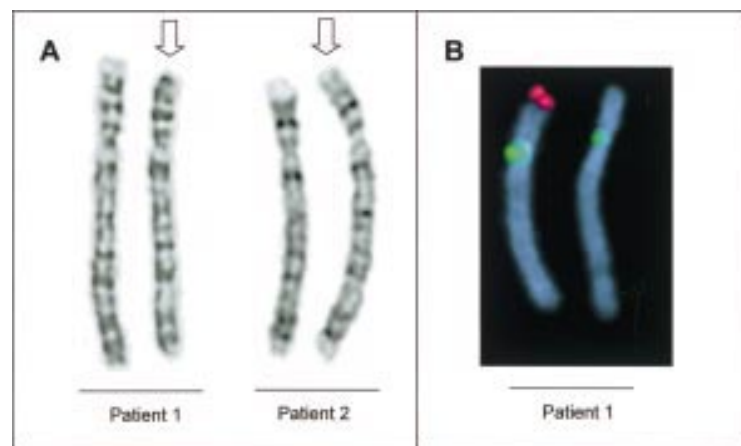
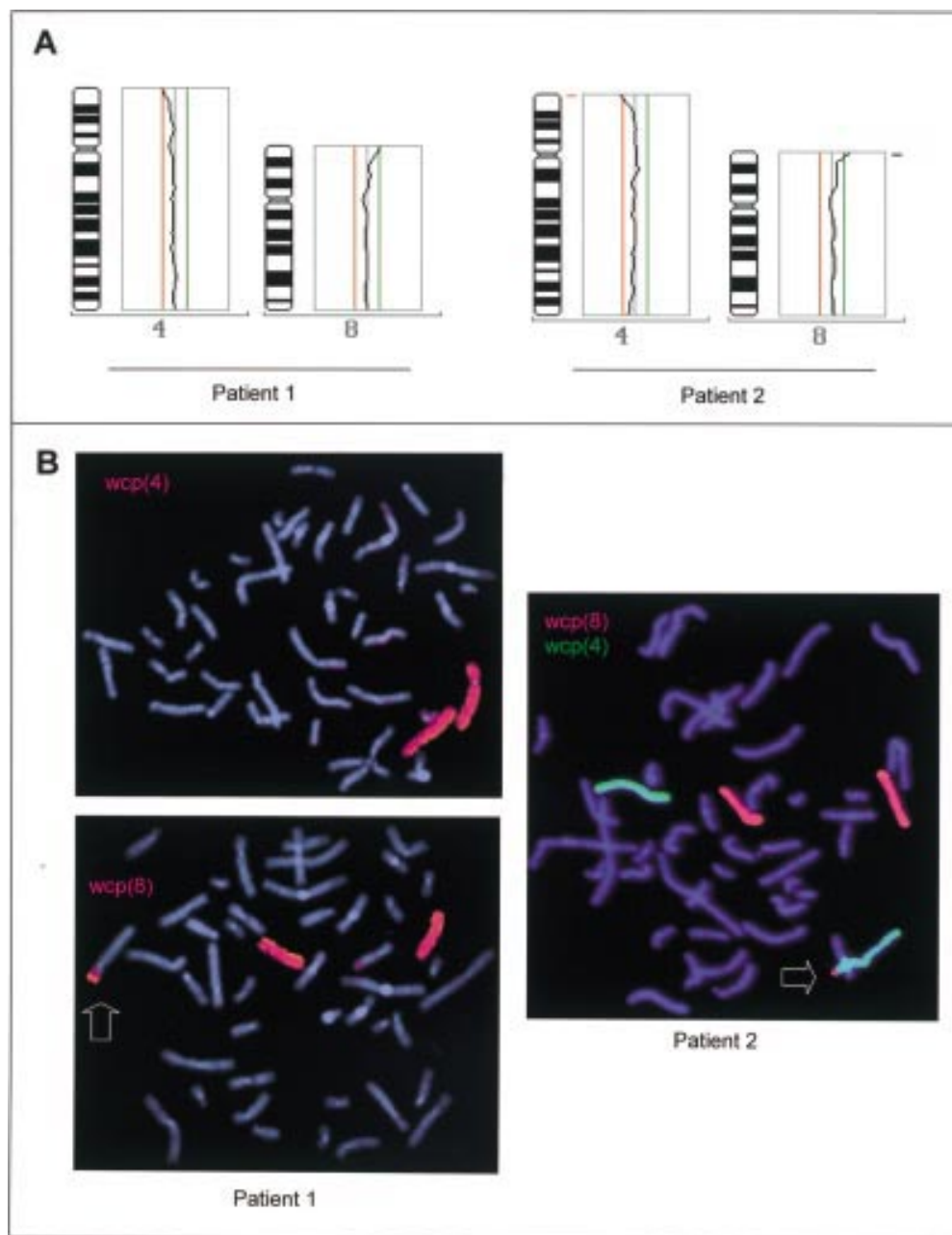


Figure 1 (A) GTG banded chromosomes 4 of patients 1 (left) and 2 (right). The derivative chromosomes 4 (arrows) show additional unknown material at the distal end of the short arm. (B) A FISH probe of the WHS deletion region 4p16.3 shows the deletion of the proximal part of the short arm in the derivative chromosome 4 in patient 1.



**Figure 2** (A) CGH average profiles of chromosomes 4 and 8 of both patients. CGH analysis indicates that the additional material on chromosome 4p is derived from chromosome 8p. However, the deletion of chromosome 4p material could also be detected clearly. Diagnostic thresholds used for the identification of chromosomal under-representations (deletions) and over-representations (duplications) were 0.80 and 1.25. (B) WCP with specific libraries from chromosomes 4 and 8 confirmed the CGH results. A small *wcp(8)* signal could be detected on the derivative chromosome 4 of both patients (arrows). The *wcp(4)* showed only hybridisation signals on both chromosomes 4.

One week after birth, peripheral blood from patient 2 was referred for cytogenetic differential diagnosis of WHS because of intrauterine growth retardation, hypertelorism, hypospadias, and iris coloboma. Patient 2 was the first child of a 29 year old mother and a 26 year old father. Growth retardation was reported in the second half of the pregnancy. The boy was born by caesarean section in the 42nd week of gestation. The amniotic fluid was viscous and green coloured. Birth measures were all below the 3rd centile (weight 2070 g, length 44 cm, and OFC 33 cm). The Apgar scores were 1/1/5 and artificial respiration of the newborn was

necessary. The clinical findings of both patients are summarised in table 1.

Blood samples from the patients and their parents were drawn after informed consent. High resolution chromosome analyses by GTG banding were performed using standard techniques. FISH for WHS differential diagnosis was performed using the commercially available probes localised in the WHS region of chromosome 4p (Vysis, Oncor). For further characterisation of the derivative chromosomes 4, genomic DNA from the patients was investigated by our CGH protocol. In brief, patient and control DNA were differently labelled by nick

translation with SpectrumGreen®-dUTP and SpectrumOrange®-dUTP (Vysis) and 200 ng of labelled test DNA, 200 ng reference DNA, and 12.5 µg Cot-1 DNA were coprecipitated, denatured, and hybridised to normal denatured metaphase spreads. After incubation at 37°C for two days, standard posthybridisation washes were performed. Metaphase images were evaluated using an epifluorescence microscope (Axiophot, Zeiss, Germany) fitted with a cooled CCD camera (Hamamatsu) and appropriate single band pass filter sets. Image analysis and karyotyping was performed using the ISIS analysis system (Metasystems, Germany). The CGH results were confirmed by whole chromosome painting.

GTG banded metaphases of both patients showed an aberrant karyotype with a derivative chromosome 4 (fig 1A). Parental karyotypes of both patients were normal. FISH with WHS locus specific probes detected a deletion in the chromosomal subband 4p16.3 in the derivative chromosomes of both patients (fig 1B, patient 1). CGH was performed to identify the detailed composition of the derivative chromosomes 4. CGH detects chromosomal imbalances and gives additional information about the localisation of the imbalances in one experiment. As expected, the CGH averaged profiles showed a partial loss in chromosome 4p in both patients and, furthermore, a partial gain of chromosome 8p material (fig 2A). FISH with chromosome 4 and 8 specific wcp probes confirmed that the derivative chromosomes 4 were generated by an unbalanced translocation (4;8) (fig 2B). Therefore, the probands' karyotypes can be described as 46,XY,der(4).ish der(4)t(4;8)(p16.1;p23)(wcp4+,wcp8+,WHSC1-,D4Z1+) (patient 1) and 46,XY,der(4).ish der(4)t(4;8)(p16.1;p23)(wcp4+,wcp8+,D4S96-,D4Z1+) (patient 2).

## Discussion

Wieczorek *et al*<sup>1</sup> found different breakpoints on 4p and 8p and suggested that the trisomic part of 8p may be responsible for the clinical variability of the t(4;8) patients. Nevertheless, the clinical features were not specific enough to determine a special genotype/phenotype correlation, or to distinguish WHS resulting from monosomy 4p and WHS resulting from unbalanced translocation 4p;8p.

The breakpoints in our cases are identical, but the patients showed different phenotypic manifestations (table 1). Whereas patient 2 was more severely affected at birth, he has only a few congenital malformations. In contrast, the abnormalities seen in patient 1 are consistent with previously reported cases of t(4;8).<sup>1</sup> However, he also has orbital cysts, which is the first time these have been described, to best of our knowledge, in a WHS patient. Patient 2 suffered from iris coloboma, another eye abnormality, which may be present in nearly one third of all patients with partial monosomy 4p,<sup>2</sup> but less frequently in patients with t(4;8).<sup>1</sup>

In summary, our clinical data confirm that the phenotype of t(4;8) patients is variable and there is no specific syndromal pattern which allows identification of these patients. Therefore, a detailed cytogenetic analysis of the patients and

their parents is necessary to unravel these chromosomal aberrations, particularly as in many published cases the translocation 4;8 was the result of a balanced parental rearrangement and therefore the parents have a risk for further children with unbalanced translocations. Only four of 13 patients reviewed by Wieczorek *et al*<sup>1</sup> occurred as de novo translocations. Our patients also belong to this group. Wieczorek *et al*<sup>1</sup> recommended performing FISH analysis with a library for chromosome 4 to exclude or confirm a de novo translocation causing WHS. This strategy can only be successful in those cases of WHS where the additional material in the distal unlabelled end of chromosome 4 is large enough for detection by wcp. However, especially in distal regions, chromosomal rearrangements can be very subtle and may not be detectable by the rather insensitive method of chromosome painting, as shown in our cases. More reliable methods for the detection of small translocations are available. CGH as a genome wide screening assay allows the identification and localisation of chromosomal imbalances in just one experiment. Alternative screening methods are multi-colour FISH techniques, which can just identify the chromosomal translocation partner but not the exact localisation of the additional chromosomal material. Therefore, our investigations clearly illustrate the potential of CGH for the precise characterisation of unbalanced chromosomal aberrations. We recommend the characterisation of de novo derivative chromosomes by CGH analysis followed by chromosome and/or locus specific probe hybridisations as reported in previous cases.<sup>3-5</sup>

The authors thank Antje Gerlach and Britta Teubner for excellent technical assistance in the molecular cytogenetic experiments.

- 1 Wieczorek D, Krause M, Majewski F, Albrecht B, Meinecke P, Riess O, Gillessen-Kaesbach G. Unexpected high frequency of de novo unbalanced translocations in patients with Wolf-Hirschhorn syndrome (WHS). *J Med Genet* 2000;37:798-804.
- 2 Battaglia A, Carey JC, Cederholm P, Viskochil D, Brothman AR, Galasso C. Natural history of Wolf-Hirschhorn syndrome: experience with 15 cases. *Pediatrics* 1999;103:830-6.
- 3 Tönnies H, Sperling K, Neitzel H. Comparative genomic hybridization as a diagnostic tool to characterize different chromosomal imbalances in routine diagnostics. *Cytogenet Cell Genet* 1999;85:28.
- 4 Stumm M, Tönnies H, Mandon U, Gotze A, Krebs P, Wieacker PF. Mosaic tetrasomy 9p in a girl with multiple congenital anomalies: cytogenetic and molecular-cytogenetic studies. *Eur J Pediatr* 1999;158:571-5.
- 5 Weimer J, Kiechle M, Wiedemann U, Tönnies H, Neitzel H, Ruhlenstroth E, Ovens-Raeder A, Arnold N. Delineation of a complex karyotypic rearrangement by microdissection and CGH in a family affected with split foot. *J Med Genet* 2000;37:442-5.

This letter was shown to Drs Wieczorek and Gillessen-Kaesbach, who reply as follows.

We read the letter by Tönnies *et al* describing two further cases of WHS with unbalanced de novo translocations t(4;8) with great interest. This observation emphasises our findings<sup>1</sup> that particularly translocations t(4;8) are quite frequent in patients with WHS.

Tönnies *et al* successfully used comparative genomic hybridisation (CGH) as their cases were not detectable by conventional cytogenetics and painting with a chromosome 4 specific library alone. We agree that CGH is a very

elegant method to identify unbalanced translocations. However, this method is restricted to the expertise of only a few laboratories. For routine analysis, chromosome painting should be followed by FISH with single copy probes from the distal part of the short arms of chromosome 8, for example, 8p telomere probe, which is commercially available.

In addition, patient 1 has an interesting phenotype. He shows some clinical findings, like normal birth weight and lack of postnatal growth retardation, which are unusual in WHS.

In summary, the description of two further cases of WHS with de novo unbalanced translocations t(4;8) by Tönnies *et al* supports our hypothesis that de novo unbalanced translocations are more frequent in WHS than suspected. In addition, they also confirm our observation that the clinical features of WHS patients with unbalanced translocations t(4;8) are by no means specific enough to distinguish between the phenotypes of simple monosomy 4p and WHS resulting from unbalanced translocation t(4;8).