

ONLINE MUTATION REPORT

Novel homozygous mutation in the alpha subunit of the rod cGMP gated channel (*CNGA1*) in two Spanish sibs affected with autosomal recessive retinitis pigmentosa

E Paloma, A Martínez-Mir, B García-Sandoval, C Ayuso, L Vilageliu, R González-Duarte, S Balcells

J Med Genet 2002;39:e66(<http://www.jmedgenet.com/cgi/content/full/39/10/e66>)

Retinitis pigmentosa (RP, MIM 268000) comprises a clinically and genetically heterogeneous group of disorders leading to progressive dysfunction of the rod photoreceptors of the retina. Patients suffer early night blindness followed by loss of peripheral vision associated with pigment accumulation in the outer retina and attenuation of the retinal vessels. The pathophysiology of RP involves apoptosis of rod cells. Although macular vision is preserved in the initial stages of the disease, visual field defects gradually increase and cone affection follows. RP can be inherited as an autosomal dominant, autosomal recessive, digenic, or X linked trait. Several RP genes and loci have been described to date (RetNet web site: <http://utsph.sph.uth.tmc.edu/www/Wtsph/RetNet/home.htm>). Altogether, the genes known to cause the autosomal recessive forms explain a small proportion of cases, while the great majority remain unexplained, which illustrates the extreme genetic heterogeneity of this condition. As expected, many of the ARRP genes are rod specific, some are only expressed in the retinal pigment epithelium, and none is cone specific.

Cyclic nucleotide gated channels (CNCG) are a group of non-selective ion channels present in different tissues. The rod cGMP gated cation channel is located in the outer segment of the plasma membrane and is involved in the last step of the phototransduction cascade. In spite of a similar function, rod and cone cells express different CNCG genes.¹ Rod channels are predicted to form heterotetramers of two alpha and beta subunit dimers. Each contains a core structural unit of six

membrane spanning segments, a pore region, and a cGMP binding domain. The alpha peptide (*CNGA1*, MIM 123825, GDB 127557) forms a functional channel by itself and is considered the main functional subunit, while the beta counterpart (*CNGB1*, MIM 600724, GDB 434397) modulates the activity of the channel and is unable to promote ion transfer by itself.²⁻⁴ The distinct roles for alpha and beta subunits seem to be conserved in vertebrate and invertebrate signal transduction.⁵

Mutations in the *CNGA1* and *CNGB1* genes have been reported to cause ARRP,^{6,7} while mutations in the cone channel subunit genes (*CNGA3* and *CNGB3*) explain the rare autosomal recessive condition named achromatopsia (total colour blindness).⁸⁻¹⁰ In contrast to a large number of mutations identified in the latter, so far only five mutations in the alpha and one in the beta subunit of the rod cGMP gated channel have been described in ARRP patients.

We describe a new family with ARRP, in which a nonsense homozygous mutation in the alpha subunit of the rod cGMP gated channel cosegregates with the disease. A panel of 46 ARRP Spanish pedigrees was analysed for cosegregation and/or homozygosity of polymorphic markers of the *CNGA1* locus on chromosome 4. Thirty-six families were excluded and the remaining 10 were selected for mutation analysis in the *CNGA1* coding region. In family M-68 (fig 1A), a novel homozygous mutation was found in exon 3.

MATERIAL AND METHODS

Patients

A total of 46 Spanish ARRP pedigrees, 28 consanguineous and 18 non-consanguineous, were analysed. The same panel was used in several previous studies of candidate genes for ARRP, and details of the pedigrees and ophthalmological assessment of patients can be found elsewhere.^{11,12} Control samples were supplied, anonymously, from the blood bank at the Hospital de la Vall d'Hebron, Barcelona. This research followed the tenets of the Declaration of Helsinki. Informed consent was obtained from all the patients included in this study.

Ophthalmological examination of the RP patients in family M-68

Complete ophthalmological examinations were performed in both patients (II.1 and II.6, fig 1). These included visual acuity testing, computerised visual field measurement, tests of dark adaptation and colour vision, as well as fundus examination

Key points

- To date, only five mutations in the alpha and one in the beta subunit of the rod cGMP gated channel genes (*CNGA1* and *CNGB1*) have been documented in autosomal recessive retinitis pigmentosa (ARRP). Here we describe a family with a diagnosis of ARRP, in which a new nonsense homozygous mutation (c.82C>T; R28X) in *CNGA1* cosegregates with the disease.
- R28X is a severe mutation which is presumed to truncate the protein very prematurely. This is similar to three other *CNGA1* mutations associated with ARRP.
- The phenotype associated with homozygosity for R28X includes all symptoms and clinical findings characteristic of RP.
- We have analysed the *CNGA1* gene in a panel of 52 Spanish ARRP families, and only one of these was found to segregate disease causing mutations in the gene. This proportion suggests that *CNGA1* may explain a small fraction of ARRP cases.

Abbreviations: ARRP, autosomal recessive retinitis pigmentosa; CNCG, cyclic nucleotide gated channels; ERG, electroretinogram; SNP, single nucleotide polymorphism; ASOH, allele specific oligonucleotide hybridisation; ORF, open reading frame

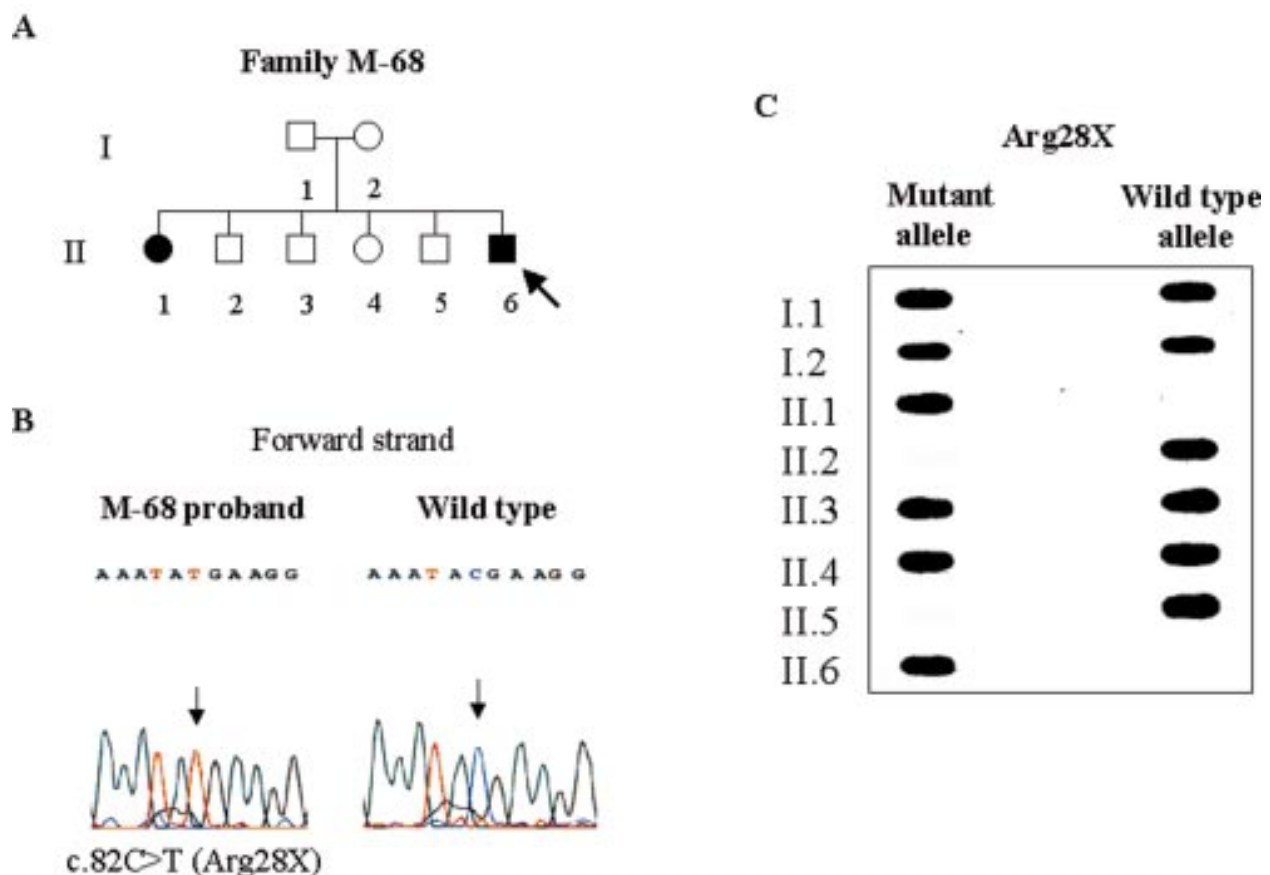


Figure 1 (A) Pedigree of family M-68; the arrow points to the proband. (B) Forward sequences of exon 3 of *CNGA1* from the proband and a control. (C) ASOH analysis of the R28X mutation in all members of the M-68 pedigree.

after pupil dilatation. Electroretinograms (ERGs) were also performed and recorded according to the standard testing protocols for clinical electroretinography (ISCEV¹³). Ganzfeld ERG was recorded with the equipment “Universal Testing and Analysis System - Electrophysiologic 2000” (UTAS-E 2000, LKC Technologies Inc, Gaithersburg, MD USA).

DNA analysis

Polymorphic markers

Microsatellite markers D4S1536 (UCSC-HGPWD (<http://genome.cse.ucsc.edu/>) chr.4: 51019155-51219507) and D4S1577 (chr.4: 57740397-57940738) are proximal and distal, respectively, to the *CNGA1* gene (chr.4: 52755116-52797546).

The *CNGA1* intragenic SNP A813T (located in exon 4) was typed by a PCR-RFLP strategy using the restriction enzyme *EarI*.

Analysis of the *CNGA1* coding region

The complete coding region of *CNGA1* encompassing exons 3 to 10¹⁴ was PCR amplified using reported primers.⁶ SSCP was carried out as described in Bayés *et al.*¹¹ Samples displaying an abnormal SSCP pattern were purified and sequenced using the Thermosequenase dye terminator cycle sequencing pre-mix kit (Amersham Pharmacia Biotech, Uppsala, Sweden) on an ABI 377 automated sequencer (Applied Biosystems, Branchburg, NJ).

Table 1 Comparison of the clinical and ophthalmological findings in the two affected sibs of family M-68

Patient	II.1	II.6
Onset (years)		
Night blindness	2-3	2-3
Visual field constriction	24	25
Decreased visual acuity	30	40
Ophthalmic examination at age 30		
Visual acuity	RE 8/10 LE 5/10	RE 8/10 LE 8/10
Biomicroscopy	N	N
Visual field	RE/LE: peripheral constriction	RE/LE: loss of upper visual field
Fundus	RE/LE: pale disc, arteriolar constriction, paravascular bone spicule pigmentation	RE/LE: pale disc, arteriolar constriction, bone spicule pigmentation
Macula	RE: N LE: macular hole	RE: N LE: N
Electroretinogram	RE/LE: extinguished	RE/LE: extinguished

RE, right eye; LE, left eye; N, normal.

Typing of the variants R28X and R28Q

The presence of these two changes in 102 control chromosomes was assayed by allele specific oligonucleotide hybridisation (ASOH). This protocol was carried out as described in Cormand *et al.*¹⁵ The oligonucleotides used to detect the mutations R28X and R28Q were 5'-AGGAAATATGAAGGATGGA-3' and 5'-AGGAAATACAAAGGATGGA-3', respectively, and the wild type oligo was 5'-AGGAAATACGAAGGATGGA-3'.

RESULTS

Cosegregation and homozygosity analysis

Markers D4S1577, D4S1536, and the SNP A813T were used to construct haplotypes of the *CNGA1* locus in all available members of the 46 ARRP Spanish pedigrees. Cosegregation of the locus and the disease could be excluded in 24 families. In 12

consanguineous pedigrees, exclusion was based on the lack of homozygosity in the affected subjects (data not shown). Seven pedigrees showed cosegregation of locus and disease, while another three were uninformative. Thus, the *CNGA1* locus could not be ruled out in 10 out of the 46 pedigrees, and these were further analysed for mutations in the *CNGA1* gene.

Screening of mutations in *CNGA1*

The complete coding region of the *CNGA1* gene, split into 10 separate fragments, was PCR amplified in one affected member of each pedigree, and subjected to SSCP analysis. Two aberrant patterns were observed in exon 3, which corresponded to the patients from families M-68 and M-71. Sequencing showed that patient II.6 of family M-68 was homozygous for a c.82C>T change (fig 1B). This substitution is expected to produce a truncated protein owing to a premature stop codon at position 28 of the ORF (R28X). ASOH experiments, performed to type all the family members, showed that the parents and two unaffected sibs were all carriers of the R28X change, while patient II.1 was a homozygous mutant (fig 1C). Additionally, 102 control chromosomes were typed and none was found to be mutant.

The aberrant pattern detected in family M-71 corresponded to a nucleotide change (c.83G>A), again affecting codon 28 but now producing an arginine to glutamine substitution (R28Q). This change had been previously described as a polymorphism or rare variant.⁶ In order to establish the allele frequency in the Spanish population, 51 controls were analysed and one was found to be a carrier, which corresponds to an allele frequency close to 1%. Moreover, the analysis of this polymorphism in family M-71 (uninformative in the cosegregation analysis) showed that it did not cosegregate with the disease.

Clinical results in patients from family M-68

Clinical characteristics of the two patients in this family are listed in table 1 and illustrated in fig 2. Night blindness had a very early onset in both patients and from there on all symptoms and clinical findings were characteristic of RP. Disease progression was similar in both patients, and at the age of 40 they both had slightly decreased visual acuity and affected visual fields. Patient II.1 was followed up at ages 47 and 53 (fig 2A). Her visual field is now constricted to 10° central in both eyes and her visual acuity is 3/10 in the right eye and 5/100 in the left eye. Fundus examination showed the typical retinitis pigmentosa appearance with pale discs, arteriolar constriction, retinal pigmented epithelium atrophy, and paravascular bone spicule pigmentation affecting the midperiphery. Maculae were normal in patient II.6 whereas patient II.1 showed a macular hole in the left eye.

DISCUSSION

After screening *CNGA1* in 10 ARRP Spanish families, two variants were detected in exon 3. The substitution R28X, found in homozygosity in the two RP sibs of family M-68, is located in the intracellular amino terminal hydrophilic segment of the protein and truncates the reading frame early in the sequence. This null mutation, which could not be detected in 102 control chromosomes, is most probably the cause of the disease in these patients. Overall, four out of the six mutations in *CNGA1* associated with ARRP⁶ (this work) either lead to a very early truncation of the protein or to its total absence. The second variant identified, R28Q, clearly corresponds to a polymorphism present in the unaffected population at an allele frequency close to 1%, and our data are in agreement with previous evidence.⁶

We have also addressed the contribution of *CNGA1* to the autosomal recessive cases of RP. From the present analysis, we conclude that it amounts to no more than 2%. This value is comparable to those corresponding to other ARRP genes such

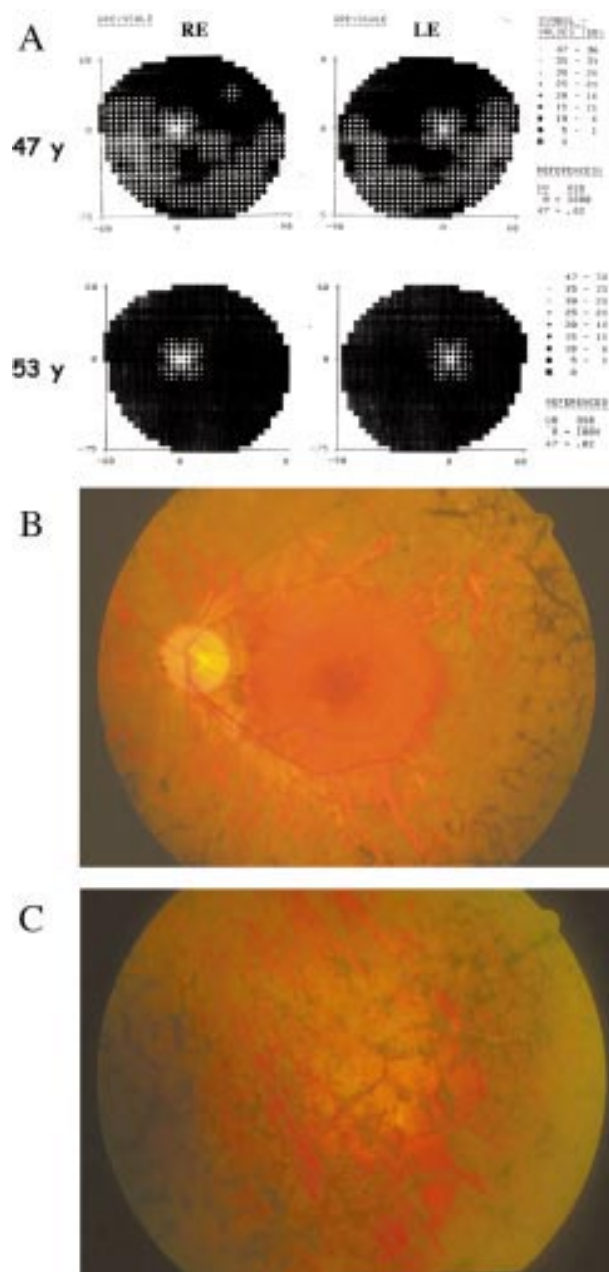


Figure 2 (A) Decrease in visual fields of patient II.1 between ages 47 and 53. (B) Fundus image of left eye of patient II.1. Pale disc, arteriolar attenuation, paravascular pigment, and RPE atrophy can be seen. (C) Fundus image of left eye of patient II.1. Characteristic bone spicule pigmentation in the midperiphery.

as *TULP1*¹⁶ or *ABCA4* (our unpublished data) and about five-fold less than *PDEB*,¹² which is still one of the leading genetic factors causing ARRP. Our data argue in favour of the extreme genetic heterogeneity of the disease and illustrate the difficulties that lie ahead to clarify its genetic basis.

Another interesting feature concerns the small number of mutations described in *CNGA1* as compared to the cone counterpart, *CNGA3*.¹⁰ Out of the 10 candidate pedigrees analysed here, pathogenic mutations could be identified in only one. The fact that we concentrated our efforts on the coding region (exons 3 to 10) does not allow us to exclude either pathogenic variants harboured in the 5'- and 3'-UTR, nor large chromosomal reorganisations. However, the discrepancy with the cone channel gene was based on the ORF segment alone. Extrapolating from the cone situation and considering the functional and structural similarities of the two proteins, it would be tempting to speculate that substitutions within the coding region of *CNGA1* may indeed happen, but not necessarily lead to RP. Rather they could be the cause of some other retinal disorder.

ACKNOWLEDGEMENTS

We thank the patients and their families for their cooperation. We also thank Dr D Gallardo from the Hospital de la Vall d'Hebron for supplying DNA samples to serve as controls. Robin Rycroft revised the English. The Serveis Científic-Tècnics from Universitat de Barcelona carried out all the automated DNA sequencing. We acknowledge the contract grant sponsors: Spanish Ministerio de Ciencia y Tecnología (grant number PM99-0168) and Spanish Fundaluce (Fundación de lucha contra la ceguera). EP is recipient of a predoctoral fellowship from CIRIT (Generalitat de Catalunya).

.....

Authors' affiliations

E Paloma, A Martínez-Mir*, L Vilageliu, R González-Duarte, S Balcells, Departament de Genètica, Facultat de Biologia, Universitat de Barcelona, Barcelona, Spain
B García-Sandoval, C Ayuso, Departamento de Genètica, Fundación Jiménez-Díaz, Madrid, Spain

*Present address: Department of Dermatology, Columbia University, College of Physicians and Surgeons, New York, USA

Correspondence to: Dr S Balcells, Departament de Genètica, Universitat de Barcelona, Av Diagonal 645, E-08028 Barcelona, Spain; susan@porthos.bio.ub.es

REFERENCES

- 1 **Bönigk W**, Altenhofen W, Muller F, Dose A, Illing M, Molday RS, Kaupp UB. Rod and cone photoreceptor cells express distinct genes for cGMP-gated channels. *Neuron* 1993;**10**:865-77.

- 2 **Kaupp UB**, Niidome T, Tanabe T, Terada S, Bönigk W, Stühmer W, Cook NJ, Kangawa K, Matsuo H, Hirose T, Miyata T, Numa S. Primary structure and functional expression from complementary DNA of the rod photoreceptor cyclic GMP-gated channel. *Nature* 1989;**342**:762-6.
- 3 **Chen TY**, Peng YW, Dhallan RS, Ahamed B, Reed RR, Yau KW. A new subunit of the cyclic nucleotide-gated cation channel in retinal rods. *Nature* 1993;**362**:764-7.
- 4 **Molday RS**, Warren R, Loewen C, Molday L. Cyclic GMP-gated channel and peripherin/rds-rom-1 complex of rod cells. *Novartis Found Symp* 1999;**224**:249-61, 261-4.
- 5 **Komatsu H**, Jin YH, L'Etoile N, Mori I, Bargmann CI, Akaike N, Ohshima Y. Functional reconstitution of a heteromeric cyclic nucleotide-gated channel of *Caenorhabditis elegans* in cultured cells. *Brain Res* 1999;**821**:160-8.
- 6 **Dryja TP**, Finn JT, Peng YW, McGee TL, Berson EL, Yau KW. Mutations in the gene encoding the alpha subunit of the rod cGMP-gated channel in autosomal recessive retinitis pigmentosa. *Proc Natl Acad Sci USA* 1995;**92**:10177-181.
- 7 **Barcil C**, Hamel CP, Delague V, Arnaud B, Demaille J, Claustres M. Segregation of a mutation in *CNGB1* encoding the beta-subunit of the rod cGMP-gated channel in a family with autosomal recessive retinitis pigmentosa. *Hum Genet* 2001;**108**:328-34.
- 8 **Kohl S**, Marx T, Giddings I, Jägle H, Jacobson SG, Apfelstedt-Sylla E, Zrenner E, Sharpe LT, Wissinger B. Total colourblindness is caused by mutations in the gene encoding the alpha-subunit of the cone photoreceptor cGMP-gated cation channel. *Nat Genet* 1998;**19**:257-9.
- 9 **Kohl S**, Baumann B, Broghammer M, Jägle H, Sieving P, Kellner U, Spegal R, Anastasi M, Zrenner E, Sharpe LT, Wissinger B. Mutations in the *CNGB3* gene encoding the beta-subunit of the cone photoreceptor cGMP-gated channel are responsible for achromatopsia (*ACHM3*) linked to chromosome 8q21. *Hum Mol Genet* 2000;**9**:2107-116.
- 10 **Wissinger B**, Gamer D, Jägle H, Giorda R, Marx T, Mayer S, Tippmann S, Broghammer M, Jurklies B, Rosenberg T, Jacobson SG, Sener EC, Tatlipinar S, Hoyng CB, Castellán C, Bitoun P, Andreasson S, Rudolph G, Kellner U, Lorenz B, Wolff G, Verellen-Dumoulin C, Schwartz M, Cremers FPM, Apfelstedt-Sylla E, Zrenner E, Salati R, Sharpe LT, Kohl S. *CNGB3* mutations in hereditary cone photoreceptor disorders. *Am J Hum Genet* 2001;**69**:722-37.
- 11 **Bayés M**, Valverde D, Balcells S, Grinberg D, Vilageliu L, Benítez J, Ayuso C, Beneyto M, Baiget M, González-Duarte R. Evidence against involvement of recoverin in autosomal recessive retinitis pigmentosa in 42 Spanish families. *Hum Genet* 1995;**96**:89-94.
- 12 **Bayés M**, Martínez-Mir A, Valverde D, Del Río E, Vilageliu L, Grinberg D, Balcells S, Ayuso C, Baiget M, González-Duarte R. Autosomal recessive retinitis pigmentosa in Spain: evaluation of four genes and two loci involved in the disease. *Clin Genet* 1996;**50**:380-7.
- 13 **ISCEV**, Marmor MF, Arden GF, Nilson SE, Zrenner E. Standard for clinical electroretinography. *Arch Ophthalmol* 1989;**107**:816-19.
- 14 **Dhallan RS**, Macke JP, Eddy RL, Shows TB, Reed RR, Yau KW, Nathans J. Human rod photoreceptor cGMP-gated channel: amino acid sequence, gene structure, and functional expression. *J Neurosci* 1992;**12**:3248-56.
- 15 **Cormand B**, Vilageliu L, Burguera JM, Balcells S, González-Duarte R, Grinberg D, Chabás A. Gaucher disease in Spanish patients: analysis of eight mutations. *Hum Mutat* 1995;**5**:303-9.
- 16 **Paloma E**, Hjelmqvist L, Bayés M, García-Sandoval B, Ayuso C, Balcells S, González-Duarte R. Novel mutations in the *TULP1* gene causing autosomal recessive retinitis pigmentosa. *Invest Ophthalmol Vis Sci* 2000;**41**:656-9.