

SHORT REPORT

In frame fibrillin-1 gene deletion in autosomal dominant Weill-Marchesani syndrome

L Faivre, R J Gorlin, M K Wirtz, M Godfrey, N Dagoneau, J R Samples, M Le Merrer, G Collod-Beroud, C Boileau, A Munnich, V Cormier-Daire

J Med Genet 2003;40:34–36

Weill-Marchesani syndrome (WMS) is a connective tissue disorder characterised by short stature, brachydactyly, joint stiffness, and characteristic eye anomalies including microspherophakia, ectopia of the lenses, severe myopia, and glaucoma. Both autosomal recessive (AR) and autosomal dominant (AD) modes of inheritance have been described and a gene for AR WMS has recently been mapped to chromosome 19p13.3-p13.2. Here, we report on the exclusion of chromosome 19p13.3-p13.2 in a large AD WMS family and show that, despite clinical homogeneity, AD and AR WMS are genetically heterogeneous entities. Because two AD WMS families were consistent with linkage to chromosome 15q21.1, the fibrillin-1 gene was sequenced and a 24 nt in frame deletion within a latent transforming growth factor- β 1 binding protein (LTBP) motif of the fibrillin-1 gene was found in a AD WMS family (exon 41, 5074_5097del). This in frame deletion cosegregated with the disease and was not found in 186 controls. This study strongly suggests that AD WMS and Marfan syndrome are allelic conditions at the fibrillin-1 locus and adds to the remarkable clinical heterogeneity of type I fibrillinopathies.

Weill-Marchesani syndrome (WMS, MIM 277600) is a rare connective tissue disorder first described by Weill¹ in 1932, and further delineated by Marchesani.² The patients present with short stature, short and stubby hands and feet, and may have stiff joints and thickened skin, especially in the hands. Most patients have been described by ophthalmologists, as complications usually consist of dislocation of microspherophakic lenses, which causes severe myopia, acute and/or chronic glaucoma, and cataract. Despite clinical homogeneity, two modes of inheritance have been reported, autosomal dominant (AD)^{3–5} and autosomal recessive inheritance (AR) with occasional brachymorphism in heterozygotes.⁶ Clinical similarities with Marfan syndrome⁷ prompted Wirtz *et al*⁵ to consider fibrillin-1 as a candidate gene for WMS. Interestingly, two large AD WMS families were consistent with linkage to chromosome 15q21.1 where the fibrillin-1 gene had been previously mapped,⁷ but this localisation had been excluded in AR WMS.⁸

We have recently reported on the homozygosity mapping of an AR WMS gene to chromosome 19p13.3-p13.2 in two large families of Lebanese and Saudi origin.⁹ Here, we show that AD WMS does not map to the same locus and report on a 24 nt in frame deletion of the fibrillin-1 gene in a large AD WMS family. This study supports genetic heterogeneity of AD and AR WMS and first ascribes the dominant form of the disease to a fibrillin-1 gene mutation on chromosome 15q21.1. It appears therefore that AD WMS and Marfan syndrome are allelic conditions at the fibrillin-1 locus.

PATIENTS AND METHODS

The members of the two AD WMS families reported by Wirtz *et al*⁵ were included in this study. Family 1 has previously been reported by Gorlin *et al*⁵ in 1974. Affected subjects, aged 2 to 60 years, fulfilled the inclusion criteria, namely short stature, brachydactyly, limitation of joint movements, microspherophakia and/or dislocated lenses, severe myopia, and glaucoma. In addition, two patients had carpal tunnel syndrome. Immunohistochemical staining of skin sections performed in family 1 showed an apparent decrease in fibrillin staining.⁵

DNA extraction and microsatellite analyses were performed as previously described¹⁰ and primers were chosen from the Genethon map¹¹ with an average spacing of 3 cM.⁹ Results were analysed by manual haplotype analysis under the assumption of autosomal dominant inheritance, with full penetrance and a 0 value for the phenocopy rate. Screening for fibrillin-1 gene mutations was performed on leucocyte DNA by directly sequencing both strands of PCR products. Exons 1 to 65 of the fibrillin-1 gene and their flanking intronic sequences were amplified as previously described.¹² One affected subject in each family was chosen for sequencing and other affected subjects were sequenced when necessary.

RESULTS

Fig 1 shows that family 1 was consistent with linkage to both chromosomes 19p13.2-p13.3 and 15q21.1, but linkage of the disease gene to chromosome 19p13.2-p13.3 was clearly excluded in family 2, as the six affected subjects did not share a common haplotype in this region.

Sequence analysis of the fibrillin-1 gene in family 1 showed heterozygosity for a 24 nucleotide in frame deletion in exon 41 (5074_5097del, fig 1). Eight amino acids were deleted (R-S-L-C-Y-R-N-Y). This deletion was confirmed on both strands and was also detectable when amplification products were separated on 1% agarose, 3% NuSieve gels and stained with ethidium bromide. The deletion was found in all affected subjects and cosegregated with the disease in family 1 (fig 1). Conversely, this deletion was not found in 186 controls of European origin (372 chromosomes). No deleterious mutation has been found so far in family 2.

DISCUSSION

Here, we report on a 24 nt in frame deletion of the fibrillin-1 gene in a large AD WMS family. The deleterious nature of this deletion is very likely for several reasons. This deletion cosegregates with the disease and has never been found in previous publications or controls in this study. This deletion involves one of the seven latent transforming growth factor- β 1 binding protein (LTBP) motifs in a conserved region of the protein. Each motif contains eight cysteine residues and interrupts multiple stretches of calcium binding epidermal growth factor-like (cbEGF) modules. LTBP domains normally display a globular structure and comprise six antiparallel beta strands

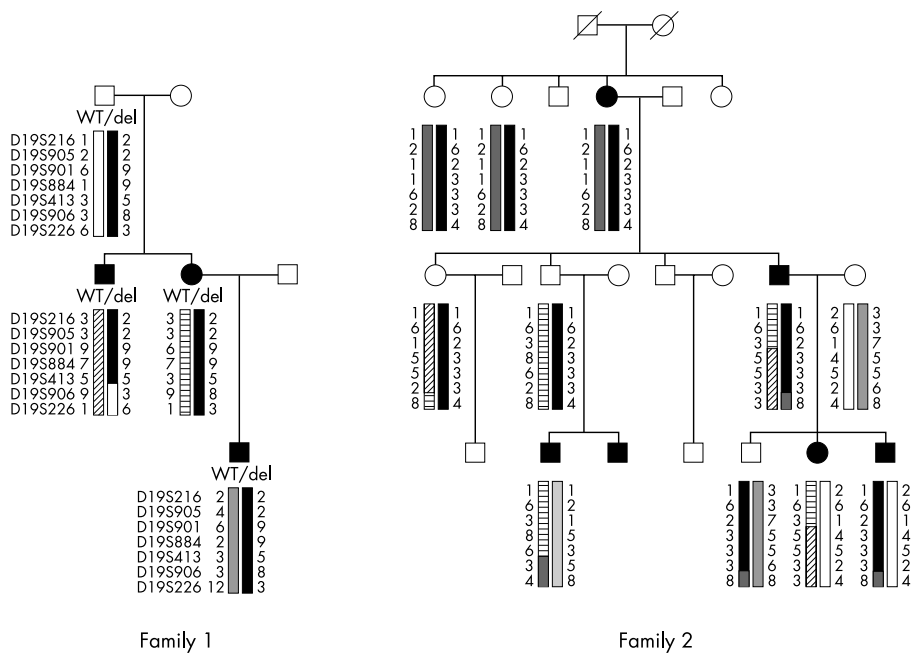


Figure 1 Pedigree of two AD WMS families, haplotypes on chromosome 19p13.2-p13.3, and genotype at the fibrillin-1 gene on chromosome 15q21.1. WT: wild type, del: 5074_5097del in exon 41 of the fibrillin-1 gene on chromosome 15q21.1.

and two alpha helices. The structure is stabilised by four disulphide bonds which pair the eight cysteine residues in a 1-3, 2-6, 4-7, 5-8 pattern.¹³ One of these eight cysteine residues is included in the fibrillin-1 gene deletion in family 1. Hence, heterozygosity for this partial deletion of the LTBP domain is expected to result in unstable mutant protein cleavage products that should interfere with microfibrillar assembly. Indeed, previous immunohistochemical analyses of skin sections in family 1 showed an apparent decrease in fibrillin staining when compared to controls.⁵ Why no fibrillin-1 gene mutation has been found so far in our second AD WMS family is questionable. This feature may be related to the low rate of mutation detection in another type I fibrillinopathy, Marfan syndrome (10-78%).^{12 14 15}

The fibrillin-1 gene has been previously shown to account for various conditions, including Marfan syndrome,¹⁶ neonatal Marfan syndrome,¹⁷ Shprintzen-Goldberg syndrome,¹⁸ familial arachnodactyly,¹⁹ ectopia lentis,²⁰ isolated ascending aortic aneurysm and dissection,²¹ mitral valve prolapse, aortic root dilatation without dissection, skeletal and skin abnormalities (MASS phenotype),²² and Marfan-like syndromes.²³ Our observation of a fibrillin-1 deletion in AD WMS adds to the striking clinical heterogeneity of type I fibrillinopathies.

It is interesting to note that mutational "hot spots" in exons 24-27 and 31-32 have been reported in neonatal Marfan syndrome¹⁷ and that exon skipping mutations apparently caused more severe phenotypes²⁴ than mutations in the 3' region of the gene.²³ So far, however, the clinical heterogeneity of type I fibrillinopathies has not been accounted for by any sound genotype-phenotype correlations. Indeed, a 7 nt deletion overlapping the deleted region of our AD WMS family led to premature protein termination in a patient with Marfan syndrome.²⁶ Moreover, patients with typical Marfan syndrome occasionally harboured mutations in a domain of the gene which is preferentially involved in neonatal Marfan syndrome²⁷ and mutations altering the same residue in two distinct modules were found to be responsible for either autosomal dominant ectopia lentis²⁰ or neonatal Marfan syndrome.¹² Similarly, the same fibrillin-1 missense mutation (C1223Y) has been found in typical Marfan syndrome²⁸ and in one patient with Shprintzen-Goldberg syndrome,¹⁸ although

another missense mutation in a second patient was shown to be a polymorphism in subsequent papers.^{29 30}

This interfamilial clinical heterogeneity at the fibrillin-1 locus is even reinforced by a striking intrafamilial variability, as two patients with Marfan syndrome had children suffering from WMS.³¹ In light of this remarkable inter- and intrafamilial variability of fibrillin-1 mutations, a possible role of environmental, stochastic, or epigenetic factors has been considered but not yet demonstrated.

Mice carrying the Tight skin (Tsk) mutation are interesting regarding WMS; they have thickened skin resulting from an accumulation of extracellular matrix molecules.^{32 33} Other features include visceral fibrosis, increased bone and cartilage growth, lung emphysema, myocardial hypertrophy, and the presence of small tendons with tendon sheath hyperplasia.³² Molecular studies of the fibrillin-1 gene showed the presence of a 30 to 40 kb genomic duplication within the fibrillin-1 gene that results in a larger than normal in frame fibrillin-1 transcript.³³ The presence of tight skin in both the Tsk mouse and WMS is particularly interesting and appears to be a distinctive feature not observed in other human conditions involving fibrillin-1 mutations.

In conclusion, we show here that despite clinical homogeneity, AD and AR WMS are genetically heterogeneous conditions. Our observation of an in frame fibrillin-1 gene deletion in an AD WMS pedigree strongly suggests that AD WMS and Marfan syndrome are allelic conditions at the fibrillin-1 locus. This study adds to the remarkable clinical heterogeneity of type I fibrillinopathies and raises the question of whether AR WMS is caused by another fibrillin gene mutation. Continuing studies will hopefully address this important question.

ACKNOWLEDGEMENTS

Electronic database: Online Mendelian Inheritance in Man (OMIM), <http://www.ncbi.nlm.nih.gov/Omim/> International Marfan database, <http://www.umd.necker.fr>

Authors' affiliations

L Faivre, N Dagonneau, M Le Merrer, A Munnich, V Cormier-Daire, Département de Génétique et INSERM U393, Hôpital Necker Enfants

Malades, Paris, France

R J Gorlin, Department of Oral Science, University of Minnesota Health Sciences Center, Minneapolis, Minnesota, USA

M K Wirtz, J R Samples, Department of Ophthalmology, Casey Eye Institute, Oregon Health Sciences University, Portland, Oregon, USA

M Godfrey, Department of Pediatrics and Munroe Center for Human Genetics, University of Nebraska Medical Center, Omaha, NE, USA

G Collod-Beroud, C Boileau, Unité INSERM 383, Hôpital Necker Enfants Malades, Paris, France

Correspondence to: Dr V Cormier-Daire, Département de Génétique, Hôpital Necker-Enfants Malades, 149 rue de Sèvres, 75015 Paris, France; cormier@necker.fr

Revised version received 17 September 2002

Accepted for publication 18 September 2002

REFERENCES

- Weill G**. Ectopie du cristallin et malformations générales. *Ann Ocul* 1932;**169**:21-44.
- Marchesani O**. Brachydactylie und angeborene kugellins als systemerkrankung. *Klin Mbl Augenheilkd* 1939;**103**:392-406.
- Gorlin RJ, L'Heureux PR, Shapiro I**. Weill-Marchesani syndrome in two generations: genetic heterogeneity or pseudodominance? *J Pediatr Ophthalmol* 1974;**11**:139-44.
- Verloes A, Hermia JP, Galand A, Koulischer L, Dodinval P**. Glaucoma-lens ectopia-microspherophakia-stiffness-shortness (GEMSS) syndrome: a dominant disease with manifestations of Weill-Marchesani syndrome. *Am J Med Genet* 1992;**44**:48-51.
- Wirtz MK, Samples JR, Kramer PL, Rust K, Yount J, Acott TS, Koler RD, Cisler J, Jahed A, Gorlin RJ, Godfrey M**. Weill-Marchesani syndrome - possible linkage of the autosomal dominant form to 15q21.1. *Am J Med Genet* 1996;**65**:68-75.
- Kloepfer HW, Rosenthal JW**. Possible genetic carriers in the spherophakia-brachymorphia syndrome. *Am J Hum Genet* 1955;**7**:398-425.
- Probert LA**. Spherophakia with brachydactyly: comparison with Marfan syndrome. *Am J Ophthalmol* 1953;**36**:1571-4.
- Megarbane A, Mustapha M, Bleik J, Waked N, Delague V, Loiselet J**. Exclusion of chromosome 15q21.1 in autosomal-recessive Weill-Marchesani syndrome in an inbred Lebanese family. *Clin Genet* 2000;**58**:473-8.
- Favre L, Mégarbané A, Alswaid A, Zylberberg L, Aldohayan N, Campos-Xavier AB, Bacq D, Legeai-Mallet L, Bonaventure J, Munnich A, Cormier-Daire V**. Homozygosity mapping of a Weill-Marchesani syndrome locus to chromosome 19p13.3-p13.2. *Hum Genet* 2002;**110**:366-70.
- Belin V, Cusin V, Viot G, Girlich D, Toutain A, Moncla A, Vekemans M, Le Merrer M, Munnich A**. SHOX mutations in dyschondrosteosis (Leri-Weill syndrome). *Nat Genet* 1998;**19**:67-9.
- Dib C, Faure S, Fizames C, Samson D, Drouot N, Vignal A, Millasseau P, Marc S, Hazan J, Seboun E, Lathrop M, Gyapay G, Morissette J, Weissenbach J**. A comprehensive genetic map of the human genome based on 5,264 microsatellites. *Nature* 1996;**380**:152-4.
- Nijbroek G, Sood S, McIntosh I, Francomano CA, Bull E, Pereira L, Ramirez F, Pyeritz RE, Dietz HC**. Fifteen novel FBN1 mutations causing Marfan syndrome detected by heteroduplex analysis of genomic amplicons. *Am J Hum Genet* 1995;**57**:8-21.
- Yuan X, Downing AK, Knott V, Handford PA**. Solution structure of the transforming growth factor beta-binding protein-like module, a domain associated with matrix fibrils. *EMBO J* 1997;**16**:6659-66.
- Tynan K, Comeau K, Pearson M, Wilgenbus P, Levitt D, Gasner C, Berg MA, Miller DC, Francke U**. Mutation screening of complete fibrillin-1 coding sequence: report of five new mutations, including two in 8-cysteine domains. *Hum Mol Genet* 1993;**2**:1813-21.
- Kainulainen K, Karttunen L, Puhakka L, Sakai L, Peltonen L**. Mutations in the fibrillin gene responsible for dominant ectopia lentis and neonatal Marfan syndrome. *Nat Genet* 1994;**6**:64-9.
- Dietz HC, Cutting GR, Pyeritz RE, Maslen CL, Sakai LY, Corson GM, Puffenberger EG, Hamosh A, Nanthakumar EJ, Curristin SM, Stetten G, Meyers DA, Francomano CA**. Marfan syndrome caused by a recurrent de novo missense mutation in the fibrillin gene. *Nature* 1991;**352**:337-9.
- Booms P, Cisler J, Mathews KR, Godfrey M, Tiecke F, Kaufmann UC, Vetter U, Hagemeyer C, Robinson PN**. Novel exon skipping mutation in the fibrillin-1 gene: two 'hot spots' for the neonatal Marfan syndrome. *Clin Genet* 1999;**55**:110-17.
- Sood S, Eldadah ZA, Krause WL, McIntosh I, Dietz HC**. Mutation in fibrillin-1 and the Marfanoid-craniosynostosis (Shprintzen-Goldberg) syndrome. *Nat Genet* 1996;**12**:209-11.
- Hayward C, Porteous ME, Brock DJ**. A novel mutation in the fibrillin gene (FBN1) in familial arachnodactyly. *Mol Cell Probes* 1994;**8**:325-7.
- Lönnqvist L, Child A, Kainulainen K, Davidson R, Puhakka L, Peltonen L**. A novel mutation of the fibrillin gene causing ectopia lentis. *Genomics* 1994;**19**:573-6.
- Milewicz DM, Michael K, Fisher N, Coselli JS, Markello T, Biddinger A**. Fibrillin-1 (FBN1) mutations in patients with thoracic aortic aneurysms. *Circulation* 1996;**94**:2708-11.
- Dietz HC, McIntosh I, Sakai LY, Corson GM, Chalberg SC, Pyeritz RE, Francomano CA**. Four novel FBN1 mutations: significance for mutant transcript level and EGF-like domain calcium binding in the pathogenesis of Marfan syndrome. *Genomics* 1993;**17**:468-75.
- Stahl-Hallengren C, Ukkonen T, Kainulainen K, Kristoferson U, Saxne T, Tornqvist K, Peltonen L**. An extra cysteine in one of the non-calcium-binding epidermal growth factor-like motifs of the FBN1 polypeptide is connected to a novel variant of Marfan syndrome. *J Clin Invest* 1994;**94**:709-13.
- Liu W, Qian C, Comeau K, Brenn T, Furthmayr H, Francke U**. Mutant fibrillin-1 monomers lacking EGF-like domains disrupt microfibril assembly and cause severe Marfan syndrome. *Hum Mol Genet* 1996;**5**:1581-7.
- Palz M, Tiecke F, Booms P, Goldner B, Rosenberg T, Fuchs J, Skovby F, Schumacher H, Kaufmann UC, von Kodolitsch Y, Nienaber CA, Leitner C, Katzke S, Vetter B, Hagemeyer C, Robinson PN**. Clustering of mutations associated with mild Marfan-like phenotypes in the 3' region of FBN1 suggests a potential genotype-phenotype correlation. *Am J Med Genet* 2000;**91**:212-21.
- Pepe G, Giusti B, Evangelisti L, Porciani MC, Brunelli T, Giurlani L, Attanasio M, Fattori R, Bagni C, Comeglio P, Abbate R, Gensini GF**. Fibrillin-1 (FBN1) gene frameshift mutations in Marfan patients: genotype-phenotype correlation. *Clin Genet* 2001;**59**:444-50.
- Tiecke F, Katzke S, Booms P, Robinson PN, Neumann L, Godfrey M, Mathews KR, Scheuner M, Hinkel GK, Brenner RE, Hovels-Gurich HH, Hagemeyer C, Fuchs J, Skovby F, Rosenberg T**. Classic, atypically severe and neonatal Marfan syndrome: twelve mutations and genotype-phenotype correlations in FBN1 exons 24-40. *Eur J Hum Genet* 2001;**9**:13-21.
- Hewett DR, Lynch JR, Child A, Sykes BC**. A new missense mutation of fibrillin in a patient with Marfan syndrome. *J Med Genet* 1994;**31**:338-9.
- Wang M, Mathews KR, Imaizumi K, Beiraghi S, Blumberg B, Scheuner M, Graham JM Jr, Godfrey M**. P1148A in fibrillin-1 is not a mutation anymore. *Nat Genet* 1997;**15**:12.
- Watanabe Y, Yano S, Koga Y, Yukizane S, Nishiyori A, Yoshino M, Kato H, Ogata T, Adachi M**. P1148A in fibrillin-1 is not a mutation leading to Shprintzen-Goldberg syndrome. *Hum Mutat* 1997;**10**:326-7.
- Bowers D**. Marfan's syndrome and the Weill-Marchesani syndrome in the S. family. *Ann Int Med* 1959;**51**:1049-70.
- Green MC, Sweet HO, Bunker LE**. Tight-skin, a new mutation of the mouse causing excessive growth of connective tissue and skeleton. *Am J Pathol* 1976;**82**:493-512.
- Siracusa LD, McGrath R, Ma Q, Moskow JJ, Manne J, Christner PJ, Buchberg AM, Jimenez SA**. A tandem duplication within the fibrillin 1 gene is associated with the mouse tight skin mutation. *Genome Res* 1996;**6**:300-13.