

SHORT REPORT

## Cluster headache-like attack as an opening symptom of a unilateral infarction of the cervical cord: Persistent anaesthesia and dysaesthesia to cold stimuli

Vincent de la Sayette, Stéphane Schaeffer, Oguzhan Coskun, François Leproux, Gilles Defer

**Abstract**

**A 54 year old man experienced excruciating left retro-orbital pain with lacrimation and redness of the eye representative of a cluster headache attack. This was followed by left hemiparesis with plegia of the lower limb and left Horner's syndrome. Five days later the hemiparesis recovered while the patient developed hypoanaesthesia to cold stimuli that evoked painful burning dysaesthesia on the right side below the C4 level. MRI disclosed a discrete infarct in the left lateral aspect of the cord at C2 level concomitant to a left vertebral artery thrombosis. This limited infarct and the clinical symptoms suggest a hypoperfusion in the peripheral arterial system of the left hemicord, supplied both by the anterior and posterior spinal arteries. Cluster headache-like attack and persistent dysaesthesia to cold stimuli are discussed respectively in view of the central sympathetic involvement and partial spinothalamic system dysfunction.**

*(J Neurol Neurosurg Psychiatry* 1999;66:397-400)

Keywords: hemicord infarction; cluster headache attack; dysaesthesia; allodynia

The cervical cord is supplied by two arterial systems, central and peripheral, which overlap but are discrete. The first is dependent entirely on the single anterior spinal artery (ASA). The second, without clear cut boundaries, receives supplies from the ASA and both posterior spinal arteries.<sup>1</sup> Because the ASA is medial and dominant, unilateral cord infarctions are very rare. They may occur in the perfusion territory supplied by the ASA<sup>2-5</sup> as a result of the obstruction of either a duplicated ASA<sup>2</sup> or the obstruction of one of the sulcal arteries which arise from the ASA and turn alternatively left or right, to supply one side of the central cord.<sup>3</sup> Peripheral hemicord infarction may result from ischaemia in the territory of the ASA<sup>3</sup> or posterior spinal artery.<sup>6</sup> We report on a patient with a unilateral infarction limited to the left lateral column of the cervical cord in relation to a ver-

tebral artery thrombosis. The clinical feature was peculiar in that the cluster headache-like attack presented as the opening symptom and, thereafter, the occurrence of anaesthesia and dysaesthesia to cold stimuli (allodynia) that affected the right side below C4 became apparent.

**Case report**

A 54 year old man with a history of mild hypertension (treated with 50 mg Iosartan/day) and common migraine without known autonomic feature presented on 13 October 1997 with an abrupt boring and throbbing pain in the left retro-orbital region spreading to the jaw, and the supraorbital, and temporal regions. There were photophobia, abundant lacrimation, and redness of the left eye. The excruciating pain lasted 30 minutes, then improved and disappeared about 20 hours later. Half an hour after onset of the headache, the patient experienced paraesthesia of the left lower limb which progressed, within 3 hours, to weakness of the left foot. The next days, a left hemiparesis occurred. The patient was admitted to our department on 15 October 1997.

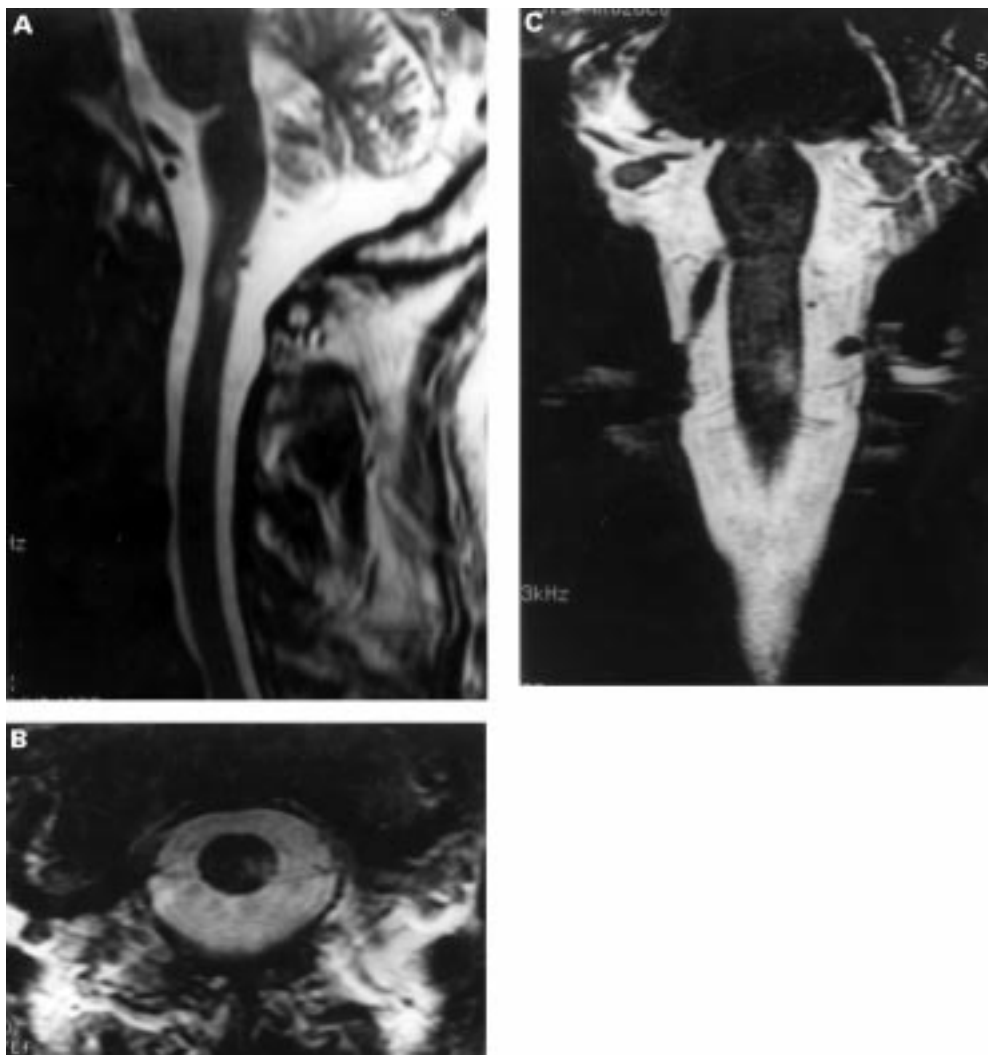
His arterial pressure was initially 160/100 mm Hg and general examination showed no abnormalities. Neurological examination disclosed a left Horner's syndrome and a flaccid left sided hemiparesis affecting the lower limb severely and partially the proximal part of the upper limb. The hand was slightly weak and the face was spared. Bilateral Babinski's signs were present. Light touch, vibration, and sense of position were normal. Pinprick and cold and warm thermal stimuli were perfectly discriminated on both sides although felt appreciably more strongly on the left. There was equal facial sensation to light touch, pain, and temperature, including symmetric corneal response, despite the patient having reported persistent soreness and left hypersensitivity of the face and head to touch since the initial attack of retro-orbital pain. Five days after onset, the hemiparesis cleared almost completely while the patient experienced unpleasant and painful right sided provoked dysaesthe-

**Service de Neurologie**  
V de la Sayette  
S Schaeffer  
G Defer

**Service de Neuroradiologie, CHU Côte de Nacre, Caen Cedex, France**  
F Leproux  
O Coskun

Correspondence to:  
Dr V de la Sayette, Service de Neurologie, CHU côte de Nacre, F14033 Caen Cedex, France.

Received 11 June 1998 and in revised form 14 September 1998  
Accepted 22 September 1998



MRI (GE-Signa 1.5 Tesla): (A) sagittal, (B) axial, and (C) coronal T2 weighted images ( $TR=5000$  ms;  $TE=105$  ms) of the cervical spinal cord 11 days after onset. Focal high intensity image in the left lateral aspect of the cord at C2. The lesion extends medially but both the anterior and posterior fasciculus are spared.

sia. At that time, examination of the patient's sensibility disclosed normal and symmetric sensations to light touch, vibration, sense of position, and pin prick. Temperature perception and discrimination were normal above C4. Below C4, on the right side, the thermal perception for warm stimuli ( $>28^{\circ}\text{C}$ ) was unchanged (quickly and strongly felt on the left side) and contrasted with more severe hypoesthesia (upper limb) and anaesthesia (trunk and lower limb) to cold stimuli ( $<28^{\circ}\text{C}$ ). Moreover, cold stimuli ( $<28^{\circ}\text{C}$ ) evoked severe dysaesthesia described as burning, aching sensations radiating around the place of stimulation. Any stimulus other than cold could elicit them.

Normal investigations included routine laboratory examinations, CT of the head, transoesophageal echocardiography, and Holter monitoring. Brain MRI was unremarkable except for a left punctiform low void vertebral artery. MRI of the cervical spine, 11 days after the onset, disclosed a spontaneous abnormally increased signal on T2 and proton density weighted images in the lateral aspect of the left cord at C2 level (figure). Vertebral angiography showed a thrombosis of the left vertebral

artery. A diagnosis of infarction in the left upper cervical hemicord was made. The patient was treated with heparin and subsequently fluindione. Four months later his motor strength fully recovered. A left Babinski's sign and Horner's syndrome persisted. The patient continued to complain of left soreness and hypersensitivity of the face and head and, above all, of a bitter, burning dysaesthesia to cold stimuli, refractory to carbamazepine, clonazepam, and amitriptyline.

#### Comment

The combination of neurological signs, left flaccid hemiparesis sparing the face with plegia of the lower limb, Horner's syndrome, and slight spinothalamic hypoesthesia on the contralateral side, suggests a lesion located in the periphery of the left lateral column of the cervical cord. A T2 weighted cervical MRI disclosed a focal high intensity signal within the left lateral aspect of the cord, at C2 level, consistent with a limited infarct of the hemicord.<sup>4,7</sup> Angiography documented further a left vertebral artery thrombosis that could correspond, although without certainty, to a dissection. Our

patient shared the main clinical features found in the ASA hemicord syndrome<sup>2-5</sup>—namely, Horner's syndrome and hemiparesis that progress over many hours on the side ipsilateral to the infarction while a spinothalamic hypoaesthesia develops on the contralateral side. None of these patients in the above mentioned studies had either posterior column loss or facial hypoaesthesia, both of which are relevant to posterior spinal artery syndrome.<sup>6</sup> Even though our patient is similar in many aspects to others, two particular points have to be emphasised: (1) the initial excruciating retro-orbital pain; (2) the limited anaesthesia and persistent dysaesthesia to cold stimuli which developed soon after the onset.

All the reported cases of cervical hemicord infarction began with severe pain that involved predominantly the neck<sup>2-5</sup> and often radiated to the shoulder or the upper limb. None of them presented with headache. On the contrary our patient never had cervicobrachial pain but developed extremely severe unilateral headache as an opening symptom. It could account for pain from arterial dissection<sup>8</sup> but, in this outlook, rather from a carotid than a vertebral artery dissection.<sup>9</sup> In return, the excruciating boring and throbbing pain in the left retro-orbital region, associated with autonomic features, lacrimation, and conjunctival injection, satisfied principally the criteria of cluster headache attack.<sup>8,10</sup> Nevertheless, as our patient experienced only a single episode of retro-orbital pain which contrasted with the striking rhythmicity of typical cluster headache attack, the generic terminology of trigeminal-autonomic cephalgia (TAC) seems more appropriate.<sup>11</sup> This kind of intense short lasting headache with autonomic features including cluster headache attack, chronic paroxysmal hemicrania, episodic paroxysmal hemicrania, and SUNCT syndrome (short lasting unilateral neuralgiform headache with conjunctival infection and tearing), shares a linked pathophysiology.<sup>11</sup> Trigeminal-autonomic cephalgia is likely to be the consequence of an activation of the trigeminal nerve and cranial parasympathetic nervous systems<sup>11-13</sup> through the trigeminal-autonomic reflex.<sup>11</sup> The finding presented here suggests a central mechanism for the initiation of attack although the causal relation with the lesion needs to be interpreted with caution. A dysfunction of the trigeminal system is doubtful as there was no clinical evidence of trigeminal nerve involvement whence the spinal nucleus is supplied by branches of the posterior spinal artery. Interestingly, the persistent residual soreness and hypersensitivity of the head and face to touch has been already reported in some patients after a cluster headache attack.<sup>10</sup> It might be postulated that the lesion of the central sympathetic pathway in the left cervical cord was the primary mechanism which allowed the attack to develop; as a consequence, the patient retained a residual Horner's syndrome. Indeed, there is abundant evidence of sympathetic dysfunction, whether peripheral or central, during the cluster period of headache.<sup>12,14-16</sup> The first phase of attack may include impaired sympathetic nervous activity

which should induce increased susceptibility to attack provocation.<sup>12</sup> Symptomatic attacks of cluster headache have been described in a wide variety of disorders, most of them located in the middle fossa close to the midline and the cavernous sinus region<sup>17</sup> or, more rarely, outside or inside the cervical spine.<sup>10</sup> Three cases might be considered as their lesions were located laterally near the medulla and upper cervical cord. They concern an upper cervical meningioma,<sup>18</sup> a vertebral artery aneurysm,<sup>19</sup> and a vertebral artery dissection.<sup>20</sup> The common mechanism for triggering attack in the above mentioned cases might be the trigeminal-autonomic activation from upper cervical segments which overlap and connect with the spinal trigeminal nucleus,<sup>18,20</sup> a hypothesis that should be considered in our own case.

The last particular point was the occurrence of painful dysaesthesia. This kind of burning stinging pain, which usually, accompanies dysfunctions of the spinothalamic pathway,<sup>21-23</sup> is very rare after cord lesions<sup>24</sup> especially spinal cord infarcts.<sup>21</sup> It can be provoked by non-noxious stimuli in the deafferented dermatomes (allodynia), either by thermal stimuli<sup>23</sup> or, in most cases, gentle touching. Therefore it is usually postulated that dysaesthesia might result from an afferent imbalance between an impaired spinothalamic system and an intact lemniscal sensory input.<sup>22</sup> Dysaesthesia in our patient could hardly correspond to this kind of mechanism as they were evoked only by cold stimuli. There was clinical evidence of partial involvement of the spinothalamic system as touch and pinprick were normally felt contrasting with hypaesthesia to thermal stimuli and above all anaesthesia (trunk and lower limb) to cold stimuli. Thus considering dysaesthesia in our patient in terms of imbalance within the spinothalamic system itself seems an attractive hypothesis. Interestingly dysaesthesia occurred while the patient recovered from hemiparesis and hypoaesthesia to pinprick and developed anaesthesia to cold stimuli. This response (dysaesthesia) suggests a functional rearrangement so that the cold stimuli could raise an inappropriate activation of pain message instead of cold thermic sensation. In this way, Triggs and Beric<sup>22</sup> considered such an alternative explanation as did Nathan and Smith,<sup>24</sup> who suggested that dysaesthesia may result from selective lesions of the spinothalamic tract sparing the spino-reticulothalamic connections.

Considering the anatomical organisation of the two spinothalamic pathways (anterior and posterior tracts) and the topographical arrangement of the fibres that they convey<sup>25</sup> (crude tactile, pain, and thermal sensations), clinical symptoms suggest, in our patient, lesioning in the most dorsal and superficial part of the spinothalamic tract. This accords well with the initial hemiparesis with plegia of the lower limb which, in turn, also indicate (considering the somatotopic arrangement of the fibres within the corticospinal tract) a superficial lesion of the lateral cord. MRI confirmed the small size of the lesion, which was

confined to the lateral fasciculus and limited in height. The deep extension could correspond to oedema<sup>7</sup> rather than to ischaemia. This suggests a hypoperfusion in a “watershed area” between both anterior and posterior spinal peripheral arterial systems rather than ischaemia in the perfusion territory of a sulcal artery or a duplicated ASA. This hypothesis agrees with the common origin of the anterior and posterior spinal arteries which both arise from the vertebral artery.

- 1 Lazorthes G. Pathology, classification and clinical aspects of vascular diseases of the spinal cord. In: Vinken PJ, Bruyn GW, eds. *Handbook of clinical neurology*. Vol 12. Oxford: Elsevier, 1972:492–506.
- 2 Wells CEC. Clinical aspects of spinovascular disease. *Proceedings of the Royal Society of Medicine* 1966;59:790–6.
- 3 Decroix JP, Ciaudo-Lacroix C, Lapresle J. Syndrome de Brown-Séquard dû à un infarctus spinal. *Rev Neurol* 1984; 140:585–6.
- 4 Millandre L, Martini P, Bourrin JC, et al. Infarctus unilatéral de la moelle cervicale. Deux cas identifiés par IRM. *Rev Neurol* 1993;149:299–302.
- 5 Baumgartner RW, Waespe W. ASA syndrome of the cervical hemicord. *Eur Arch Psychiatry Clin Neurosci* 1992;241:205–9.
- 6 Gutowski NJ, Murphy RP, Beale DJ. Unilateral upper cervical posterior spinal artery syndrome following sneezing. *J Neurol Neurosurg Psychiatry* 1992;55:841–3.
- 7 Takahashi S, Yamada T, Ishii K, et al. MRI of ASA syndrome of the cervical spinal cord. *Neuroradiology* 1992; 34:25–9.
- 8 Headache Classification Committee of the International Headache Society. Classification and diagnostic criteria for headache disorders, cranial neuralgias and facial pain. *Cephalgia* 1988;8(suppl 7):1–96.
- 9 Biousse V, Tehindrazanarivelo A, Bousser MG. The secondary headache: carotid and vertebral artery pain. In: Olesen J, ed. *The headaches*. New-York: Raven Press, 1993:663–9.
- 10 Sjaastad O. Cluster headache. In: F Clifford Rose, ed. *Handbook of clinical neurology*. Vol 48. Amsterdam: Elsevier, 1986:217–44.
- 11 Goadsby PJ, Lipton RB. A review of paroxysmal hemicranias, SUNCT syndrome and other short-lasting headaches with autonomic feature, including new cases. *Brain* 1997;120:193–209.
- 12 Kudrow L. The pathogenesis of cluster headache. *Curr Opin Neurol* 1994;7:278–82.
- 13 Goadsby PJ, Edvinsson L. Human in vivo evidence for trigeminovascular activation in cluster headache. Neuropeptide changes and effects of acute attacks therapies. *Brain* 1994;117:427–34.
- 14 Schoenen J, Maertens de Noordhout A. The role of the sympathetic nervous system in migraine and cluster headache. In: Olesen J, Edvinsson L, eds. *Basics mechanisms of headache*. Amsterdam: Elsevier, 1988:393–410.
- 15 Russell D, Fancuillacci M. Tension-type headache, cluster headache, and miscellaneous headaches: neurophysiology, hemodynamics, trigger factors, cerebrospinal fluid, and psychological factors. In: Olesen J, ed. *The headaches*. New-York: Raven Press, 1993:561–8.
- 16 Havelius U, Heuck M, Milos P, et al. Ciliospinal reflex response in cluster headache. *Headache* 1996;36:568–73.
- 17 Hardebo JE, Suzuki N. Tension-type headache, cluster headache and miscellaneous headache: anatomy and pathology. In: Olesen J, ed. *The headaches*. New-York: Raven Press, 1993:547–9.
- 18 Kuritzky A. Cluster headache-like pain caused by an upper cervical meningioma. *Cephalgia* 1984;4:185–6.
- 19 West P, Todman D. Chronic cluster headache associated with a vertebral artery aneurysm. *Headache* 1991;31:210–2.
- 20 Cremer PD, Halmagyi GM, Goadsby PJ. Secondary cluster headache responsive to sumatriptan. *J Neurol Neurosurg Psychiatry* 1995;59:633–4.
- 21 Central pain. In: Binica JJ, ed. *The management of pain*. Vol 1. London: Lea and Febiger, 1990:264–85.
- 22 Triggs W, Beric A. Sensory abnormalities and dysaesthesias in the anterior spinal artery syndrome. *Brain* 1992;115: 189–98.
- 23 Peyron R, Garcia-Larrea L, Grégoire MC, et al. Allodynia after lateral-medullary (Wallenberg) infarct. A PET study. *Brain* 1998;121:345–56.
- 24 Nathan PW, Smith MC. Dysesthésie après cordotomie. *Médecine et Hygiène* 1984;42:1788–90.
- 25 Warwick R, Williams PL, eds. *Gray's anatomy*. Edinburgh: Longman, 1973: 816–24.