

SHORT REPORT

Novel mutation of the P₀ extracellular domain causes a Déjérine-Sottas syndrome

Gian Maria Fabrizi, Tiziana Cavallaro, Michela Morbin, Alessandro Simonati, Federica Taioli, Nicolo' Rizzuto

Abstract

A patient is described with a Déjérine-Sottas syndrome caused by a novel heterozygous Cys(98)Tyr mutation in the extracellular domain of the major peripheral myelin protein zero (P₀ex). Homotypical interactions between P₀ex tetramers of apposed extracellular faces of the Schwann cell membrane play a crucial part in myelin compaction. The amino acid change disrupts a unique disulphide bond that stabilises the immunoglobulin-like structure of P₀ex and it is predicted to cause severe de-hypomyelination through dominant negative effects on the wild type protein.

(J Neurol Neurosurg Psychiatry 1999;66:386-389)

Keywords: Déjérine-Sottas syndrome; P₀; myelin

The hereditary demyelinating neuropathies include the usually autosomal dominant Charcot-Marie-Tooth disease type 1 (CMT-1) and the sporadic, presumably recessive, Déjérine-Sottas syndrome (DSS).¹ CMT-1 manifests in the first two decades with peroneal atrophy and reduced nerve conduction velocities (NCVs). DSS has an infantile onset, faster disease progression, and extremely slow NCVs (motor NCVs <6 m/s). In CMT-1, nerve biopsy discloses de-remyelination with onion bulbs; in DSS, hypomyelination predominates.¹⁻² CMT1 and DSS are caused by allelic heterozygous mutations that affect the genes of the peripheral myelin proteins PMP22 (CMT-1A and DSD-A) or P₀ (CMT-1B and DSD-B). De novo mutations cause sporadic cases.³⁻⁴

P₀ is the major structural protein of peripheral myelin. It contains a glycosylated immunoglobulin-like extracellular domain (P₀ex), a single membrane spanning domain, and a basic intracellular domain.⁵ P₀ex plays a crucial part in the compaction of myelin at the intraperiod line,^{6,7} whereas the cytoplasmic domain intervenes to form the major dense line.⁸

We describe a patient with DSS harbouring a novel heterozygote Cys(98)Tyr substitution in P₀ex. The mutation disrupts the unique disulphide bond that stabilises the immuno-

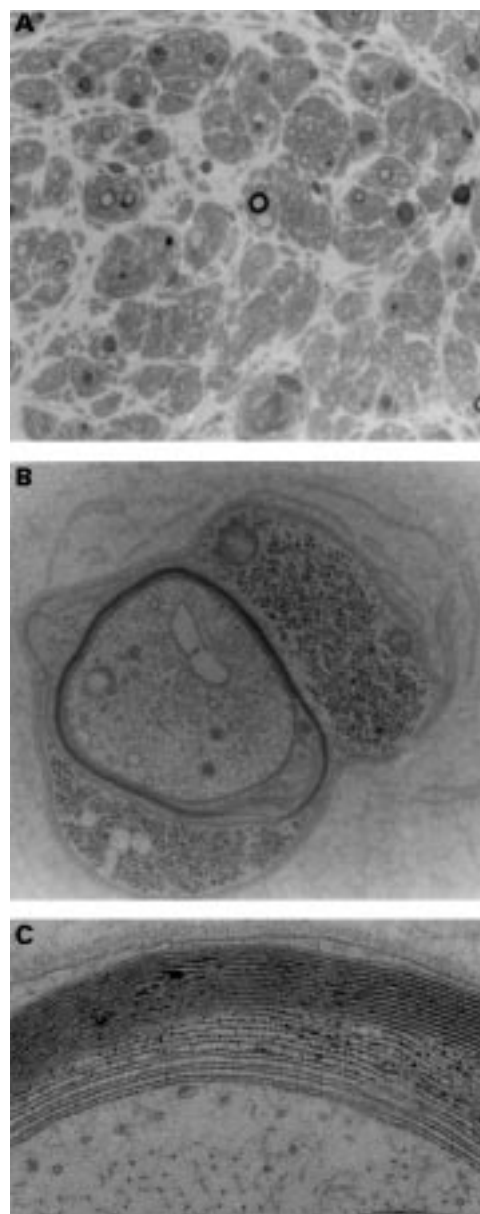


Figure 1 (A) Semithin section of a sural nerve specimen from the patient showing the severe loss of fibres. Residual fibres consist of thinly myelinated or naked axons ($\times 550$). (B) Electron micrograph of a remyelinating fibre surrounded by few fragmented Schwann cell basal laminae ($\times 18\,000$). (C) High magnification of a fibre with uncompactness of the inner lamellae of the myelin sheath ($\times 64\,000$).

Department of Neurological and Visual Sciences, Section of Clinical Neurology, University of Verona, Italy

G M Fabrizi
T Cavallaro
M Morbin
A Simonati
F Taioli
N Rizzuto

Correspondence to:
Professor Nicolo' Rizzuto,
Department of Neurological
and Visual Sciences, Section
of Clinical Neurology,
University of Verona,
Policlinico Borgo Roma, via
delle Menegone 37134,
Verona, Italy. Telephone
0039 45 8074285; fax 0039
45 585933; email
rizzuto@borgoroma.univr.it

Received 15 June 1998 and
in revised form
9 September 1998
Accepted 22 September
1998

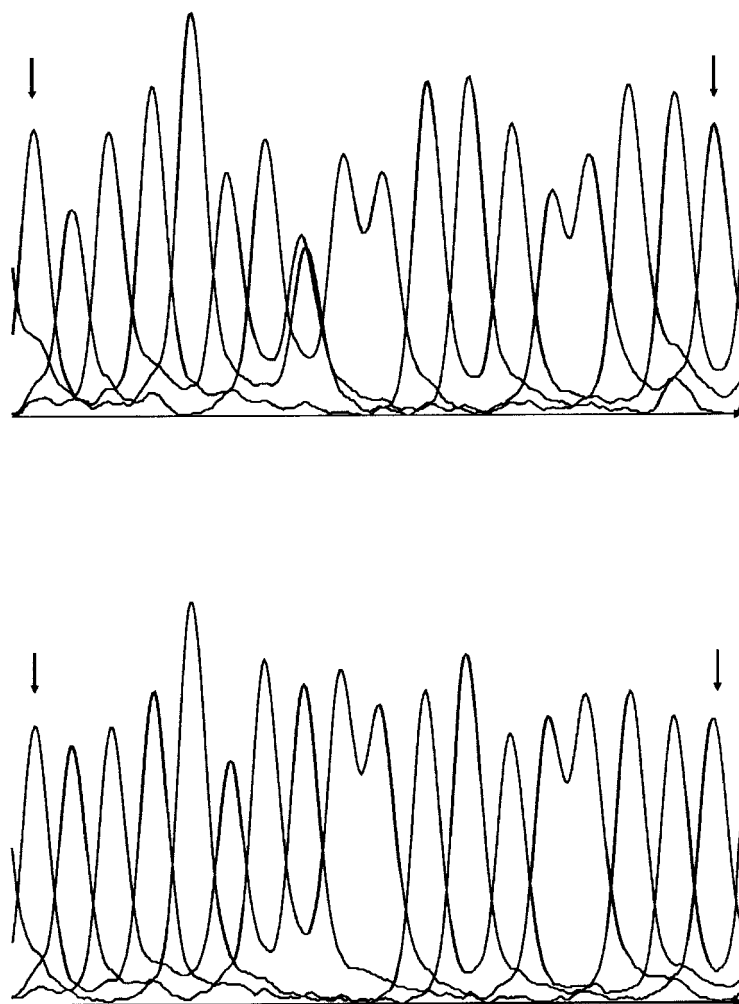


Figure 2 Fluorograms from direct sequencing of the antisense strand of the P_0 exon 3 amplified from genomic DNA. Nucleotide numbering refers to the P_0 cDNA, starting at the initiation site of translation (nucleotides from 370 to 387 are shown in the 3' to 5' direction). (A) the patient's DNA. The arrow and the Y indicate the heterozygous C to T transition (G to A for the sense strand) at nucleotide position 380 (codon 127). The mutation leads to a Cys(98) Tyr substitution in the mature protein, which lacks the first 29 aminoacids of the signal peptide. (B) the wild type sequence in a patient with non-duplicated CMT1.

globulin-like folding of the molecule,⁵ and it is predicted to exert a dominant negative effect on the product of the wild type allele.

Patient and methods

CASE REPORT

The patient, a 29 year old man, is the only child of healthy non-consanguineous parents. The pregnancy and birth were normal. The motor milestones were delayed and he could not walk alone until he was 10 years old. Examination at the age of 24 years disclosed short stature, prominent kyphoscoliosis, pes cavus, bilateral ptosis, and paresis of the left medial rectus muscle. Gait was stepping and ataxic. Muscle wasting and weakness were generalised with prominent distal involvement. Somatic and deep sensations were impaired at the distal lower limbs. Tendon reflexes were absent. Nerve conduction studies disclosed extreme slowing of motor and sensory NCVs in all nerves tested. At the left ulnar nerve values were as follows: motor NCV=3.8 m/s; distal latency=11.08 ms; compound muscle action

potential (cMAP)=0.4 mV. Sensory action potential (SAP) was unrecordable at the right median nerve. No cMAP was obtained by stimulation of the common peroneal nerve. Electromyography showed denervation.

PATHOLOGY

Biopsy specimens from the right sural nerve were processed according to standard procedures for light and electron microscopic examination and teased fibre analysis. The density and the histogram of the myelinated fibres were obtained from randomly chosen nerve samples covering a surface of about 0.11 mm². The g-ratio was obtained from more than 30 micrographs enlarged $\times 8500$.

MOLECULAR ANALYSIS

Genomic DNA samples were extracted from blood according to routine procedures. Pulsed field gel electrophoresis (PFGE) analysis of the 17p11.2p12 duplication was done as previously described.⁹

The six P_0 exons and related exon-intron boundaries were polymerase chain reaction (PCR) amplified from the proband's DNA sample according to Hayasaka *et al.*¹⁰ The PCR reactions were performed using one biotinylated and one standard primer. The biotinylated single stranded PCR products were captured on streptavidin coated combs and direct sequenced using the T7 DNA polymerase and Cy5 labelled nested primers (AutoLoad Solid Phase Sequencing Kit, Pharmacia-Biotech). Sequence analysis was performed on an ALFexpress DNA sequencer (Pharmacia-Biotech).

Rapid mutation detection was performed on DNA samples from the patient, his unaffected parents, and 100 unrelated control subjects including 30 patients with CMT1 with the 17p11.2-p12 duplication, 10 non-duplicated patients with CMT1, and 60 healthy subjects. A 143 bp fragment corresponding to the P_0 exon 3 was amplified by PCR using the forward primer 5'-TCCATTGTCATACACAACC-TAGACTACAGTGGCAATG-3' and the reverse primer 5'-TTGTCCCCATCCCTTC-TCACACCTTTTCAAAGACATACAGC-CTGACC-3'. The underlined nucleotides represent two mismatches (G for A and C for G) to the published sequences.¹⁰ The PCR products were digested with *MaeIII* (Boehringer) and electrophoresed through a 12% non-denaturing polyacrylamide gel. The wild-type allele was cut into two fragments of 93 and 50 bp whereas the mutant allele remained uncut.

Results

PATHOLOGICAL FINDINGS

Light microscopy disclosed features of demyelinating neuropathy with severely reduced myelinated fibre density (1164/mm²), not associated with Schwann cell hypertrophy (fig 1A). Most axons had thin myelin or no myelin. The remaining myelinated fibres were small or middle sized: the histogram showed a unimodal, skewed to the left distribution; 13% of fibres were ≥ 6 μ m in diameter. On teased fibres, all internodes disclosed extensive paranodal or

segmental de-remyelination. Ultrastructural examination confirmed the prevalence of naked axons or early remyelinating axons (fig 1 B). In some fibres the inner lamellae of the myelin sheath were uncompacted (fig 1 C). Almost all fibres were surrounded by collagen containing sparse fragmented Schwann cell cytoplasmic processes as well as empty basal lamina. No evidence was found of classic or of basal lamina onion bulbs. The mean g-ratio (0.88 (SD 0.06); normal values: 0.66–0.67) corresponded to the severe hypomyelination.

MOLECULAR ANALYSIS

PFGE analysis excluded the common CMT1A duplication at chromosome 17p11.2–p12.

Sequence analysis showed a novel heterozygous G to A transition at nucleotide position 380 in the P₀ exon 3 that abolishes a *MaeIII* site (fig 2). A *MaeIII* restriction analysis excluded the presence in the healthy parents and in 100 unrelated controls indicating that the mutation originated de novo and it was associated with disease. The nucleotide change leads to a Cys(98)Tyr substitution in the extracellular domain of the mature protein, which lacks the first 29 aminoacids of the signal peptide.¹⁰ The amino acid substitution is predicted to disrupt the unique disulphide bond that links Cys21 to Cys98.

Discussion

The patient fitted the clinical and electrophysiological criteria for DSS.¹ A peculiar sign was the impairment of extraocular muscles that cannot be ascribed definitely to the disorder. Involvement of the cranial nerves is not a classic symptom of DSS¹; we note, however, that Tyson *et al* recently reported in some patients weakness of the facial and bulbar muscles as well as sensorineural deafness.⁴ Nerve biopsy was also consistent with DSS, disclosing extensive de-remyelination with severe loss of large myelinated fibres and extremely thin myelin sheaths.^{1,2} Remarkable findings were the absence of significant Schwann cell hyperplasia represented either by classic or basal lamina onion bulbs and decompaction of the inner lamellae of the myelin sheath in some fibres. Variations in the response of the Schwann cell in patients with DSS probably reflect the genetic heterogeneity of DSS and the existence of different pathogenetic mechanisms. Uncompacted myelin was seen previously in association with other point mutations of P₀ex and it has been related to an alteration of the adhesive properties of the molecule.

Molecular analysis disclosed a novel heterozygous G to A transition at nucleotide position 380 in the P₀ exon 3 that causes a Cys(98)Tyr substitution in P₀ex. The structure of P₀ex resembles that of a single variable region of the immunoglobulin heavy chains and of other cell adhesion proteins involved in homotypic binding interactions.⁵ P₀ex crystal is made up of a series of 10 antiparallel β strands arranged into two facing β sheaths and a unique disulphide bond between Cys21 and Cys98 unites the non-consecutive aminoacid sequences carried on the two β sheaths.¹² Tetramers of P₀ex ema-

nating from the extracellular surfaces of Schwann cell membranes interact with tetramers of apposed extracellular membrane surfaces to form the myelin intraperiod line.¹³ Both the disulphide bond and glycosylation are crucial for membrane adhesion.^{14,15} Thus the Cys(98)Tyr mutation is predicted to alter heavily the function of P₀ex by destroying the disulphide bond between Cys21 and Cys98.⁵

The patient reported on with DSS associated with Cys(98)Tyr substitution is similar to a model of Chinese hamster ovary (CHO) cells that express a mutant P₀ lacking the disulphide bond because of an engineered Cys(21)Ala substitution.¹⁴ Unlike CHO cells expressing the wild-type protein, those cells do not aggregate, although the lack of the disulphide bond does not completely disrupt the tertiary structure of P₀, allowing the full glycosylation of the engineered protein and its arrival at the cell surface.¹⁴ However, we speculate that the pathogenetic effects of Cys(98)Tyr in vivo do not reflect merely a loss of the adhesive properties of P₀ex. So far, only three P₀ex mutations have been reported to cause DSS in heterozygosity; by contrast, about 20 mutations caused CMT1B.^{3,4} Warner *et al* hypothesised that less severe phenotypes of demyelinating neuropathy (CMT1B) are caused by loss-of-function alleles, whereas more severe phenotypes (DSS) are caused by dominant negative alleles.³ Straightforward examples were represented by alternative mutations occurring at aminoacid residues 34 and 69.³ Arg(69)Cys^{11,12} and Ser(34)Cys¹⁰ were associated with DSS; based on the P₀ex crystal,¹³ Arg69 and Ser34 are thought to introduce outwardly pointing thiols that may form detrimental disulphide aggregates with the wild-type partner molecules.³ By contrast, Arg(69)His,^{11,12} Arg(69)Ser,¹¹ Ser(34)Phe,¹⁶ and Ser(34)del,^{12,17} which may lead to functional or structural loss of P₀, resulted in CMT1B. An Asn(93)Ser substitution caused simply a CMT1B phenotype, although preventing the protein from glycosylation.¹⁸ However, this pathogenetic model raised some criticism,¹⁹ and it could not be extended to all of the cases, mainly because of the existence of apparently overlapping patients with DSS-CMT1B with debatable pathological definition.²⁰

Our report strongly supports the hypothesis of Warner *et al*.³ As the lack of the disulphide bond in vitro did not prevent the glycosylation and assembly of the P₀ex containing the Cys(21)Ala substitution,¹² it may be predicted that, in the presented patient, the mutant P₀ containing the Cys(98)Tyr substitution is similarly incorporated in the P₀ex tetramers. The Cys21 residue, left orphan by the mutation, remains free to poison the wild-type P₀ex molecules leading to severe de-hypomyelination.

The work was supported by the Telethon-Italy (grant No 750 to NR) and by the Giunta Regione Veneto-Ricerca Sanitaria Finalizzata (grant No 628-03-95 to AS). We are indebted to Sandra Galiazzo Rizzuto for invaluable technical assistance.

1 Dyck PJ. Inherited neuronal degeneration and atrophy affecting peripheral motor, sensory, and autonomic neurons. In: Dyck PJ, Thomas PK, Lambert EH, eds. *Peripheral neuropathy*. Philadelphia: WB Saunders, 1975:825–67.

- 2 Gabreëls-Festen AAWM, Gabreëls FJM, Jennekens FGI, *et al.* The status of HMSN type III. *Neuromusc Disord* 1994;4:63-9.
- 3 Warner LE, Hilz MJ, Appel SH, *et al.* Clinical phenotypes of different MPZ (P₀) mutations may include Charcot-Marie-Tooth type 1B, Dejerine-Sottas, and Congenital Hypomyelination. *Neuron* 1996;17:451-60.
- 4 Tyson J, Ellis D, Fairbrother U, *et al.* Hereditary demyelinating neuropathy of infancy. A genetically complex syndrome. *Brain* 1997;120:47-63.
- 5 Lemke G, Axel R. Isolation and analysis of the gene encoding peripheral myelin protein zero. *Neuron* 1988;1:73-8.
- 6 D'Urso D, Brophy PJ, Staugaitis SM, *et al.* Protein zero of peripheral nerve myelin: biosynthesis, membrane insertion, and evidence for homotypic interaction. *Neuron* 1990;2:449-60.
- 7 Filbin MT, Walsh FS, Trapp BD, *et al.* Role of myelin P₀ protein as a homophilic adhesion molecule. *Nature* 1990;344:871-2.
- 8 Ding Y, Brunden KR. The cytoplasmic domain of myelin glycoprotein P₀ interacts with negatively charged phospholipid bilayers. *J Biol Chem* 1994;269:10764-70.
- 9 Lorenzetti D, Pareyson D, Sghirlanzoni A, *et al.* A 1.5-Mb in 17p11.2-p12 is frequently observed in Italian families with hereditary neuropathy with liability to pressure palsies. *Am J Hum Genet* 1995;56:91-8.
- 10 Hayasaka K, Himoro M, Sawaishi Y, *et al.* De novo mutation of the myelin protein zero gene in Dejerine-Sottas disease (hereditary motor and sensory neuropathy type III). *Nat Genet* 1993;5:266-8.
- 11 Meijerink PHS, Hoogendijk JE, Gabreëls-Festen AAWM, *et al.* Clinically distinct codon 69 mutations in major myelin protein zero in demyelinating neuropathies. *Ann Neurol* 1996;40:672-5.
- 12 Gabreëls-Festen AAWM, Hoogendijk JE, Meijerink PHS, *et al.* Two divergent types of nerve pathology in patients with different P₀ mutations in Charcot-Marie-Tooth disease. *Neurology* 1996;47:761-5.
- 13 Shapiro L, Doyle JP, Hensley P, *et al.* Crystal structure of the extracellular domain from P₀, the major structural protein of peripheral nerve myelin. *Neuron* 1996;17:435-49.
- 14 Zhang K, Filbin MT. Formation of a disulfide bond in the immunoglobulin domain of the myelin P₀ protein is essential for its adhesion. *J Neurochem* 1994;63:367-70.
- 15 Filbin MT, Tennekon GI. Homophilic adhesion of the myelin P₀ protein requires glycosylation of both molecules in the homophilic pair. *J Cell Biol* 1993;122:451-9.
- 16 Blanquet-Grossard F, Pham-Dinh, Dautigny A, *et al.* Charcot-Marie-Tooth type 1B neuropathy: third mutation at serine 63 codon in the major peripheral myelin glycoprotein P₀ gene. *Clin Genet* 1995;48:281-3.
- 17 Kulkens T, Bolhuis PA, Wolterman RA, *et al.* Deletion of the serine 34 codon from the major peripheral myelin protein P₀ gene in Charcot-Marie-Tooth disease type 1B. *Nat Genet* 1993;5:35-9.
- 18 Blanquet-Grossard F, Pham-Dinh D, Dautigny A, *et al.* Charcot-Marie-Tooth type 1B. A mutation at the single glycosylation site in the major peripheral myelin glycoprotein P₀. *Hum Mutat* 1996;8:185-6.
- 19 Scherer SS. Molecular genetics of demyelination: new wrinkles on an old membrane. *Neuron* 1997;18:13-16.
- 20 Komiyama A, Ohnishi A, Izawa K, *et al.* De novo mutation (Arg98Cys) of the myelin P₀ gene and uncompactness of the major dense line of the myelin sheath in a severe variant of Charcot-Marie-Tooth disease type 1B. *J Neurol Sci* 1997;149:103-9.