

# Pontine lesions mimicking acute peripheral vestibulopathy

Frank Thömke, Hanns Christian Hopf

## Abstract

**Objectives**—Clinical signs of acute peripheral vestibulopathy (APV) were repeatedly reported with pontine lesions. The clinical relevance of such a mechanism is not known, as most studies were biased by patients with additional clinical signs of brainstem dysfunction.

**Methods**—Masseter reflex (MassR), blink reflex (BlinkR), brainstem auditory evoked potentials (BAEPs), and DC electro-oculography (EOG) were tested in 232 consecutive patients with clinical signs of unilateral APV.

**Results**—Forty five of the 232 patients (19.4%) had at least one electrophysiological abnormality suggesting pontine dysfunction mainly due to possible vertebrobasilar ischaemia (22 patients) and multiple sclerosis (eight patients). MassR abnormalities were seen in 24 patients, and EOG abnormalities of saccades and following eye movements occurred in 22 patients. Three patients had BlinkR-R abnormalities, and one had delayed BAEP waves IV and V. Clinical improvement was almost always (32 of 34 re-examined patients) associated with improvement or normalisation of at least one electrophysiological abnormality. Brain MRI was done in 25 of the 44 patients and confirmed pontine lesions in six (two infarcts, three inflammations, one tumour).

**Conclusions**—Pontine dysfunction was suggested in 45 of 232 consecutive patients with clinical signs of APV on the basis of abnormal electrophysiological findings, and was mainly attributed to brainstem ischaemia and multiple sclerosis. The frequency of pontine lesions mimicking APV is underestimated if based on MRI established lesions only.

(*J Neurol Neurosurg Psychiatry* 1999;66:340-349)

**Keywords:** acute peripheral vestibulopathy; vestibular neuritis; brainstem lesions; masseter reflex; electro-oculography

Acute peripheral vestibulopathy (APV), also called “vestibular neuritis”, “vestibular neuronitis”, “labyrinthitis”, or “neurolabyrinthitis”, is a clinical syndrome characterised by vertigo and vomiting, falls, and past pointing towards the affected side; horizontal-rotatory, direction fixed spontaneous nystagmus towards the unaffected side; and unilateral canal paresis with normal hearing.<sup>1-3</sup> Although the aetiology remains uncertain in most patients, it is usually

attributed to viral inflammation or ischaemia of the extra-axial vestibular portion of the eighth nerve, or the labyrinth, or both.<sup>1-3</sup> There are, however, several studies indicating pontine dysfunction as a cause of APV. These studies were based on abnormal saccadic or pursuit eye movements,<sup>4-6</sup> stapedius, or masseter reflex abnormalities,<sup>7,8</sup> and MRI established lesions involving the region of the intrapontine vestibular nerve, the medial and lateral vestibular nuclei, or both.<sup>9-11</sup> Some of these reports, however, were biased by the inclusion of patients with additional clinical signs of brainstem dysfunction.<sup>4-6,8,9,11</sup> We report our 13 year experience based on 45 out of 232 consecutive patients with APV (without additional clinical signs of brainstem disease), who had electrophysiological abnormalities indicating responsible pontine lesions.

## Patients and methods

DC electro-oculography (EOG), masseter reflex (MassR), blink reflex (BlinkR), and brainstem auditory evoked potentials (BAEPs) were examined routinely in 232 unselected patients with clinical signs of unilateral APV seen over a 13 year period. Diagnosis of APV was based on (a) sustained vertigo (at least for 24 hours) with nausea, or vomiting, or both; (b) horizontal-rotatory, direction fixed spontaneous nystagmus enhanced or only visible by Frenzel's lenses or during EOG recordings with closed eyes; (c) past pointing, or falling, or both to the direction opposite to nystagmus fast phases; (d) clinically unimpaired hearing function on the affected side; (e) unresponsiveness or hyporesponsiveness of one horizontal semicircular canal during bithermal caloric testing, and (f) unimpaired fixation suppression of the vestibular nystagmus during bithermal caloric testing (maximum slow phase velocity with open eyes/maximum slow phase velocity with closed eyes <0.7). Clinical and electrophysiological examinations were done within 7 and 10 days, respectively after onset of vertigo.

Diagnosis of a presumed vascular origin of the APV was based on (a) sudden onset; (b) presence of at least one relevant risk factor for the development of cerebrovascular diseases (diabetes, hypertension, previous strokes or transient ischaemic attacks, atrial fibrillation, heavy smoking, hypercholesterolaemia, signs of general arteriosclerosis); and (c) subsequent improvement or recovery. Multiple sclerosis was diagnosed according to the criteria given by Poser *et al*<sup>12</sup> and Paty *et al*.<sup>13</sup>

Electrophysiological abnormalities in favour of pontine lesions were found in 45 patients. None had additional abnormal clinical findings

Department of  
Neurology,  
University of Mainz,  
Langenbeckstrasse 1,  
D-55101 Mainz,  
Germany  
F Thömke  
H C Hopf

Correspondence to:  
Dr Frank Thömke,  
Neurologische  
Universitätsklinik,  
Langenbeckstrasse 1,  
D-55101 Mainz, Germany.  
Telephone 0049 6131  
177194; fax 0049 6131  
173271.

Received 18 November 1997  
and in final form  
10 August 1998  
Accepted 22 September 1998

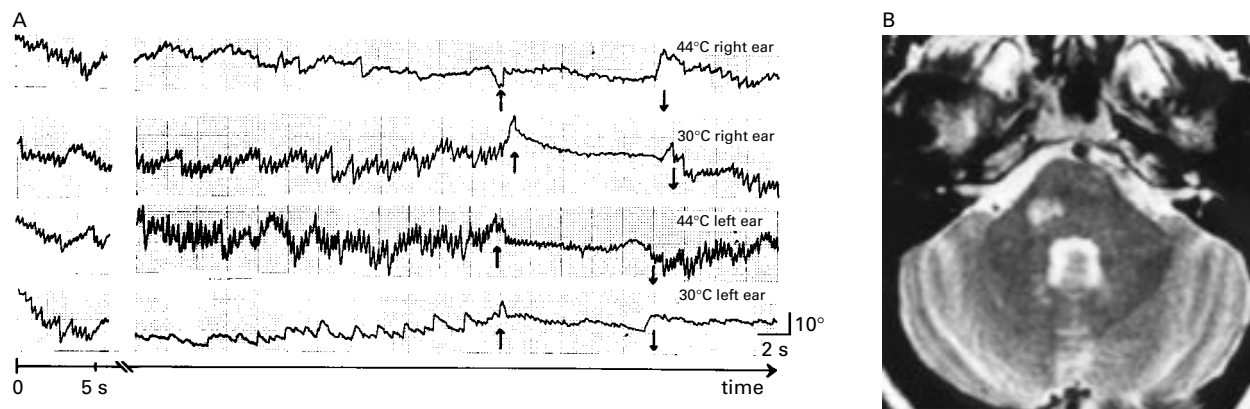


Figure 1 (A) Bithermal caloric testing in patient 25 with right sided vestibular paresis as the presenting sign of multiple sclerosis. Spontaneous nystagmus to the left (about  $24^{\circ}/s$ ) ceased for some seconds, but was not reversed by warm water irrigation of the right ear, and was almost unchanged ( $27^{\circ}/s$ ) after cold water irrigation of the right ear. Traces are shown from the left eye; 0=the start of warm or cold water irrigation; 90 s=90 s after the start of the respective irrigation; arrows=eye opening (up) and eye closure (down). (B) T2 weighted MRI of the same patient documenting an ipsilateral pontine lesion involving the region of the intrapontine vestibular nerve.

except for signs of a distal symmetric sensory neuropathy in three diabetic patients, reduced visual acuity in one eye from a previous optic neuritis in a patient with multiple sclerosis, and bilaterally increased deep tendon reflexes known from a previous myelitis in another patient with multiple sclerosis. In all patients, the vertigo improved during the first week. Thirty four patients were re-examined within 10 days to 10 weeks; all had improved from clinical signs of APV (spontaneous nystagmus, past pointing, tendency to fall). Brain MRI was done in 25 and CT in 14 of the 44 patients.

#### EOG

Horizontal eye movements were recorded separately for either eye with surface electrodes placed near the outer and inner canthi of the eyes (bandwidth 0–40 Hz), and documented by a linear ink jet writer or a polygraph (paper speed 10 and 100 mm/s).

#### Voluntary saccades

Patients were asked to refixate between light spots projected at random intervals on a screen at a distance of 1.2 m. Mean peak velocities were evaluated graphically from the steepest part of the record (100 mm/s) from six  $30^{\circ}$  saccades from the primary position. (Normal range (50 healthy volunteers): 320 to  $640^{\circ}/s$  for  $30^{\circ}$  abduction saccades, 335 to  $670^{\circ}/s$  for  $30^{\circ}$  adduction saccades, interocular difference  $<35^{\circ}/s$ .) Hypometric (undershooting) saccades were considered abnormal in patients with a constant dysmetria exceeding at least 20% of the amplitude of the saccade.

#### Optokinetic nystagmus

An alternating black and white stripe pattern (each stripe covered a visual angle of  $7^{\circ}$ ) moved across the screen at 20, 40, and  $60^{\circ}/s$ . The gain (velocity of following eye movements/target velocity) was evaluated graphically from 10 successive nystagmic beats. (Normal gain values (50 healthy volunteers; target velocity:  $60^{\circ}/s$ ):  $>0.7$ ; right/left-difference  $<0.15$ .)

#### Smooth pursuit

Stimulus was a sinusoidally swinging laser spot (0.3 Hz, peak to peak amplitude:  $30^{\circ}$ ).

Interruption by small saccades (=saccadic pursuit eye movements) was considered abnormal.

#### Bithermal caloric testing

This involved irrigation of either ear with 200 ml water within 30 seconds at  $44^{\circ}\text{C}$  and  $30^{\circ}\text{C}$  (intervals 5 minutes). Responses were recorded with closed eyes. Fixation suppression was assessed by eye opening when vestibular nystagmus was maximal. Maximum slow phase velocity of vestibular nystagmus was evaluated graphically from the recording to quantify the responses according to standard formulas. (see appendix and Baloh and Honrubia<sup>14</sup>) For quantification of vestibular paresis, we subtracted the value and direction of spontaneous nystagmus from the patient's warm and cold responses. (For example, patient 25 had a  $24^{\circ}/s$  spontaneous nystagmus to the left, which ceased for some seconds after right sided warm water irrigation, and increased to  $69^{\circ}/s$  after left sided warm water irrigation (fig 1). This was interpreted as a  $24^{\circ}/s$  response to the right, and a  $45^{\circ}/s$  to the left.) Findings were considered abnormal for vestibular paresis  $>25\%$ , and directional preponderance  $>30\%$ .

#### MASS R AND BLINK R

Examinations were performed with commercially available systems (MassR: Toennies, Multiliner; BlinkR: Medelec MS 6). The MassR was elicited by a brisk tap on the patient's jaw with a reflex hammer. The recording was triggered at the moment of the mechanical tap by a signal from a commercially available piezo-electric element mounted in the hammer. The reflex was recorded simultaneously on both sides with surface electrodes placed over the muscle belly 25 mm above the margin of the mandible (recording electrode), and over the zygoma at the lateral edge of the orbit (reference electrode) (bandwidth 20–2000 Hz). Latency refers to the onset of the EMG response, and mean latencies were calculated from 10 successive events. Normal MassR latencies are given in table 1. These latencies and their variances with follow up were repeatedly re-evaluated and confirmed in more than 200 other volunteers (unpublished

Table 1 Normal latencies of the masseter reflex (MassR), and the R<sub>1</sub>-component of the blink reflex (Blink-R<sub>1</sub>)

	Mean latency	2.5 SD
MassR:		
Age <40 years	6.9 (7.9) ms	1.0 (0.8) ms
Age >40 years	7.6 (8.5) ms	1.3 (1.2) ms
right/left difference	0.15 ms	0.3 ms
Blink-R <sub>1</sub> :		
Age <40 years	10.4 ms	0.8 ms
Age >40 years	10.7 ms	0.8 ms
right/left difference	0.5 ms	0.7 ms

Examinations were done with commercially available systems. MassR: Toennies, Multiliner; BlinkR: Medelec MS 6. The values are based on 57 (MassR) and 50 (BlinkR) healthy volunteers.<sup>15</sup> These latencies and their variances with follow ups were repeatedly re-evaluated and confirmed in more than 200 (MassR) and 100 (BlinkR) volunteers,<sup>16</sup> unpublished data. MassR latencies in brackets refer to our present, self made recording system and are based on 50 healthy volunteers.<sup>17</sup> These longer latencies were attributed to a new reflex hammer with another piezo-electric element, as MassR latencies are essentially influenced by the delay of the trigger device. Right/left differences were the same with both systems.

data).<sup>15 16</sup> Age related latencies of a recent study from our laboratory, however, were about 1.0 ms longer than our previously reported values (table 1).<sup>17</sup> This study was done with a new, self made recording system including a new reflex hammer with another piezo-electric element, which is the most probable explanation of the longer latencies, as MassR latencies are essentially influenced by the delay of the trigger device.

The BlinkR was elicited by stimulating the supraorbital nerve on either side using rectangular stimuli (duration 0.1 ms; current 25 mA; intervals 10 s). Responses of the orbicularis oculi muscles were recorded simultaneously with surface electrodes inferior to the lower lid halfway between the inner and outer edge of the orbit (recording electrode) and at the lateral edge of the orbit (reference electrode) (bandwidth 20–2000 Hz). Mean latencies of the R<sub>1</sub> and R<sub>2</sub> components were calculated from five successive events. Age related normal latencies of the R<sub>1</sub> component (BlinkR-R<sub>1</sub>), which were repeatedly re-evaluated and confirmed in more than 100 other volunteers (Hopf *et al*<sup>15</sup> and unpublished data), are given in table 1.

Criteria of MassR and BlinkR-R<sub>1</sub> abnormalities<sup>18–21</sup> were: (1) unilateral or bilateral delay outside the age related mean + 2.5 SD, (2) unilateral or bilateral loss (for MassR also partial loss—that is, loss of more than four responses out of 10 trials); (3) right/left differences outside the age related mean + 2.5 SD. Criteria for improvement were (1) reappearance of completely or partially abolished responses and (2) shortening of latency by  $\geq 0.8$  ms (MassR) or  $\geq 1.3$  ms (BlinkR-R<sub>1</sub>).

#### BAEP

Rarefaction and condensation clicks of 70 dB above individual hearing threshold levels were delivered monaurally with a repetition rate of 10/s. Responses were recorded with surface electrodes over the mastoid (recording electrode) and the vertex (reference electrode). Mean latencies were determined from 1000 averaged responses. Unilateral or bilateral delay of wave III, IV, or V, or wave III to V interpeak latency outside the age related mean

+ 2.5 SD were interpreted in favour of a brainstem lesion only if present after stimulation with both rarefaction and condensation clicks.

#### MRI

MRI was carried out with 1.0 (Siemens Magnetom) or 1.5 Tesla (Philips S) superconducting systems before and after intravenous gadolinium (T1 weighted (repetition time: 500–750 ms, echo time: 20–50 ms) and T2 weighted (repetition time: 1800–2080 ms, echo time: 80–100 ms)). Slice thickness was between 3 and 7 mm.

#### CT

CT was performed with an EMI 1010 or an Siemens Somatom ARP with slice thicknesses between 3 and 7 mm.

## Results

Based on the above criteria, an ischaemic cause for the APV was diagnosed in 22 patients, 15 with one and seven with more than one relevant risk factor for the development of cerebrovascular disease (mainly hypertension: 12 patients, type II diabetes four patients). An ischaemic origin was evident in another patient (12) undergoing surgery because of hemifacial spasm: coagulation of a small basilar artery branch to the pons was followed by ipsilateral APV. In eight patients with definite multiple sclerosis, clinical signs of an APV were the only indication of the first (four patients), second (three patients), or third (one patient) exacerbation. Another two patients had an undiagnosed inflammatory disorder (CSF 14 and 18 white cells/ $\mu$ l without oligoclonal banding), and one had an ipsilateral pontomedullary tumour. In the remaining nine patients, the aetiology was undetermined.

Abnormal electrophysiological findings are given in detail in table 2. Bithermal caloric testing documented an unresponsiveness in 12 patients, and a hyporesponsiveness in 33 patients (between 26% and 93%) of one horizontal semicircular canal. At the time of bithermal caloric testing, which was done within 1 week after the clinical examination, spontaneous nystagmus was still present in 28 patients. It was unimpaired by warm water irrigation of the affected side in six patients, decreased, or ceased, but was not reversed in 13 patients (fig 1), and was reversed in nine patients (table 2).

Unilateral MassR or BlinkR-R<sub>1</sub> or BAEP abnormalities were almost always (in 20 of 21 patients) on the side of the APV (figs 2 and 3) (table 2). Slowed abduction or adduction saccades on one eye, and slowed lateral saccades or impaired following eye movements were also almost (17 of 22 patients) on the side or directed to the side of the APV (figs 4 and 5) (table 2). Clinical improvement was almost always (32 of 34 re-examined patients) associated with improvement or normalisation of at least one electrophysiological abnormality (figs 2, 3, and 5) (table 2). The remaining two patients (8 and 11) had an ipsilateral MassR abnormality, which was

Table 2 Abnormal electrophysiological findings in 43 patients with clinical signs of acute peripheral vestibulopathy

No and aetiology	Age	Sex	SN	Caloric testing		VP DP	Electrophysiological abnormalities	
1 Ischaemia	66	F	9°/s L	R <sub>w</sub> 7°/s L R <sub>c</sub> 9°/s L	L <sub>w</sub> 23°/s L L <sub>c</sub> 4°/s R	100% R 81% L	MassR	R 10.3 ms L 8.5 ms
2 Ischaemia	58	M	5°/s L	R <sub>w</sub> 5°/s R R <sub>c</sub> 7°/s L	L <sub>w</sub> 19°/s L L <sub>c</sub> 13°/s R	45% R 18% L	MassR	R 9.9 → 8.7 ms L 8.0 → 8.1 ms
3 Ischaemia	61	M	0	R <sub>w</sub> 8°/s R R <sub>c</sub> 0	L <sub>w</sub> 25°/s L L <sub>c</sub> 6°/s R	59% R 28% L	MassR	R 9.5 → 8.5 ms L 8.4 → 8.3 ms
4 Ischaemia	65	F	4°/s L	R <sub>w</sub> 4°/s L R <sub>c</sub> 7°/s L	L <sub>w</sub> 21°/s L L <sub>c</sub> 7°/s R	81% R 64% L	MassR	R 9.4 ms L 8.7 ms
5 Undetermined	48	F	5°/s L	R <sub>w</sub> 3°/s L R <sub>c</sub> 5°/s L	L <sub>w</sub> 27°/s L L <sub>c</sub> 5°/s R	100% R 75% L	MassR	R 9.3 → 8.5 ms L 8.4 → 8.4 ms
6 Ischaemia	82	M	6°/s R	R <sub>w</sub> 19°/s R R <sub>c</sub> 9°/s L	L <sub>w</sub> 4°/s R L <sub>c</sub> 6°/s R	100% L 53% R	MassR	R 8.4 ms L 9.3 ms
7 Ischaemia	56	F	2°/s R	R <sub>w</sub> 31°/s R R <sub>c</sub> 21°/s L	L <sub>w</sub> 3°/s L L <sub>c</sub> 12°/s R	55% L 28% R	MassR	R 8.8 → 8.3 ms L 9.2 → 8.0 ms
8 Ischaemia	57	F	0	R <sub>w</sub> 35°/s R R <sub>c</sub> 18°/s L	L <sub>w</sub> 14°/s L L <sub>c</sub> 6°/s R	45% L 12% R	MassR	R 7.9 → 8.0 ms L 8.9 → 8.3 ms
9 Inflammation	37	M	15°/s R	R <sub>w</sub> 37°/s R R <sub>c</sub> 11°/s L	L <sub>w</sub> 13°/s R L <sub>c</sub> 17°/s R	84% L 72% R	MassR	R 7.9 → 7.2 ms L 8.5 → 6.9 ms
10 Inflammation	29	F	2°/s L	R <sub>w</sub> 9°/s R R <sub>c</sub> 6°/s L	L <sub>w</sub> 39°/s L L <sub>c</sub> 21°/s R	60% R 20% L	MassR	R 8.1 ms L 7.3 ms
11 Ischaemia	56	M	7°/s L	R <sub>w</sub> 5°/s L R <sub>c</sub> 8°/s L	L <sub>w</sub> 37°/s L L <sub>c</sub> 7°/s R	83% R 75% L	MassR	R 7.8 → 7.5 ms L 7.2 → 7.4 ms
12 Ischaemia	48	F	27°/s R	R <sub>w</sub> 51°/s R R <sub>c</sub> 6°/s L	L <sub>w</sub> 27°/s R L <sub>c</sub> 23°/s R	100% L 89% R	MassR	R 6.8 ms L 7.5 ms
13 Ischaemia	63	F	3°/s R	R <sub>w</sub> 37°/s R R <sub>c</sub> 11°/s L	L <sub>w</sub> 7°/s L L <sub>c</sub> 17°/s R	33% L 50% R	MassR	R 6.5 → 6.5 ms L 7.5 → 6.7 ms
14 MS <sup>2nd</sup>	28	F	0	R <sub>w</sub> 60°/s R R <sub>c</sub> 33°/s L	L <sub>w</sub> 17°/s L L <sub>c</sub> 9°/s R	56% L 16% R	MassR	R 6.5 ms L 7.4 ms
15 MS <sup>3rd</sup>	43	F	0	R <sub>w</sub> 70°/s R R <sub>c</sub> 40°/s L	L <sub>w</sub> 30°/s L L <sub>c</sub> 25°/s R	33% L 15% R	MassR	R 7.7 → 7.0 ms L 7.2 → 5.9 ms
16 Ischaemia	52	M	7°/s R	R <sub>w</sub> 26°/s R R <sub>c</sub> 5°/s L	L <sub>w</sub> 4°/s R L <sub>c</sub> 7°/s R	83% L 64% R	MassR	R 0 → 7.5 ms L 0 → 7.3 ms
17 Undetermined	56	M	7°/s L	R <sub>w</sub> 4°/s L R <sub>c</sub> 7°/s L	L <sub>w</sub> 17°/s L L <sub>c</sub> 7°/s R	100% R 60% L	MassR	R 9.6 → 8.5 ms L 10.1 → 8.4 ms
18 Undetermined	53	F	0	R <sub>w</sub> 67°/s R R <sub>c</sub> 32°/s L	L <sub>w</sub> 27°/s L L <sub>c</sub> 13°/s R	42% L 19% R	MassR	R 9.1 → 8.3 ms L 9.5 → 8.5 ms
19 Undetermined	49	F	19°/s R	R <sub>w</sub> 46°/s R R <sub>c</sub> 11°/s L	L <sub>w</sub> 17°/s R L <sub>c</sub> 19°/s R	93% L 40% R	MassR	R 8.1 → 7.6 ms L 7.5 → 6.3 ms
20 Ischaemia	53	M	0	R <sub>w</sub> 7°/s R R <sub>c</sub> 12°/s L	L <sub>w</sub> 0 L <sub>c</sub> 0	100% L 26% L	MassR	R 7.6 → 7.4 ms L 8.1 → 7.7 ms
21 Undetermined	38	F	10°/s R	R <sub>w</sub> 31°/s R R <sub>c</sub> 9°/s L	L <sub>w</sub> 7°/s R L <sub>c</sub> 11°/s R	82% L 45% R	MassR	R 7.3 → 6.7 ms L 7.8 → 6.8 ms
22 Undetermined	45	M	0	R <sub>w</sub> 29°/s R R <sub>c</sub> 17°/s L	L <sub>w</sub> 0 L <sub>c</sub> 0	100% L 26% R	MassR	R 0 → 8.2 ms L 8.1 <sup>24</sup> → 8.5 ms
23 Ischaemia	60	M	0	R <sub>w</sub> 28°/s R R <sub>c</sub> 19°/s L	L <sub>w</sub> 14°/s L L <sub>c</sub> 7°/s R	38% L 3% R	MassR	R 10.3 → 9.9 ms L 11.5 → 10.8 ms
24 MS <sup>1st</sup>	25	F	5°/s R	R <sub>w</sub> 22°/s R R <sub>c</sub> 24°/s L	L <sub>w</sub> 0 L <sub>c</sub> 10°/s R	64% L 14% R	MassR	R 7.1 → 5.4 ms L 7.8 → 5.3 ms
25 MS <sup>1st</sup>	29	F	24°/s R	R <sub>w</sub> 0 R <sub>c</sub> 27°/s L	L <sub>w</sub> 69°/s L L <sub>c</sub> 6°/s R	47% R 88% L	BlinkR-R <sub>1</sub>	R 12.5 ms L 11.3 ms
26 Ischaemia	53	F	10°/s L	R <sub>w</sub> 6°/s L R <sub>c</sub> 10°/s L	L <sub>w</sub> 27°/s L L <sub>c</sub> 13°/s R	84% R 54% L	BlinkR-R <sub>1</sub>	R 10.8 → 9.3 ms L 9.3 → 9.4 ms
27 Ischaemia	68	M	2°/s L	R <sub>w</sub> 6°/s R R <sub>c</sub> 4°/s L	L <sub>w</sub> 57°/s L L <sub>c</sub> 32°/s R	80% R 23% R	BlinkR-R <sub>1</sub>	R 11.8 → 12.0 ms L 12.6 → 11.8 ms
28 Undetermined	58	F	2°/s L	R <sub>w</sub> 7°/s R R <sub>c</sub> 5°/s L	L <sub>w</sub> 56°/s L L <sub>c</sub> 37°/s R	77% R 16% L	BAEP	R wave IV 5.1 → 4.6 ms V 6.5 → 5.6 ms L wave IV 4.4 → 4.6 ms V 5.6 → 5.5 ms
29 Tumour	43	F	0	R <sub>w</sub> 21°/s R R <sub>c</sub> 9°/s L	L <sub>w</sub> 0 L <sub>c</sub> 0	100% L 40% R	EOG Saccades to the R: RE 443°/s, LE 459°/s	to the L: RE 355°/s, LE 372°/s
30 Ischaemia	60	M	0	R <sub>w</sub> 10°/s R R <sub>c</sub> 5°/s L	L <sub>w</sub> 20°/s L L <sub>c</sub> 12°/s R	36% R 6% L	EOG Saccades to the R: RE 431°/s, LE 449°/s → RE 453°/s, LE 477°/s	to the L: RE 339°/s, LE 317°/s → RE 461°/s, LE 483°/s
31 Ischaemia	60	M	9°/s L	R <sub>w</sub> 9°/s L R <sub>c</sub> 8°/s L	L <sub>w</sub> 25°/s L L <sub>c</sub> 11°/s R	100% R 58% L	EOG Saccades to the R: RE 349°/s, LE 331°/s → RE 401°/s, LE 423°/s	to the L: RE 459°/s, LE 437°/s → RE 437°/s, LE 451°/s
32 Ischaemia	65	M	4°/s L	R <sub>w</sub> 25°/s R R <sub>c</sub> 8°/s L	L <sub>w</sub> 0 L <sub>c</sub> 4°/s L	78% L 35% R	EOG Saccades to the R: RE 457°/s, LE 457°/s	to the L: RE 367°/s, LE 350°/s
33 Ischaemia	38	F	0	R <sub>w</sub> 11°/s R R <sub>c</sub> 6°/s L	L <sub>w</sub> 22°/s L L <sub>c</sub> 10°/s R	31% R 14% L	EOG Saccades to the R: RE 247°/s, LE 271°/s	to the L: RE 448°/s, LE 422°/s
34 Ischaemia	71	F	0	R <sub>w</sub> 0 R <sub>c</sub> 0	L <sub>w</sub> 33°/s L L <sub>c</sub> 14°/s R	100% R 40% L	EOG Saccades to the R: RE 287°/s, LE 301°/s → RE 341°/s, LE 357°/s	to the L: RE 391°/s, LE 397°/s → RE 369°/s, LE 379°/s
35 Undetermined	20	F	0	R <sub>w</sub> 0 R <sub>c</sub> 0	L <sub>w</sub> 36°/s L L <sub>c</sub> 17°/s R	100% R 40% L	EOG Saccades to the R: RE 417°/s, LE 523°/s → RE 473°/s, LE 507°/s	Saccadic pursuit to the L <sup>N</sup>
36 Ischaemia	28	F	7°/s R	R <sub>w</sub> 29°/s R R <sub>c</sub> 16°/s L	L <sub>w</sub> 5°/s R L <sub>c</sub> 7°/s R	91% L 44% R	EOG Saccades to the L: RE 487°/s, LE 365°/s → RE 457°/s, LE 427°/s	
37 Undetermined	29	M	0	R <sub>w</sub> 15°/s R R <sub>c</sub> 7°/s L	L <sub>w</sub> 30°/s L L <sub>c</sub> 12°/s R	31% R 16% L	EOG Saccades to the R: RE 340°/s, LE 537°/s → RE 447°/s, LE 515°/s	
38 MS <sup>1st</sup>	31	F	11°/s L	R <sub>w</sub> 24°/s R R <sub>c</sub> 20°/s L	L <sub>w</sub> 56°/s L L <sub>c</sub> 19°/s R	26% R 27% L	EOG Saccades to the R: RE 383°/s, LE: 488°/s	
39 Undetermined	49	F	0	R <sub>w</sub> 15°/s R R <sub>c</sub> 15°/s L	L <sub>w</sub> 0 L <sub>c</sub> 0	100% L 0	EOG Saccades to the R: RE 343°/s, LE 507°/s → RE 441°/s, LE 477°/s	

Table 2 Continued

No and aetiology	Age	Sex	SN	Caloric testing		VP DP	Electrophysiological abnormalities
40 MS <sup>1st</sup>	24	F	5°/s R	R <sub>w</sub> 57°/s R R <sub>c</sub> 22°/s L	L <sub>w</sub> 13°/s L L <sub>c</sub> 8°/s R	58% L 30% R	EOG <u>Saccades to the R</u> : RE 477°/s, LE 376°/s → RE 497°/s, LE 467°/s
41 MS <sup>2nd</sup>	30	M	10°/s L	R <sub>w</sub> 0 R <sub>c</sub> 14°/s L	L <sub>w</sub> 45°/s L L <sub>c</sub> 27°/s R	67% R 37% L	EOG <u>Saccades to the L</u> : RE 318°/s, LE 407°/s → RE 454°/s, LE 423°/s
42 Undetermined	43	M	7°/s L	R <sub>w</sub> 17°/s R R <sub>c</sub> 13°/s L	L <sub>w</sub> 63°/s L L <sub>c</sub> 31°/s R	52% R 23% L	EOG <u>Saccades to the L</u> : RE 348°/s, LE 427°/s → RE 449°/s, LE 439°/s
43 MS <sup>2nd</sup>	27	F	0	R <sub>w</sub> 23°/s R R <sub>c</sub> 13°/s L	L <sub>w</sub> 9°/s L L <sub>c</sub> 4°/s R	47% L 10% R	EOG <u>Saccadic pursuit to the L</u> <sup>I</sup>
44 Ischaemia	63	F	9°/s L	R <sub>w</sub> 0 R <sub>c</sub> 13°/s L	L <sub>w</sub> 65°/s L L <sub>c</sub> 4°/s R	68% R 90% L	EOG <u>Saccadic pursuit to the R</u> <sup>I</sup>
45 Ischaemia	80	F	0	R <sub>w</sub> 45°/s R R <sub>c</sub> 22°/s L	L <sub>w</sub> 15°/s L L <sub>c</sub> 18°/s R	34% L 26% R	EOG <u>Saccadic pursuit to the L &amp; R</u> <sup>I</sup>

Abnormal results are underlined; M= male; F= female; MS<sup>no</sup>= multiple sclerosis, NO of exacerbation; SN= spontaneous nystagmus (slow phase velocities depend on the level of alertness. We gave individual maximal values measured before starting warm and cold water irrigation of each ear); VP= vestibular paresis; DP= directional preponderance; R<sub>w</sub>= right warm; R<sub>c</sub>= right cold; L<sub>w</sub>= left warm; L<sub>c</sub>= left cold; R= right; L= left; RE= right eye; LE= left eye; MassR= masseter reflex; BlinkR<sub>i</sub>= R<sub>i</sub>-component of the blink reflex; BAEP= brainstem auditory evoked potentials; →indicates re-examinations; N= normalisation; I= improvement.

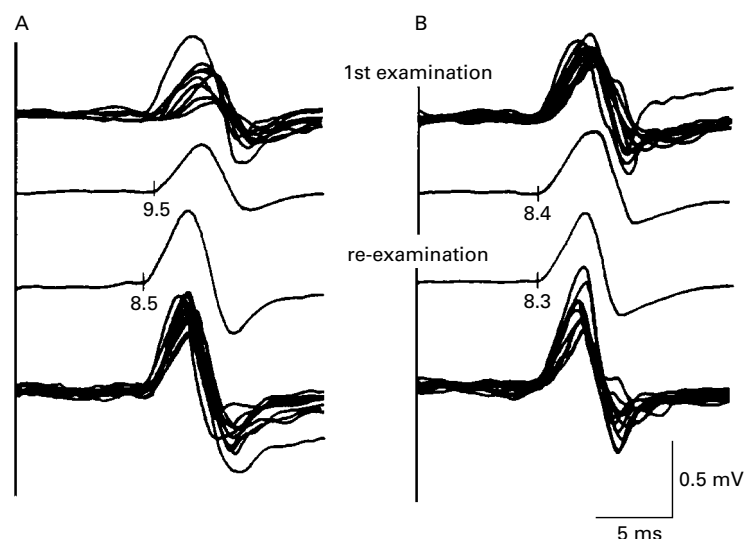


Figure 2 Delayed masseter reflex (upper two tracings) with normalisation at re-examination (lower two tracings) in patient 3 with right sided vestibular paresis due to pontine ischaemia. (first and fourth traces: superimposition of 10 responses; second and third traces: average of the 10 responses). A=left side; B=right side.

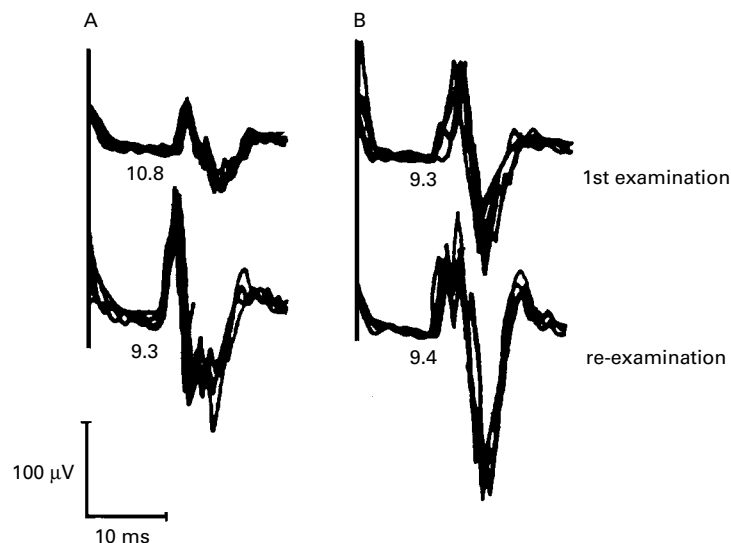


Figure 3 Delayed R<sub>1</sub> component of the blink reflex (upper tracings) with normalisation at re-examination (lower tracings) in patient 26 with right sided vestibular paresis due to pontine ischaemia. A=left side; B=right side.

normal at re-examination, but shortening of latency was not significant (0.6 and 0.3 ms, table 2).

MRI was carried out in 25 of the 45 patients and confirmed ipsilateral pontine lesions in six patients. The lesions mainly involved the region of the intrapontine vestibular nerve in five patients—three with multiple sclerosis (figs 1, 6, and 7), one with ischaemia (fig 8), and one with pontomedullary tumour—and the region of the vestibular nuclei in one patient with ischaemia (fig 4). Another patient (23) with clinical signs of a left sided APV had a right sided space occupying cerebellar infarction with pontine compression, but no pontine or medullary lesion. Another two patients with risk factors for cerebrovascular diseases had hyperintense bilateral pontine lesions, which correspond to “pontine ischaemic rarefaction” shown to be a common finding in such patients.<sup>22, 23</sup> The bilaterality of these lesions and lack of gadolinium enhancement prevent definite conclusions on their functional relevance. Small vascular lesions of the supratentorial white matter were seen in all patients with risk factors for cerebrovascular diseases, and multiple high signal lesions of the periventricular white matter in all patients with multiple sclerosis. CT was performed in 14 patients and failed to disclose any brainstem lesion.

## Discussion

Forty five of 232 consecutive patients with clinical signs of unilateral APV had abnormal electrophysiological findings, which cannot be explained by lesions of the labyrinth or the extra-axial vestibular nerve. Abnormal saccadic and pursuit eye movements are well known indicators of CNS involvement,<sup>24, 25</sup> although abnormal pursuit eye movements are of little topodiagnostic value.<sup>25</sup> The central MassR loop follows the entire length of the trigeminal mesencephalic tract and nucleus, closely approaching the region of the vestibular nuclei at the level of the trigeminal nerve motor nucleus (fig 9).<sup>26–28</sup> The BlinkR-R<sub>i</sub> is mediated between the lateral midpons and the facial nucleus via a trigeminofacial connection, which runs likely ventrolateral to the medial longitudinal fasciculus (MLF).<sup>21, 27, 28</sup> Provided that trigeminal nerve functions are intact as in all our patients (a normal corneal reflex, normal trigeminal

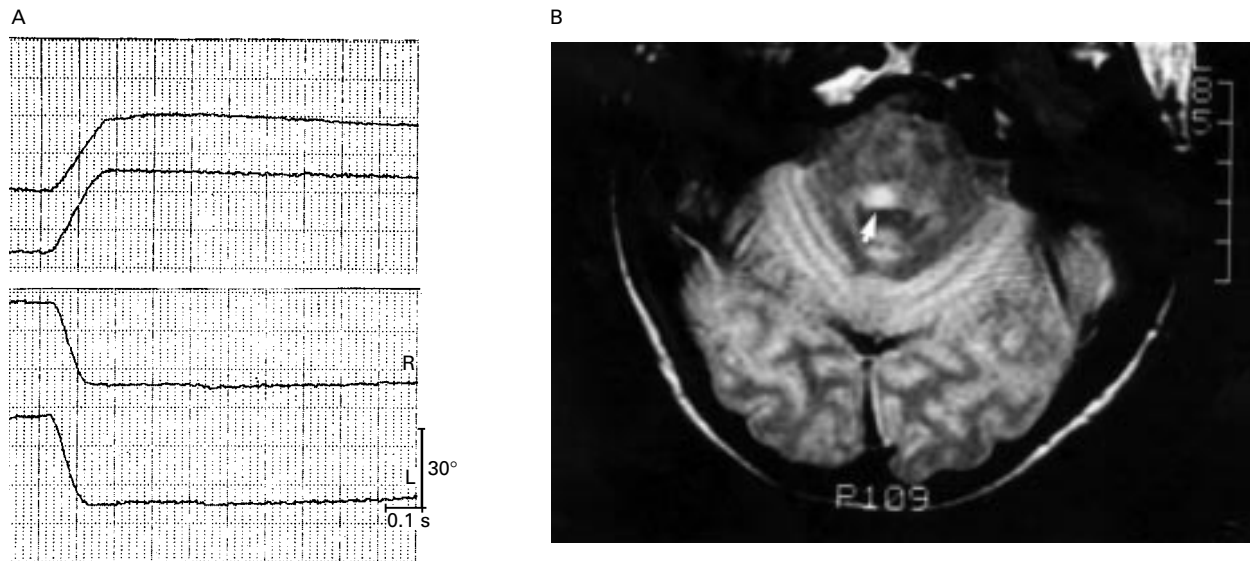


Figure 4 (A) Slowed saccades to the right (upward deflection; right eye: 247/s, left eye: 271°/s) and normal saccades to the left (downward deflection; right eye 448°/s, left eye 422°/s) in patient 33 with right sided vestibular paresis due to pontine ischaemia. (R=right eye; L=left eye). (B) T2 weighted MRI of the same diabetic woman documenting an ipsilateral pontine lesion compatible with infarction, which involved the region of the medial vestibular nucleus and the paramedian pontine reticular formation.

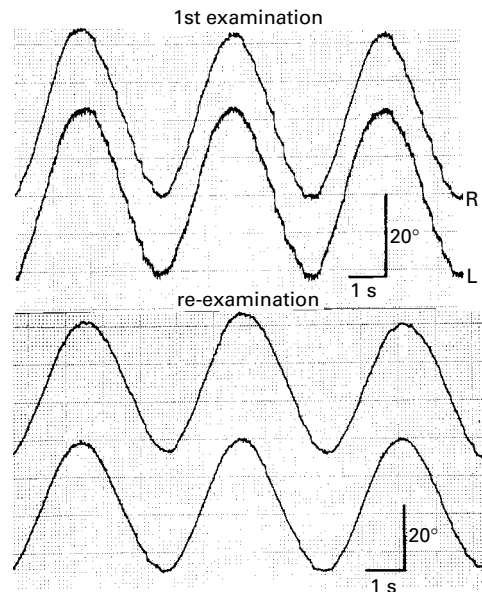


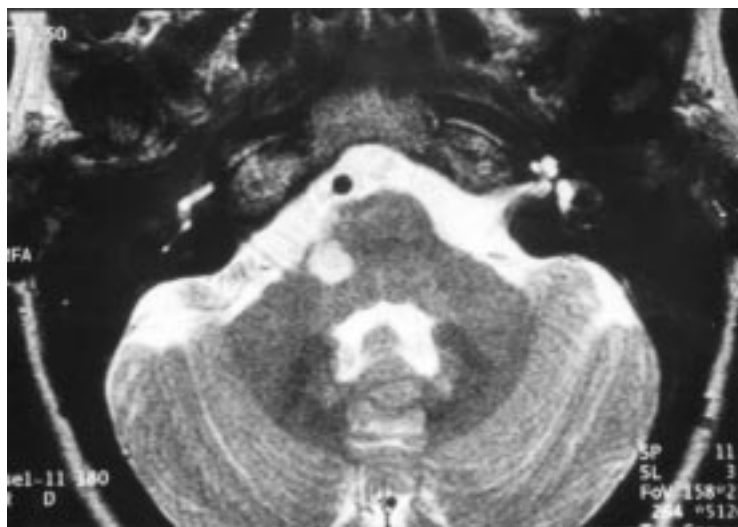
Figure 5 Upper tracings: saccadic smooth pursuit eye movements to the left (downward deflection) with normalisation at re-examination (lower tracings) in patient 43 with left sided vestibular paresis as the only clinical sign of the second exacerbation of multiple sclerosis. R=right eye; L=left eye.

sensory function, no masseter paresis), MassR abnormalities indicate ipsilateral brainstem lesions between the level of the trigeminal motor nucleus and the oculomotor nucleus, and BlinkR-R<sub>1</sub> abnormalities indicate lesions between the lateral midpons and the medial caudal pons.<sup>15 26 28-33</sup>

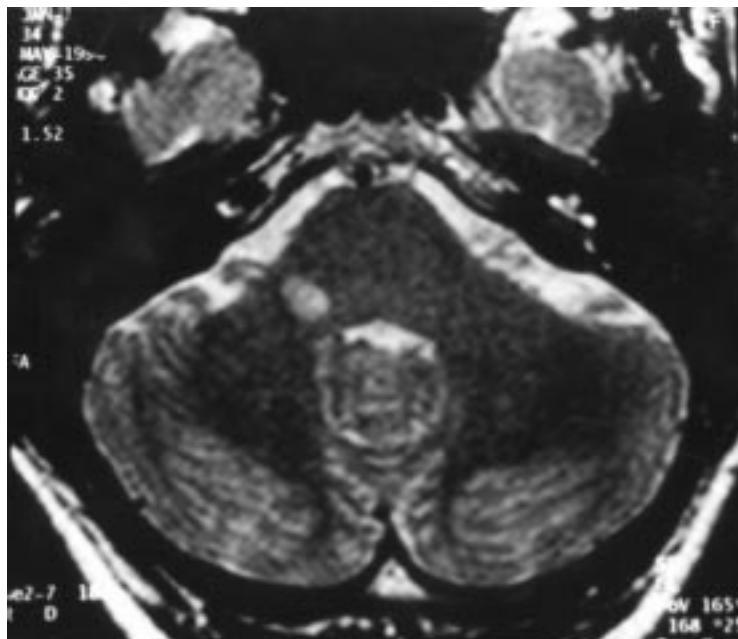
In a given setting, latencies of the MassR do not show much variation,<sup>15 18 29</sup> and do not seem to be significantly affected by electrode placement.<sup>17</sup> Our average MassR and BlinkR-R<sub>1</sub> latencies and our criteria of abnormal responses are in accord with previous reports from other laboratories.<sup>18-21 29 34</sup> Only Yates and Brown reported longer MassR latencies,<sup>30</sup> but they used

a different triggering mechanism which may account for the difference, as MassR latencies are essentially influenced by the delay of the trigger device.<sup>15 35</sup> Very short MassR latencies (<6.0 ms) were occasionally found in previous studies,<sup>15 18</sup> even by Yates and Brown,<sup>30</sup> and in some of our patients, and may reflect normal variations. Unlike latencies, MassR amplitudes are much less useful interpretive tools because of much greater variation. Typical values range between 0.5 and 3 mV, but can even be below 0.5 mV and may reach 7 mV. Amplitudes also depend on the degree of masseter muscle preinnervation and the strength of the stimulus.<sup>35 36</sup> Therefore, we do not consider amplitudes as a reliable indicator of an abnormal MassR in our study. As shown in patients with internuclear ophthalmoplegia, demyelinating and vascular lesions, which were the most common causes of APV in our study, caused similar MassR abnormalities; the average of the delayed responses were only slightly longer in patients with multiple sclerosis, and the average amplitudes were about 10% smaller in patients with lacunar infarctions.<sup>15</sup> As long as ischaemic lesions do not cause relevant axonal degeneration, delayed latencies with relative preservation of amplitude are explicable and the most likely explanation of such MassR abnormalities in patients with mesencephalic and pontine infarctions.<sup>15 31</sup>

The electrophysiological abnormalities of our patients may be attributed to (a) pre-existing brainstem lesions, (b) disseminated brainstem lesions, or (c) single common lesions involving the intrapontine vestibular nerve, the medial or lateral vestibular nucleus, or some combination of these, and the central loop of the MassR or BlinkR, or the neural networks generating saccadic and pursuit eye movements, or some combination of these. Pre-existing lesions are unlikely, as most electrophysiological abnormalities had improved at re-examination, which suggests acute lesions. Moreover, unilateral MassR, BlinkR-R<sub>1</sub>, or



*Figure 6* T2 weighted MRI in a 31 year old woman (patient 38) with right sided vestibular paresis as the presenting sign of multiple sclerosis documenting a hyperintense lesion of the pons involving the region of the ipsilateral intrapontine vestibular nerve. Considering the site of the lesion, simultaneous involvement of the intrapontine abducens nerve was likely, and the most probable explanation of slowed abduction saccades in this patient.



*Figure 7* T2 weighted MRI in a 30 year old man (patient 41) with right sided vestibular paresis as the only clinical sign of the second exacerbation of multiple sclerosis documenting a hyperintense lesion of the pons involving the region of the ipsilateral intrapontine vestibular nerve. This patient also had ipsilaterally slowed adduction saccades interpreted as internuclear ophthalmoplegia, but MRI may fail to disclose medial longitudinal fasciculus lesions in some patients with internuclear ophthalmoplegia (see discussion for more details).

BAEP abnormalities were almost always (19 of 20 patients) on the side of the APV, as were slowed abduction or adduction saccades (seven of eight patients), or slowed horizontal saccades (six of seven patients). This can hardly be explained by chance and indicates an association with the APV, which was also suggested by the associated improvement of APV and electrophysiological abnormalities seen in more than 90% of re-examined patients. These findings strongly indicate a single common or simultaneously formed disseminated lesions, but disseminated lesions are not required to explain the electrophysiological abnormalities in most of our patients.

Clinical signs of APV with ipsilateral vestibular paresis can occur with brainstem lesions involving the medial vestibular nucleus, lateral vestibular nucleus, and the intrapontine vestibular fascicle.<sup>8-11, 37</sup> Such lesions are usually associated with additional clinical evidence of brainstem dysfunction such as long tract signs or internuclear ophthalmoplegia,<sup>8, 9, 11, 37</sup> but may also cause isolated APV.<sup>8</sup> Parts of the paramedian pontine reticular formation (PPRF), the intrapontine abducens nerve and nucleus, the MLF, and the central MassR loop are adjacent to the proximal intrapontine vestibular nerve and the lateral and medial vestibular nucleus (figure 9), the last receiving direct afferents from the horizontal semicircular canal.<sup>38</sup> This region is mainly supplied by branches of the basilar artery.<sup>39-41</sup> Ischaemia (or inflammation) within this region may variably impair these structures causing APV by involvement of the intrapontine vestibular nerve and/or the medial and/or lateral vestibular nucleus,<sup>8, 9, 11, 37</sup> ipsiversively slowed horizontal saccades by involvement of the abducens nucleus and/or the PPRF,<sup>42, 43</sup> ipsilaterally slowed abduction or adduction saccades by involvement of the intrapontine abducens nerve or the MLF,<sup>44, 45</sup> and ipsilateral MassR abnormalities by affection of the central MassR loop.<sup>8, 15, 26, 28-30</sup> Such a mechanism was obvious in the patient with APV and ipsilaterally abnormal MassR after coagulation of a small basilar artery branch to the pons, and is the most likely explanation in patients with clinical signs of APV and ipsilateral MassR abnormalities (16 patients), slowed ipsiversive saccades, (seven patients), and ipsilaterally slowed abduction and adduction saccades (four and three patients, respectively) (table 2). Penetrating basilar artery branches often show asymmetric terminations,<sup>39-41</sup> which may explain bilateral MassR abnormalities (four patients) by asymmetric bilateral ischaemic lesions.

Smooth pursuit eye movements are generated by a neural network, which includes afferent and efferent cerebellar connections (from the flocculus, paraflocculus, dorsal parts of the vermis), dorsolateral pontine nuclei, vestibular nuclei, nucleus prepositus hypoglossi, ocular motor nuclei, and connections between these structures.<sup>25, 46, 47</sup> Following eye movements during optokinetic nystagmus (slow phases) are mainly generated by the same premotor structures as smooth pursuit eye movements,<sup>25, 46, 47</sup> and the smooth pursuit component mainly determines optokinetic nystagmus in humans.<sup>47</sup> Pontine lesions may be followed by impaired pursuit eye movements<sup>25, 48</sup> and are a plausible explanation of saccadic pursuit eye movements and reduced velocities of following eye movements during optokinetic nystagmus as seen in five and two patients, respectively (table 2). Although saccadic pursuit eye movements are often associated with impaired fixation suppression of vestibular nystagmus<sup>38, 49</sup> such lesions do not necessarily affect fixation suppression. A responsible lesion in the region of the intrapontine vestibular nerve may affect parts of the smooth pursuit system—for example, connections between the dorsolateral pontine nuclei or

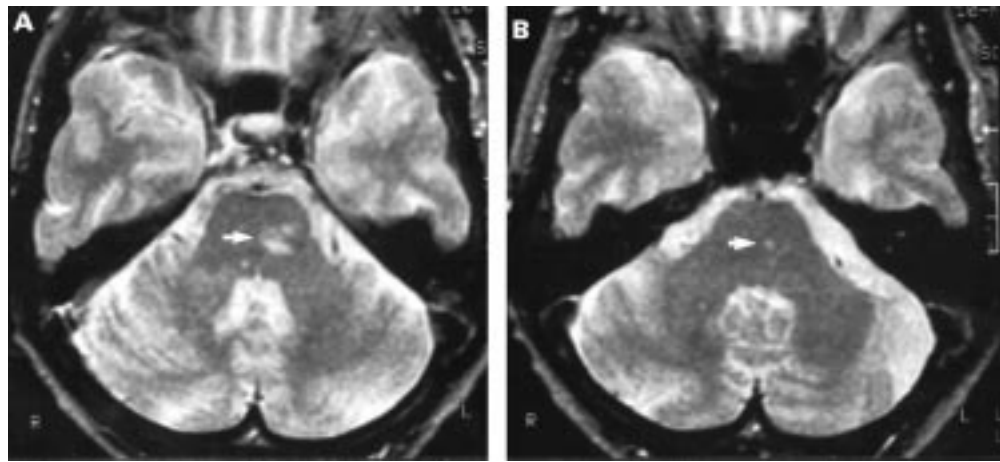


Figure 8 T2 Weighted MRI in an 80 year old woman (patient 45) with left sided vestibular paresis documenting an ipsilateral pontine lesion compatible with infarction. The lesion was mainly above the level of the vestibular nerve entry zone (left side) and extended to the level of the labyrinth (right side). Although main portions of the lesion were outside the region of the intrapontine vestibular nerve, it may have affected portions of the nerve causing mild canal paresis.

the nucleus prepositus hypoglossi and the vestibular nuclei. Such lesions may spare efferent cerebellar connections from the flocculus and paraflocculus mediating fixation suppression of vestibular nystagmus, which descend to the vestibular nuclei.<sup>38-49</sup>

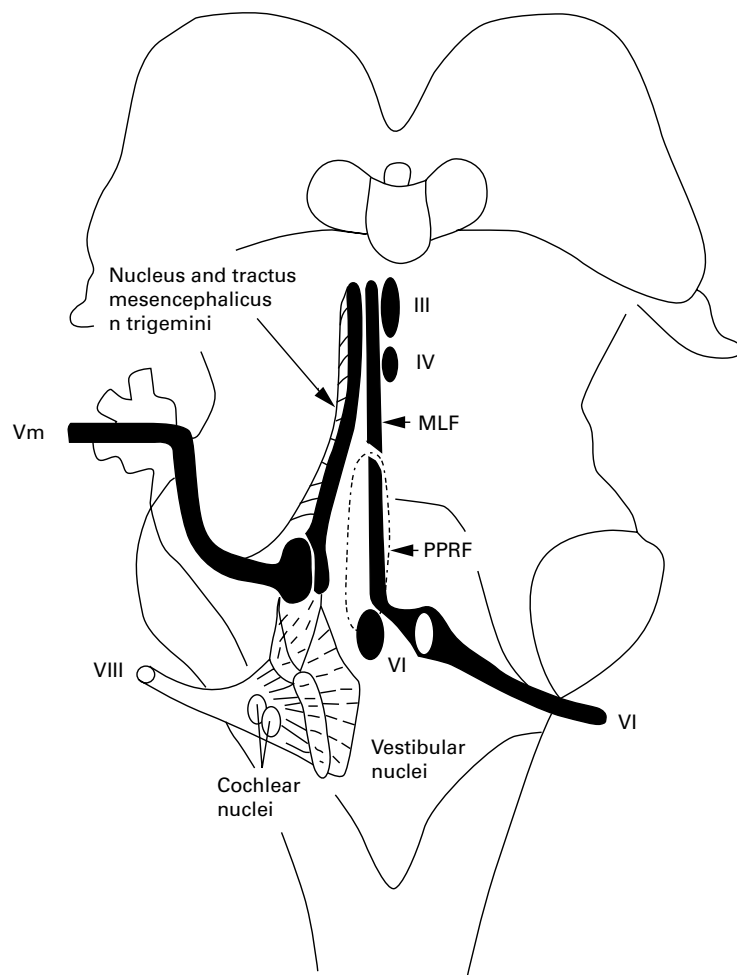


Figure 9 Semischematic drawing of the intrapontine vestibular nerve and nuclei and their relation to other structures tested in the present study. (III=oculomotor nucleus; IV=trochlear nucleus; VI=abducens nucleus and nerve; VIII=eighth cranial nerve; MLF=medial longitudinal fasciculus; PPRF=paramedian pontine reticular formation; Vm=motor part of the trigeminal nerve).

Disseminated lesions have to be considered in some patients. Two patients had contralaterally slowed abduction saccades, which were attributed to lesions of the intrapontine abducens nerve opposite to the side of the APV. A single lesion involving the intrapontine vestibular nerve, the medial vestibular nucleus or both on one side and the intrapontine abducens nerve on the other should also involve the intrapontine abducens nerve on the side of the APV. But signs of an ipsilateral sixth nerve involvement were absent in these patients, which makes a single lesion unlikely. The simultaneous improvement of clinical signs of APV and contralaterally slowed abduction saccades were interpreted in favour of disseminated brainstem lesions, which were reported in up to 25% of patients with vertebrobasilar ischaemia.<sup>50</sup> A third patient had a space occupying cerebellar infarction opposite to the side of the APV. Clinical signs of acute APV including ipsilateral vestibular paresis can occur with ipsilateral cerebellar infarctions,<sup>51-52</sup> and are attributed to labyrinthine ischaemia by circulatory arrest in the territory of the internal auditory artery, which is a branch of the anterior inferior cerebellar artery (AICA), or ischaemia in the territory of recurrent penetrating arteries off AICA, which supply the region of the intrapontine vestibular nerve.<sup>51-53-54</sup> But APV occurred contralateral to the cerebellar infarction in our patient, indicating bilateral lesions, which were concluded from bilaterally delayed MassR latencies more pronounced on the side of the APV. This may reflect brainstem compression by the space occupying cerebellar infarction, or disseminated lesions, which were reported in up to 25% of patients with vertebrobasilar ischaemia.<sup>50</sup> Another patient with right sided vestibular paresis and ipsilaterally slowed adduction saccades interpreted as internuclear ophthalmoplegia had MRI documented hyperintense lesion of the pons involving the region of the ipsilateral intrapontine vestibular nerve, but not the medial longitudinal fasciculus (fig 7). But a second demyelinating lesion or an extension of the documented lesion into



the region of the medial longitudinal fasciculus were probably too small to be detected by MRI, as MRI may fail to disclose lesions of the medial longitudinal fasciculus in some patients with internuclear ophthalmoplegia.<sup>55-57</sup> The simultaneous improvement of both clinical signs of APV and ipsilaterally slowed adduction saccades, indicated that both were caused by the same actual or simultaneously formed disseminated lesions.

Our findings add further evidence on the existence of acute APV due to pontine lesions, which were mainly suggested by abnormal brainstem reflexes and abnormal saccadic eye movements in 45 of 232 consecutive patients (19.4%). Vestibular paresis may be caused by pontine lesions affecting the intrapontine vestibular nerve fascicle or the medial and lateral vestibular nucleus.<sup>9-11</sup> But normal fixation suppression of caloric nystagmus, which was seen in all our patients, indicated fascicular vestibular nerve lesions, as nuclear lesions usually show little or no inhibitory effect of visual fixation on caloric nystagmus.<sup>9, 58</sup> Previous studies on smaller groups of patients with APV reported higher frequencies of responsible pontine lesions (between 31.5% and 59.4%) based on abnormal saccadic, or pursuit eye movements, or prolonged BAEP latencies.<sup>4-6</sup> But these studies were biased by up to 20% of patients with additional clinical signs of brainstem dysfunction, which does not match the diagnosis of APV, thereby overestimating patients with central lesions. But even an incidence of 19.4% as in our study shows that pontine lesions are a common cause of APV, which is underestimated, if based on MRI established lesions only; MRI was performed in 25 of our patients with electrophysiological abnormalities and confirmed corresponding pontine lesions in six patients only, indicating that some brainstem lesions escape proof by MRI. This was also shown in a large series of patients with third and sixth nerve palsies due to brainstem lesions,<sup>31, 33, 59</sup> and in up to 55.6% of patients with multiple sclerosis with BAEP and BlinkR abnormalities, or internuclear ophthalmoplegia with impaired convergence as an indicator of midbrain lesions, who showed no corresponding MRI established brainstem lesions.<sup>55, 60-62</sup>

We thank Mrs Annette Möller for her excellent technical assistance, and are indebted to Professor P Stoeter (Department of Neuroradiology, University of Mainz) and to Dr A v Essen (Neuroradiologist, Koblenz) for their kind permission to publish MRI findings and to reproduce figs 1 and 6-8 (Professor P Stoeter), and fig 4 (Dr A v Essen).

## Appendix

### Vestibular paresis

$$= \frac{(\text{Right}44^{\circ}\text{C} + \text{Right}30^{\circ}\text{C}) - (\text{Left}44^{\circ}\text{C} + \text{Left}30^{\circ}\text{C})}{\text{Right}44^{\circ}\text{C} + \text{Right}30^{\circ}\text{C} + \text{Left}44^{\circ}\text{C} + \text{Left}30^{\circ}\text{C}} \times 100$$

### Directional preponderance

$$= \frac{(\text{Right}44^{\circ}\text{C} + \text{Left}30^{\circ}\text{C}) - (\text{Left}44^{\circ}\text{C} + \text{Right}30^{\circ}\text{C})}{\text{Right}44^{\circ}\text{C} + \text{Right}30^{\circ}\text{C} + \text{Left}44^{\circ}\text{C} + \text{Left}30^{\circ}\text{C}} \times 100$$

### Fixation suppression index

$$= \frac{\text{maximum slow phase velocity with open eyes}}{\text{maximum slow phase velocity with closed eyes}} \times 100$$

- 1 Schuknecht HF, Kitamura K. Vestibular neuritis. *Ann Otol Rhinol Laryngol* 1981;90(suppl 78):1-19.
- 2 Brandt T. Vestibular neuritis. In: Brandt T. *Vertigo: its multi-sensory syndromes*. London:Springer,1991:29-40.
- 3 Böhmer A. Acute unilateral peripheral vestibulopathy. In: Baloh RW, Halmagyi GM, eds. *Disorders of the vestibular system*. Oxford:Oxford University Press, 1996:318-27.
- 4 Wennmo C, Pykkö I. Vestibular neuritis. A clinical and electro-oculographic analysis. *Acta otolaryngol* 1982;94: 507-15.
- 5 Ishikawa K, Edo M, Togawa K. Clinical observation of 32 cases of vestibular neuronitis. *Acta Otolaryngol* 1993;(suppl 503):13-15.
- 6 Imate Y, Sekitani T, Okami M, et al. Central disorders in vestibular neuronitis. *Acta Otolaryngol* 1995;(suppl 519): 204-5.
- 7 Bergenius J, Borg E. Audio-vestibular findings in patients with vestibular neuritis. *Acta Otolaryngol* 1983;96:389-95.
- 8 Hopf HC. Vertigo and masseter paresis. A new local brainstem syndrome probably of vascular origin. *J Neurol* 1988; 235:42-5.
- 9 Francis DA, Bronstein AM, Rudge P, et al. The site of brainstem lesions causing semicircular canal paresis: an MRI study. *J Neurol Neurosurg Psychiatry* 1992;55:446-9.
- 10 Brandt T, Dieterich M. Preliminary classification of vestibular brain-stem disorders. In: Caplan LR, Hopf HC, eds. *Brain-stem localization and function*. Berlin: Springer,1993:79-91.
- 11 Lawden MC, Bronstein AM, Kennard C. Repetitive paroxysmal nystagmus and vertigo. *Neurology* 1995;45:276-80.
- 12 Poser C, Paty D, Scheinberg L, et al. New diagnostic criteria for multiple sclerosis: guidelines for research protocols. *Ann Neurol* 1983;13:227-31.
- 13 Paty DW, Asbury AK, Herndon RM, et al. Use of magnetic resonance imaging in the diagnosis of multiple sclerosis: Policy statement. *Neurology* 1986;36:1575.
- 14 Baloh RW, Honrubia V. Electronystagmography. In: Baloh RW, Honrubia V. *Clinical neurophysiology of the vestibular system*. Philadelphia: Davis, 1990:130-52.
- 15 Hopf HC, Thömke F, Gutmann L. Midbrain v pontine medial longitudinal fasciculus lesions: the utilization of masseter and blink reflexes. *Muscle Nerve* 1991;14:326-30.
- 16 Krämer G, Bremer T, Hubrich P, et al. Altersabhängige Normwerte des Masseter Reflexes. *Aktuelle Neurologie* 1992;19(suppl):XVIII.
- 17 Ben Ghezala K, Hundemer HP, Koehler J, et al. The variance of masseter reflex (MassR) latencies and amplitudes with different recording techniques and follow-up with weekly intervals. *Electroencephalogr Clin Neurophysiol* 1996;99:334.
- 18 Kimura J, Rodnitzky RL, van Allen MW. Electrodiagnostic study of trigeminal nerve. *Neurology* 1970;20:574-83.
- 19 Ferguson IT. Electrical study of jaw and orbicularis oculi reflexes after trigeminal nerve surgery. *J Neurol Neurosurg Psychiatry* 1978;41:819-23.
- 20 Sanders EACM, Ongerboer de Visser BW, Barendswaard EC. Jaw, blink and corneal reflex latencies in multiple sclerosis. *J Neurol Neurosurg Psychiatry* 1985;48:1284-9.
- 21 Kimura J. The blink reflex. In: Kimura J. *Electrodiagnosis in diseases of nerve and muscle: principle and practice*. Philadelphia: Davis, 1989:307-31.
- 22 Pullicino P, Ostrow P, Miller L, et al. Pontine ischemic rarefaction. *Ann Neurol* 1995;37:460-6.
- 23 Kwa VII, Stam J, Blok LM, et al. T2-weighted hyperintense MRI lesions in the pons in patients with atherosclerosis. *Stroke* 1997;28:1357-60.
- 24 Henn V. Pathophysiology of rapid eye movements in the horizontal, vertical and torsional directions. In: Brandt T, Büttner U, eds. *Ocular motor disorders of the brain stem*. London: Baillière Tindall,1992:373-91.
- 25 Pierrot-Deseilligny C, Gaymard B. Smooth pursuit disorders. In: Brandt T, Büttner U, eds. *Ocular motor disorders of the brain stem*. London: Baillière Tindall,1992:435-54.
- 26 Ongerboer de Visser BW. Afferent limb of the human jaw reflex: electrophysiologic and anatomic study. *Neurology* 1982;32:563-6.
- 27 Ongerboer de Visser BW. Anatomical and functional organization of reflexes involving the trigeminal system in man. In: Desmedt JE, ed. *Motor control mechanisms in health and disease (Advances in Neurology.)* Vol 39. New York: Raven Press, 1983:727-38.
- 28 Hopf HC. Topodiagnostic value of brain stem reflexes. *Muscle Nerve* 1994;17:475-84.
- 29 Ongerboer de Visser BW, Goor C. Jaw reflexes and masseter electromyograms in mesencephalic and pontine lesions. *J Neurol Neurosurg Psychiatry* 1976;39:90-2.
- 30 Yates SK, Brown WF. The human jaw jerk: electrophysiologic methods to measure latency, normal values and changes in multiple sclerosis. *Neurology* 1981;31:632-4.
- 31 Hopf HC, Gutmann L. Diabetic 3rd nerve palsy: evidence for a mesencephalic lesion. *Neurology* 1990;40:1041-5.
- 32 Kiers L, Carroll WM. Blink reflexes and magnetic resonance imaging in focal unilateral central trigeminal pathway demyelination. *J Neurol Neurosurg Psychiatry* 1990;53:526-9.
- 33 Thömke F, Tettenborn B, Hopf HC. Third nerve palsy as the sole manifestation of midbrain ischemia. *Neuro-Ophthalmology* 1995;15:327-35.
- 34 Malin JP. The human orbicularis oculi reflex. *Electromyogr Clin Neurophysiol* 1982;22:45-53.
- 35 Dengler R. The masseter reflex in the topodiagnosis of brain-stem lesions. In: Caplan LR, Hopf HC, eds. *Brain-stem localization and function*. Berlin: Springer,1993: 191-7.

- 36 Lewis GR, Pilcher R, Yemm R. The effect of stimulus strength on the jaw-jerk response in man. *J Neurol Neurosurg Psychiatry* 1980;**40**:699-704.
- 37 Lopez L, Bronstein AM, Gresty MA, et al. Torsional nystagmus. *Brain* 1992;**115**:1107-24.
- 38 Baloh RW, Honrubia V. The central vestibular system. In: Baloh RW, Honrubia V. *Clinical neurophysiology of the vestibular system*. Philadelphia: Davis, 1990:44-87.
- 39 Hassler O. Arterial pattern of human brainstem. Normal appearance and deformation in expanding supratentorial conditions. *Neurology* 1967;**7**:368-75.
- 40 Duvernoy AM. *Human brainstem vessels*. Berlin: Springer, 1978.
- 41 Miller NR. The basilar artery and its branches. In: Miller NR. *Walsh and Hoyt's clinical neuroophthalmology*. Vol 4. Baltimore: Williams and Wilkins, 1991:1911-35 and 1969-73.
- 42 Pierrot-Deseilligny C, Goasguen J. Isolated abducens nucleus damage due to histiocytosis X. Electro-oculographic analysis and physiological deductions. *Brain* 1984;**107**:1019-32.
- 43 Hanson MR, Hamid MA, Tomsak RL, et al. Selective saccadic palsy caused by pontine lesions: clinical, physiological, and pathological correlations. *Ann Neurol* 1986;**20**:209-17.
- 44 Bronstein AM, Morris J, du Boulay G, et al. Abnormalities of horizontal gaze. Clinical, oculographic and magnetic resonance imaging findings. I Abducens palsy. *J Neurol Neurosurg Psychiatry* 1990;**53**:194-9.
- 45 Zee DS. Internuclear ophthalmoplegia: pathophysiology and diagnosis. In: Brandt T, Büttner U, eds. *Ocular motor disorders of the brain stem*. London: Baillière Tindall, 1992: 455-70.
- 46 Leigh RJ, Zee DS. Smooth pursuit and visual fixation. In: Leigh RJ, Zee DS. *The neurology of eye movements*. Philadelphia: Davis, 1991:139-79.
- 47 Büttner U. Smooth pursuit eye movements, optokinetic nystagmus, and vestibulo-ocular reflex suppression. In: Kennard C, Rose CR, eds. *Physiological aspects of clinical neuroophthalmology*. London: Chapman and Hall, 1988: 277-92.
- 48 Gaynard B, Pierrot-Deseilligny C, Rivaud S, et al. Smooth pursuit eye movement deficit after pontine nuclei lesions in humans. *J Neurol Neurosurg Psychiatry* 1993;**56**:799-807.
- 49 Zee DS, Yamazaki A, Butler PH, et al. Effects of ablation of flocculus and paraflocculus on eye movements in primate. *J Neurophysiol* 1981;**46**:878-99.
- 50 Tettenborn B. Multifocal ischemic brain-stem lesions. In: Caplan LR, Hopf HC, eds. *Brain-stem localization and function*. Berlin: Springer, 1993:23-31.
- 51 Rubinstein RL, Norman DM, Schindler RA, et al. Cerebellar infarction: a presentation of vertigo. *Laryngoscope* 1980;**90**:505-14.
- 52 Huang CY, Yu YL. Small cerebellar strokes may mimic labyrinthine lesions. *J Neurol Neurosurg Psychiatry* 1985;**48**: 263-5.
- 53 Hinojosa R, Kohut RI. Clinical diagnosis of anterior inferior cerebellar artery thrombosis. Autopsy and temporal bone histopathologic study. *Ann Otol Rhinol Laryngol* 1990;**99**: 261-72.
- 54 Oas JG, Baloh RW. Vertigo and the anterior inferior cerebellar artery syndrome. *Neurology* 1992;**42**:2274-9.
- 55 Bronstein AM, Rudge P, Gresty MA, et al. Abnormalities of horizontal gaze. Clinical, oculographic and magnetic resonance imaging findings. II. Gaze palsy and internuclear ophthalmoplegia. *J Neurol Neurosurg Psychiatry* 1990;**53**: 200-7.
- 56 Mutschler V, Eber AM, Rumbach L, et al. Internuclear ophthalmoplegia in 14 patients. Clinical and topographic correlation using magnetic resonance imaging. *Neuro-Ophthalmology* 1990;**10**:319-25.
- 57 Rumbach L, Eber AM, Dietemann, et al. Apport de l'I.R.M. au diagnostic topographique des troubles oculomoteurs dans la sclérose en plaques. *Rev Neurol* 1990;**146**:30-5.
- 58 Hood JD, Korres S. Vestibular suppression in peripheral and central vestibular disorders. *Brain* 1979;**102**:785-804.
- 59 Thömke F. Isolated abducens palsies due to pontine lesions. *Neuro-Ophthalmology* 1998;**20**:91-100.
- 60 Newmann NJ, Lessell S. Isolated pupil-sparing third-nerve palsy as the presenting sign of multiple sclerosis. *Arch Neurol* 1990;**47**:817-8.
- 61 Rose JW, Digre KB, Lynch SG, et al. Acute VIth cranial nerve dysfunction in multiple sclerosis. *Journal of Clinical Neuro-Ophthalmology* 1993;**12**:17-20.
- 62 Uncini A, Faricelli, Assetta M, et al. Electrophysiological and magnetic resonance imaging correlates of brainstem demyelinating lesions. *Electromyogr Clin Neurophysiol* 1990;**30**:233-8.