

## LETTERS TO THE EDITOR

### Cerebral metabolism during vegetative state and after recovery to consciousness

One way to approach the study of consciousness is to explore lesional cases in which impairment of consciousness is the prominent clinical sign. Vegetative state is such a condition wherein awareness is abolished whereas arousal persists. It can be diagnosed clinically soon after a brain injury and may be reversible (as in the following case report) or progress to a persistent vegetative state or death. The distinction between vegetative state and persistent vegetative state is that the second is defined as a vegetative state that has continued or endured for at least 1 month.<sup>1</sup> We present a patient who developed a vegetative state after carbon monoxide poisoning and in whom we had the opportunity to measure brain glucose metabolism distribution during the vegetative state and after recovery to consciousness. Using [<sup>18</sup>F]fluorodeoxyglucose (FDG) PET and statistical parametric mapping (SPM) we compared both patient's sets to a normal control population. Our findings offer an insight into the neural correlates of "awareness", pointing to a critical role for posterior associative cortices in consciousness.

A 40 year old right handed woman attempted suicide through CO intoxication and was found unconscious. She was treated with hyperbaric oxygen but evolved to a vegetative state diagnosed according to the following criteria:<sup>1</sup> (1) spontaneous eye opening without evidence of awareness of the environment; (2) no evidence of reproducible voluntary behavioural responses to any stimuli; (3) no evidence of language comprehension or expression; (4) intermittent wakefulness and behaviourally assessed sleep-wake cycles; (5) normal cardiorespiratory function and blood pressure control; (6) preserved pupillary, oculocephalic, corneal, and vestibulo-ocular reflexes. Brain MRI performed 14 days after admission was normal. Electroencephalography showed a 6 Hz basal activity with more pronounced slowing on the left parietal regions. Auditory evoked potentials were normal. Somaesthetic evoked potentials of the median nerve showed

normal latency and amplitude of P14 and N20 potentials without any late cortical components. After remaining in a vegetative state for 19 days the patient regained consciousness. Her sequelae consisted of a bilateral spastic paresis of upper and lower limbs. Neuropsychological testing 1 month after admission showed an attention deficit with moderate impairment of short term memory. One year after the accident she showed a spastic gait with altered fine motor function, most prominent on the right, a slurred speech, and minor short term memory disturbances. FDG-PET was performed during the vegetative state (day 15 after admission) and after recovery to consciousness (day 37).

The control population consisted of 48 drug free, healthy volunteers, aged from 18 to 76 years (mean: 42 (SD 21) years).

The study was approved by the ethics committee of the University of Liège. Informed consent was obtained by the husband of the patient and for all control subjects. Five to 10 mCi FDG was injected intravenously; PET data were obtained on a Siemens CTI 951 R 16/31 scanner in bidimensional mode. Arterial blood samples were drawn during the whole procedure and cerebral metabolic glucose rates (CMRGlucose) were calculated for all subjects. PET data were analysed using SPM software (SPM96 version; Welcome Department of Cognitive Neurology, Institute of Neurology, London, UK).<sup>2</sup> The use of SPM to assess between subject (rather than within subject) variability is unlikely to alter the relevance of our results given their high degree of significance. Data from each subject were normalised to a standard stereotactic space and then smoothed with a 16 mm full width half maximum isotropic kernel. The analysis identified brain regions where glucose metabolism was significantly lower in each patient scan compared with the control group. The resulting foci were characterised in terms of peak height over the entire volume analysed at a threshold of corrected  $p < 0.05$ .<sup>2</sup>

During the vegetative state, average grey matter glucose metabolism was 38% lower than in controls (4.5 v 7.3 (SD 1.4) mg/100 g/min). No substantial change in mean CMRGlucose was found after recovery (4.7 mg/100 g/min). During the vegetative state, significant regional CMRGlucose decreases were found in the left and right superior parietal lobule; the left inferior parietal lobule; the precuneus; the left superior occipital, superior and middle temporal gyri; and the premotor and postcentral and precentral cortex (figure, yellow colour). After recovery, metabolic impairment was confined to the

left and right precentral and postcentral gyri and premotor cortices (figure, blue colour).

This case report offers an insight into the neural correlates of human consciousness (at least, external awareness as it can be assessed at the patient's bedside). Given that global glucose utilisation levels remained essentially the same, the recovery of consciousness seems related to a modification of the regional distribution of brain function rather than to the global resumption of cerebral metabolism. The main decreases in metabolism seen during the vegetative state but not after recovery were found in parietal areas, including the precuneus. This is in agreement with postmortem findings in persistent vegetative state, in which involvement of the association cortices is reported as a critical neuroanatomical substrate<sup>3</sup> and with PET studies in postanoxic syndrome, in which the parieto-occipital cortex showed the most consistent impairment.<sup>4</sup> The functions of these areas are manifold: lateral parietal areas are involved in spatial perception and attention, working memory, mental imagery, and language, whereas the precuneus is activated in episodic memory retrieval, modulation of visual perception by mental imagery, and attention.<sup>2</sup> Our data point to a critical role for these posterior associative cortices in the emergence of conscious experience.

STEVEN LAUREYS  
CHRISTIAN LEMAIRE  
PIERRE MAQUET

*Cyclotron Research Centre, University of Liège, Sart Tilman, 4000 Liège, Belgium*

CHRISTOPHE PHILLIPS

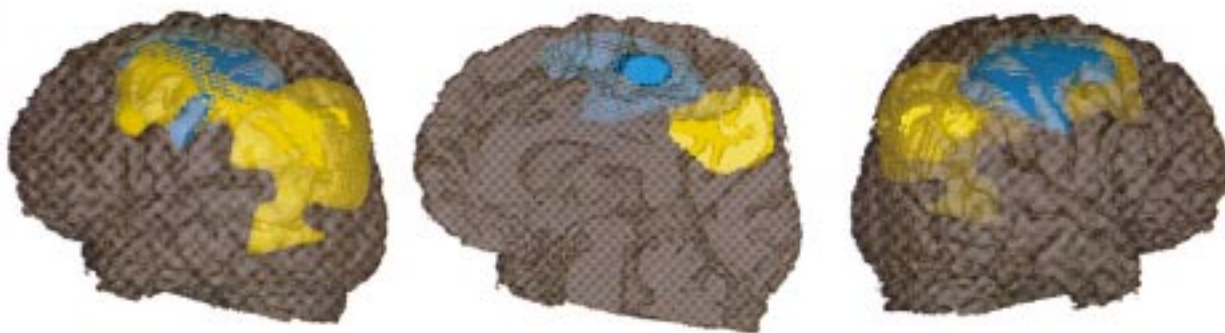
*Institute of Cognitive Neurology, University College London, Alexandra House, 17 Queens Square, London WC1N3AR, England, UK*

GEORGE FRANCK

*Department of Neurology, CHU Liège Sart, Tilman B-35, 4000 Liège, Belgium*

Correspondence to: Dr Pierre Maquet, Cyclotron Research Centre (B30), University of Liège, Sart Tilman, 4000 Liège, Belgium Telephone 0032 43 66 36 87; fax 0032 43 66 29 46; email maquet@pet.crc.ac.be

- 1 The Multi-Society Task Force on PVS. Medical aspects of the persistent vegetative state (1). *N Engl J Med* 1994;330:1499-508.
- 2 Frackowiak RSJ, Friston KJ, Frith CD, et al. *Human brain function*. San Diego: Academic Press, 1997.
- 3 Kinney HC, Samuels MA. Neuropathology of the persistent vegetative state: a review. *J Neuropathol Exp Neurol* 1994;53:548-58.
- 4 De Volder AG, Goffinet AM, Bol A, et al. Brain glucose metabolism in postanoxic syndrome. Positron emission tomographic study. *Arch Neurol* 1990;47:197-204.



Localisation of voxels in which cerebral glucose metabolism was impaired during vegetative state (in yellow) and after recovery to consciousness (in blue), compared with the control population. SPM<sub>Z</sub> threshold was set at voxel level corrected  $p < 0.05$  and projected on the patient's coregistered MRI, normalised to the stereotaxic space of Talairach.

### Electrical inexcitability of nerves and muscles in severe infantile spinal muscular atrophy

Spinal muscular atrophy (SMA) is one of the most common fatal autosomal recessive disorders, characterised by progressive degeneration of anterior horn cells. Before the advent of genetic testing, the diagnosis of SMA was based on clinical, histopathological, and electrophysiological features. In 1992, the International SMA Consortium defined diagnostic criteria of proximal SMA based on clinical findings.<sup>1</sup> In SMA type I (severe; Werdnig-Hoffmann disease), affected persons have onset of symptoms before 6 months of age and are never able to sit without support. Electromyography demonstrates denervation features. In early 1995, the candidate gene, the survival motor neuron (SMN) gene, was identified, making the confirmation of SMA by DNA analysis possible.<sup>2</sup>

With the availability of a genetic test for SMA, many investigators are refining the diagnostic criteria published by the Consortium. Studies involving hundreds of patients with proximal SMA have disclosed a subset of patients who fulfill at least one exclusion criterion defined by the Consortium.<sup>3</sup> We identified an infant with severe SMA who fulfilled two exclusion criteria and also showed inexcitability of all nerves as well as muscles. This report will further delineate the wide range of phenotypes for this particular gene mutation.

A 2945 g male infant was born at term. First fetal movements were noted at 13 weeks of gestation. Chorionic villus sampling at 10 weeks of gestation disclosed normal chromosomes. Decreased fetal movement and polyhydramnios were noted at about 34 weeks of gestation. At delivery, the infant was cyanotic with no respiratory effort and was subsequently intubated. On physical examination, the infant had no spontaneous movements. He opened his eyes with brief fixation but no following. Tongue fasciculations were present. Other cranial nerves seemed intact. Mild flexion contractures of both elbows, knees, and ankles were noted. Tone was flaccid in both upper and lower limbs, and there was no movement response to painful stimulus. Deep tendon reflexes were absent.

Brain MRI disclosed mild diffuse cortical and deep atrophy. His EMG was severely abnormal, with widespread fibrillations and absent voluntary motor units except in the genioglossus, where mildly neurogenic motor units with decreased recruitment were seen. Stimulation of the median, ulnar, tibial, and peroneal nerves with a maximal stimulus resulted in no clinical or electrical response. The biceps brachii and rectus femoris muscles were electrically inexcitable by direct needle stimulation. Median, ulnar, and sural sensory potentials were not obtainable. DNA testing showed a homozygous deletion of exons 7 and 8 in the telomeric SMN gene, confirming the diagnosis of SMA. The infant expired at 3 weeks of age, and the parents declined postmortem examination.

Typical EMG studies in those with SMA show fibrillations and fasciculations at rest and an increased mean duration and amplitude of motor units. Motor nerve conduction velocities may be slowed but are usually normal. Korinthenberg *et al* reported inexcitability of motor nerves in three siblings, each of whom died from SMA before 1 month of age.<sup>4</sup> In addition to a homozygous deletion of

exons 7 and 8 of the telomeric SMN gene, all three siblings showed a large deletion in the region that includes all alleles of the multicopy markers Ag1-CA and C212, localised at the 5' end of the two SMN gene copies. It has been postulated that the severity of disease may be correlated to the extent of a deletion involving the SMN gene and the multicopy markers.<sup>3-5</sup> The infant in our report with SMA type I showed electrical inexcitability of motor nerves as well as the characteristic alteration of the SMN gene.

Although it has been known for some time from histological studies that sensory systems are involved in SMA, electrophysiological sensory findings have been previously reported only once.<sup>4</sup> Sensory nerve conduction velocity was tested in an infant with severe SMA and showed no recordable potential, but the infant in our report also exhibited universal absence of sensory potentials. In both cases, DNA analysis disclosed the 5q deletion. It is unclear whether this finding represents a distinct entity or merely the severe end of classic Werdnig-Hoffmann disease. The diagnostic criteria produced by the International SMA Consortium currently lists "abnormal sensory nerve action potentials" as an exclusion criterion.<sup>1</sup> Our finding of absent sensory potentials in a 5q deletion established case of SMA indicates further need for revision of the Consortium criteria.

Studies involving large series of patients with SMA have identified cases of SMA variants.<sup>3</sup> These patients were diagnosed as infantile SMA by the presence of proximal weakness and atrophy, hypotonia, and evidence of neurogenic alterations in EMG and muscle biopsy. In addition, these patients also exhibited one of the exclusion criteria defined by the Consortium—for example, diaphragmatic weakness, involvement of the CNS, or arthrogryposis. Although these patients did not show the typical SMN deletion and were therefore probably not linked to chromosome 5q, they could have had point mutations. The infant in our report showed no respiratory effort after birth, indicating diaphragmatic weakness. He did, however, possess the characteristic SMN gene alterations. This finding suggests that diaphragmatic weakness should be reconsidered as an exclusion criterion by the Consortium.

Review of the literature disclosed no previous reports of electrically inexcitable muscles in SMA. This phenomenon is known to occur in a few other neuromuscular conditions such as periodic paralysis and critical illness polyneuropathy. Fibrillations, as seen in the infant in our report, are commonly seen in acute denervation and are thought to be caused by perturbation of the sarcolemmal membrane, rendering it unstable. One possibility may be that the severe denervation in SMA type I can result in abnormal function of the membrane to make it electrically inexcitable. Further electrophysiological studies at the cellular level are required to delineate this interesting finding.

ALICE A KUO

Department of Pediatrics

STEFAN-M PULST  
DAWN S ELIASHIV  
CAMERON R ADAMS

Division of Neurophysiology, Cedars-Sinai Medical Center, Los Angeles, CA, USA

Correspondence to: Dr Cameron R Adams, Department of Neurophysiology, Cedars-Sinai Medical Center, 8631 West Third Street, Room 1145, East Tower, Los Angeles, CA 90048, USA.

- 1 The International SMA consortium. Meeting report. *Neuromusc Disord* 1992;2:423-8.
- 2 Lefebvre S, Burglen L, Reboullet S, *et al*. Identification and characterization of spinal muscular atrophy-determining gene. *Cell* 1995;80:155-65.
- 3 Zerres K, Wirth B, and Rudnik-Schoneborn S. Spinal muscular atrophy-clinical and genetic correlations. *Neuromusc Disord* 1997;7:202-7.
- 4 Korinthenberg R, Sauer M, Ketelsen UP, *et al*. Congenital axonal neuropathy caused by deletions in the spinal muscular atrophy region. *Ann Neurol* 1997;42:364-8.
- 5 Wirth B, Hahnen E, Morgan K, *et al*. Allelic association and deletions in autosomal recessive proximal spinal muscular atrophy: association of marker genotype with disease severity and candidate cDNAs. *Hum Mol Gen* 1995;4:1273-84.

### Acute overdosage and intoxication with carbidopa/levodopa can be detected in the subacute stage by measurement of 3-*o*-methyldopa

Although the effects of a chronic overdosage with levodopa are well known, few cases of acute intoxication have been described.<sup>1,2</sup> A particular problem in establishing a diagnosis of levodopa overdosage is the relatively short half life in the circulation of levodopa.<sup>3,4</sup> If there is a delay in bringing an acutely intoxicated patient to hospital, perhaps due to late discovery, the blood concentration of levodopa could already be normal (corresponding to the peak levodopa concentration in Parkinson's disease therapy) after 6-8 hours. Depending on the extent of the overdosage, the time could be even shorter. This report describes the clinical effects and the plasma concentrations of levodopa and specific metabolites over a period of 132.5 hours after ingestion of 30 tablets of carbidopa/levodopa (50 mg/200 mg tablets).

A 76 year old patient had a pre-existing mild akinetic rigid Parkinson's syndrome, which had been treated for the past 1.5 years with 3x1 tablets of carbidopa/levodopa (50 mg/200 mg) a day without a substantial response. The weight of the patient was 74 kg. A known chronic obstructive airway disease was treated with a home oxygen appliance. At about 8.30 pm, the patient had attempted suicide by taking 30 tablets of carbidopa/levodopa. About 9.00 pm he appeared psychically altered, crying without reason, anxious, and depressed. After about 30 minutes he was increasingly inadequate, agitated, and subeuphoric, and was experiencing visual hallucinations; he was restless, tossing and turning, and getting out of bed. He did not represent peak dose dyskinesia or other extrapyramidal clinical features. At 10.00 pm he showed bilaterally maximally dilated pupils. The muscle stretch reflexes were lively, there were no pyramidal tract signs, and he did not show any signs of Parkinson's syndrome or dyskinesia. Arterial hypertonus and sinus tachycardia could be registered.

After an empty box of Striaton (carbidopa/levodopa, 50 mg/200 mg) was found in the patient's flat, 1 g of carbon was given by stomach tube after gastric lavage. Cranial CT was carried out before the diagnosis of intoxication had been made; it showed a pronounced subcortical arteriosclerotic encephalopathy with reduced brain volume. The patient was moved to the medical intensive care unit and observed for 24 hours. The ECG showed a P pulmonale, but no other unusual features. Echocardiography showed normal right and left ventricular function with suspicion of right ventricular hypertro-