

## SHORT REPORT

## Late onset levodopa responsive Huntington's disease with minimal chorea masquerading as Parkinson plus syndrome

I Reuter, M T M Hu, T C Andrews, D J Brooks, C Clough, K Ray Chaudhuri

### Abstract

**Huntington's disease is characterised by hyperkinetic movements, mainly chorea, cognitive dysfunction, and psychiatric abnormalities. Non-dopa responsive parkinsonism occurs in the later stages of choreic disease or as the predominant feature of juvenile patients (Westphal variant). Late onset Huntington's disease presenting as levodopa responsive parkinsonism is rare. A series of four patients with late onset Huntington's disease presenting as levodopa responsive parkinsonism and cardiovascular dysautonomia, initially misdiagnosed as multiple system atrophy (MSA) in three patients, is reported. Levodopa treatment did not unmask significant chorea. These cases suggest the presence of a distinct phenotypic variant of Huntington's disease to be added to the differential diagnosis of other akinetic rigid syndromes.**

(*J Neurol Neurosurg Psychiatry* 2000;68:238-241)

Keywords: Huntington's disease; chorea; dopa-responsive; multiple system atrophy; postural hypotension

The classic presentations of Huntington's disease, an autosomal dominant neurodegenerative disorder associated with a CAG triplet repeat expansion in the IT 15 gene, includes chorea, dystonia and tics, a range of neuropsychiatric abnormalities, dementia, and disorders of gait.<sup>1-3</sup> Considerable heterogeneity, however, has been recognised in relation to the clinical phenotype.<sup>4-6</sup> Non-levodopa responsive parkinsonism may be the dominant presenting feature in young patients, the so called "Westphal" variant, which seems to account for about 85% of childhood onset Huntington's disease.<sup>5,7</sup> Other phenotypic variants such as patients with adult onset disease with minimal cognitive impairment and pure chorea have been reported.<sup>4</sup> In adults non-iatrogenic parkinsonism as a presenting feature of late onset Huntington's disease (onset after 50 years age) is rare. Bittenbender and Quadfasel reviewed the literature on akinetic and rigid forms of Huntington's disease and concluded that the rigid form is commoner than generally

appreciated.<sup>5</sup> However, the mean age of onset of "rigid Huntington's disease" documented in this review ranged from 22.2 years to 37.8 years, which is substantially younger than that of our patients. To our knowledge, only two patients with late onset Huntington's disease and levodopa responsive parkinsonism have been previously reported. Trosch and Le Witt<sup>8</sup> reported one patient with late onset Huntington's disease with parkinsonism responsive to levodopa and Racette and Perlmutter<sup>9</sup> reported the case of a 38 year old man with an akinetic-rigid syndrome, loss of balance, and mild dementia relieved by high doses of levodopa. In this paper, we report a series of four patients with genetically confirmed late onset (mean age of onset 56.75 years) Huntington's disease presenting with levodopa responsive parkinsonism along with combinations of limb dystonia, gait apraxia, torticollis, and myoclonus causing considerable diagnostic confusion. Three patients were initially misdiagnosed as having multiple system atrophy (MSA). Additional features of note in these patients included an uncertain family history, minimal chorea, and minimal cognitive impairment.

### Case reports

#### CASE 1

A 63 year old right handed white man with a presumptive diagnosis of MSA was referred for tertiary opinion. He gave a 3 year history of slowly progressive ataxic gait, falls, abnormal posturing of his right arm, and slurred speech. On examination, he had a dominantly axial akinetic rigid syndrome with a wide based gait, impaired postural reflexes, and a tendency to fall backwards. Dystonic posturing of his right arm and mild chorea of the left fingers were noted and rigidity was more marked in the right upper limb. He had mild difficulties on routine cognitive testing and eye movements showed a saccadic pursuit movement but no supranuclear gaze palsy. There were no pyramidal signs. Family history was that of "probable Parkinson's disease" in a paternal aunt and "tremor" in a maternal aunt. He had mild urinary frequency but sphincter electromyography (SEMG) studies were highly abnormal. Neuropsychometry showed a verbal IQ of 81 and performance IQ of 76, with an

The Regional Movement Disorders Unit, Department of Neurology, Regional Neurosciences Centre, King's College Hospital, Guy's, King's, and St Thomas School of Medicine, London, UK  
I Reuter  
M T M Hu  
C Clough  
K Ray Chaudhuri

MRC Cyclotron Unit, Imperial College School of Medicine, Hammersmith Hospital, London, UK  
M T M Hu  
T C Andrews  
D J Brooks

University Hospital Lewisham, London, UK  
K Ray Chaudhuri

Correspondence to:  
Dr K Ray Chaudhuri,  
Department of Clinical Neurosciences, Mapother House, King's College Hospital, Denmark Hill, London SE5 9RS, UK  
email  
judy.grimshaw@kcl.ac.uk

Received 7 April 1999 and in revised form  
17 September 1999  
Accepted 21 October 1999

## Patient characteristics

Age	Disease duration (y)	Initial diagnosis	Estimated IQ	CAG Repeat length	Levodopa		Family history	Chorea	Dystonia	SEMG
					Dose mg/day	Response				
63	5	MSA	91	18/43	400	++	P	±	-	AB
67	7	PD/MSA	95	19/44	800	+++	P	-	CC/LL	ND
52	7	ARS	94	17/46	200	+	C/HD	-	UL	ND
68	4	MSA	NA	17/42	400	++	P/E/M	±	LL	ND

P=parkinsonism; C=chorea; E=epilepsy; M=motor neuron disease; ARS=akinetic-rigid syndrome; NA=not available; ND=not done; CC=craniocervical; LL=lower limb; UL=upper limb; AB=abnormal.

estimated IQ of 91. Verbal subtests showed average results and non-verbal reasoning and memory functioning was borderline defective. Language functioning and perception was good. Brain MRI showed generalised atrophy and single photon emission tomography (SPECT) indicated left temporoparietal hypoperfusion. A standardised levodopa challenge test showed greater than 30% improvement on the modified King's College Hospital Parkinson's disease rating scale (KCHPDRS).<sup>10</sup> However, because of coexistent mild chorea and a family history of parkinsonism, genetic tests for Huntington's disease and dentatorubro-pallidoluysian atrophy (DRPLA) were carried out and testing for Huntington's disease was positive (table). At 2 year follow up, the patient has continuing levodopa responsiveness (400 mg/day) with minimal chorea and no deterioration in cognitive function.

## CASE 2

A 67 year old right handed white man was referred with a 6 year history of slowness of manual dexterity and gait. He and his carer denied history of cognitive decline, falls, or urinary difficulties although there was erectile dysfunction. His father was thought to have Parkinson's disease and family history was otherwise negative. On examination, he had a bradykinesia dominant akinetic rigid syndrome with a left sided emphasis and impaired postural reflexes. In addition, there was a right laterocollis and dystonic posturing of his left hand. Eye movements showed breaking up of smooth pursuit but no supranuclear gaze palsy or impersistence of tongue protrusion. A levodopa challenge test was strongly positive with greater than 40% improvement in KCHPDRS and he was thought to have Parkinson's disease or the parkinsonian variant of MSA (MSA-P). Neuropsychometry showed a verbal IQ of 105 and a performance IQ of 93 with an estimated IQ of 95. All other neuropsychological testing was rated at the average level with no significant impairment. Brain MRI showed abnormal enhancement at the striatal region. Genetic tests performed because of family history of parkinsonism and dystonia at onset of illness was negative for DRPLA but positive for Huntington's disease (table). At 2 year follow up the patient continues to be dopa responsive (levodopa dose 800 mg) with mild progression of clinical signs (table).

## CASE 3

A 52 year old white left handed woman was referred because of a 5 year history of increas-

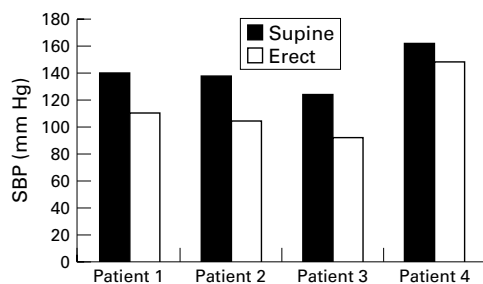
ing slowness and difficulty in walking. She had a family history of movement disorders including chorea and one sister was known to have parkinsonism, later diagnosed as Huntington's disease. On examination, she had an akinetic rigid syndrome with frequent gait freezing and reduced left arm swing with dystonic posturing of the left hand. She had reduced saccadic and pursuit upgaze but no supranuclear downgaze paresis, impersistence of tongue protrusion, or chorea. The initial diagnosis was thought to be a variant of akinetic rigid syndrome. Levodopa therapy at a dose of 600 mg produced moderate benefit but unmasked slight chorea of her face and limbs after therapy for 1 year. Neuropsychometry showed a verbal IQ of 90 and a performance IQ of 95 with an estimated IQ of 94. Other tests were rated as average. A genetic test for Huntington's disease was positive (table). Levodopa therapy had to be discontinued because of dyskinesias and decreased response with time.

## CASE 4

A 68 year old white man presented with a 4 year history of unsteady gait and swallowing difficulties. There was history of parkinsonism, epilepsy, motor neuron disease, and narcolepsy in the family. On examination, he had mild asymmetric parkinsonism with global hyperreflexia, extensor plantar responses, heel-toe ataxia, dystonia of lower limbs, but normal eye movements. There was a mild dysdiadochokinesis. The differential diagnoses included spinocerebellar ataxia, MSA, and other hereditary degenerative akinetic rigid syndromes. Levodopa therapy (300 mg) improved bradykinesia and rigidity and the patient continues with 400 mg of levodopa at 2 year follow up. Formal neuropsychometry could not be performed but a mini mental state examination documented a score of 25/30. Brain MRI showed generalised cerebral and caudate atrophy. A genetic test for Huntington's disease was positive (table).

In all patients the following tests were normal or negative: an autoantibody and acanthocyte screen, thyroid function tests, vitamin B12/folate concentrations, angiotensin converting enzymes, lysosomal enzymes, urinary organic and amino acids, slit lamp examination of eye, and serum copper and caeruloplasmin (case 3).

Autonomic signs and symptoms were evident in all patients and included mild but significant systolic postural hypotension in three patients (figure). Additionally, urinary frequency was present in patients 1 and 4 and



Changes in systolic blood pressure (SBP) while supine and after 3 minutes standing in four patients with Huntington's disease.

facial hyperhidrosis in patient 1. As noted previously, SEMG studies were highly abnormal in patient 1.

## Results

### POSITRON EMISSION TOMOGRAPHY (PET)

PET was performed in patients 1, 2, and 3. Patient 1 had a striatal fluorodopa uptake within the normal range and patient 2 demonstrated markedly reduced and asymmetric fluorodopa uptake in the putamen (right more affected than the left) with relative caudate sparing.  $^{11}\text{C}$  raclopride PET studies in patient 2 showed supranormal  $\text{D}_2$  receptor binding in the right putamen suggesting an up regulation of postsynaptic  $\text{D}_2$  receptors in response to reduced dopamine release. The caudate  $\text{D}_2$  receptor binding in this patient was reduced, suggesting early Huntington's disease. Patients 1 and 3 had reduced caudate and putamen  $^{11}\text{C}$  raclopride binding.

## Discussion

This series of four patients illustrates that (a) levodopa responsive parkinsonism may be a presenting feature of late onset Huntington's disease; (b) these patients may be misdiagnosed as MSA or atypical akinetic rigid syndromes; (c) dysautonomia may complicate clinical diagnosis in favour of MSA; and (d) a family history of "Parkinson's disease" may be a misleading clue in these cases.

We think that this is the first report of a series of patients with Huntington's disease presenting with a moderately levodopa responsive parkinsonism, mild dysautonomia, and a family history of parkinsonism. Other atypical features include the late age of onset of disease (56.75 years), asymmetric parkinsonism, absence of eye or tongue movement abnormalities seen in Huntington's disease, abnormal sphincter EMG in one patient, lack of appreciable limb chorea and cognitive abnormalities, and mild dysautonomia manifest as postural hypotension, urinary frequency, and hyperhidrosis. Reports of such patients are extremely rare although recently two such patients have been described and one of these, reported on by Racette and Perlmuter,<sup>9</sup> had a family history of a tremor disorder. Rigid and akinetic forms of Huntington's disease were also reported by Bittenbender and Quadfasel, who described four "rigid" cases of Huntington's disease and reviewed the literature on this subject.<sup>5</sup> The mean age of onset of disease in

these cases was 15.2 years, suggesting that these were of juvenile onset and thus different from our patient group. While reviewing the literature, these authors documented 64 cases of rigid Huntington's disease with varying combinations of chorea, family history, cognitive impairment, and a mean age of onset of 22.2 years.<sup>5</sup>

The clinical phenotype and the unusual family histories in our patients led to misdiagnosis of these cases as MSA (patients 1, 2, and 4); supported by an abnormal sphincter EMG in patient 1, query Parkinson's disease (patient 2), and an atypical akinetic-rigid syndrome (patient 3). These diagnoses were further supported by a positive levodopa response without unmasking chorea (a feature used to test for Huntington's disease before genetic testing), cardiovascular dysautonomia particularly postural hypotension, the presence of early falls and craniocervical and limb dystonias, and a lack of chorea and appreciable cognitive dysfunction. The diagnosis of Huntington's disease was suspected on the basis of the atypical signs described above and the fact that MSA is rarely familial. There was a family history of Huntington's disease in one patient (patient 3). However, a high index of suspicion is required as otherwise our patients could have been included in a familial Parkinson's disease or MSA study or clinical trial.

In choreic and asymptomatic carriers of the Huntington's disease gene, workers have reported a selective depletion of enkephalin immunoreactive terminals (colocalised in the indirect  $\text{D}_2$  expressing external striatopallidal pathway).<sup>11,12</sup> However, in patients with akinetic-rigid Huntington's disease a near total loss of both indirect and direct striatopallidal fibres containing enkephalin as well as GABA and substance P have been reported.<sup>13,14</sup> Studies using PET have shown that reduced striatal glucose metabolism and dopamine receptor binding occurs in symptomatic patients in Huntington's disease and reduction of striatal  $\text{D}_1$  and  $\text{D}_2$  receptor binding in about 50% of at risk asymptomatic adults and mutation carriers.<sup>15</sup> In our series, patient 1 had normal striatal fluorodopa uptake thus ruling out concurrent Parkinson's disease whereas in patient 2, fluorodopa uptake in the putamen was reduced in an asymmetric fashion with relative sparing of caudate as seen in Parkinson's disease. However, in this patient, caudate  $\text{D}_2$  binding was reduced suggesting early Huntington's disease. Although the possibility of coexistent Parkinson's disease in this patient exists, clinically this is unlikely as there was early postural reflex impairment, laterocollis, and dystonia at the onset of disease. Furthermore, we have reported postmortem findings on another patient with late onset Huntington's disease with levodopa responsive parkinsonism and chorea who did not have Lewy bodies.<sup>16</sup> This also suggests that the levodopa responsiveness in Huntington's disease is unlikely to be due to concurrent Parkinson's disease. The issue of dopa responsiveness and parkinsonism as the presenting feature in late onset Huntington's disease is also unusual and merits discussion.

Although both cases reported by Trosch and LeWitt<sup>8</sup> and Racette and Perlmutter<sup>9</sup> were levodopa responsive, the first responded only to large doses while in the second follow up information after 1 year is not available. Our patients (except patient 3) continue to derive benefit from a moderate dose of levodopa (mean dose 533.3 (SD 52) mg) at 2 year follow up. Benefit from levodopa in Huntington's disease has previously only been reported in the juvenile hypokinetic-rigid variant.<sup>17</sup> A recent <sup>11</sup>C DTBZ PET study has shown that striatal vesicular monoamine transporter type 2 (VMAT2) binding is markedly reduced in the posterior putamen of patients with akinetic rigid Huntington's disease.<sup>18</sup> This would indicate that the nigrostriatal pathway is additionally involved in akinetic rigid Huntington's disease. The beneficial effect of levodopa in these patients with Huntington's disease may reflect facilitation of neurotransmission through a damaged nigrostriatal pathway.

All our patients had small expansions of CAG repeats in IT 15 (42–46, normal <38), as did the patient reported on by Racette and Perlmutter.<sup>8</sup> Patients with juvenile onset parkinsonian Huntington's disease tend to have CAG repeats in excess of 60, which correlates with a rapidly progressive course of Huntington's disease, by contrast with slowly progressive disease seen in our patients. It may be speculated that the small CAG repeat expansion in our patients accounts for their slowly progressive disease.

In conclusion, we have described a distinct variant of Huntington's disease with the following features:

(1) Late onset parkinsonism with moderate and persistent dopa responsiveness at 2 year follow up, without inducing chorea.

(2) Minimal or absent chorea or significant cognitive, eye and tongue movement abnormalities.

(3) Family history of "parkinsonism" or other movement disorders.

#### (4) Mild cardiovascular dysautonomia.

We thank Drs C M Timberlake, NPS Bajaj, and D Collier for helpful comments, A Dean for necropsy studies, and J Grimshaw for secretarial assistance.

- 1 Bruyn GW. Huntington's chorea: historical, clinical and laboratory synopsis. In: Vinken PJ, Bruyn GW, eds. *Handbook of clinical neurology*. Vol 6. Amsterdam: North Press Publishing 1968;6:298–378.
- 2 Huntington's Disease Collaborative Research Group. A novel gene containing a trinucleotide repeat that is expanded and unstable in Huntington's disease chromosomes. *Cell* 1993;72:971–83.
- 3 Folstein SE. *Huntington's disease. A disorder of families*. Baltimore: Johns Hopkins University Press, 1989.
- 4 Britton JW, Uitti RJ, Ahlskog JE, et al. Hereditary late onset chorea without significant dementia. Genetic evidence for substantial phenotypic variant in HD. *Neurology* 1995;45:443–7.
- 5 Bittenbender JB, Quadfasel FA. Rigid and akinetic forms of Huntington's chorea. *Arch Neurol* 1962;7:37–50.
- 6 Bird MT, Paulson GW. The rigid form of Huntington's chorea. *Neurology* 1971;21:271–6.
- 7 Brion S, Comoy C. Rigidite et choree de Huntington: la forme infantile de la maladie de Huntington (etude d'un cas anatomo-clinique). *Rev Neurol* 1965;112:183–99.
- 8 Trosch RM, LeWitt PA. Westphal variant Huntington's disease masquerading as MSA. *Mov Disord* 1996;11(suppl 2):181.
- 9 Raclette BA, Perlmutter JS. Levodopa responsive parkinsonism in an adult with Huntington's disease. *J Neurol Neurosurg Psychiatry* 1998;65:577–9.
- 10 Quinn NP, Marsden CD, Parkes JD. Complicated response fluctuations in Parkinson's disease: response to intravenous infusions of levodopa. *Lancet* 1982;ii:412–15.
- 11 Reiner A, Albin RL, Anderson KD, et al. Differential loss of striatal projection neurons in HD. *Proc Natl Acad Sci USA* 1988;85:5733–7.
- 12 Storey E, Beal MF. Neurochemical substrates of rigidity and chorea in Huntington's disease. *Brain* 1993;116:1201–22.
- 13 Albin RL, Reiner A, Anderson KD, et al. Striatal and nigral neuron subpopulations in rigid HD: implications for the functional anatomy of chorea and rigidity-akinesia. *Ann Neurol* 1990;27:357–65.
- 14 Bugiani O, Tabaton M, Cammarata S. Huntington's disease: survival of large striatal neurons in the rigid variant. *Ann Neurol* 1984;15:155–6.
- 15 Andrews TC, Brooks DJ. Advances in the understanding of early Huntington's disease using the functional imaging techniques of PET and SPET. *Molecular Medicine Today* 1998;12:532–9.
- 16 Chaudhuri K Ray, Reuter I, Andrews T, et al. Late onset Huntington's disease presenting with dopa-responsive parkinsonism and minimal chorea. A new phenotypic variant. *Mov Disord* 1998;13(suppl 2):167.
- 17 Jongen PJH, Renier WO, Gabreels FJM. Seven cases of Huntington's chorea in childhood and levodopa induced improvement of hypokinetic-rigid form. *Clin Neurol Neurosurg* 1980;82:251–61.
- 18 Bohnen NI, Meyer P, Koeppe RA, et al. Decreased striatal monoaminergic terminals in Huntington's disease demonstrated with (+)-[C-11]DTBZ PET. *J Nucl Med* 1998; 5(suppl):125P.