

SHORT REPORT

Complete bilateral horizontal gaze paralysis disclosing multiple sclerosis

D Milea, M Napolitano, H Dechy, P Le Hoang, J-Y Delattre, C Pierrot-Deseilligny

Abstract

Two women presented with bilateral internuclear ophthalmoplegia evolving in a few days to complete bilateral horizontal gaze paralysis. Convergence and vertical eye movements were normal. Cerebral MRI showed a few small white matter lesions in the lateral ventricle regions, and, at the brainstem level, a single, small, bilateral lesion affecting the posterior part of the medial pontine tegmentum and responsible for the clinical syndrome. The condition gradually improved in both patients, following a similar progression as at the onset: improvement first involved the adduction movements in both eyes, whereas bilateral abduction paresis still persisted for a few weeks, before complete recovery of eye movements. Bilateral damage to the medial longitudinal fasciculus and subsequent lateral extent of damage to the region of the two abducens emerging fibres may explain the clinical findings. In both cases, the cause was probably multiple sclerosis.

(*J Neurol Neurosurg Psychiatry* 2001;70:252-255)

Keywords: multiple sclerosis; bilateral gaze palsy; internuclear ophthalmoplegia

Complete bilateral horizontal gaze paralysis is a rare disorder which has been reported in bilateral pontine lesions due to infarction,¹ haemorrhage,^{2,3} or metastasis.⁴ Demyelinating lesions may also be responsible for bilateral horizontal gaze paresis,⁵⁻⁷ but, to our knowledge, complete bilateral horizontal gaze paralysis—that is, without any remaining lateral eye movement—has not been reported so far in this disorder. We report on two patients with such a syndrome resulting from demyelinating lesions, probably due to multiple sclerosis.

Case 1

A 31 year old woman with an unremarkable medical history presented for sudden onset of horizontal diplopia. On examination, horizontal eye movements were abnormal: adduction saccades of either eye were impossible, whereas abduction saccades were present, with a dissociated monocular nystagmus existing in the abducting eye. Convergence and vertical eye movements were unaffected in either eye. Ocu-

locephalic manoeuvre failed to improve horizontal eye movements. Bilateral internuclear ophthalmoplegia was therefore diagnosed. Four days later, diplopia spontaneously resolved, but both eyes remained fixed on the midline because of subsequent bilateral abduction failure. The details concerning the onset of this abduction failure (directly symmetric or firstly asymmetric for a few days) are not known. Thus, at this second stage, a complete bilateral horizontal gaze paralysis was seen, with absence of horizontal saccades, pursuit, and oculocephalic movements. Convergence was still preserved. Vertical eye movements seemed qualitatively normal. Eye movement recordings using electro-oculography confirmed that no lateral conjugate eye movements persisted. Vertical eye movements were not recorded. There was also a right peripheral facial paresis, but the remainder of the neurological examination was normal. Brain MRI, performed while the bilateral horizontal gaze paralysis existed, showed a few bilateral white matter signals on T2 weighted images in the lateral ventricle regions and a single lesion in the brain stem, affecting bilaterally the posterior and medial part of the lower pontine tegmentum—namely, the region of the abducens nucleus and the adjacent medial longitudinal fasciculus (MLF) on both sides (fig 1 A). The investigation included routine blood tests, which were normal. There were no immunological abnormalities in the serum. Cerebrospinal fluid was within normal limits and no oligoclonal bands were found. Treatment with intravenous steroids (1000 mg/day methylprednisolone for 5 days) resulted in rapid recovery of the facial palsy. After 1 week of complete horizontal gaze paralysis, a progressive improvement of adduction was noted in both eyes, with transient recurrence of horizontal diplopia due to persistent severe bilateral abduction paresis. After a few weeks, adduction was normal and a partial reduction in bilateral abduction paresis was also seen. Two months after the onset, ocular motility was normal. At this time, the patient complained of dysaesthesia in her left arm and multiple sclerosis was diagnosed. On examination, no other neurological abnormality existed. Treatment using β -interferon was started, and, 1 year later, the patient had no neurological symptoms and was

Department of
Ophthalmology,
Hôpital de la
Pitié-Salpêtrière,
Paris, France
D Milea
P Le Hoang

Department of
Neurology and
INSERM 289
M Napolitano
J-Y Delattre
C Pierrot-Deseilligny

Hôpital Ambroise
Paré,
Boulogne-sur-Seine,
France
H Dechy

Correspondence to:
C Pierrot-Deseilligny,
Service de Neurologie 1,
Hôpital de la
Pitié-Salpêtrière, 47
Boulevard de l'Hôpital,
75651 Paris Cedex 13,
France
cp.deseilligny@
psl.ap-hop-paris.fr

Received 10 December 1999
and in revised form
19 October 2000
Accepted 26 October 2000

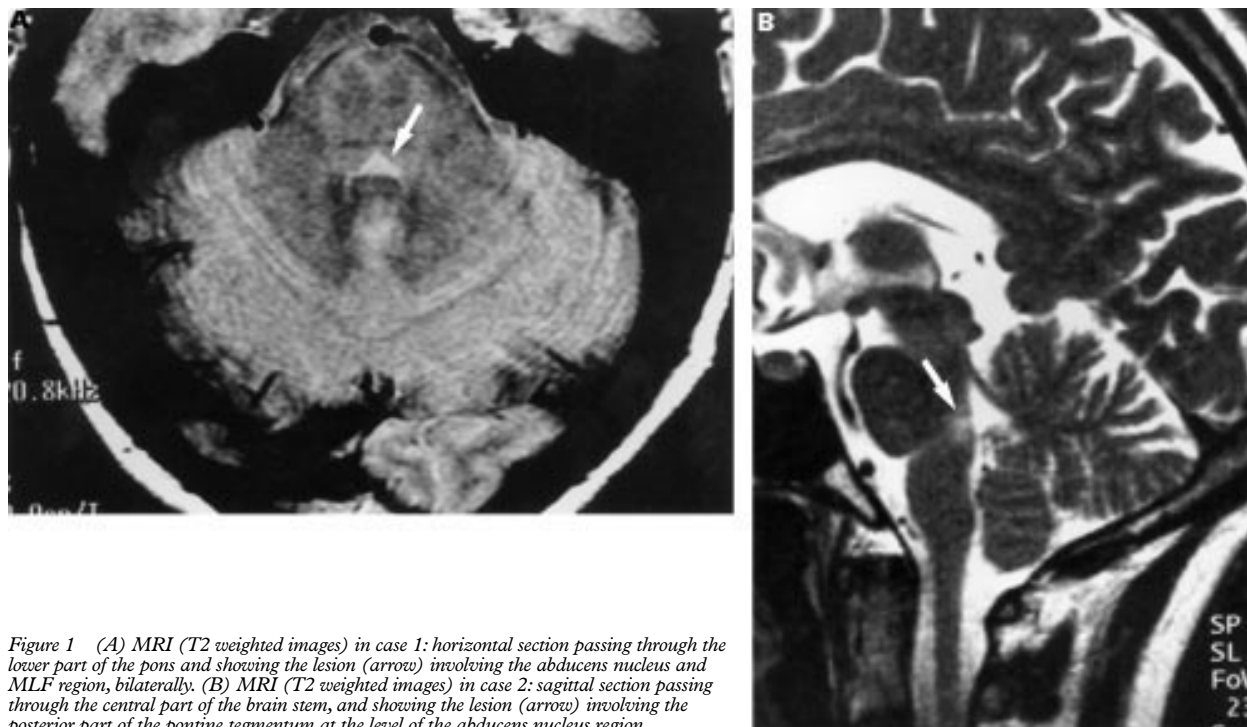


Figure 1 (A) MRI (T2 weighted images) in case 1: horizontal section passing through the lower part of the pons and showing the lesion (arrow) involving the abducens nucleus and MLF region, bilaterally. (B) MRI (T2 weighted images) in case 2: sagittal section passing through the central part of the brain stem, and showing the lesion (arrow) involving the posterior part of the pontine tegmentum at the level of the abducens nucleus region.

normal on examination. Brain MRI was not repeated.

Case 2

A 30 year old woman, with a history of congenital strabismus, surgically corrected at the age of 14, suddenly complained of dizziness and ocular motor disturbances lasting several days. On examination, bilateral adduction paralysis with preservation of convergence was seen. There was also an abduction nystagmus in both lateral directions. Typical bilateral internuclear ophthalmoplegia therefore was diagnosed. A moderate peripheral paresis of the right facial nerve was present, but no other neurological signs were seen. The patient's condition progressively worsened and 1 week later, when she was examined again, a complete bilateral horizontal gaze paralysis was found, with absence of abduction and adduction in both eyes and for all lateral eye movements—saccades, pursuit, and oculocephalic movements. Convergence and vertical ocular motility were unaffected. The remainder of the neurological examination was normal. Cerebral MRI, performed at this stage, showed a few hyperintense T2 weighted lesions in the periventricular white matter of the cerebral hemispheres and a single, bilateral lesion in the brain stem, affecting the posterior and medial part of the lower pontine tegmentum—that is, the same region as in case 1 (fig 1 B). The lumbar puncture disclosed 0.38 g/l proteinorachia, with several oligoclonal bands and 3 cells/mm³. Rheumatoid factor, antinuclear antibodies, immunoelectrophoresis, complement, and immune complex concentrations in the serum were normal. Visual evoked potentials were significantly impaired in both eyes, but somatosensory and auditory evoked potentials were normal. As multiple sclerosis was suspected, a

treatment using intravenous methylprednisolone (1000 mg/day) was started. Allergic exanthema occurred after the first administration and the treatment was stopped. A spontaneous, progressive recovery of eye movements started 1 week later, involving first adduction and subsequently abduction of both eyes. Therefore, a mild bilateral abduction paresis with horizontal diplopia but normal adduction was seen for a few weeks after the bilateral horizontal gaze paralysis. Two months after the first symptoms, eye movements were normal and MRI was not repeated.

Discussion

There were remarkable similarities in the characteristics and cause of the ocular motor abnormalities in our two patients. There was a complete bilateral horizontal gaze paralysis for all lateral eye movements, which is a very rare syndrome. Furthermore, the course of the eye movement disturbances reported here is, to our knowledge, unique, and was similar in each patient, as the bilateral horizontal gaze paralysis lasted 1 week and was preceded for a few days by an isolated bilateral internuclear ophthalmoplegia and followed for a few weeks by a single bilateral abduction paresis before complete recovery. Lastly, in both cases, the complete bilateral horizontal gaze paralysis was only associated with a unilateral peripheral facial paresis and was the first clinical sign, likely due to multiple sclerosis, a cause which has not yet been reported in such a syndrome.

In a CNS pathology, a complete unilateral or bilateral horizontal gaze paralysis—that is, for all types of lateral eye movements—implies a pontine lesion.^{8,9} The final common pathway of conjugate lateral eye movements begins in the abducens nucleus, which contains two intermingled populations of neurons: (1) the motor

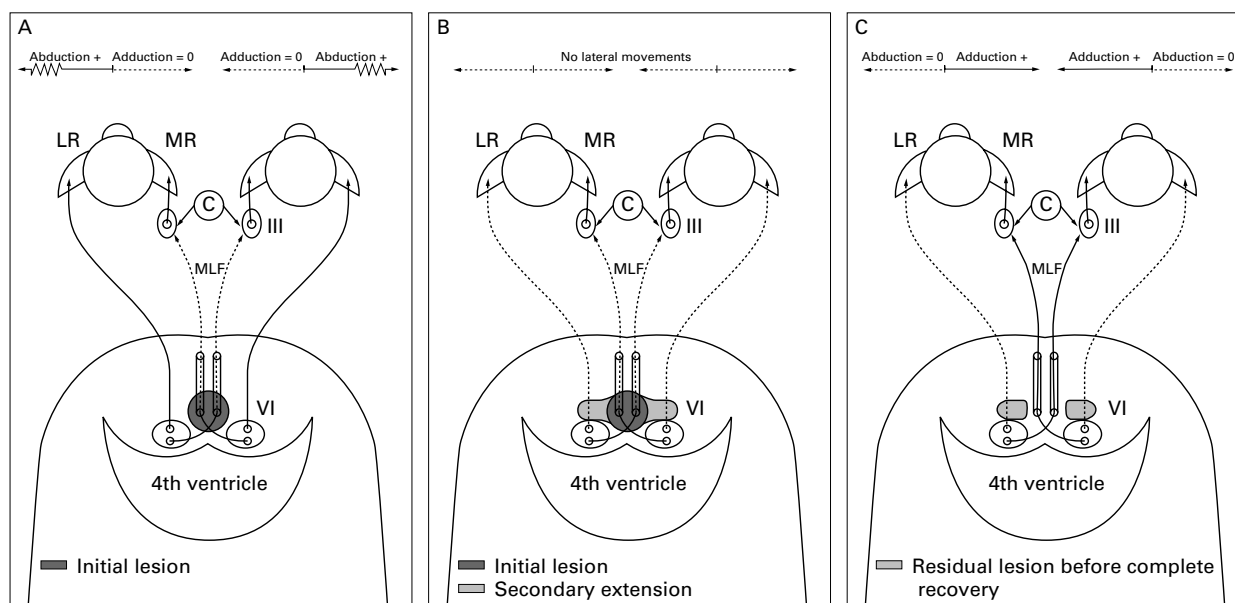


Figure 2 Hypothetical course of the lesions in the brainstem. (A) Both MLFs are affected, resulting in bilateral internuclear ophthalmoplegia. (B) A bilateral extension of the lesions to the abducens nucleus region would explain the complete horizontal gaze paralysis. (C) Recovery starts at the level of the MLFs, bilaterally, with persistence of both lateral parts of the lesion, which would explain the recovery of adduction and the continued impairment of abduction at this third stage. C = Convergence; LR = lateral rectus; MLF = medial longitudinal fasciculus; MR = medial rectus; III = oculomotor nucleus; VI = abducens nucleus.

neurons of the sixth nerve controlling abduction and (2) the internuclear neurons ensuring conjugate adduction via the contralateral MLF and oculomotor nucleus (III).

A complete unilateral gaze paralysis for all conjugate lateral eye movements may therefore be due either to a single pontine lesion affecting the ipsilateral abducens nucleus, or to two different pontine lesions, the first affecting the ipsilateral abducens fibres in their course at the lower pontine level, and the second the contralateral MLF (somewhere between the abducens nucleus and the third nerve nucleus). In the case of a complete bilateral horizontal gaze paralysis, as in our two patients, the lesion(s) may either affect both abducens nuclei, or the MLFs (controlling adduction) and the abducens fibres (controlling abduction) on both sides. In these two hypotheses, convergence and vertical eye movements are preserved because these eye movements are controlled by midbrain structures. Which of these hypotheses seems more likely in our two patients?

In both cases, the course of the ocular motor abnormalities suggests that damage first involved both MLFs and secondarily extended laterally on each side to the adjacent abducens fibres emerging from abducens nuclei (fig 2 A and B). There was a bilateral internuclear ophthalmoplegia at the beginning of the ocular motor disturbances. Such a syndrome implies bilateral damage to the MLFs, usually due to a single median lesion in the posterior part of the pontine tegmentum, where these two fasciculi are very close to each other near the midline. At the recovery stage, in our two patients, only a bilateral abduction paresis persisted, with normal adduction (fig 2 C). Therefore, at this stage, it may be deduced that (1) MLFs were no longer affected as bilateral adduction was present, (2) the abducens nuclei were not

damaged for the same reason, and (3) the abducens fibres were damaged on both sides because of bilateral abduction paresis. Thus, the course of the ocular motor abnormalities suggests that the extension and regression of the lesions had a centrifugal progression, medially to laterally with: (1) first, at the stage of bilateral internuclear ophthalmoplegia, damage to both MLFs, probably at the level of the abducens nuclei, which are located in the lower pons laterally to the MLFs; (2) then, at the stage of complete bilateral horizontal gaze paralysis, lateral extension of the lesion on both sides (like “wings”) to the regions of the abducens nuclei, probably affecting the abducens fibres at their emergence from the nuclei rather than the nuclei themselves; and (3) finally, at the recovery stage, persistence for a while, of the abducens fibre lesions on both sides. Therefore, two different functional lesions remained at this third stage, each of them being located at the extremity of both lateral wings, whereas the initial median corpus of the lesion (affecting the MLFs) had functionally disappeared. In both cases, the presence of unilateral peripheral facial paresis may be explained by the extension on one side of the lesion to the facial fibres, somewhere in their relatively complicated course just anteriorly or around the abducens nucleus. Brain MRI confirmed in both cases that the lesion affected bilaterally the region of the MLF and abducens nucleus in the lower pons. However, because of insufficient spatial resolution, the MRI results could not contribute to a more detailed topographical discussion.

Lastly, the probable cause was multiple sclerosis, taking into account the age of patients, the regressive course of the ocular motor disturbances and the MRI data in each case, and the existence of a second type of sign 2 months later in case 1 and of inflammatory

signs in the CSF in case 2. In multiple sclerosis, although eye movement abnormalities and bilateral internuclear ophthalmoplegia are frequent, a “one and a half” syndrome⁵⁻⁸ or a complete unilateral conjugate gaze paralysis¹⁰ are rare. To our knowledge, there are no previous reports of complete bilateral horizontal gaze paralysis in multiple sclerosis. Thus, these two patients seem to be unique, both in the course of the ocular motor abnormalities, in three successive stages, and with a probable demyelinating cause.

- 1 Kataoka S, Hori A, Shirakawa T, *et al.* Paramedian pontine infarction. Neurological/topographical correlation. *Stroke* 1997;28:809-15.
- 2 Koehler PJ, Wattendorff AR, Goor C, *et al.* Bilateral horizontal gaze paralysis due to pontine hemorrhage. A case report. *Clin Neurol Neurosurg* 1986;88:121-5.

- 3 Shimura M, Kiyosawa M, Tominaga T, *et al.* Bilateral horizontal gaze palsy with pontine cavernous hemangioma: a case report. *Ophthalmologica* 1997;211:320-2
- 4 Pierrot-Deseilligny C, Goasguen J, Chain F, *et al.* Pontine metastasis with dissociated bilateral horizontal gaze paralysis. *J Neurol Neurosurg Psychiatry* 1984;47:159-64
- 5 Bronstein AM, Rudge P, Gresty MA, *et al.* Abnormalities of horizontal gaze. Clinical, oculographic and magnetic resonance imaging findings. II. Gaze palsy and internuclear ophthalmoplegia. *J Neurol Neurosurg Psychiatry* 1990;53:200-7
- 6 Tan E, Kansu T. Bilateral horizontal gaze palsy in multiple sclerosis. *J Clin Neuroophthalmol* 1990;10:124-6.
- 7 Boghen D, Katz B, Wall M. She could not look to either side. *Surv Ophthalmol* 1996;4:165-70.
- 8 Pierrot-Deseilligny C, Chain F, Gray F, *et al.* The “one-and-a-half” syndrome: electro-oculographic analysis of five cases with deductions about the physiological mechanisms of lateral gaze. *Brain* 1981;104:665-99.
- 9 Pierrot-Deseilligny C, Goasguen J. Isolated abducens nucleus damage due to histiocytosis X. Electro-oculographic analysis and physiological deductions. *Brain* 1984;107:1019-32
- 10 Müri RM, Shermann JF, Cohen L, *et al.* Ocular motor consequences of damage to the abducens nucleus area in humans. *J Neuroophthalmol* 1996;16:191-5.

NEUROLOGICAL STAMP

Charles Robert Richet (1850–1935)

Although he had a preference for literature the French Physiologist Charles Richet studied medicine to please his father, a distinguished surgeon. As a medical student in Paris Charles Richet became interested in hypnosis. This led to the publication of his first paper *Du Somnambulism provoqué*. His experimental work covered a large field—the physiology of nerve and muscle, respiration, body temperature regulation, liver function, and dietetics. In 1885 he found that a small centre within the brain responding to bacterial toxins and foreign proteins was responsible for the accompanying fever. In 1888 he demonstrated that animals injected with bacteria developed antibodies and in 1890 he was the first to employ serum therapy.

His most important work began in 1901. Richet joined a marine exploration with Paul Jones Portier (1866–1962), a professor of comparative physiology at the University of Paris. The exploration was led by Albert I of Monaco, a

specialist in oceanography. Their ship, *Hirondelle II*, was equipped with a laboratory. Richet and Portier found that injections of the fluid from the nematocysts of *Physalia*, the Portuguese man of war, and the tentacles of the sea anemone *Actinia*, could induce a violent reaction in dogs that had survived an earlier injection without distress. If 22 days later a second injection was given the dogs became severely ill and died 25 minutes later. Richet, with Portier, had discovered anaphylaxis, a term Richet coined in 1902 to mean the opposite of phylaxis or protection. By 1903 he had shown that any protein could produce the same effect if there were 3 to 4 weeks between injections. Richet later found that small doses given at frequent intervals could immunise the animal and that susceptibility to anaphylaxis could be transferred by transferring blood from an animal at risk to another. He also found that mixing the blood from the sensitised animal with the substance that had produced the hypersensitivity caused anaphylaxis when injected into the new animal.

The work had profound implications for the newly emerging science of immunology. In 1912 Sir Charles Sherrington wrote of Richet “To honour him is to honour the spirit of physiology in its most graceful, most eloquent and inspiring presentment...” Richet also wrote poetry, fiction, and drama. His poetry was published under the name Charles Ephyeyre. In 1913 Richet was awarded the Nobel prize for physiology or medicine.

In 1953 to commemorate the 50th anniversary of the discovery of anaphylaxis Monaco issued a set of stamps on which the *Hirondelle II* and *physalia* are shown, along with Albert I, Richet, and Portier (Stanley Gibbons 475–477, Scott 303–305).



L F HAAS