

## SHORT REPORT

# Cognitive dysfunction after isolated brain stem insult. An underdiagnosed cause of long term morbidity

P Garrard, D Bradshaw, H R Jäger, A J Thompson, N Losseff, D Playford

*J Neurol Neurosurg Psychiatry* 2002;**73**:191–194

Cognitive dysfunction adversely influences long term outcome after cerebral insult, but the potential for brain stem lesions to produce cognitive as well as physical impairments is not widely recognised. This report describes a series of seven consecutive patients referred to a neurological rehabilitation unit with lesions limited to brain stem structures, all of whom were shown to exhibit deficits in at least one domain of cognition. The practical importance of recognising cognitive dysfunction in this group of patients, and the theoretical significance of the disruption of specific cognitive domains by lesions to distributed neural circuits, are discussed.

Studies concerned with the recovery of independence after brain injury have largely emphasised the importance of motor function, but there is now increasing recognition of the influence of cognitive impairment on functional recovery.<sup>1,2</sup> There persists, however, a widespread assumption that cognition will be spared after an isolated infratentorial insult,<sup>3</sup> and that the focus of rehabilitation in such cases should be on motor recovery. In reality, some such patients need long periods of inpatient management and are often referred to specialist rehabilitation units. Moreover, problems may persist long after discharge: a recent study of young patients with cerebellar infarcts documented a high prevalence of neuropsychiatric symptoms and inability to return to full time work despite a favourable outcome according to the modified Rankin scale.<sup>4</sup>

The contribution of the cerebellum to cognition is well documented,<sup>5</sup> but the evidence for cognitive dysfunction after isolated brain stem insults is scant. Our experience of this group of patients is that they too exhibit cognitive problems that affect function. We therefore present the following survey of patients with isolated brain stem lesions, not only to document the existence of cognitive dysfunction after such insults, but also to highlight their potential for persistent functional morbidity.

### PATIENTS AND METHODS

Between December 1999 and March 2001, seven patients with isolated brain stem lesions demonstrated on magnetic resonance imaging (MRI) were admitted to the neurological rehabilitation unit. All patients underwent detailed neuropsychological assessment using standardised tests with published normative data. Motor and speech difficulties prevented administration of certain tests to some of the patients, but information about a range of cognitive abilities was obtained from all patients (see table 1). There was no suggestion of premorbid neuropsychological dysfunction in any of the patient histories, and none of the MRI scans showed any supratentorial lesions (see fig 1).

The neuropsychological test battery provided estimates of premorbid intellectual function using the National Adult Reading Test (NART)<sup>6</sup> or a standardised demographic

formula,<sup>7</sup> and of current general intellectual performance using the shortened Wechsler Adult Intelligence Scale.<sup>8</sup> In addition, six specific cognitive domains were assessed, using a range of standardised neuropsychological instruments (all with published normative data). A domain was judged to be impaired if performance on one or more measures was below the 10th percentile level or below the cut off score.

- Executive function was tested using one or more of the following: Weigl sorting test,<sup>9</sup> Modified Card Sorting Test,<sup>10</sup> Initial letter fluency,<sup>11</sup> Stroop Colour and Word Test,<sup>12</sup> Trails "B",<sup>13</sup> and Hayling Sentence Completion Test.<sup>14</sup>
- Speed and attention was tested using one or both of the following: Trails "A",<sup>13</sup> and letter cancellation test.<sup>15</sup>
- Name production was assessed using the Graded Naming Test.<sup>16</sup>
- Visual and verbal memory were assessed using the Recognition Memory Test for words and faces, respectively.<sup>17</sup>
- Visuo-perceptual skills were assessed using selected subtests from the Visual Object and Space Perception Battery.<sup>18</sup>

All seven patients were reviewed. The mean age of the group was 44 years (range 29–61). The neuropsychological findings are summarised in table 1, together with the type, site, and relative size of the lesions. Patients and cognitive domains are presented in order of severity of impairment. The figure shows representative axial (left) and coronal (right) slices from six of the seven MR scans (the scans from case seven were not available for reproduction).

### CLINICAL SUMMARIES

#### Case 1

A 43 year old, right handed former nursing sister without past history of neurological deficit or headache, who experienced a sudden onset of weakness and sensory disturbance in the right arm, visual blurring, vomiting, and imbalance. Examination revealed a complex ophthalmoplegia, severe cerebellar dysarthria, right sided sensory disturbance involving the face, and an ataxic quadriparesis. MRI revealed haemorrhage into the midbrain and upper pons, and an underlying cavernoma. During rehabilitation she exhibited marked emotional lability, impulsivity, distractibility, and disinhibition. Formal testing revealed significant deficits in frontal executive function, attention, and word retrieval and a mild weakness of visual memory on a background of marked decline in intellectual capacity. All deficits were found to be persistent at a follow up assessment five months later.

#### Case 2

A 53 year old, right handed man with a history of cigarette smoking, treated hypertension, and hypercholesterolaemia, who developed right hemiplegia anarthria and dysphagia overnight in August 2000. He was admitted to hospital, where examination revealed left third and right lower motor

**Table 1** Summary of imaging and neuropsychological findings in the patient cohort

Case number	Lesion type	Lesion size (rank)	Location	Frontal-executive*	Attention	General intellectual ability	Naming	Visual memory	Verbal memory	Perception	Total domains affected/ tested
1	Acute haemorrhage (cavernoma) with surrounding oedema	2	Haemorrhage centered on superior cerebellar peduncle and inferior colliculus on the left involving the red nucleus and medial lemniscus. Oedema extending into the crus cerebri, substantia nigra and middle cerebellar peduncle on the left.	I	<5th	<5th	<5th	<10th	N	N	5/7
2	Ischaemic lesion	6	Ischaemia of the left midbrain involving the crus cerebri, substantia nigra, red nucleus. High signal along corticospinal tract down to pyramid of medulla. Wallerian degeneration?	I	<5th	<10th	<5th	N	N	N	4/7
3	Acute ischaemia	3	Right inferior cerebellar peduncle. Medial portion of right pons and entire left side of pons between fifth nerves and cerebellar peduncles.	I	<5th	<10th	NT	N	N	N	3/6
4	Acute ischaemia	4	Infarct of pons between the seventh/eighth nerves and fifth nerve on the right side and above the fifth nerve on the left side, mainly involving cortico spinal tracts.	I	<10th	<10th	N	N	N	N	3/7
5	Acute bleed (cavernoma) with some surrounding oedema	1	Haemorrhage on the right side of the pons involving the right medial lemniscus, inferior cerebellar peduncle and right inferior olive. Oedema extends across the midline superiorly into inferior colliculi and crus cerebri on the right.	I	<5th	N	N	N	N	N	2/7
6	Acute infarct	5	Infarct involving medial part of left pons at the level of the 5th nerves and slightly above	N	<5th	N	N	N	<10th	N	2/7
7	Probable infarct	7	Solitary high signal lesion in left pons	I	NT	N	N	N	N	N	1/6

\*Percentile scores could not be calculated for tests of executive function, so cut off scores were used. N=test scores fell within the normal range, I=scores fell within the impaired range on at least two tests of executive function, NT=tests relevant to the cognitive domain were not performed, <5th=scores on one or more measures fell below the 5th percentile compared with age matched controls, <10th=scores on one or more measures fell below the 10th percentile compared with age matched controls.

neurone seventh palsies, leftward deviation of the palate, and a spastic right hemiparesis. MRI revealed an isolated left sided pontine infarct, with no evidence of previous hemispheric pathology. He was transferred for rehabilitation after three months. Neuropsychological assessment revealed significant impairment of executive function, attention and word retrieval, together with a moderate decline in overall intellectual function.

### Case 3

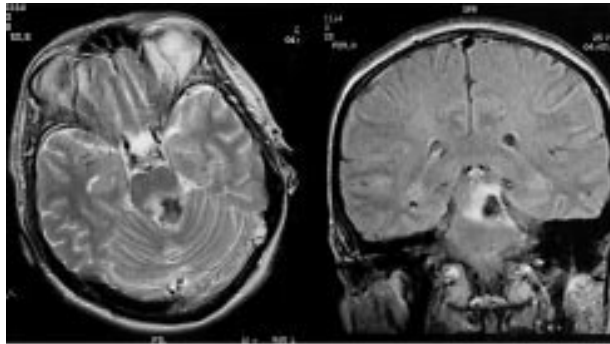
A 44 year old right handed woman who developed neck pain, nausea, dizziness, clumsiness of the right arm, and dysarthria two hours after a hairdressers' appointment at which she had

held her head backwards over a sink. Five days later she developed a right hemiparesis, left conjugate gaze paresis, right facial weakness, and sensory impairment over the right face and left side of the body. MRI showed changes of infarction in the right pons and rostral medulla, and attenuation of the right vertebral and basilar arteries suggestive of thrombosis. She was anticoagulated. Neuropsychological assessment revealed significant impairment in frontal executive function and attention with a mild decline in intellectual capacity.

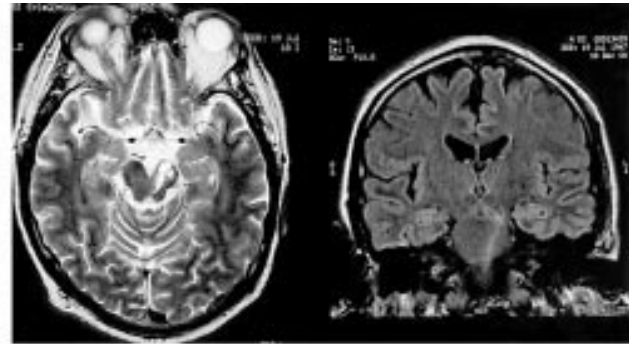
### Case 4

A 37 year old right handed female artist who developed neck pain after slipping while standing on her head during yoga.

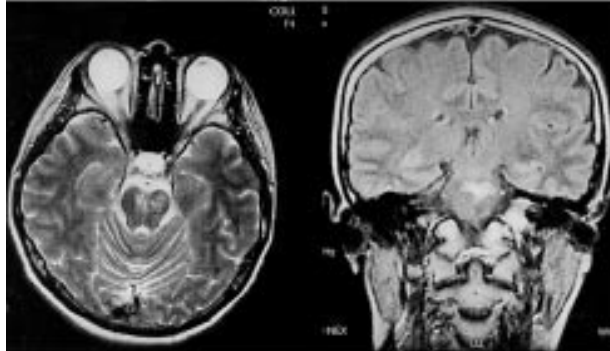
Case 1



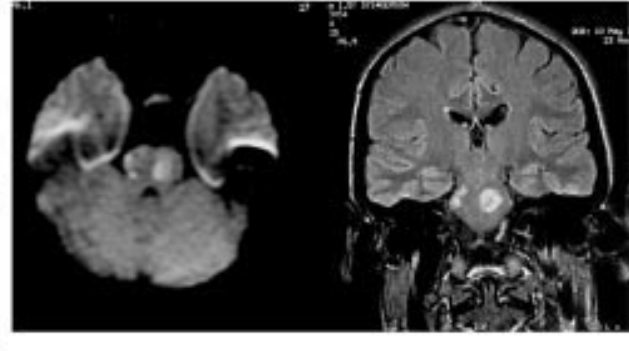
Case 2



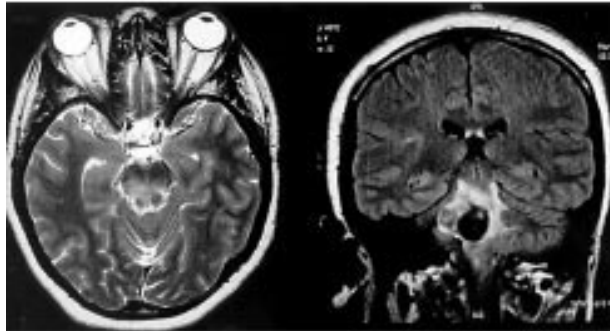
Case 3



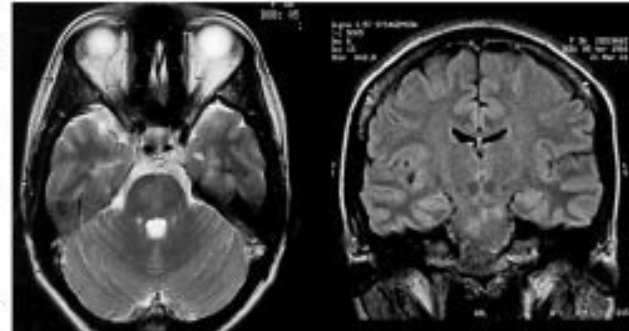
Case 4



Case 5



Case 6



**Figure 1** Sample MR images obtained acutely from patients 1 to 6: axial T2 weighted (DWI in case 4) on the left, coronal FLAIR on the right of each panel. All images show changes of acute vascular insult centred on brain stem structures—haemorrhagic in cases 1 and 5, and ischaemic in cases 2, 3, 4 and 6—together with varying degrees of oedema extending into the midbrain. No supratentorial lesions of any kind are present on any of the images.

Three days later she developed anarthria and quadriplegia overnight. Comprehension was preserved and eye movements intact. MRI showed an isolated pontine infarct, and an absent basilar artery segment, suggesting thrombosis, but no dissection or other source of embolus was detected. Supportive treatment was given and she was anticoagulated. She gradually regained bulbar and limb function over the next two months. During rehabilitation she was subject to episodes of emotional lability. On psychometric testing executive function was significantly impaired, attention was weak, and there was a mild deterioration in overall intellectual function. Follow up assessment after four months showed persistent, though mild, deficits in attention and frontal executive function.

#### Case 5

A 37 year old, Afro-Caribbean female office worker, admitted with a three day history of dull right frontal headache without neck pain. By the time of admission she had developed weakness, paraesthesia and clumsiness of the left side, and

diplopia. She later became drowsy and developed a right facial weakness. On examination the Glasgow Coma Score was 14, there was a divergent squint with right horizontal gaze palsy, fifth and seventh nerve involvement, and an ataxic left hemiparesis. MRI demonstrated a left sided brain stem haemorrhage involving cerebellum, pons and medulla (see fig 1). Neuropsychometric testing revealed significant impairment of frontal executive function and attention.

#### Case 6

A 29 year old, right handed man with a history of occasional cocaine use, who acutely developed anarthria and right sided hemiplegia in November 2000. A similar event associated with severe occipital headache had occurred 24 hours earlier, but resolved spontaneously after two hours. MRI demonstrated an isolated left sided pontine infarct. No evidence for dissection or vasculopathy was found on MRA. A thrombophilia screen was negative and transoesophageal echocardiogram normal. He was transferred for rehabilitation, and during the course of his admission demonstrated a degree of emotional lability.

Formal testing demonstrated significant attentional deficits and mild weakness of verbal memory.

### Case 7

A 51 year old right handed woman with a history of diabetes, hypertension, and heavy cigarette smoking, who presented with left sided facial numbness and right hemiparesis. MRI scan revealed a single high signal lesion in the left pons. Psychometry demonstrated significant frontal executive dysfunction.

### DISCUSSION

This unselected sample of patients referred to a neurological rehabilitation unit with isolated brain stem injury, has demonstrated a high prevalence of cognitive dysfunction. There was a significant impact on function in some cases, which was persistent in two patients. One case (patient 1) was rendered severely disabled by cognitive deficits, which were only partially responsive to compensatory strategies. These observations suggest that similar patterns of disability, either transient or persistent, may be common among such patients.

Although the severity of cognitive deficits was variable, all patients demonstrated impaired attention and all but one showed significant executive dysfunction. The two most severely impaired patients also showed naming deficits, but memory impairment was unusual, and disturbance of posterior cortical function was not seen. The severity of functional impairment was unrelated to the size of the lesion, and different patterns of cognitive impairment did not appear to map in a systematic way to any particular lesion sites in the brain stem. The findings do illustrate, however, that specific domains of cognition may be disrupted by lesions distant from the neural circuitry that is of primary importance to their operation, and perhaps represent a form of "diaschisis".<sup>19</sup>

There are a few single case reports of cognitive dysfunction after brain stem injury,<sup>20, 21</sup> and a systematic study of the same phenomenon in patients with multiple sclerosis<sup>22</sup> though the more widespread nature of the cerebral pathology in the latter case left the importance of the brain stem itself unresolved. By contrast, the deficits documented in the present series probably reflect disruption to cognitively eloquent areas of distributed networks involving both brain stem and hemispheres.<sup>23</sup> The particular pattern of deficits described here implies specific disruption of frontal cortical areas involved in attentional and executive functions. Further studies of this patient group, using functional imaging techniques, may provide insights into the mechanisms of these brainstem-hemisphere interactions. This preliminary survey, however, suggests that deficits underpinned by such mechanisms may be more widespread than has previously been recognised.

### Authors' affiliations

**P Garrard**, Institute of Cognitive Neuroscience, London, UK  
**D Bradshaw, A J Thompson, D Playford**, Department of Neurorehabilitation, National Hospital for Neurology and Neurosurgery, London, UK

**H R Jäger**, Department of Radiology, National Hospital for Neurology and Neurosurgery

**N Losseff**, Department of Neurology, National Hospital for Neurology and Neurosurgery

Correspondence to: Dr P Garrard, Institute of Cognitive Neuroscience, Alexandra House, 17 Queen Square, London WC1N 3AR, UK; pgarrard@ucl.ac.uk

Received 17 October 2001

In revised form 11 April 2002

Accepted 30 April 2002

### REFERENCES

- 1 **Novack T**, Haban G, Graham K. Prediction of stroke rehabilitation outcome from psychologic screening. *Arch Phys Med Rehabil* 1987;**68**:729-34.
- 2 **Galski T**, Bruno R, Zorowitz R. Predicting length of stay, functional outcome and aftercare in the rehabilitation of stroke patients. *Stroke* 1993;**24**:1794-800.
- 3 **Nelles G**, Cotonis KA, Valente SL, et al. Recovery following lateral medullary infarction. *Neurology* 1998;**50**:1418-22.
- 4 **Malm J**, Kristensen B, Karlsson T, et al. Cognitive impairment in young adults with infratentorial infarcts. *Neurology* 1998;**51**:433-40.
- 5 **Fiez J**. Cerebellar contributions to cognition. *Neuron* 1996;**16**:13-15.
- 6 **Nelson HE**. *The national adult reading test*. Windsor: NFER-Nelson, 1982.
- 7 **Krull KR**, Sherer M, Adams RL. A comparison of indices of premorbid intelligence in clinical populations. *Appl Neuropsychol* 1995;**2**:35-8.
- 8 **Wechsler D**. *WAIS-R manual*. New York: The Psychological Corporation, 1981.
- 9 **Weigl E**. On the psychology of the so-called processes of abstraction. *Journal of Normal and Social Psychology* 1941;**36**:3-33.
- 10 **Nelson HE**. A modified card sorting test sensitive to frontal lobe deficits. *Cortex* 1976;**12**:313-24.
- 11 **Benton AL**, Hamsher K deS. *Multilingual aphasia examination*. Iowa City: University of Iowa, 1976.
- 12 **Stroop JR**. Studies of interference in serial verbal reactions. *J Exp Psychol* 1935;**18**:643-62.
- 13 **Reitan RM**. Validity of the Trailmaking test as an indication of organic brain damage. *Percept Mot Skills* 1958;**8**:271-6.
- 14 **Burgess P**, Shallice T. *The Hayling and Brixton Tests*. Bury St Edmunds, Suffolk: England Thames Valley Test Company, 1997.
- 15 **Lezak MD**. *Neuropsychological assessment*. New York: Oxford University Press, 1983.
- 16 **McKenna P**. *Graded naming test*. Windsor, Berks: NFER-Nelson, 1983.
- 17 **Warrington EK**. *Recognition memory test*. Windsor, Berks: NFER-Nelson, 1984.
- 18 **Warrington EK**, James M. *Visual object and space perception test*. Bury St Edmunds, Suffolk: Thames Valley Test Company, 1991.
- 19 **Feeney D**, Baron J-C. Diaschisis. *Stroke* 1986;**17**:817-30.
- 20 **Evyapan D**, Kumral E. Pontine anosognosia for hemiplegia. *Neurology* 1999;**53**:647-9.
- 21 **Crosson B**, Trautt GM. Cortical functioning during recovery from brainstem infarction: a case report. *International Journal of Clinical Neuropsychology* 1981;**2**:3-7.
- 22 **Callanan MM**, Logsdail SJ, Ron MA, et al. Cognitive impairment in patients with clinically isolated lesions of the type seen in multiple sclerosis. A psychometric and MRI study. *Brain* 1989;**112**:361-74.
- 23 **Sturm W**, de Simone A, Krause BJ, et al. Functional anatomy of intrinsic alertness - Evidence for a fronto-parietal-thalamic-brainstem network in the right hemisphere. *Neuropsychologia* 1999;**37**:797-805.