

# fMRI studies of associative encoding in young and elderly controls and mild Alzheimer's disease

R A Sperling, J F Bates, E F Chua, A J Cocchiarella, D M Rentz, B R Rosen, D L Schacter, M S Albert

*J Neurol Neurosurg Psychiatry* 2003;74:44–50

See end of article for authors' affiliations

Correspondence to:  
Dr Reisa Sperling,  
221 Longwood Avenue,  
Boston, MA 02115, USA;  
reisa@rics.bwh.harvard.edu

Received 4 March 2002  
In revised form 22 August  
2002

Accepted 12 September  
2002

**Objective:** To examine alterations in patterns of brain activation seen in normal aging and in mild Alzheimer's disease by functional magnetic resonance imaging (fMRI) during an associative encoding task.

**Methods:** 10 young controls, 10 elderly controls, and seven patients with mild Alzheimer's disease were studied using fMRI during a face–name association encoding task. The fMRI paradigm used a block design with three conditions: novel face–name pairs, repeated face–name pairs, and visual fixation.

**Results:** The young and elderly controls differed primarily in the pattern of activation seen in prefrontal and parietal cortices: elderly controls showed significantly less activation in both superior and inferior prefrontal cortices but greater activation in parietal regions than younger controls during the encoding of novel face–name pairs. Compared with elderly controls, the Alzheimer patients showed significantly less activation in the hippocampal formation but greater activation in the medial parietal and posterior cingulate regions.

**Conclusions:** The pattern of fMRI activation during the encoding of novel associations is differentially altered in the early stages of Alzheimer's disease compared with normal aging.

The ability to consciously learn and retain new information (that is, explicit memory) is typically the earliest cognitive impairment seen in Alzheimer's disease,<sup>1</sup> but it also decreases significantly with advancing age.<sup>2</sup> Recent evidence suggests that the neural substrates underlying these two impairments of explicit memory differ.

There is widespread agreement that the memory impairment seen in Alzheimer's disease is the result of neuronal loss in the perforant pathway of the medial temporal lobe, a region that includes the hippocampus and the entorhinal cortex.<sup>3</sup> Because age related neuronal loss within these brain regions is minimal,<sup>4</sup> memory problems among non-demented older individuals are thought to be related to alterations in the coordinated modulation of other brain regions, based at least in part on decreases in neurotransmitter levels and declines in synaptic integrity.<sup>5</sup>

We therefore sought to determine whether functional magnetic resonance imaging (fMRI) data collected during an explicit encoding task would demonstrate a different pattern of activation in mild Alzheimer's disease from the pattern of alteration seen in normal aging. We chose to study associative encoding because the hippocampus is thought to play a crucial role in binding together previously unrelated items of information.<sup>6</sup> The associative memory task we employed involved forming novel face–name associations. Such tasks appear to be particularly difficult because they require the formation of an association across the visual and verbal domains, and because first names are often arbitrarily assigned and are not conducive to forming associations. Perhaps for this reason, difficulty in remembering proper names is the most common complaint among elderly individuals and in memory disorder clinics.<sup>7, 8</sup>

We have previously reported that the face–name encoding task employed in this study activates a specific set of brain regions in young subjects, which include the striate, fusiform, and prefrontal cortices and the anterior hippocampus.<sup>9</sup> In a second study with a different cohort of young subjects, we examined patterns of activation during pharmacologically

induced memory impairment using lorazepam and scopolamine. In that study we demonstrated reliable activation of these regions using a two week test–retest interval, and then showed alterations in fusiform, prefrontal, and hippocampal regions during pharmacologically induced memory impairment.<sup>10</sup> These studies suggested that there is a specific set of brain regions involved in the encoding of novel associations between names and faces. In the current study, we hypothesised that the functional alterations in this set of brain regions would differ in normal aging from that seen in mild Alzheimer's disease, and that the greatest functional differences between disease related and age related change would be evident in the hippocampus.

## METHODS

### Subjects

Twenty seven right handed subjects were participants in the study. They comprised three groups:

- Young: 10 young controls, mean (SD) age, 24.9 (3.5) years; age range 23 to 33 years; six female, four male;
- Elderly: 10 elderly controls, mean age 74.1 (7.3) years; age range 67 to 88 years; eight female, two male;
- Mild Alzheimer's disease: seven patients with mild probable Alzheimer's disease, mean age 80.6 (6.9) years; age range 71 to 89 years; six female, one male.

The patients with probable Alzheimer's disease were diagnosed according to NINCDS-ADRDA criteria.<sup>11</sup> They were mildly impaired on the basis of their scores on the mini-mental state examination (MMSE)<sup>12</sup> (mean 22.6 (2.2);

**Abbreviations:** fMRI, functional magnetic resonance imaging; MR, magnetic resonance; NINCDS-ADRDA, National Institute of Neurological and Communicative Disorders and Stroke—Alzheimer's Disease and Related Disorders Association; NvF, novel v fixation; NvR, novel v repeated; RvF, repeated v fixation

range 20 to 26). None of the subjects was taking prescription or over the counter drugs with central nervous system effects. All the Alzheimer patients had either been off cholinesterase inhibitors for at least 30 days before scanning or had never taken these agents. All subjects were scanned during the morning hours.

The study was approved by the human research committee of the Massachusetts General Hospital. All subjects provided written informed consent.

### Cognitive activation task

#### Task conditions

The associative encoding task comprised faces (previously unfamiliar to the subjects) paired with fictional first names.<sup>9</sup> The face stimuli were colour photographs taken with a digital camera with a resolution of 924 × 1096 mp. The photographs were of individuals who varied in age (range 18 to 90 years) and ethnicity, with equal numbers of male and female faces. Popular first names were obtained from the public lists on the internet of the most commonly used names for each decade from 1910 to 1990. First names were assigned to each face by the investigators. The face stimuli were centred on a black background with the first name printed in white below the face, forming a face–name pair. Visual stimuli were presented using a Macintosh Computer (Apple) connected to a Sharp 2000 colour LCD projector. Images were projected through a collimating lens (Buhl Optical) onto a screen attached to the head coil during functional data acquisition.

Subjects were given explicit instructions to try to remember which name was associated with which face for later testing. These stimuli were used in a block design paradigm with three conditions:

- Novel: each novel face–name pair was presented once for five seconds. Subjects viewed seven novel face–name pairs during each novel block, seeing a total of 84 novel face–name pairs over the course of the session;
- Repeated: two repeated face–name pairs (one male and one female) were presented for five seconds each, with the male and female face–name pairs alternating throughout each repeated block. The two repeated face–name pairs were first shown to the subject in a practice run immediately before the functional runs, so that these stimuli were already somewhat familiar to the subjects before beginning the functional runs. Each repeated face–name pair was presented 49 times over the course of the session;
- Fixation: subjects were instructed to look at a white fixation cross (+) presented in the centre of the visual field on a black background in order to focus their attention in the visual domain.

#### Post-scan memory testing

Immediately after scanning, subjects were tested for their memory of a subset of the face–name pairs. For this purpose, 12 faces were presented: six from the block of novel face–name pairs, four distracter faces (never presented), and the male and female faces presented throughout the repeated blocks. Subjects were asked to indicate if they had seen the face before with a yes/no answer, and if yes, to recall the name associated with the face.

#### Image acquisition

Structural and echo planar functional images were acquired on a 3.0 tesla General Electric scanner with ANMR upgrade (Advanced NMR Systems, Wilmington, Massachusetts, USA). The standard GE quadrature head coil was used. Subjects were positioned in the head coil with a cervical collar and foam padding to reduce head motion.

A sagittal localiser scan was done first for positioning the slice planes. A spoiled gradient echo structural scan,

consisting of 60 slices (resolution 1.6 × 1.6 × 2.8 mm), was then obtained for registration with the functional data for anatomical localisation. Functional data were then acquired using an asymmetric spin echo T2\* weighted blood oxygen level dependent (BOLD) method with time of repetition (TR) 2500 ms, time of echo (TE) 40 ms, and flip angle 90°; voxel dimensions were 3.125 × 3.125 × 8.0 mm. Twenty slices (7 mm thick; 1 mm gap between slices) were acquired in a coronal orientation, perpendicular to the anterior commissure–posterior commissure line. Scanning time for each functional run was 4 min 15 s, consisting of 102 time points (four for T1 stabilisation and 98 for functional data collection). In all, six functional runs per subject were acquired.

#### Data analysis

Functional MRI data were preprocessed and analysed using statistical parametric mapping<sup>13</sup> (SPM99; <http://www.fil.ion.ucl.ac.uk/spm>; Wellcome Department of Cognitive Neurology) for Matlab (Mathworks Inc). The data were realigned and normalised to the standard SPM99 EPI template and then smoothed with a gaussian kernel of 8 mm. The data were modelled with a fixed response (box-car), and convolved with the canonical haemodynamic response function. A high pass filter of 260 seconds was used for all contrasts.

Activation maps were generated for three contrasts:

- novel *v* fixation (NvF), which primarily provided information on the encoding of novel complex visual face–name stimuli compared with a low level visual fixation;
- repeated *v* fixation (RvF), which primarily provided information on the viewing of familiar complex visual stimuli compared with fixation;
- novel *v* repeated (NvR), which held the visual complexity of the stimuli constant, and thus provided information on the encoding of novel face–name associations compared with viewing familiar face–name associations.

Group averaged activation maps and between-group comparisons (young *v* elderly controls, and elderly controls *v* mild Alzheimer patients) were assessed using SPM 99 random effects models.<sup>14</sup> As we chose to use random effects models and had small numbers of subjects in each group, we used a less conservative significance value than the standard whole brain corrected p value in SPM. Within-group activations were considered to be significant with a height threshold of 0.001 (uncorrected) and an extent threshold of at least 10 contiguous voxels, and between-group differences were considered to be significant at 0.01 (uncorrected) with at least 10 contiguous voxels. Coordinates for peak significant activations were converted from standard MNI coordinate system in SPM 99 to Talairach coordinates (<http://www.mrc-cbu.cam.ac.uk/imaging/mni2tal>) and localised using the neuroanatomical atlas of Talairach and Tournoux.<sup>15</sup>

In order to examine whether there was evidence of hippocampal dysfunction in addition to potential confounding effects on activation caused by atrophy, we sampled MR signal time courses within each subject's hippocampus. We placed a small (6 mm<sup>3</sup>) region of interest in the centre of the hippocampus, guided by each individual subject's hippocampal anatomy, and extracted the MR signal time course to assess whether there was evidence of paradigm linked activation (<http://spm-toolbox.sourceforge.net>).

## RESULTS

### Within-group analyses

The within-group activations for young controls, elderly controls, and mild Alzheimer patients for all contrasts (NvF, RvF, NvR) are shown in table 1.

All subjects showed significant activation in striate and fusiform regions for the NvF contrast. They also all showed

**Table 1** Within-group activations (SPM99 random effects)

Contrast	Region	BA	x	y	z	No of voxels	z Value	p Value (uncorrected)
<b>Young controls</b>								
NvF	Middle/inferior frontal gyrus	BA 9/46	54	27	24	76	4.04	0.00003
	Middle frontal gyrus	BA 6	-42	6	52	189	4.64	0.000002
	Inferior frontal gyrus	BA 47	-27	20	-9	11	3.42	0.0003
	Medial frontal gyrus	BA 6	-6	20	43	58	4.62	0.000002
	Anterior cingulate	BA 33	-6	7	19	18	3.93	0.00004
	Caudate		-18	-2	17	30	3.87	0.00005
	Thalamus		18	-17	15	20	4.21	0.00001
	Hippocampal formation		-24	-24	-11	104	4.66	0.000002
	Hippocampal formation		21	-30	-9	110	4.72	0.000001
	Extrastriate/fusiform gyrus	BA 20	-39	-48	-25	330	4.4	0.000005
	Extrastriate/fusiform gyrus	BA 20	42	-48	-28	105	4.12	0.00002
RvF	Fusiform gyrus	BA 37	42	-48	-25	12	3.38	0.0004
	Extrastriate/fusiform gyrus	BA 19	-45	-62	-22	88	4.5	0.000003
	Extrastriate/fusiform gyrus	BA 19	39	-65	-25	18	3.75	0.00009
	Extrastriate/lingual gyrus	BA 18	-21	-85	-6	31	4.23	0.00001
NvR	Orbital frontal	BA 11/47	27	31	-14	39	4.18	0.00001
	Medial frontal gyrus	BA 6/8	-6	20	43	92	4.26	0.00001
	Inferior frontal gyrus	BA 9	42	16	24	55	4.11	0.00002
	Inferior frontal gyrus	BA 9	-42	10	22	117	3.91	0.00005
	Anterior cingulate	BA 33	6	10	19	13	3.66	0.0001
	Middle frontal gyrus	BA 6	-40	6	55	16	4.71	0.000001
	Hippocampal formation	BA 35	-21	-27	-11	140	5.01	0.0000003
	Hippocampal formation	BA 35	24	-30	-11	99	4.94	0.0000004
	Extrastriate/fusiform gyrus	BA 20	42	-48	-28	103	4.19	0.00001
	Extrastriate/fusiform gyrus	BA 20	-39	-48	-28	258	4.17	0.00002
	Angular gyrus	BA 39	39	-69	31	10	4.02	0.00003
<b>Elderly controls</b>								
NvF	Inferior frontal gyrus	BA 45	51	38	9	53	3.86	0.00006
	Inferior frontal gyrus	BA 47	-36	29	-6	12	3.42	0.0003
	Inferior frontal gyrus	BA 45	-54	21	13	17	3.62	0.0001
	Inferior frontal gyrus	BA 9	53	10	33	56	3.75	0.00009
	Anterior cingulate	BA 33	-3	10	19	13	4.25	0.00001
	Putamen		-21	-8	9	18	4.06	0.00002
	Hippocampal formation		-21	-27	-14	84	4.3	0.000008
	Hippocampal formation		21	-24	-14	30	3.98	0.00004
	Extrastriate/fusiform gyrus	BA 37	54	-56	-17	65	4.55	0.000003
	Extrastriate/fusiform gyrus	BA 37	-45	-57	-22	345	5.23	0.00000009
	Superior parietal lobule	BA 7	-27	-59	44	55	3.57	0.0002
RvF	Inferior frontal gyrus	BA 44/45	-42	30	12	36	3.8	0.00007
	Hippocampal formation		27	-18	-14	38	4.18	0.00001
	Inferior parietal lobule	BA 40	-27	-59	36	11	3.43	0.0003
	Inferior parietal lobule	BA 40	42	-50	47	15	3.68	0.0001
	Superior parietal lobule	BA 7	-33	-50	52	18	3.56	0.0002
	Superior parietal lobule	BA 7	-30	-74	42	12	3.67	0.0001
	Extrastriate/fusiform gyrus	BA 37	-45	-54	-23	94	4.47	0.000004
	Extrastriate/fusiform gyrus	BA 37	48	-54	-20	29	4.12	0.00002
	Middle temporal gyrus	BA 19	-33	-78	18	23	3.51	0.0002
NvR	Anterior cingulate	BA 33	-3	10	22	17	4	0.00003
	Putamen		-21	-11	9	16	3.53	0.0002
	Hippocampal formation	BA 28	-27	-24	-6	58	4.36	0.000006
	Hippocampal formation	BA 28	15	-24	-14	17	3.58	0.0002
	Extrastriate/fusiform gyrus	BA 37	-39	-45	-26	251	4.61	0.000002
<b>Mild Alzheimer's disease</b>								
NvF	Inferior frontal gyrus	BA 9	-48	16	24	75	3.71	0.0001
	Inferior frontal gyrus	BA 9	48	13	32	21	3.66	0.0001
	Hippocampal formation	BA 28	21	-27	-9	19	3.65	0.0001
	Precuneus/superior parietal lobule	BA 7	18	-56	47	74	4.38	0.000006
	Superior parietal lobule	BA 7	-33	-59	47	21	3.58	0.0002
	Extrastriate/fusiform gyrus	BA 37	-27	-45	-18	50	3.82	0.00007
	Extrastriate/fusiform gyrus	BA 19	15	-67	-9	23	3.92	0.0004
RvF	No significant clusters found							
NvR	Fusiform gyrus	BA 37	9	-44	-8	10	3.5	0.0002

BA, Brodmann area; NvF, novel v fixation; NvR, novel v repeated; RvF, repeated v fixation.

significant activation in prefrontal and superior parietal regions, but young and elderly controls differed in the pattern of activation in these regions, which is discussed in detail below.

Both young and elderly controls showed significant paradigm linked activation in the hippocampal formation in both the NvF and NvR contrast. In the NvR contrast, the hippocampal activation was greater in extent and more symmetrical in the young controls than in the elderly controls; however, the location and significance of the peak activation within the hippocampus was similar (within-group random effects averages: peak voxel location, right: 24, -30, -11 ( $p < 0.0001$ ); left: -21, -27, -11 ( $p < 0.0001$ ) for young controls; right: 15, -24, -14 ( $p = 0.0002$ ); left: -27, -24, -6 ( $p < 0.0001$ ) for elderly controls). The patients with mild Alzheimer's disease showed no activation in either hippocampal formation for the NvR contrast, and only a small area of activation in the right hippocampal formation for the NvF contrast (21, -27, -9 ( $p = 0.0001$ )). In addition, sampling of the MR signal within the hippocampus using a region of interest analysis showed that only one of the seven Alzheimer patients had evidence of paradigm linked MR signal within the hippocampus (fig 1). This patient had the mildest dementia in the group (age = 84; MMSE = 26).

### Between-group analyses

The between-group differences for both young *v* elderly controls and elderly controls *v* mild Alzheimer's disease for all contrasts (NvF, RvF, NvR) are shown in table 2.

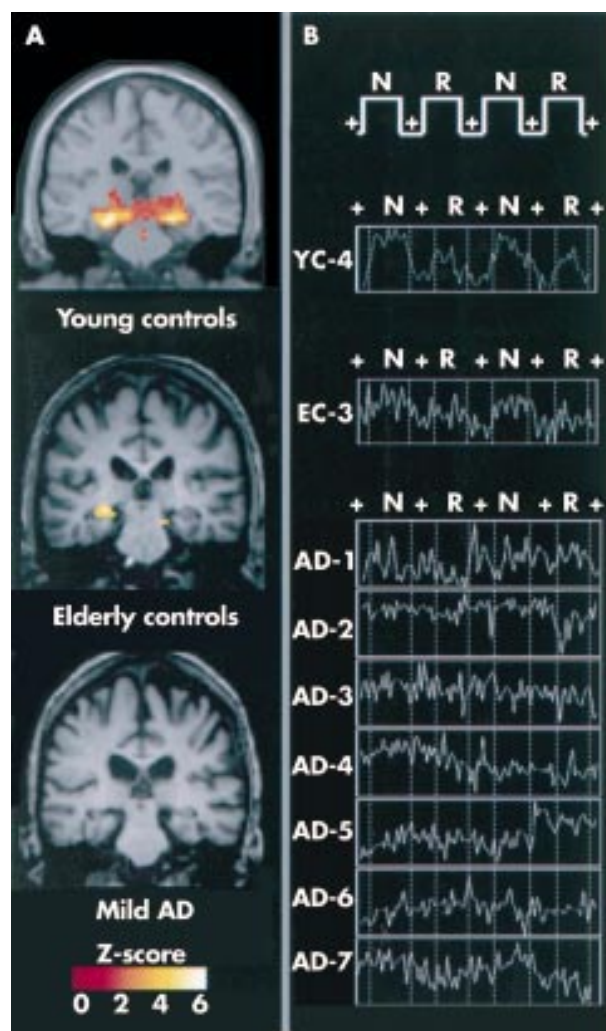
### Young *v* elderly controls

The most significant differences between the young and elderly controls were found in the pattern of activation in prefrontal and parietal cortices (fig 2). In the NvF contrast, young controls showed greater activation than elderly controls in left superior prefrontal regions (BA 10, peak coordinates -18, 53, 17; random effects between-group difference,  $p = 0.0002$ ). Conversely, elderly controls showed greater activation than the young controls in superior and inferior parietal regions bilaterally (BA 7, peak coordinates: 18, -65, 50 ( $p = 0.0003$ ), and -18, -71, 31 ( $p = 0.0004$ ); BA 40, peak coordinates: 42, -36, 29 ( $p = 0.0003$ ), and -50, -22, 29 ( $p = 0.0005$ )), and also in the anterior cingulate region (-9, 30, 12 ( $p = 0.0002$ )) for the NvF contrast. The elderly controls also showed greater activation than the young controls in multiple regions for the RvF contrast, particularly in the prefrontal regions (BA 8/9: -30, 14, 49 ( $p = 0.0002$ )) and the superior parietal regions (BA 7: -33, -50, 49 ( $p = 0.0004$ )).

There were no significant differences between the young controls and the elderly controls in hippocampal activation for the NvF contrast. In the NvR contrast, there were no differences in the left hippocampal formation, but young subjects showed greater activation in the right hippocampal formation. In the RvF contrast, elderly subjects showed slightly greater activation in the right hippocampal formation (27, -18, -14 ( $p = 0.003$ )). Young and elderly controls showed a similar pattern of significant paradigm linked activation in striate and fusiform cortices in all contrasts, but the young subjects showed a greater extent of activation than the elderly controls in the posterior extrastriate regions (BA 18/19: -9, -64, 6 ( $p = 0.003$ )).

### Elderly controls *v* mild Alzheimer patients

The most significant differences between elderly controls and mild Alzheimer patients were seen in the hippocampal formation for both the NvF and NvR contrasts. The patients with Alzheimer's disease showed significantly less activation than elderly controls for the NvF contrasts bilaterally in the hippocampal formation (random effects between-group difference: 12, -33, -13 ( $p = 0.001$ ) and -30, -24, -4 ( $p = 0.003$ )). For the NvR contrast, the only region showing a significant decrease in the Alzheimer group compared with



**Figure 1** (A) Within-group, random effects average activation maps for the novel *v* repeated contrast for young controls, elderly controls, and patients with mild Alzheimer's disease, shown on a representative structural image from each group in the coronal plane at the level of the hippocampal formation. (B) Magnetic resonance signal time courses on a standardised scale from a representative young control (YC-4), a representative elderly control (EC-3), and the seven patients with mild Alzheimer's disease. Only one Alzheimer patient (AD-7; MMSE = 26) showed evidence of paradigm linked activation within the hippocampus.

the elderly controls was located in the right hippocampal formation (15, -24, -16 ( $p = 0.002$ )).

The elderly controls and the Alzheimer patients showed a similar pattern of significant activation in striate and posterior fusiform cortices. Interestingly, there were several neocortical regions that showed increased activation in the Alzheimer group compared with the elderly controls. These increases were most evident in the medial parietal cortex bilaterally in NvF and NvR (precuneus: -15, -66, 28 ( $p = 0.0004$ )), the right posterior cingulate in NvF and NvR (12, -37, 21 ( $p < 0.001$ )), and the superior frontal cortex in NvF, RvF, and NvR (BA 9: -24, 48, 28 ( $p < 0.0001$ )).

### Post-scan testing

Young controls correctly identified 94% of the faces in post-scan testing, compared with 78% correct for the elderly controls ( $p < 0.05$ ). The young controls correctly named 58% of the faces on free recall of the name, compared with 40% for the elderly controls ( $p < 0.05$ ). All young and elderly controls correctly identified both repeated faces. All young subjects

**Table 2** Between-group differences (SPM99 random effects)

Contrast	Region	BA	x	y	z	No of voxels	z Value	p Value (uncorrected)	
<b>Young control &gt; elderly control</b>									
NvF	Superior frontal gyrus	BA 10	-18	53	17	80	3.49	0.0002	
	Superior frontal gyrus	BA 10	18	62	24	12	2.43	0.008	
	Inferior frontal gyrus	BA 46	-45	47	3	23	3.2	0.001	
	Extrastriate/lingual gyrus	BA 18	-9	-64	6	25	2.76	0.003	
	Extrastriate/lingual gyrus	BA 19	33	-67	-4	91	3.29	0.001	
RvF	No significant clusters								
NvR	Inferior frontal gyrus	BA 46	-45	47	3	79	3.35	0.0004	
	Middle frontal gyrus	BA 9	-42	13	24	12	2.72	0.003	
	Caudate		21	29	4	13	2.74	0.003	
	Caudate		9	12	-1	17	3.04	0.001	
	Thalamus		0	-18	-4	159	3.1	0.001	
	Hippocampal formation		30	-24	-11	62	3.39	0.0003	
	Extrastriate/lingual gyrus	BA 18	-15	-64	3	464	3.63	0.0001	
	Extrastriate/lingual gyrus	BA 18	6	-70	-7	188	3.09	0.001	
<b>Elderly control &gt; young control</b>									
NvF	Anterior cingulate	BA 24	-9	30	12	50	3.55	0.0002	
	Cingulate gyrus	BA 24	12	13	32	46	2.78	0.003	
	Cingulate gyrus	BA 24	3	-4	39	41	3.22	0.001	
	Inferior frontal gyrus	BA 9	24	10	33	24	3.1	0.001	
	Inferior frontal gyrus	BA 9	60	7	22	123	3.13	0.001	
	Middle frontal gyrus	BA 6	24	5	47	42	3.2	0.001	
	Superior temporal gyrus	BA 38	56	14	-16	14	3.18	0.001	
	Superior temporal gyrus	BA 38	-45	-21	-7	51	2.93	0.002	
	Inferior parietal lobule	BA 40	-50	-22	29	160	3.3	0.0005	
	Inferior parietal lobule	BA 40	42	-36	29	175	3.45	0.0003	
	Superior parietal lobule	BA 7	18	-65	50	63	3.47	0.0003	
	Superior parietal lobule	BA 7	-18	-71	31	181	3.37	0.0004	
	RvF	Middle frontal gyrus	BA 11	-30	31	-19	102	3.51	0.0002
		Inferior frontal gyrus	BA 47	36	29	-6	91	3.5	0.0002
Inferior frontal gyrus		BA 9	24	10	33	150	3.87	0.0006	
Inferior frontal gyrus		BA 44	53	6	8	20	2.77	0.003	
Superior frontal gyrus		BA 8	-30	14	49	782	4.16	0.0002	
Thalamus			0	9	2	187	3.76	0.0008	
Hippocampal formation			27	-18	-14	24	2.8	0.003	
Cingulate gyrus		BA 31	-12	-27	43	20	2.86	0.002	
Fusiform gyrus		BA 20	45	-30	-14	44	3.12	0.001	
Fusiform gyrus		BA 20	33	-39	-13	16	2.71	0.003	
Middle temporal gyrus		BA 21	-50	-47	2	56	4.1	0.0002	
Superior parietal lobule		BA 7	-33	-50	49	1459	3.95	0.0004	
NvR		Superior temporal gyrus	BA 6	-48	-3	6	15	2.58	0.005
		Postcentral gyrus	BA 3	60	-11	23	14	2.54	0.006
<b>Elderly control &gt; Alzheimer's disease</b>									
NvF	Inferior frontal gyrus	BA 45	54	36	9	12	2.93	0.002	
	Hippocampal formation		-30	-24	-4	11	2.78	0.003	
	Hippocampal formation		12	-33	-13	63	2.99	0.001	
	Superior parietal lobule	BA 7	-21	-60	42	12	2.57	0.005	
RvF	Middle frontal gyrus	BA 11	27	42	-13	58	2.75	0.003	
	Middle frontal gyrus	BA 6	-30	14	46	34	2.88	0.002	
	Inferior frontal gyrus	BA 47	-18	37	-9	13	2.9	0.002	
	Anterior cingulate	BA 24	-12	32	-1	15	3.03	0.001	
	Putamen		24	6	5	60	2.71	0.003	
	Hippocampal formation		27	-18	-14	10	3.09	0.001	
	Hippocampal formation		-33	-27	-19	18	3.08	0.001	
	Middle temporal gyrus	BA 39	36	-54	30	27	2.99	0.001	
	Middle temporal gyrus	BA 39	-36	-75	23	166	3.87	0.0001	
	Middle occipital gyrus	BA 19	30	-70	9	46	2.97	0.001	
NvR	Hippocampal formation		15	-24	-16	24	2.86	0.002	
<b>Alzheimer's disease &gt; elderly control</b>									
NvF	Superior frontal gyrus	BA 9	-24	48	28	50	3.27	0.0001	
	Middle temporal gyrus	BA 21	-42	-15	-9	10	2.72	0.003	
	Superior temporal gyrus	BA 41	56	-25	10	20	2.77	0.003	
	Posterior cingulate	BA 29	12	-37	21	18	3.17	0.001	
	Precuneus	BA 31	9	-62	34	108	3.65	0.0001	
	Precuneus	BA 31	-15	-69	28	57	3.46	0.0003	
RvF	Superior frontal gyrus	BA 6	-9	26	57	10	3.9	0.00005	
NvR	Superior frontal gyrus	BA 9	-27	48	28	35	3.48	0.0002	
	Superior frontal gyrus	BA 9	-15	40	37	11	2.54	0.006	

**Table 2** continued

Contrast	Region	BA	x	y	z	No of voxels	z Value	p Value (uncorrected)
NvR	Cingulate	BA 10	-21	35	1	189	3.3	0.0005
	Middle temporal gyrus	BA 21	50	-4	-12	20	2.78	0.003
	Middle temporal gyrus	BA 21	-48	-9	-15	11	2.81	0.002
	Precuneus/posterior cingulate	BA 31	12	-57	33	443	3.6	0.0002
	Fusiform gyrus	BA 36	-36	-27	-19	22	2.99	0.001
	Precuneus	BA 31	-15	-66	28	83	3.35	0.0004
	Extrastriate/fusiform gyrus	BA 18	-21	-76	-4	31	2.89	0.002

BA, Brodmann area; NvF, novel v fixation; NvR, novel v repeated; RvF, repeated v fixation.

correctly recalled the names of both repeated faces, while two elderly subjects missed one of the names of the repeated faces on free recall, which was not a significant difference.

The patients with mild Alzheimer's disease correctly recognised 60% of the faces, a difference from elderly controls that approached significance ( $p = 0.059$ ). The Alzheimer patients named 12% of the faces correctly, which was significantly less than elderly controls ( $p < 0.005$ ). Five of the Alzheimer group correctly recognised both of the repeated faces, while two correctly recognised only one of the repeated faces, which was a trend towards a significant difference from the elderly controls ( $p = 0.08$ ). The Alzheimer patients performed significantly worse than the elderly controls on free recall of the names for the repeated faces ( $p < 0.006$ ).

## DISCUSSION

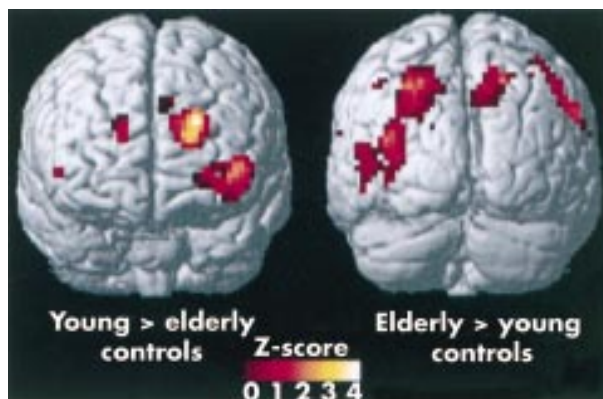
These findings suggest that the functional neuroanatomical alterations underlying explicit memory changes in mild Alzheimer's disease differ from those seen with normal aging. Particularly striking was the fact that the regions showing the greatest decreases in activation in the patients with mild Alzheimer's disease compared with the elderly controls were in the hippocampal formation. We hypothesise that this is the result of the extensive neuronal loss (in conjunction with neuritic plaques and neurofibrillary tangles) that develops early in the course of Alzheimer's disease.<sup>3</sup> It is likely that regional atrophy is also at least partially responsible for the decreased hippocampal activation in Alzheimer's disease.<sup>16</sup> However, this is unlikely to be the entire explanation for our findings, as we saw little evidence of paradigm linked activation in the hippocampus in six of the seven Alzheimer patients when the MR signal was sampled within a small section of the hippocampus, guided by each individual subject's anatomy. This suggests that

in addition to hippocampal atrophy, there is dysfunction in the remaining hippocampal tissue. We studied fewer Alzheimer patients than elderly controls; however, several regions showed greater activation in the Alzheimer group than in the elderly controls, suggesting that reduced power is also unlikely to explain the findings in the hippocampus. Further fMRI studies with larger numbers of subjects are clearly needed; however, our findings are consistent with the few fMRI studies using encoding tasks in Alzheimer's disease published to date,<sup>17-19</sup> and suggest that fMRI may be useful in assessing the integrity of hippocampal function early in the course of the disease.

Our findings with respect to elderly v young controls showed a different anatomical distribution than in the elderly v Alzheimer's disease comparison discussed above. The elderly controls showed significant hippocampal activation which was very similar to young controls for the NvF contrast. For the NvR contrast, the activation of the hippocampus was similar in magnitude between the young and elderly controls, but was greater in extent and more symmetrical in the young controls. These findings are consistent with reports of minimal cell loss accompanied by alterations in the neurotransmitter levels and synaptic integrity within the hippocampus in normal aging.<sup>4,5</sup> Consistent with our results, recent fMRI studies using encoding tasks have reported significant activation within the hippocampal formation in elderly controls,<sup>17-20</sup> but have also reported age related decreases in hippocampal activation during an associative working memory task.<sup>21</sup>

The most striking age related change in the present study was the alteration in the pattern of prefrontal and parietal activation seen in the elderly controls compared with the young controls. The elderly controls showed decreased prefrontal activation and increased parietal activation during the encoding of novel face-name pairs compared with the young controls. We hypothesise that these alterations result in differential activity in a frontoparietal attentional network, which may in part underlie age related changes in memory. These findings are consistent with several recent fMRI and positron emission tomography (PET) studies showing age related alterations in patterns of prefrontal activation during memory tasks.<sup>22-25</sup>

It is noteworthy that the patients with mild Alzheimer's disease showed greater activation in several neocortical regions than the elderly controls, as mentioned above. The most striking increases were found in medial parietal cortex (precuneus) and posterior cingulate. These regions have been reported to show decreased resting metabolism and perfusion in patients with mild Alzheimer's disease and in asymptomatic genetically at risk subjects.<sup>26-28</sup> Our findings suggest that these regions—which show evidence of dysfunction at rest—may have an exaggerated increase in activation during an encoding task. This could be the result of a compensatory process that occurs once there is substantial neuronal loss within the hippocampus. In an effort to perform the task, patients with Alzheimer's disease may engage other neural systems, resulting in increased activation in these brain regions compared with elderly controls. Previous PET activation studies in Alzheimer's disease,<sup>29,30</sup> and a recent fMRI



**Figure 2** Between-group random effects comparison for young v elderly controls for the novel v fixation contrast. Young controls showed greater activation than elderly controls (shown on the left) in the prefrontal regions, whereas elderly controls showed greater activation than young controls in the superior parietal regions (shown on the right).

study in genetically at risk subjects,<sup>20</sup> have likewise suggested such a compensatory mechanism.

It is also possible, however, that the strategies employed to learn the face–name associations differed among the groups of subjects. Although all subjects were instructed at the start of each run to try to remember which name was associated with each face during the presentation of the face–name pairs and to look at the fixation cross during the fixation condition, it is possible that some subjects were rehearsing the face–name pairs during fixation, which could account for some of the group differences in the patterns of activation in the NvF and RvF contrast. Our fMRI findings, however, are consistent with the differences seen in behavioural performance on the post-scan memory tests. Elderly subjects performed significantly worse than young subjects on novel face recognition and free recall of the names. The patients with Alzheimer's disease performed significantly worse than the elderly controls on novel face recognition and on novel and repeated free recall of the name.

Finally, it should be noted that although the young subjects showed a greater extent of activation in the posterior extrastriate regions, young and elderly controls and Alzheimer patients showed similar patterns of significant paradigm linked activation in the striate and extrastriate cortices. These results indicate that both elderly controls and people with Alzheimer's disease are able to mount a significant BOLD response to stimuli, and furthermore, that these extrastriate regions are responding appropriately to the presentation of complex visual stimuli, consistent with the absence of pathology in these regions in aging or in mild Alzheimer's disease.<sup>3</sup>

## Conclusions

In summary, our study indicates that the pattern of activation involved during the encoding of novel associations is differentially altered in the early stages of Alzheimer's disease compared with the alterations seen in normal aging. Age related changes in memory performance appear to be related to alterations in the frontoparietal regions involved in complex attention, whereas the changes related to Alzheimer's disease seem to reflect alterations in the hippocampus and related regions involved in medial temporal memory systems. Our results must be interpreted with some caution, given the small number of subjects in each group, and hence the use of less stringent corrections for multiple comparisons. Further fMRI studies with larger numbers of elderly control subjects, subjects with mild cognitive impairment, and patients with Alzheimer's disease are under way to clarify the earliest point in the course of Alzheimer's disease when such differences can be observed.

## ACKNOWLEDGEMENTS

We gratefully acknowledge the contribution of the study subjects, the Alzheimer's disease patients, and their caregivers. We thank Terry Campbell and Mary Foley for assistance with scan acquisition. This work was supported by grants from NINDS: K23-NS02189 (RAS), NIMH: MH60941 (DLS), NIA: AG08441 (DLS); P01-AG04953 (MSA), and the Dana Foundation (MSA).

## Authors' affiliations

**R A Sperling, E F Chua, A J Cocchiarella, D M Rentz**, Memory Disorders Unit, Department of Neurology, Brigham and Women's Hospital, Boston, Massachusetts, USA  
**J F Bates, B R Rosen**, NMR Center, Massachusetts General Hospital, Boston  
**M S Albert**, Gerontology Research Unit, Department of Psychiatry, Massachusetts General Hospital, Boston  
**D L Schacter**, Department of Psychology, Harvard University, Cambridge, Massachusetts

Competing interests: none declared

## REFERENCES

- 1 **Welsh K**, Butters N, Hughes J, et al. Detection of abnormal memory decline in mild cases of Alzheimer's disease using CERAD neuropsychological measures. *Arch Neurol* 1991;**48**:278–81.
- 2 **Craik F**. Age differences in human memory. In: Birren J, Schaie K, eds. *Handbook of the psychology of aging*. New York: Van Nostrand Reinhold, 1977:384–420.
- 3 **Braak H**, Braak E. Neuropathological staging of Alzheimer-related changes. *Acta Neuropathol* 1991;**82**:239–59.
- 4 **Morrison JH**, Hof PR. Life and death of neurons in the aging brain. *Science* 1997;**278**:412–19.
- 5 **Smith TD**, Adams MM, Gallagher M, et al. Circuit-specific alterations in hippocampal synaptophysin immunoreactivity predict spatial learning impairment in aged rats. *J Neurosci* 2000;**20**:6587–93.
- 6 **Eichenbaum H**. How does the brain organize memories? *Science* 1997;**277**:333–5.
- 7 **Zelinski EM**, Gilewski MJ. Assessment of memory complaints by rating scales and questionnaires. *Psychopharmacol Bull* 1988;**24**:523–9.
- 8 **Leirer VO**, Morrow DG, Sheikh JJ, et al. Memory skills elders want to improve. *Exp Aging Res* 1990;**16**:155–8.
- 9 **Sperling R**, Bates J, Cocchiarella A, et al. Encoding novel face–name associations: a functional MRI study. *Hum Brain Map* 2001;**14**:129–39.
- 10 **Sperling R**, Greve D, Dale A, et al. fMRI detection of pharmacologically induced memory impairment. *Proc Natl Acad Sci USA* 2002;**99**:455–60.
- 11 **McKhann G**, Drachman D, Folstein M, et al. Clinical diagnosis of Alzheimer's disease: report of the NINCDS-ADRDA work group under the auspices of Department of Health and Human Services task force on Alzheimer's disease. *Neurology* 1984;**34**:939–44.
- 12 **Folstein MF**, Folstein SE, McHugh PR. "Mini-mental state". A practical method for grading the cognitive state of patients for the clinician. *J Psychiatr Res* 1975;**12**:189–98.
- 13 **Friston KJ**, Holmes AP, Worsley KJ, et al. Statistical parametric maps in functional imaging: a general linear model approach. *Human Brain Mapping* 1995;**2**:189–210.
- 14 **Holmes AP**, Friston KJ. Generalisability, random effects, and population inference. *Neuroimage* 1998;**7**:S754.
- 15 **Talairach J**, Tournoux P. *Co-planar stereotaxic atlas of the human brain*. Stuttgart: Thieme, 1988.
- 16 **Jack CR**, Petersen RC, Xu YC, et al. Medial temporal atrophy on MRI in normal aging and very mild Alzheimer's disease. *Neurology* 1997;**49**:786–94.
- 17 **Small SA**, Perera GM, DeLaPaz R, et al. Differential regional dysfunction of the hippocampal formation among elderly with memory decline and Alzheimer's disease. *Ann Neurol* 1999;**45**:466–72.
- 18 **Rombouts SA**, Barkhof F, Veltman DJ, et al. Functional MR imaging in Alzheimer's disease during memory encoding. *Am J Neuroradiol* 2000;**21**:1869–75.
- 19 **Kato T**, Knopman D, Liu H. Dissociation of regional activation in mild AD during visual encoding: a functional MRI study. *Neurology* 2001;**57**:812–16.
- 20 **Bookheimer SY**, Strojwas MH, Cohen MS, et al. Patterns of brain activation in people at risk for Alzheimer's disease. *N Engl J Med* 2000;**343**:450–6.
- 21 **Mitchell KJ**, Johnson MK, Raye CL, et al. fMRI evidence of age-related hippocampal dysfunction in feature binding in working memory. *Brain Res Cogn Brain Res* 2000;**10**:197–206.
- 22 **Cabeza R**, Anderson N, Houle S, et al. Age-related differences in neural activity during item and temporal-order memory retrieval: a positron emission tomography study. *J Cogn Neurosci* 2000;**12**:197–206.
- 23 **Rypma B**, D'Esposito M. Isolating the neural mechanisms of age-related changes in human working memory. *Nat Neurosci* 2000;**3**:509–15.
- 24 **Rypma B**, Prabhakaran V, Desmond JE, et al. Age differences in prefrontal cortical activity in working memory. *Psychol Aging* 2001;**16**:371–84.
- 25 **Langley LK**, Madden DJ. Functional neuroimaging of memory: implications for cognitive aging. *Microsc Res Techn* 2000;**51**:75–84.
- 26 **Small GW**, Ercoli LM, Silverman DH, et al. Cerebral metabolic and cognitive decline in persons at genetic risk for Alzheimer's disease. *Proc Natl Acad Sci USA* 2000;**97**:6037–42.
- 27 **Reiman EM**, Caselli RJ, Chen K, et al. Declining brain activity in cognitively normal apolipoprotein E varepsilon 4 heterozygotes: a foundation for using positron emission tomography to efficiently test treatments to prevent Alzheimer's disease. *Proc Natl Acad Sci USA* 2001;**98**:3334–9.
- 28 **Johnson KA**, Lopera F, Jones K, et al. Presenilin-1-associated abnormalities in regional cerebral perfusion. *Neurology* 2001;**56**:1545–51.
- 29 **Becker JT**, Mintum MA, Aleva K, et al. Compensatory reallocation of brain resources supporting verbal episodic memory in Alzheimer's disease. *Neurology* 1996;**46**:692–700.
- 30 **Stern Y**, Moeller JR, Anderson K, et al. Different brain networks mediate task performance in normal aging and AD: defining compensation. *Neurology* 2000;**55**:1291–7.