

SHORT REPORT

The natural course of Sneddon syndrome: clinical and magnetic resonance imaging findings in a prospective six year observation study

S M Boesch, A L Plöner, A J Auer, W Poewe, F T Aichner, S R Felber, N T Sepp

J Neurol Neurosurg Psychiatry 2003;**74**:542–544

Sneddon syndrome (SS) is increasingly recognised as a cause of ischaemic stroke in young adults. As the natural course of SS is not well defined, the authors performed a prospective six year clinical and neuroradiological follow up study. Thirteen patients with definite diagnosis of SS (livedo racemosa, characteristic skin biopsy, and history of stroke) entered a follow up programme that consisted of clinical examinations, two magnetic resonance imaging (MRI) investigations, and a comprehensive laboratory follow up protocol. The most frequent clinical findings during follow up had been headache (62%) and vertigo (54%). Seven patients (54%) suffered from transient ischaemic attacks, however, completed stroke has not been obtained during follow up. Progression of white matter lesions detected in MRI were present in 10 of 13 patients. Laboratory follow up protocol revealed transient antiphospholipid antibodies in two subjects. This prospective six year follow up study suggests a low incidence of territorial stroke but outlines progressive leucoencephalopathy in patients with SS.

Sneddon syndrome (SS) is an uncommon disorder that is characterised by stroke and generalised livedo racemosa of the skin.¹ Neurological symptoms in SS range from headache, vertigo, transient ischaemic attacks (TIA), stroke, and seizures to mental deterioration and dementia. Livedo racemosa is clinically characterised by irregular broken circular segments, whereas livedo reticularis² is characterised by a netlike, regular pattern of violaceous vasculature resulting in a smaller pattern than livedo racemosa. Diagnosis of SS is mainly based on skin biopsy and abnormal findings in neurological examination and/or MRI. Pre-existing retrospective studies on the course of the disease in SS revealed a wide range in neurological deterioration.^{1,3,4}

Therefore, we undertook a prospective longitudinal study on the clinical course of SS in 13 of 17 previously published patients with definite SS.⁵

METHODS

Clinical follow up investigations

Thirteen of 17 previously published patients with definite diagnosis of SS gave their informed consent to enter in this prospective six year follow up programme. Three patients did not agree to a long term follow up, one patient died before the study because of pulmonary failure. None of the SS patients had antiphospholipid antibodies at the time point of entering in the study.⁵ There were 12 women and one man. Their mean (SD) age at diagnosis of SS was 36 (7.5) years. Duration of disease before the study was 10 (4.1) years, the age at the last follow up was 46.5 (8.9) years. All patients were examined

three to six monthly by a dermatologist (ALP, NTS) and a neurologist (SMB) assessing a standardised questionnaire (for example, type, duration, and frequency of neurological symptoms). Patients 7, 9, 12 received platelet aggregation inhibitors after their first vascular episode (acetylsalicylic acid 50 mg daily).

Laboratory tests

Annual routine laboratory tests included blood chemistry, blood cell count, blood sedimentation rate, fasting lipid profile, and creatinine clearance.

Immunological testing included C reactive protein, rheumatoid factor, Rose-Waaler test, antistreptolysin titre, antinuclear antibodies (ANA), antineutrophil cytoplasmic antibodies (ANCA), cryoglobulins, cold agglutinins, anticardiolipin antibodies (aCL), lupus anticoagulant, and complement consumption parameters.

Testing of blood *coagulation factors* included prothrombin, prothrombin time, fibrinogen, protein C, protein S, antithrombin III, and activated protein C resistance test.

Magnetic resonance imaging (MRI) and angiography (MRA) protocol

The magnetic resonance imaging protocol (1.5-T Magnetom and Vision, Siemens, Erlangen, Germany) consisted of T1 and T2 weighted multislice spin echo sequences (TR=500 ms, TE=15 ms and TR=2800 ms, TE=15/90 ms) in sagittal, transverse, and coronal orientations. A three dimensional gradient echo sequence (TR=38 ms, TE=6 ms, slice thickness=1 mm) with incorporated motion compensating gradients for constant velocities in slice select and read out direction was used for MRA. The individual MRA images were reviewed for vessel patency and reconstructed by a ray tracer algorithm to render projectional angiograms. As no MR examinations were performed during TIA-like episodes, we did not use diffusion weighted imaging.

MRI and MRA scans were analysed independently by three neuroradiologists (AJA, SRF, FTA) according to an evaluation protocol with respect to the size and location of individual lesions as well as their signal characteristics. The protocol differentiated between territorial infarcts, watershed ischaemia, small foci of posts ischemic gliosis within the deep white matter and cortical atrophy.

RESULTS

Clinical features

History of headache was observed in 85% (11 of 13 patients) and represented the most frequent unspecific symptom

Abbreviations: MRI, magnetic resonance imaging; SS, Sneddon syndrome; TIA, transient ischaemic attack; ANA, antinuclear antibodies; aCL, anticardiolipin antibodies; MRA, magnetic resonance angiography

Table 1 Neurological symptoms and MR follow up findings in 13 patients with Sneddon syndrome

Patients (sex/year of birth)	Diagnosis of SS	Non-specific symptoms	Annual rate of TIAs	Duration of TIAs (min)	Treatment	Progression of clinical symptoms	White matter lesions 1990 (cortical-subcortical versus periventricular lesions)	White matter lesions 1996 (cortical-subcortical versus periventricular lesions)
1/F/1957	1986	H, V	2	10–20	no	no	2/18	2/18
2/F/1939	1984	H	–	–	no	no	6/12	7/12
3/F/1959	1990	M	–	–	no	no	2/15	2/17
4/F/1957	1986	H	–	–	no	no	39/3	40/4
5/F/1944	1965	M, V	12	10–20	no	no	11/1	12/1
6/F/1955	1984	M, V	2	5–10	no	no	10/6	12/9
7/F/1947	1990	V	–	–	ASS 50 mg	no	3/12	5/16
8/F/1936	1979	H, V	20	5–10	no	yes	21/16	28/21
9/M/1942	1990	H, V	5	10–20	ASS 50 mg	no	4/3	9/4
10/F/1959	1991	H	4	5–10	no	no	5/4	8/4
11/F/1953	1984	H	–	–	no	no	23/1	25/1
12/F/1949	1991	H, V	7	10–20	ASS 50 mg	no	15/3	15/3
13/F/1969	1990	–	–	–	no	no	1/1	1/1

H, headache; V, vertigo; M, migraine; TIA, transient ischaemic attack; white matter lesions, number of lesions in MRI involving the cortical-subcortical watershed compared with number of lesions in the periventricular white matter; ASS, aspirin.

observed during follow up. Vertigo and dizziness occurred in 62% (8 of 13) of patients, three patients fulfilled the clinical criteria for migraine without aura (23%). The frequency of these unspecific symptoms remained unchanged during follow up. Ten patients (77%) reported loss of concentration ability, memory disturbances, or emotional impairment but none was demented according to mini-mental state examination (mean (SD) 28 (2) points).

TIA occurred in seven patients (54%) and were of less than one hour duration. The deficit was motor in the majority of events (75%) and was related to the middle cerebral artery territory in 84%. The frequency of TIA (table 1) varied between one and twenty attacks per year. One patient showed some

clinical progression and became positive for plantar extension reflexes bilaterally, however he did not experience completed territorial infarction. Vascular risk factors such as hypertension (two patients, stage 1, 2 hypertension), smoking, dyslipidaemia, body weight, oral contraception did not correlate with disease progression. At the time point of diagnosis six patients (46%) had been smoking, all but three patients stopped smoking during observation period. Dyslipidaemia was present in six patients initially, but the reduction of body weight and dietary measurements led to normal serum lipid values in all of them.

Livedo racemosa did not change in the extent of skin involvement as well as in the severity of discoloration in our SS series.

Laboratory findings

Sequential testing of serological parameters revealed positive titres for antinuclear antibodies in three patients. One patient transiently had positive aCL during follow up and, another lupus anticoagulant. Both aPL did not persist in additional follow up investigations. Other immunological parameters such as ANCA, cryoglobuline, or complement factors remained within normal ranges. Recurrent testing was normal for protein C, however, three patients showed decreased levels of protein S in repeated testing. Serum urea nitrogen and serum creatinine concentration very slightly increased in two patients, creatinine clearance decreased in 9 of 13 patients (70%) because of possible renal involvement.

MRI findings

All patients cooperated well during the examination and all scans were evaluated. There were no differences in the ratings of the readers (AJA, SRF, FTA).

At entry into the study eight patients had one or more (case 2 had four infarcts) chronic infarcts. The size of these lesions ranged from 1×2 cm to 3×4 cm (in size). All infarcts involved the cortices and subcortical layers. They were located in the peripheral tributaries in five patients and in watershed areas in seven patients. Four patients had both peripheral territorial and watershed infarctions. During the observation period, none of the patients experienced a new infarction.

All but one patient had additional, small and circumscribed lesions in the white matter of the hemispheres and brain stem or the cerebellum, or both. These lesions were small foci (2 mm to 7 mm in size), which were hyperintense on proton density and T2 weighted images and isointense on T1 weighted images (for example, patient 8, see fig 1). Within six years the number of these small white matter lesions increased in 10 patients. Qualitatively assessed cortical atrophy did not change during follow up.

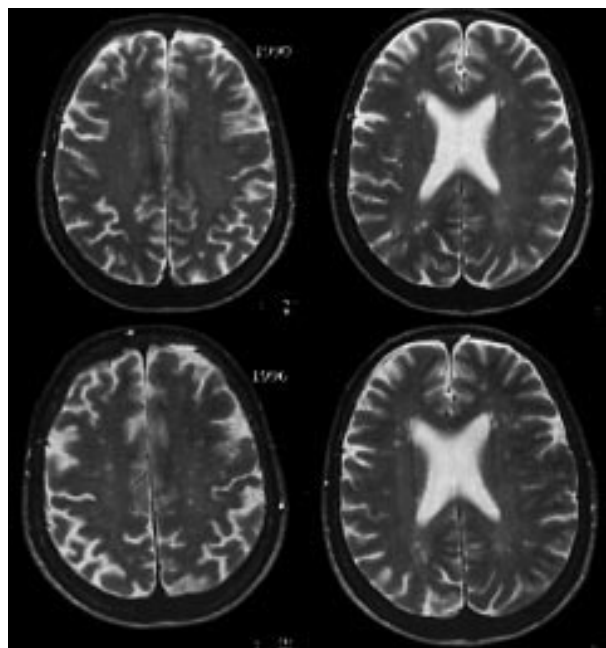


Figure 1 This female patient had a history of 12 years of Sneddon syndrome and had suffered from a right occipital borderzone infarction between the middle cerebral artery (MCA) and the posterior cerebral artery (PCA). The T2 weighted MR scan at the level of the lateral ventricles was obtained when the patient was 54 years old. The image shows small hyperintense foci within the subcortical U fibres and the periventricular region that ranges from 1 to 6 mm in size and one accentuated in the left hemisphere. Six years later the image shows small hyperintense foci within the subcortical U fibres and the periventricular region that ranges from 1 to 6 mm in size are considerably increased.

The MRA protocol used in this study is sensitive to the detection of intracranial arteries that are larger than 0.5 mm in size. Within the boundaries of this anatomical resolution all patients had a normal flow related enhancement of their vessels on MRA images and projections.

DISCUSSION

We report the first prospective longitudinal clinical and MR follow up study that included exclusively patients with definite SS. The most important clinical diagnostic criteria for SS, livedo racemosa and neurological deficit, remained unchanged in most of our patients during a six year follow up period. Unspecific symptoms such as recurrent attacks with vertigo and headache that preceded the onset of GLR by several years persisted also during follow up period.⁶ Still, a high incidence of so called "non-specific symptoms" suggests a causal rather than a coincidental presence in SS.^{7,8}

Rapid clinical worsening because of recurrent territorial ischaemic infarction previously claimed to be a typical symptom of SS, has not been observed in our patients. Our results are limited by a small number of patients, as all patients have intensively been investigated to rule out other acquired and inherited non-inflammatory vasculopathies. Although two patients were transiently positive for aPL during study follow up, definite antiphospholipid antibody syndrome did not occur in our SS patients. We conclude that recurrent territorial infarctions and previously reported "catastrophic" clinical course in definite SS might be rare.^{1,9,10}

Still, young onset stroke represented an inclusion criteria for entering in our SS study and in 10 of 13 SS patients white matter changes in MRI increased within a six year observation period. From a purely descriptive point of view the lesion pattern on MRI is comparable to the one seen in patients with recurrent cardiac embolism.¹¹ However, during a six year observation time a higher number of completed/definite strokes could have been expected if cardiac embolism would have been a major risk factor for ischaemic stroke in our series. Moreover, increasing numbers of lesions with a hyperintense signal in T2 weighted MR images in our series contrast with unchanged pre-existent cortical atrophy, although we cannot exclude minimal changes in cortical atrophy because the degree of atrophy was not measured quantitatively. Finally, white matter signal hyperintensities in population based studies are closely related to increasing age and vascular risk profile, however both, age and vascular risk factors are not likely to account for white matter lesions in our patients.^{12,13} We used the same standard protocol throughout the study, which allowed us to use lesion counting as a surrogate marker of disease progression. Still, because of potential limitations of our MR study protocol, T2 weighted images yield inferior sensitivity towards small periventricular lesions as compared with FLAIR images, white matter changes might even have been underscored in our study. The distribution pattern with lesions predominantly in the subcortical white matter, however, argues against the notion that a significant number of additional lesions would have been detected on FLAIR images.

Neuropathological studies in a larger series of SS patients that could clarify potential mechanisms that cause stroke and progressive leucoencephalopathy in SS are currently not available. Boortz-Marx found granulomatous leptomeningeal infiltration and suggested a primary role of inflammation in SS.¹⁴ In turn, Pinol-Aguade and Geschwind demonstrated thrombosis and recanalisation in meningeal and cerebral vessels but no evidence of vasculitis in their cases.^{15,16} In line with aforementioned findings and in analogy to findings in skin

specimens of our series that revealed a predominant involvement of medium sized arteries, we suggest a comparable vascular process of SS in vessels of the central nervous system. Progressive obstruction by a sponge-like plug in an early stage represents an important diagnostic criterion in SS specimen compared with, for example, APL primary or secondary to lupus erythematosus, and might result in arterial fibrosis, shrinkage, and atrophy in final stages.^{5,17} Relapsing obstruction and recanalisation processes in cerebral arteries might find their clinical correlate in recurrent TIA-like events, and their neuroradiological correlate in progressive leucoencephalopathy often seen in SS.¹⁸

.....

Authors' affiliations

S M Boesch, W T Poewe, Department of Neurology, University of Innsbruck, Austria

A L Plörer, N T Sepp, Department of Dermatology, University of Innsbruck

A J Auer, F T Aichner, S R Felber, Department of Magnetic Resonance and Spectroscopy, University of Innsbruck

Competing interests: none declared.

Correspondence to: Dr Sa Boesch, Department of Neurology, University of Innsbruck, Anichstrasse 35, 6020 Innsbruck, Austria; sylvia.boesch@uibk.ac.at

Received 11 October 2002

Accepted in revised form 2 December 2002

REFERENCES

- 1 **Sneddon IB**. Cerebrovascular lesions and livedo reticularis. *Br J Dermatol* 1965;**77**:180-5.
- 2 **Ehrmann S**. Ein neues Gefäßsymptom bei Lues. *Wien Med Wochenschr* 1907;**16**:777-82.
- 3 **Zelger B, Sepp N, Stockhammer G, et al**. Sneddon's syndrome. *Arch Dermatol* 1993;**129**:437-47.
- 4 **Tietjen G, Levine S**. Sneddon's syndrome and Divry-Van Bogaert syndrome. In: Bogousslavsky J, Caplan L, eds. *Stroke syndromes*. Cambridge: Cambridge University Press 1995.
- 5 **Stockhammer G, Felber SR, Zelger B, et al**. Sneddon's syndrome: diagnosis by skin biopsy and MRI in 17 patients. *Stroke* 1993;**24**:685-90.
- 6 **Martinelli A, Martinelli P, Ippoliti M, et al**. Sneddon syndrome presenting with hemicranic attacks: a case report. *Acta Neurol Scand* 1991;**83**:201-3.
- 7 **Lieb K, Vaith P, Berger M, et al**. Systemic immunologic diseases as differential diagnosis in psychiatry. *Nervenarzt* 1997;**68**:696-707.
- 8 **Kume M, Imai H, Motegi M, et al**. Sneddon's syndrome (livedo racemosa and cerebral infarction) presenting psychiatric disturbance and shortening of fingers and toes. *Intern Med* 1996;**35**:668-73.
- 9 **Rumpl E, Neuhofer J, Pallua A, et al**. Cerebrovascular lesions and livedo reticularis (Sneddon's syndrome): a progressive cerebrovascular disorder? *J Neurol* 1985;**231**:324-30.
- 10 **Bruyn RPM**. Sneddon's syndrome. In: Toole JF, ed. *Handbook of clinical neurology, volume 11: vascular diseases, part iii*. New York: Elsevier Science, 1989:401-10.
- 11 **Tourbah A, Piette JC, Iba-Zizen MT, et al**. The natural course of cerebral lesions in Sneddon syndrome. *Arch Neurol* 1997;**54**:53-60.
- 12 **Schmidt R, Hayn M, Fazekas F, et al**. Magnetic resonance imaging white matter hyperintensities in clinically normal elderly individuals. Correlations with plasma concentrations of naturally occurring antioxidants. *Stroke* 1996;**27**:2043-7.
- 13 **Fazekas F, Kleinert R, Offenbacher H, et al**. The morphologic correlate of incidental punctate white matter hyperintensities on MR images. *Am J Neuroradiol* 1991;**12**:915-21.
- 14 **Boortz-Marx RL, Clark HB, Taylor S, et al**. Sneddon's syndrome with granulomatous meningeal infiltration. *Stroke* 1995;**26**:492-5.
- 15 **Pinol-Aguade J, Ferradiz C, Ferrer Roca O, et al**. Livedo reticularis y accidentes cerebro-vasculares. *Med Cub Ibero Lat Am* 1975;**3**:257-65.
- 16 **Geschwind DH, Fitzpatrick M, Mishel PS, et al**. Sneddon's syndrome is a thrombotic vasculopathy: neuropathologic and neuroradiologic evidence. *Neurology* 1995;**45**:557-60.
- 17 **Sepp N, Zelger B, Schuler G, et al**. Sneddon's syndrome-an inflammatory disorder of small arteries followed by smooth muscle proliferation: immunohistochemical and ultrastructural evidence. *Am J Surg Pathol* 1995;**19**:448-53.
- 18 **Fetoni V, Grisoli M, Salmaggi A, et al**. Clinical and neuroradiological aspects of Sneddon' syndrome and primary antiphospholipid syndrome. A follow-up study. *Neurol Sci* 2000;**21**:157-64.