

SHORT REPORT

Supranuclear gaze palsy and opsoclonus after Diazinon poisoning

T-W Liang, L J Balcer, D Solomon, S R Messé, S L Galetta

J Neurol Neurosurg Psychiatry 2003;**74**:677–679

A 52 year old man developed a supranuclear gaze palsy and opsoclonus after Diazinon poisoning. The diagnosis was confirmed by low plasma and red blood cell cholinesterase activity and urine mass spectroscopy. Saccadic control may be mediated in part by acetylcholine. Opsoclonus in the setting of organophosphate intoxication may occur as a result of cholinergic excess which overactivates the fastigial nuclei.

Various central eye movement abnormalities have been described after organophosphate poisoning.^{1,2} Diazinon, an organophosphate, acts as a cholinesterase inhibitor. Accumulation of acetylcholine at muscarinic, nicotinic, and central sites results in the acute toxic effects. Often the well recognised findings such as delirium, convulsions, and paralysis overshadow such eye findings. We report a patient with supranuclear gaze palsy and opsoclonus from Diazinon poisoning and speculate on the possible underlying mechanisms.

CASE REPORT

A 52 year old man with a history of hypothyroidism and anxiety disorder was admitted to a local hospital with acute confusion, dysarthria, and ataxia. Shortly after admission, he had a convulsion and was intubated for airway protection. Computed tomography (CT) of the head was normal. EEG was normal. Cerebrospinal fluid contained 1 white blood cell/mm³, 1 red blood cell/mm³, protein 50 mg/dl, and glucose 115 mg/dl. A peripheral white blood cell count was 21 000/mm³. A urine toxicology screen was positive for benzodiazepines. Blood, urine, stool, sputum, and CSF cultures were negative. The patient was extubated on the third day after admission, only to require reintubation for hypoxic respiratory failure. Pupillary miosis, copious secretions, and diarrhoea were noted. He was transferred to our hospital for further evaluation.

On examination, his temperature was 99.3°F, pulse 98 beats/min and regular, and blood pressure 127/96 mm Hg. Marked diaphoresis and copious bronchial secretions were present. He was intubated, but was alert and oriented. Bilateral severe ptosis was present. Pupils were miotic and sluggishly reactive to light stimulation. Convergence was absent. Voluntary conjugate pursuit eye movements were markedly limited in range (less than 10°) in all directions. Saccadic eye movements were absent to a target and optokinetic strip. Oculocephalic reflexes and Bell's phenomenon remained intact. Fixation was interrupted by ocular flutter and occasional opsoclonus. He had a 3 Hz jaw tremor and occasional myoclonus, more prominent on the right. There was diffuse weakness (4/5), proximal greater than distal. Sensory examination was intact to light touch, temperature, and vibration. Reflexes were 1+ bilaterally and plantar responses were flexor.

Brain magnetic resonance imaging was normal. Nerve conduction studies and EMG with repetitive stimulation were normal. Organophosphate poisoning was confirmed by low levels of plasma and red blood cell cholinesterase activity, 0.1 IU/ml (normal 5.2 to 12.8 IU/ml) and 2.2 IU/ml (normal 6.2 to 10.3 IU/ml), respectively. Treatment with atropine and pralidoxime was initiated over the next 10 days. On day 15 of the hospital course, he became more responsive and on day 17 he was extubated. Neurological examination at this time showed mild diffuse weakness and tremor. His voluntary eye movements were full and his ocular flutter had resolved.

His wife brought in a sample of liquid found in his garage which proved to be Diazinon. Diazinon was also detected in the patient's urine by mass spectroscopy. He then admitted to ingesting wasp spray in a suicide attempt.

DISCUSSION

Preservation of the oculocephalic reflex and Bell's phenomenon suggests that our patient's gaze palsy was supranuclear. In the largest case series describing the neurological manifestations of organophosphate poisoning, Wadia and colleagues³ described both "ocular paralysis" and "slowed eye movements." Ocular paralysis usually consisted of bilateral sixth and occasionally third nerve palsies. There were also five cases of lateral conjugate gaze palsy, but reflex eye movements were not reported. In two patients with slowed voluntary eye movements, caloric stimulation revealed nystagmus in one patient and conjugate eye deviation in the other. To our knowledge, no other case of supranuclear gaze palsy after organophosphate poisoning has been reported.

Formal eye movement recordings were not undertaken on our patient owing to his critical condition. Nevertheless, he was unable to perform voluntary saccades on command during the period when he was alert. Pursuit eye movements were also markedly restricted. On the basis of clinical observation the saccadic oscillations were presumed to be opsoclonus and ocular flutter.

Although opsoclonus has been previously described in association with organophosphate poisoning,^{4,5} our patient was unique in that he demonstrated both supranuclear gaze palsy and saccadic oscillations. Ocular flutter is a saccadic oscillation similar to opsoclonus, characterised by involuntary horizontal eye movements without an intersaccadic interval. Although the exact mechanism and localisation of saccadic oscillations is uncertain, it has been suggested that opsoclonus and ocular flutter occur as a result of dysfunction of omnipause neurones that reside in the nuclei raphé interpositus.⁶ During normal fixation, these neurones are thought to inhibit the activity of burst neurones that drive normal saccades. However, pathological studies of patients with opsoclonus have not shown consistent abnormalities in the omnipause region.⁷ Furthermore, experimental lesions of omnipause neurones have been shown to cause slowing of horizontal and vertical saccades, but not saccadic oscillations.⁸ Zee and Robinson⁶ proposed that in addition to

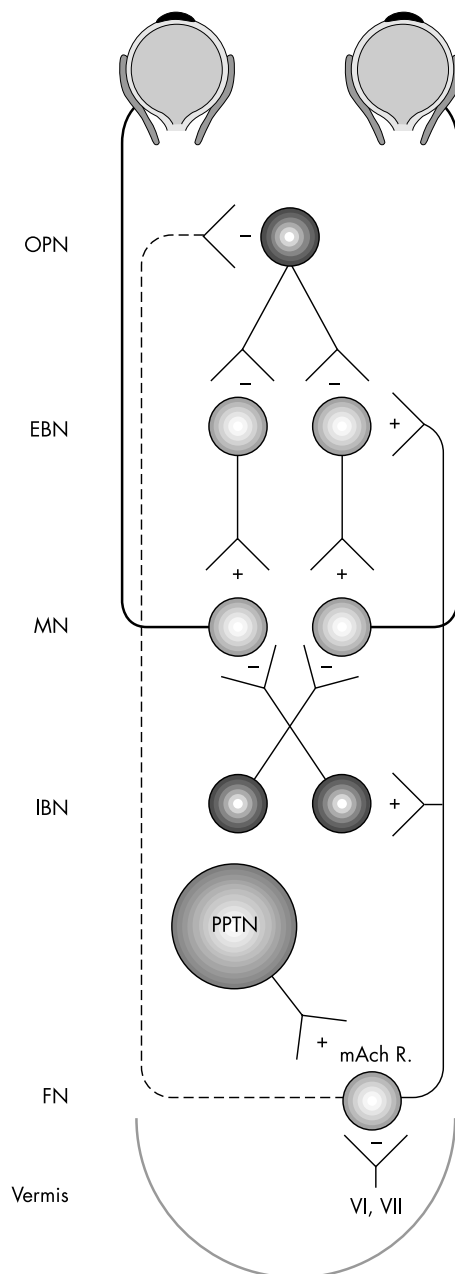


Figure 1 Schematic representation of the brain stem saccade system. Excitatory connections are labelled +, inhibitory connections are labelled -. Cholinergic neurones from the pedunculopontine tegmental nucleus (PPTN) project to the contralateral fastigial nucleus (FN). Excitatory projections terminate onto excitatory (EBN) and inhibitory (IBN) burst neurones bilaterally. The projections from the fastigial nucleus to omnipause neurones are presumably inhibitory. Organophosphate intoxication leads to a state of cholinergic excess that may overactivate the fastigial nuclei. Opsoclonus may occur as a result of inhibition of omnipause neurones (OPN) and subsequent release of EBNs. Adapted and modified from Robinson and Fuchs, 2001; with permission from the *Annual Review of Neuroscience* 2002, vol 24 (© 2001, Annual Reviews; www.AnnualReviews.org).

omnipause dysfunction there is inherent instability in the brain stem saccade system that could account for oscillations under appropriate conditions.

The fastigial ocular motor region has a well known role in the control of saccade accuracy. It is known to project to omnipause neurones and burst neurones.⁹⁻¹⁰ Although lesion studies of the cerebellum have not demonstrated opsoclonus or flutter, fastigial and vermal lesions have been shown to lead

to saccades with highly variable gains and velocities.¹⁰ Wong and colleagues⁹ created a model of opsoclonus by incorporating the fastigial ocular motor region into the brain stem saccade system. By introducing a slight delay and increase in the fastigial output (gain) into the feedback loop, they produced hypermetria. With further increases in the gain, they produced indefinite oscillations with a frequency and amplitude consistent with opsoclonus.

The fact that the eye findings occurred after organophosphate intoxication suggests that the pathways involved in saccade generation are partly mediated by acetylcholine. We propose that the source of input may arise from brain stem cholinergic nuclei such as the pedunculopontine tegmental nucleus (PPTN). This paired cell group has been traditionally linked to a variety of functions including locomotion, arousal, and sleep.¹¹ Its location adjacent to the brain stem saccadic system and the fastigial nucleus raises the possibility of a functional connection between these structures. PPTN neurones have been shown to project to the contralateral fastigial nucleus¹² and intermediate layers of the superior colliculus.¹³

In our case of organophosphate intoxication, excess acetylcholine could have led to enhanced fastigial output resulting in inhibition of omnipause neurones¹⁴ and release of burst neurones (fig 1). Activation of the fastigial nucleus along with the inherent instability and delay in the saccade generator could have led to opsoclonus. The signal for voluntary gaze control may have been inhibited by the effect of excess acetylcholine on other supranuclear projections.

Our patient's constellation of eye findings suggests that saccadic control may be mediated in part by acetylcholine. A similar combination of supranuclear gaze palsy and saccadic intrusions manifesting as square wave jerks often occurs in progressive supranuclear palsy. In contrast to our case, it is a loss of cholinergic cells in the PPTN, interstitial nucleus of Cajal, rostral interstitial nucleus of the MLF, and superior colliculus that is thought to lead to the hallmark eye movements of progressive supranuclear palsy.¹⁵⁻¹⁶ Whether it is a loss of acetylcholine or an excess in brain stem nuclei, it is conceivable that an imbalance of acetylcholine may lead to simultaneous release and inhibition of supranuclear structures involved in gaze control. The role of acetylcholine in gaze control is not well understood, and study of these cholinergic pathways may provide further insight into disorders of ocular motility. Furthermore, the diagnosis of organophosphate poisoning may be aided by the recognition of these eye findings.

Authors' affiliations

T-W Liang, L J Balcer, D Solomon, S R Messé, Department of Neurology, University of Pennsylvania School of Medicine, Philadelphia, Pennsylvania, USA

S L Galetta, Department of Ophthalmology, University of Pennsylvania School of Medicine

Competing interests: none declared

Correspondence to: Dr Tsao-Wei Liang, Department of Neurology, 3 East Gates, 3400 Spruce Street, Philadelphia, PA 19104, USA; liangtw@msn.com

Received 12 August 2002
In revised form 1 October 2002
Accepted 4 November 2002

REFERENCES

- Jay WM, Marcus RW, Jay MS. Primary position upbeat nystagmus with organophosphate poisoning. *J Pediatr Ophthalmol Strabismus* 1982;19:318-19.
- Hata S, Bernstein E, Davis LE. Atypical ocular bobbing in acute organophosphate poisoning. *Arch Neurol* 1986;43:185-6.
- Wadia RS, Sadagopan C, Amin RB, et al. Neurological manifestations of organophosphorus insecticide poisoning. *J Neurol Neurosurg Psychiatry* 1974;37:841-7.

- 4 **De Bleecker JL**. Transient opsoclonus in organophosphate poisoning. *Acta Neurol Scand* 1992;**86**:529–31.
- 5 **Pullicino P**, Aquilina J. Opsoclonus in organophosphate poisoning. *Arch Neurol* 1989;**46**:704–5.
- 6 **Zee DS**, Robinson DA. A hypothetical explanation of saccadic oscillations. *Ann Neurol* 1979;**5**:405–14.
- 7 **Digre KB**. Opsoclonus in adults. Report of three cases and review of the literature. *Arch Neurol* 1986;**43**:1165–75.
- 8 **Kaneko C**. Effect of ibotenic acid lesions of omnipause neurons on saccadic eye movements in rhesus monkeys. *J Neurophysiol* 1996;**75**:2229–42.
- 9 **Wong AM**, Musallam S, Tomlinson RD, *et al*. Opsoclonus in three dimensions: oculographic, neuropathologic and modelling correlates. *J Neurol Sci* 2001;**189**:71–81.
- 10 **Robinson FR**, Fuchs AF. The role of the cerebellum in voluntary eye movements. *Annu Rev Neurosci* 2001;**24**:981–1004.
- 11 **Steckler T**, Inglis W, Winn P. The pedunclopontine tegmental nucleus: a role in cognitive processes? *Brain Res Rev* 1994;**19**:298–318.
- 12 **Noda H**, Sugita S, Ikeda Y. Afferent and efferent connections of the oculomotor region of the fastigial nucleus in the macaque monkey. *J Comp Neurol* 1990;**302**:330–48.
- 13 **Kobayashi Y**, Saito Y, Isa T. Facilitation of saccade initiation by brainstem cholinergic system. *Brain Dev* 2001;**23**(suppl 1):S24–7.
- 14 **Scudder CA**, Kaneko CS, Fuchs AF. The brainstem burst generator for saccadic eye movements. A modern synthesis. *Exp Brain Res* 2002;**142**:439–62.
- 15 **Hirsch EC**, Graybiel AM, Duyckaerts C, *et al*. Neuronal loss in the pedunclopontine tegmental nucleus in Parkinson disease and in progressive supranuclear palsy. *Proc Natl Acad Sci USA* 1987;**84**:5976–80.
- 16 **Juncos JL**, Hirsch EC, Malessa S, *et al*. Mesencephalic cholinergic nuclei in progressive supranuclear palsy. *Neurology* 1991;**41**:25–30.