

PostScript

LETTERS

A case of late onset sporadic Parkinson's disease with an A53T mutation in α -synuclein

Parkinson's disease is a common progressive neurological disorder characterised by loss of nigral dopaminergic neurones. Rare autosomal dominant familial cases have been associated with point mutations in α -synuclein,^{1,2} but the vast majority of cases occur sporadically in older patients without an obvious cause. We now report a unique case of typical late onset Parkinson's disease without a family history which was associated with an A53T mutation in α -synuclein.

Case report

A war veteran of Polish origin was initially referred for assessment of his parkinsonian condition in 1997 at the age of 74. At presentation his history was of progressive bradykinesia, difficulty in rising from his chair, a tendency to fall, and mild tremor. He was a smoker and had been treated for hypertension and hypercholesterolaemia, but he gave no clear history of cerebrovascular disease. His Austrian mother died at 91 years of age and his French father lived to 89, neither suffering from symptoms of Parkinson's disease. He had four brothers and three sisters, none of whom had symptoms of Parkinson's disease (two died in their 20s during the war, the others died at ages 68, 76, 78, and 86, and one has lost touch with the family). Furthermore, his three children, each now in their sixth decade, currently have no diagnosis of Parkinson's disease. The family know of no relatives of Italian or Greek origin.

Examination was consistent with Parkinson's disease, with a typical shuffling gait, bilateral cogwheel rigidity, and mild tremor, but no pyramidal or cerebellar signs. Investigations were normal, but magnetic

resonance imaging of his brain was not possible because of metal shrapnel in his left orbit, face, and nose from the second world war. Computed tomography of the brain showed only mild age related cerebral atrophy without evidence of vascular disease.

Before presentation he had been prescribed co-beneldopa 62.5 mg three times a day with some symptomatic benefit. In July 1997 a five week trial off levodopa caused a deterioration in his symptoms, therefore his co-beneldopa was restarted and increased to 125 mg three times daily, and selegiline was started. On this treatment his symptoms remained stable for the next three years, and a second trial without levodopa or a dopamine agonist was attempted in May 2000, which again provoked marked bradykinesia and deterioration in his gait. His treatment was restarted after only five days, following which the symptoms once again resolved, showing the clear levodopa responsive element to his condition. He died in August 2002 but a necropsy examination of the brain was not undertaken.

Genetic analysis

PCR primers were designed from 5' untranslated region (UTR) and 3' UTR spanning each exon of α -synuclein (from NACP/ α -synuclein sequences submitted to NCBI database; accession number U46896-U46901; primer pairs designed to amplify exon 3 were 3F: GAGGACCTCTGTAGCTGG, and 3R: GACTGATATGTTCTAGATGCTC. Polymerase chain reaction (PCR) products were purified using QIAquick columns and sequenced according to the manufacturer's protocols by dye terminator (BigDye) methods using an ABI 377 automated sequencer (Applied Biosystems, Foster City, California, USA). All sequences were edited and confirmed by entering them into the BLAST algorithm database at the National Center for Biotechnology Information (<http://www.ncbi.nlm.nih.gov/blast>).

A single mutation from G to A was found at nucleotide 209 in exon 3 of the α -synuclein gene from this patient (fig 1A). The sample

was reanalysed twice following this observation, and also verified in the reverse direction. Restriction digest of the PCR products was carried out with Tsp45 I (New England BioLabs, Beverly, Massachusetts, USA), and digested products were separated by electrophoresis on a 2% agarose gel (fig 1B). The results correspond to an alanine to threonine shift at position 53 of α -synuclein (an A53T mutation).

Comment

The discovery of families with autosomal dominant Parkinson's disease together with the subsequent development of symptomatic α -synuclein transgenic models of the disease³ has provided strong support that a point mutation in α -synuclein is sufficient to cause this disorder. Furthermore, the discovery of α -synuclein in the Lewy bodies of patients with the common sporadic form of Parkinson's disease⁴ has suggested that this protein may well play a central role in all forms of the disease.

Until now the A53T mutation in α -synuclein has only been described in a large kindred of Italian origin and a small number of unrelated families of Greek origin, each with autosomal dominant inheritance of the Parkinson's disease phenotype.¹ The clinical phenotype and response to levodopa in the Italian kindred is relatively typical for Parkinson's disease, but with an earlier mean age of onset at 46 (SD 13) years, and a relatively rapid course, averaging 9.7 years from onset to death.⁵

The case we describe had no such family history, first noticed symptoms in his eighth decade, and had a clinical phenotype compatible with sporadic idiopathic Parkinson's disease. He had a relatively mild tremor, as noted in the Italian kindred.⁵ This case is therefore of particular interest as it appears to represent a unique sporadic mutation in α -synuclein that was not found in the remaining 60 control and patient samples that we analysed, and has not been reported in other series. Furthermore, despite carrying the

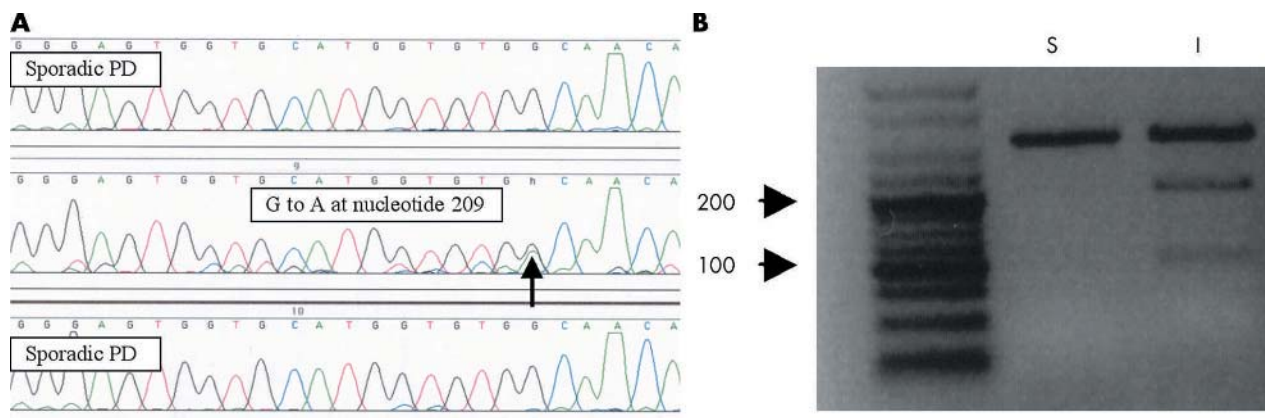


Figure 1 (A) Electropherogram of three patients with Parkinson's disease, the middle showing the mutation at nucleotide G209A in exon 3. Results were confirmed in the opposite direction. (B) Restriction digest of exon 3 polymerase chain reaction product. The patient is heterozygous for the G to A mutation, thus creating a new recognition site for Tsp45 I which cleaves the wild type 393 bp product to two fragments of 258 bp and 135 bp (S, sample from patient with sporadic Parkinson's disease; I, sample from index case).

genetic mutation this patient developed symptoms much later in life than most members of the Italian kindred described above.

The penetrance of the A53T α -synuclein gene in the Italian kindred has been estimated at 85%¹ so, although unlikely, it is theoretically possible that in this case the mutated gene is asymptomatic and the patient has developed unrelated late onset sporadic Parkinson's disease. Alternatively it is possible that the relatively mild late onset of Parkinson's disease in this patient represents a dose effect of the mutant gene. For example, both duplication and triplication of the α -synuclein gene locus have recently been found to cause familial Parkinson's disease,^{6,7} and the different severity of clinical phenotype seems to be correlated with the dose of α -synuclein.

This unique case extends the repertoire of patients in whom Parkinson's disease is associated with point mutations of α -synuclein. While we do not advocate routine clinical screening, this case suggests that further evaluation of mutations on this gene should be considered in cases of sporadic Parkinson's disease.

Acknowledgements

Our work is supported by the MRC, the Parkinson's Disease Society, and the Raymond and Beverly Sackler Fund.

A W Michell, R A Barker, R Raha-Chowdhury
Cambridge Centre for Brain Repair, Cambridge, UK

S K Raha

Department of Integrated Medicine, Princess of Wales Hospital, Bridgend, UK

Correspondence to: Dr Andrew Michell, Cambridge Centre for Brain Repair, Forvie Site, Robinson Way, Cambridge CB2 2PY, UK; awm13@cam.ac.uk

doi: 10.1136/jnnp.2004.046425

Competing interests: none declared

References

- 1 **Polymeropoulos MH, Lavedan C, Leroy E, et al.** Mutation in the alpha-synuclein gene identified in families with Parkinson's disease. *Science* 1997;**276**:2045-7.
- 2 **Kruger R, Kuhn W, Muller T, et al.** Ala30Pro mutation in the gene encoding alpha-synuclein in Parkinson's disease. *Nat Genet* 1998;**18**:106-8.
- 3 **Feany MB, Bender WW.** A Drosophila model of Parkinson's disease. *Nature* 2000;**404**:394-8.
- 4 **Spillantini MG, Schmidt ML, Lee VM, et al.** Alpha-synuclein in Lewy bodies. *Nature* 1997;**388**:839-40.

- 5 **Golbe LI, Di Iorio G, Bonavita V, et al.** A large kindred with autosomal dominant Parkinson's disease. *Ann Neurol* 1990;**27**:276-82.
- 6 **Chartier-Harlin MC, Kachergus J, Roumier C, et al.** Alpha-synuclein locus duplication as a cause of familial Parkinson's disease. *Lancet* 2004;**364**:1167-9.
- 7 **Singleton AB, Farrer M, Johnson J, et al.** alpha-Synuclein locus triplication causes Parkinson's disease. *Science* 2003;**302**:841.

Decreased CSF hypocretin-1 (orexin-A) after acute haemorrhagic brain injury

The novel hypothalamic neuropeptides orexins, or hypocretins, have gained much attention as potent modulators of various different physiological functions.¹ Deficient orexin neurotransmission may be responsible for excessive somnolence, as shown in several conditions related to secondary narcolepsy, through direct or indirect damage to the posterior hypothalamus and its connections.² We have studied for the first time the longitudinal changes of hypocretin-1 concentrations in cerebrospinal fluid (CSF) in patients with acute haemorrhagic brain injury.

Nine patients from a previously reported cohort³ and 21 controls (seven women and five men, median age 38 years, range 17 to 70) with other neurological disease were enrolled in the study (table 1). The patient group included five subjects with intracerebral haemorrhage and five with subarachnoid haemorrhage (table 1). All patients had extraventricular drains inserted within a median of two days of disease onset (range 2 to 36) as a treatment procedure because of increasing signs of hydrocephalus. Morning CSF samples were collected twice: first between day 1 and day 2 after catheter insertion, and second between day 4 and day 10. Patients were assessed using the Glasgow coma score (GCS) at presentation and the Glasgow outcome score (GOS) after three months.

The control group consisted of two patients with primary dementia, two with chronic headache, one with ataxia syndrome, and seven with non-specific neurological symptoms. None reported sleep abnormalities.

All samples were stored at -80°C until analysis. Hypocretin-1 was measured blind to diagnosis by direct radioimmunoassay of 100 μ l of CSF (Phoenix Pharmaceuticals, Belmont, California, USA; detection limit 40 pg/ml, intra-assay variation <5%), as described previously.⁴ Samples with undetectable concentrations (value below 40 pg/ml) were operationally plotted at 0 pg/ml. Statistical tests were carried out with the

GraphPad InStat 3.05 software package using the non-parametric Mann-Whitney U test.

There was a significant difference in median CSF hypocretin-1 concentrations between the controls (319.4 (302 to 361) pg/ml) and acute brain injury patients (100.4 (0 to 145.2) pg/ml) (calculated from the means of two measurements; median (range)). No difference was found for sex or age (table 1). The concentration of hypocretin-1 in CSF on the first day of sample collection (24 hours after catheter insertion) was 98.8 (0 to 147) pg/ml and did not change significantly over the observation period (114.0 (0 to 144) pg/ml). All concentrations were either lower than control values (>200 pg/ml), in the intermediate range (110 to 200 pg/ml), or in the very low, narcolepsy range (<110 pg/ml).⁴ Two patients (Nos 4 and 6) had undetectable levels, while all others had moderately decreased values compared with the cut off level of 196 pg/ml. In patient 6, the hypocretin-1 level increased to 53 pg/ml, but it remained undetectable in patient 4. Both patients suffered from spontaneous intracerebral haemorrhage, which was localised either to the thalamus (patient 4) or to the midbrain (patient 6). Other patients with moderately decreased hypocretin-1 levels were diagnosed as having subarachnoid haemorrhage (six patients) and intracerebral haemorrhage in the frontal lobe (one patient). There was no correlation between hypocretin-1 levels and GCS at disease onset or GOS at three months after disease onset.

Comment

This is the first study to show decreased levels of hypocretin-1 in the CSF of patients in the first week after acute brain injury caused by haemorrhagic stroke. Our data are in line with previous observations in patients with traumatic brain injury.⁴

The findings seem important in the light of a study investigating long term outcome in patients after subarachnoid haemorrhage.² More than 75% of patients reported excessive fatigue or daytime sleepiness, which persisted for long period (months to years) after the event. However, the exact mechanism responsible for the complaints remained unknown. Although the aetiology may be quite complex, an abnormality in the hypocretin/orexin system could make an important contribution to the phenomenon.

How intracerebral haemorrhage affects hypothalamic function remains obscure. In two of our patients direct damage to the thalamic/brain stem circuits appeared to be responsible. However, the remainder of the patients had a subarachnoid bleed or lesions in remote brain structures unrelated to the

Table 1 Patient characteristics

| Case | Sex | Age (y) | Diagnosis | Lesion and complications | GCS | IVS | GOS |
|------|-----|---------|--------------------|---------------------------------|-------|-----|------|
| 1 | M | 45 | ICH | HC | 6/15 | 2 | 2.4 |
| 2 | M | 66 | SAH (ACA aneurysm) | HC, multiple infarcts | 5/15 | 2 | 2.1 |
| 3 | M | 54 | SAH (PCA aneurysm) | HC, occipital infarct, re-bleed | 3/15 | 15 | 15.1 |
| 4 | F | 59 | ICH (spontaneous) | HC, thalamus | 9/15 | 4 | 4.1 |
| 5 | M | 59 | SAH | HC | 14/15 | 2 | 2.1 |
| 6 | F | 59 | ICH (spontaneous) | HC, midbrain, re-bleed | 6/15 | 2 | 2.1 |
| 7 | M | 72 | SAH | HC | 14/15 | 2 | 2.4 |
| 8 | F | 70 | SAH (ACA aneurysm) | HC, re-bleed | 15/15 | 8 | 8.5 |
| 9 | M | 45 | ICH (spontaneous) | Frontal lobe | 8/15 | 36 | 36.3 |

ACA, anterior cerebral artery; F, female; GCS, Glasgow coma scale (on admission); GOS, Glasgow outcome scale (after 3 months); HC, hydrocephalus; ICH, intracranial haemorrhage; IVS, intraventricular shunt (days after disease onset); M, male; PCA, posterior cerebral artery; SAH, subarachnoid haemorrhage; y, years.