

SHORT REPORT

Linear high intensity area along the medial margin of the internal segment of the globus pallidus in Machado-Joseph disease patients

S Yamada, J Nishimiya, T Nakajima, F Taketazu

J Neurol Neurosurg Psychiatry 2005;76:573–575. doi: 10.1136/jnnp.2004.040279

Our new finding on magnetic resonance imaging (MRI) of Machado-Joseph disease (MJD) patients indicates degeneration of the lenticular fasciculus (LF), a major outflow of the internal segment of the globus pallidus (GPi). We examined the clinical, radiological, and autopsy findings of one MJD patient and then retrospectively reviewed the MRI images of another 15 patients looking for a similar abnormal signal intensity. The significance of the clinicoradiological correlation of the MRI finding was confirmed by examining the MRI images of 130 control subjects. In the autopsy case, abnormal linear high intensity areas were observed along the bilateral medial margins of the internal segments of the GPi on T2 weighted, FLAIR, and proton density images, but not on T1 weighted images. Pathologically, this abnormal signal intensity was consistent with degeneration of the LF. The same finding was also observed in the other 15 patients. In two patients the finding was only unilaterally observed. No control subject showed this MRI finding. In MJD patients, abnormal linear high intensity areas indicating LF degeneration are usually observed along the medial margin of the GPi on T2 weighted, FLAIR, and proton density sequences. To our knowledge, this MRI finding has not previously been described.

The lenticular fasciculus (LF), which is a major outflow of the internal segment of the globus pallidus (GPi), is severely degenerated^{1–3} in Machado-Joseph disease (MJD), which is one of the most prevalent familial cerebellar degenerative diseases in Japan.⁴ We found in MJD patients that abnormal linear high intensity is observed on T2 weighted magnetic resonance imaging (MRI) along the medial margin of the internal segment of the GPi. This study was carried out to confirm that this MRI finding indicates LF degeneration. An autopsied case of MJD was clinicopathologically examined and then MRI images of other MJD cases were reviewed. The clinicoradiological relationship was examined and the significance of the MRI finding confirmed by examining MRI images of control subjects.

METHODS

Patients and control subjects

There were 16 MJD patients (table 1). The diagnosis of MJD was made based on clinical presentation, positive family history for autosomal dominant cerebellar degeneration, and DNA analysis. The control subjects consisted of 130 consecutive patients (aged between 12 and 77 years old; mean age 51.7 years), who presented at our hospital during 2003 because of headache or dizziness, but showed no neurological abnormality other than exaggerated deep tendon reflexes.

Molecular analysis of the MJD1 gene

Molecular analysis of the MJD1 gene was performed as described by Kawaguchi and colleagues.⁵

MRI examination

MRI examinations were performed using two different systems. A 1.0 T system (SMT-100X, Shimadzu, Kyoto, Japan) was used until April 2000, and a 1.5 T system (Magnetom Symphony, Siemens, Munich, Germany) thereafter. Standard brain examinations were carried out using T1 and T2 sequences with contiguous 10 mm thick slices. Proton density and FLAIR sequences were added in some cases. The axial slices were angled to lie parallel to the skull base. The modified coronal slices were angled perpendicular to the posterior limb of the internal capsule in axial slice. No patient had had a previous MRI examination.

Neuropathological examination

The cerebrum was cut into hemispheres on the mid-sagittal line, and sliced coronary (the left hemisphere) and horizontal (the right hemisphere) sections were embedded in paraffin, and subjected to haematoxylin-eosin, Klüver-Barrera, and Holzer staining.

RESULTS

Autopsied patient (patient 4 in table 1)

Physical characteristics

A 48 year old man was admitted to our hospital because of unstable gait of 8 years' duration. Mild nystagmus, slurred scanning speech, and limb ataxia had been noted when he was 43 years old. He had a family history of a similar neurologic disturbance (his mother's clinicopathological findings had previously been reported⁶). Mild lateral and upward gaze palsy, gaze nystagmus, and bulging eyes were noted. He would close the right eye to avoid double vision. Muscle tone was generally decreased, but strength was normal. Deep tendon reflexes were generally increased, and clonus was present in the right wrist and bilateral ankles, but planter responses were flexor. Limb ataxia was present in all extremities. There were no autonomic disturbances. By age 52, moderate muscle weakness of the limbs had appeared and the patient became unable to walk at age 54. The diagnosis of MJD was confirmed by DNA analysis. At age 56, the first MRI examination was performed. At age 58, near looking reflex became absent. Athetoid movement of the tongue, neck, and extremities, and rapid ballistic movements of the lower limbs were observed. Hypoalgesia of the left side of the face and thermo-hypoesthesia of the legs were noted. The patient died of aspiration pneumonia at age 61.

Abbreviations: GPi, internal segment of the globus pallidus; LF, lenticular fasciculus; MJD, Machado-Joseph disease; MRI, magnetic resonance imaging

Table 1 MJD patient characteristics

Patients			Symptoms at the time of MRI											
No	Sex	(CAG) _n	Onset age	Duration before MRI (years)	Lim EM	Slow EM	Atx	M atroph	Fasc	Sp	Bab	IM	Rig	Sen
1	F	13/73	30	19	p	n	p	n	n	n	n	n	n	n
2	F	14/56	48	16	p	n	p	n	p	n	n	p	n	p
3	F	25/67	42	16	p	n	p	n	p	n	n	n	n	n
4*	M	18/71	40	16	p	n	p	p	n	p	p	n	n	n
5	M	27/70	50	16	n	p	p	n	p	n	p	n	p	n
6	M	23/72	32	14	p	n	p	n	p	p	n	p	n	n
7	F	18/70	36	12	n	n	p	n	n	p	n	n	n	p
8	M	19/70	31	11	n	n	p	n	p	p	n	n	p	n
9	F	25/63	48	10	p	n	p	n	p	p	p	n	n	p
10	M	19/65	52	8	n	n	p	p	n	p	p	n	n	n
11†	F	19/65	40	8	n	n	p	n	p	p	n	n	n	p
12	F	27/72	38	7	p	p	p	n	p	n	p	n	n	p
13	M	27/59	69	6	n	n	p	p	p	n	p	n	n	n
14	M	27/63	54	5	n	n	p	n	p	p	n	n	n	n
15	M	27/65	37	3	p	n	p	n	p	p	n	n	p	n
16	M	27/66	58	1	n	n	p	n	n	n	n	n	n	n

*The autopsied patient; †the sister of the autopsied patient.

Atx, ataxia; Bab, Babinski's sign; (CAG)_n, the number of CAG repeats; Fasc, fasciculation; IM, abnormal involuntary movement; Lim EM, limitation in eye movement; M atroph, muscular atrophy; n, absent; p, present; Rig, rigidity; Sens, sensory disturbance; Slow EM, slow eye movement; Sp, spasticity.

Neuropathological findings

The brain of the autopsied patient weighed 1130 g. The brain stem and the cerebellum were markedly atrophic. On horizontal section, the GPi showed severe gliosis with relative preservation of neurons (fig 1A). A dense band of fibrillary gliosis was observed along the medial margin of the GPi and appeared to result from the degeneration of the nerve fibres projecting medially through the internal capsule. This gliosis was prominent from the middle to the caudal portion of the GPi, a distribution consistent with that of the LF⁷ which emerges at the medial margin of the GPi and penetrates the internal capsule. On coronal section, the gliosis was not observed at the level of the putamen (fig 1B), a distribution consistent with the LF running upwards before penetrating the internal capsule.⁷ The subthalamic nucleus was also degenerated; its dorsal margin was unclear because of the marked myelin pallor of the neighbouring LF. The substantia nigra showed moderate neuronal loss and astrocytosis.

MRI findings

On axial sections, abnormal linear high intensity areas were observed bilaterally along the medial margins of the GPi on T2 weighted, FLAIR, and proton density images (fig 1C and D), but were not apparent on T1 weighted image. These areas were prominent from the middle to the caudal portion of the posterior limb of the internal capsule and were most clear at the level of the anterior commissure. This finding was observed in both the first MRI at age 56 and the last image at age 60. This distribution of high intensity areas was identical to that of the gliosis on the pathological specimens.

MRI findings in the other patients and control subjects

The same finding as described above was observed in all the other 15 MJD patients. Modified coronal slices were examined in three patients and showed abnormal high intensity areas (fig 1E and F), whose distribution was the same as that of the gliosis on the coronary section of the pathological specimen (fig 1B), and coincided with the distribution of the LF which runs upwards before penetrating the internal capsule.⁷ This abnormal high intensity area was only weakly observed in patients 8, 11, and 16. In patients 2 and 16, the abnormal high intensity area was demonstrated only on the right side (fig 1G and H). None of the 130 control subjects showed the above finding.

DISCUSSION

Our results showed that an abnormal linear high intensity area indicating LF degeneration is usually observed along the medial margin of the GPi on MRI in MJD patients; this finding was not observed in control subjects. Our results are supported by the fact that on pathological examination severe LF degeneration is usually observed in the MJD brain.² To our knowledge this MRI finding has not previously been described.

The abnormal signal probably indicates LF degeneration but could also be due to the degeneration of other fibre systems whose topographical distribution partly overlaps that of the LF. There are two candidates for this possibility because the subthalamic nucleus and the substantia nigra are usually involved^{1-3, 8} in MJD. The first is the subthalamic fasciculus⁹⁻¹¹ which is the main outflow of the subthalamic nucleus to the globus pallidus. The second is the dopaminergic mesostriatal fibres which run along the LF,¹² but we have never observed this abnormal signal in Parkinson's disease patients. On the other hand, the abnormal signal may not be specific for MJD because it probably indicates LF degeneration.

Our results show that the signal is observed in most MJD patients from the early to the end stages of the disease, but may not be present at the very beginning, because the signal was observed only unilaterally in a patient (patient 16) 1 year after the onset of the disease. This result is similar to a radiological report demonstrating that atrophy of the globus pallidus was observed only in patients with an MJD duration of 10 years or longer.¹³ In addition, the unilateral presentation 16 years after onset of the disease in a patient (patient 2) whose CAG expansion was very small compared to our other patients, suggests that the presentation of the abnormal signal depends on the size of the CAG expansion in the MJD1 gene. This result accords with the fact that the clinical course and the degree of brainstem and cerebellar atrophy in MJD patients are closely correlated with the size of CAG expansion in the MJD1 gene.¹⁴⁻¹⁷

No specific correlation was confirmed between the presence of the signal and clinical symptoms. But it is interesting that no rigidity was observed in 13 of our 16 patients. Considering that the substantia nigra of MJD patients is usually severely degenerated,¹⁵ and that nigral degeneration results in parkinsonism, it seems likely that MJD patients would usually show parkinsonism. But

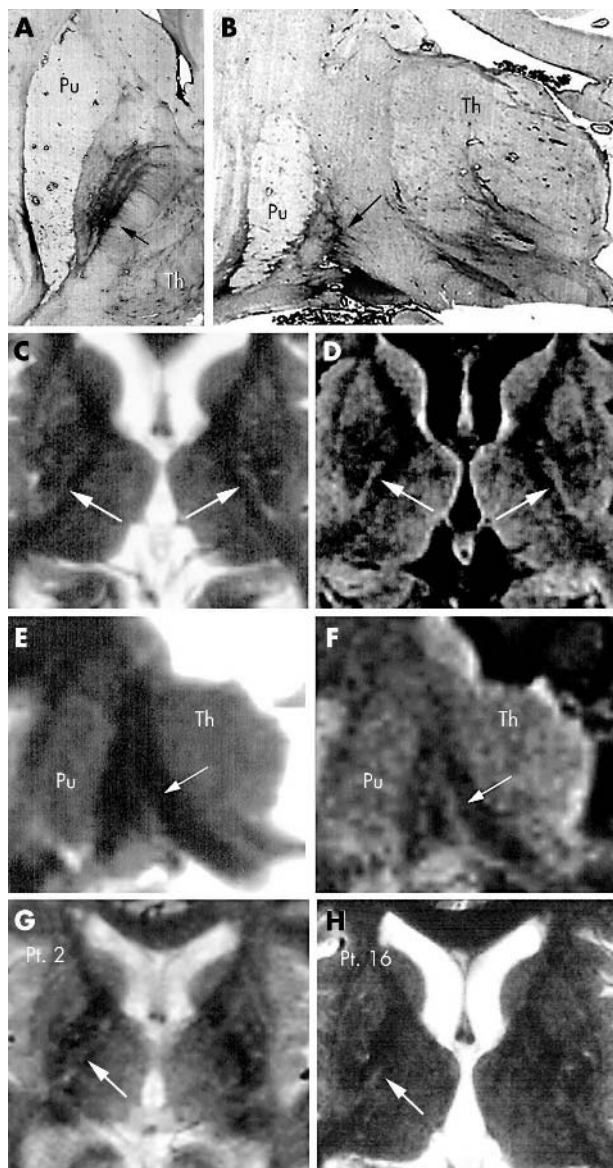


Figure 1 Horizontal (A) and coronary (B) sections of the autopsied brain (Holzer's stain). Severe fibrillary gliosis observed along the medial margin of the globus pallidus appears to result from the degeneration of nerve fibres arising in the globus pallidus and projecting medially through the internal capsule. This gliosis is not apparent at the level of the putamen (arrows; Holzer; Pu, putamen; Th, thalamus). (C, D). MRI images of the brain of the autopsied patient (patient 4, axial section). Abnormal linear high intensity areas (arrows) are observed bilaterally along the medial margin of the GPI on T2 weighted (C) and FLAIR images (D). This high intensity area is most intense from the middle to the caudal portion of the posterior limb of the internal capsule (arrow; Pu, putamen; Th, thalamus). (E, F). T2 weighted (E) and FLAIR (F) MRI images of the modified coronal slices of patient 8. Abnormal high intensity areas are observed along the medial margin of the globus pallidus (arrows). The thickness of this high intensity area decreases as it ascends upwards and is not observed at the level of the putamen. This distribution is the same as that of the fibrillary gliosis observed on the pathological specimen (Pu, putamen; Th, thalamus). (G, H). T2 weighted images of patients 2 and 16 in whom abnormal high intensity is demonstrated only on the right side (Pt., patient number described in table 1).

parkinsonian features are usually absent in MJD patients even in the late stage of the disease.^{3, 18} This is a major clinicopathological discrepancy in MJD. However, our results can explain this problem as follows. The early development of the abnormal signal in our patients indicates that GPI

degeneration starts at an early stage in MJD. This GPI degeneration can alleviate rigidity by decreasing the output from GPI to the thalamus, and may cancel the influence of the nigral lesion which causes excessive tonic and phasic inhibition of thalamocortical neurons.¹⁹ This effect of GPI lesion in MJD is similar to that of pallidotomy, which alleviates symptoms in Parkinson's disease.²⁰

Authors' affiliations

S Yamada, Department of Neurology, Yamanashi University School of Medicine, Tamaho-cho, Yamanashi, Japan

S Yamada, J Nishimiya, Department of Neurology, Kohnodai Hospital, Chiba, Japan

T Nakajima, Department of Neurology, National Saigata Hospital, Niigata, Japan

F Taketazu, Division of Hematology, Department of General Medicine, Omiya Medical Center, Jichi Medical School, Saitama, Japan

Competing interests: none declared

Correspondence to: S Yamada, Department of Neurology, Kohnodai Hospital, Kohnodai 1-7-1, Ichikawa-shi, Chiba 272-8516, Japan; lives@oak.dti.ne.jp

Received 29 February 2004

Revised version received 6 August 2004

Accepted 8 August 2004

REFERENCES

- 1 Yuasa T, Ohama E, Harayama H, *et al*. Joseph's disease: clinical and pathological studies in a Japanese family. *Ann Neurol* 1986;**19**:152-7.
- 2 Iwabuchi K, Yagishita S. A neuropathological study on autosomal dominant forms of spinocerebellar degeneration. *Neuropathology* 1991;**11**:155-77.
- 3 Takiyama Y, Oyanagi S, Kawashima S, *et al*. A clinical and pathological study of a large Japanese family with Machado-Joseph disease tightly linked to the DNA markers on chromosome 14q. *Neurology* 1994;**44**:1302-8.
- 4 Watanabe H, Tanaka F, Matsumoto M, *et al*. Frequency analysis of autosomal dominant cerebellar ataxias in Japanese patients and clinical characterization of spinocerebellar ataxia type 6. *Clin Genet* 1998;**53**:13-9.
- 5 Kawaguchi Y, Okamoto T, Taniwaki M, *et al*. CAG expansions in a novel gene for Machado-Joseph disease at chromosome 14q32.1. *Nat Genet* 1994;**8**:221-8.
- 6 Mizutani T, Oda M, Abe H, *et al*. Hereditary multisystemic degeneration with unusual combination of cerebellar, dentato-rubal, and nigro-subthalamic degenerations. *Clin Neuropathol* 1983;**2**:147-55.
- 7 Kuo J, Carpenter MB. Organization of pallidothalamic projections in the rhesus monkey. *J Comp Neurol* 1973;**151**:201-36.
- 8 Iwabuchi K, Nagatomo H, Hanihara T, *et al*. Clinicopathological study on autosomal dominant hereditary spastic ataxia (Greenfield): its relationship to ataxo-choreoathetosis form of DRPLA, spinocerebellar degeneration, Machado-Joseph disease, and SCA3. *Shinkei Kenkyu no Shinpo* 1995;**39**:164-87.
- 9 Carpenter MB, Strominger NL. Efferent fibers of the subthalamic nucleus in the monkey. A comparison of the efferent projections of the subthalamic nucleus, substantia nigra and globus pallidus. *Am J Anat* 1967;**121**:41-72.
- 10 Nauta WH, Mehler WR. Projections of the lentiform nucleus in the monkey. *Brain Res* 1966;**1**:3-42.
- 11 Nauta HJW, Cole M. Efferent projections of the subthalamic nucleus: an autoradiographic study in monkey and cat. *J Comp Neurol* 1978;**180**:1-16.
- 12 Lavoie B, Smith Y, Parent A. Dopaminergic innervation of the basal ganglia in the squirrel monkey as revealed by tyrosine hydroxylase immunohistochemistry. *J Comp Neurol* 1989;**289**:36-52.
- 13 Tokumaru AM, Kamakura K, Maki T, Murayama S, *et al*. Magnetic resonance imaging findings of Machado-Joseph disease: histopathologic correlation. *J Comput Assist Tomogr* 2003;**27**:241-8.
- 14 Maruyama H, Nakamura S, Matsuyama Z, *et al*. Molecular features of the CAG repeats and clinical manifestation of Machado-Joseph disease. *Hum Mol Genet* 1995;**4**:807-12.
- 15 Onodera O, Idezuka J, Igarashi S, *et al*. Progressive atrophy of cerebellum and brainstem as a function of age and the size of the expanded CAG repeats in the MJD1 gene in Machado-Joseph disease. *Ann Neurol* 1998;**43**:288-96.
- 16 Abe Y, Tanaka F, Matsumoto M, *et al*. CAG repeat number correlates with the rate of brainstem and cerebellar atrophy in Machado-Joseph disease. *Neurology* 1998;**51**:882-4.
- 17 Yoshizawa T, Watanabe M, Frusho K, *et al*. Magnetic resonance imaging demonstrates differential atrophy of pontine base and tegmentum in Machado-Joseph disease. *J Neurol Sci* 2003;**215**:45-50.
- 18 Lopes-Cendes I, Silveira I, Maciel P, *et al*. Limits of clinical assessment in the accurate diagnosis of Machado-Joseph disease. *Arch Neurol* 1996;**53**:1168-74.
- 19 DeLong MR. Primate models of movement disorders of basal ganglia origin. *Trends Neurosci* 1990;**40**:281-5.
- 20 Fine J, Duff, Chen R, *et al*. Long-term follow-up of unilateral pallidotomy in advanced Parkinson's disease. *N Engl J Med* 2000;**342**:1708-14.