

## ADVERSE DRUG REACTION

## Hypersensitivity syndrome caused by amitriptyline administration

Haralampos J Milionis, Antigone Skopelitou, Moses S Elisaf

### Abstract

**Adverse cutaneous manifestations are among the most common side effects associated with psychotropic drugs. Skin reactions due to amitriptyline (a tricyclic antidepressant agent) include rashes and hypersensitivity reactions (for example, urticaria and photosensitivity) as well as hyperpigmentation. Hypersensitivity syndrome is a specific severe idiosyncratic reaction causing skin, liver, joint, and haematological abnormalities, which usually resolve after the discontinuation of the implicated drug. A case of a 24 year old woman who experienced hypersensitivity syndrome three weeks after the initiation of amitriptyline is reported.**

(*Postgrad Med J* 2000;76:361-363)

Keywords: tricyclic antidepressant drugs; amitriptyline; adverse cutaneous reactions; hypersensitivity syndrome

Psychotropic agents, such as mood stabilising drugs, antidepressants and anti-anxiety drugs, have been in widespread use since mid-1950s. Among the most common side effects associated with their use are those involving the skin.<sup>1</sup> It is estimated that skin reactions caused by psychotropic drugs are twice as frequent as those caused by most other drugs.<sup>1</sup> Amitriptyline is a tricyclic antidepressant agent prescribed for the management of depressive illness, particularly when sedation is required. Adverse cutaneous manifestations related to amitriptyline include rashes and hypersensitivity reactions (for example, urticaria and photosensitivity).<sup>1</sup>

Hypersensitivity syndrome is a specific severe idiosyncratic reaction causing skin, liver, joint, and haematological disturbances. Certain drugs have been incriminated.<sup>2</sup> We report the case of a 24 year old woman who experienced hypersensitivity syndrome three weeks after the initiation of amitriptyline.

### Case report

A 24 year old woman was referred to the emergency department because of erythroderma and fever. She was receiving amitriptyline 25 mg orally twice daily because of mild depression for three weeks when she noticed a pruritic morbilliform rash on the trunk. Her past medical history was unremarkable.

On admission she was anxious and febrile (38.3°C), blood pressure was 110/65 mm Hg, pulse rate 125 beats/min, and respiration rate was 23 breaths/min. On physical examination,

generalised erythroderma with mild scaling (fig 1) was evident. There was also cervical lymphadenopathy, but no hepatomegaly or splenomegaly.

The electrocardiogram showed sinus tachycardia; a chest radiograph was normal. Complete blood count showed: packed cell volume 0.45, white blood cell count  $29 \times 10^9/l$ , with neutrophils 40%, lymphocytes 30%, monocytes 5%, and eosinophils 25% (absolute number of eosinophils  $7.25 \times 10^9/l$ ). The platelet count was  $210 \times 10^9/l$ ; erythrocyte sedimentation rate 10 mm/hour; and C reactive protein 12 mg/l. Serum aspartate aminotransferase was 87 U/l (normal range 0-40 U/l) and alanine aminotransferase 103 U/l (normal range 0-40 U/l). Other laboratory investigations gave results within normal limits. Serological tests for syphilis, cytomegalovirus, Epstein-Barr virus, hepatitis A, B, and C, HIV, human T cell leukaemia virus (HTLV)-I, and HTLV-II were negative. Urinalysis as well as urine and blood cultures were also negative.

An ultrasound of the abdomen and an echocardiogram showed no abnormalities.

A bone marrow specimen showed a normal erythroid cell line, normal megakaryocytes, and a remarkable increase of eosinophils in the

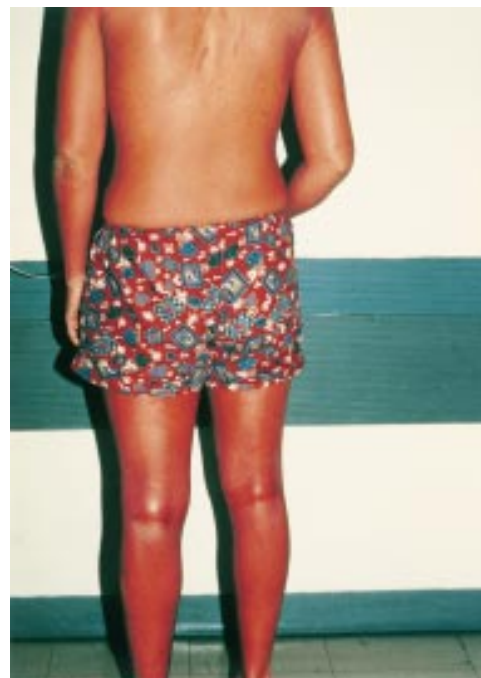

Figure 1 Erythroderma after three weeks of amitriptyline initiation (reproduced with the patient's permission).

Department of  
Internal Medicine,  
Medical School,  
University of Ioannina,  
GR 451 10 Ioannina,  
Greece

H J Milionis  
A Skopelitou  
M S Elisaf

Correspondence to:  
Dr Elisaf (e-mail:  
melisaf@cc.uoi.gr)

Submitted 14 June 1999  
Accepted 8 October 1999

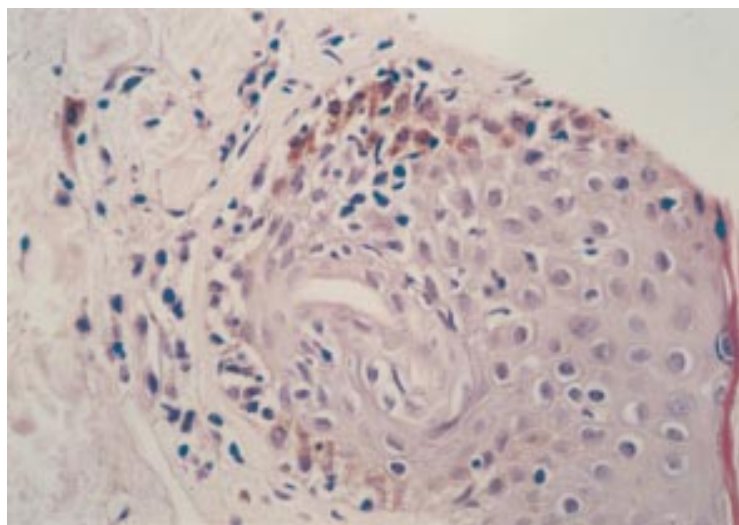


Figure 2 Skin biopsy: a site of "pigmentary incontinence" and mild eosinophilic infiltration (haematoxylin and eosin  $\times 40$ ) consistent with the diagnosis of drug induced eruption.

myeloid cell line. The myeloid to erythroid cell line ratio was 5:1.

Skin biopsy disclosed sites of basal cell layer hydropic degeneration and the presence of melanin within macrophages in the upper dermis (pigmentary incontinence). A moderate inflammatory eosinophilic infiltration was found perivascularly and round skin appendages (fig 2). These findings were consistent with a drug induced eruption.

Amitriptyline was discontinued. Prednisolone 25 mg daily was administered intravenously for seven days, tapered over the following week. Five days after amitriptyline withdrawal, the patient was afebrile. The rash became exfoliating with generalised scaling from the head downwards. An emollient euserine cream was applied. A month later, skin lesions and blood tests normalised.

### Discussion

Amitriptyline administration has been associated with skin rashes and hypersensitivity reactions, such as urticaria and photosensitivity as well as hyperpigmentation.<sup>1</sup> The rapidly progressive pigmentation has been attributed to the synergistic effect of amitriptyline and minocycline, potentiating the functional disruption in cellular activity that leads to hyperpigmentation.<sup>3</sup>

Hypersensitivity syndrome refers to a specific severe idiosyncratic reaction. The syndrome typically includes skin rash and fever, often with hepatitis, arthralgias, lymphadenopathy, or haematological disorders (mainly eosinophilia and atypical lymphocytosis).<sup>2</sup> Hypersensitivity syndrome develops two to six weeks after a drug is initiated, a period that is significantly longer than that seen with other drug associated skin reactions.<sup>2</sup> For example, Stevens-Johnson syndrome or drug induced vasculitis usually appear one to three weeks after a drug's first dose.<sup>2,4</sup> Because of its relatively late onset, slow evolution, and clinical similarities with many infections (principally viral), the diagnosis of hypersensitivity syn-

drome may be delayed. Certain drugs, such as antiepileptic agents (phenytoin, carbamazepine, and phenobarbital), allopurinol, gold salts, dapsone, and sulphonamides have been reported to be associated with hypersensitivity syndrome.<sup>2,5,6</sup> Hypersensitivity syndrome due to either antiepileptics or sulphonamides are clinically indistinguishable.<sup>2</sup> In addition to exfoliating dermatitis, atypical lymphoid hyperplasia, pseudolymphoma, hepatitis, interstitial nephritis, and haematological abnormalities (eosinophilia and mononucleosis-like atypical lymphocytosis) have been described in relation with phenytoin and carbamazepine treatment.<sup>2,6</sup>

Like replicating viruses (for example Epstein-Barr virus), drugs such as phenytoin, carbamazepine and sulfamethoxazole, stimulate major T cell subgroups, while drug specific T cell clones (mainly CD4+ and CD8+) may be generated.<sup>7</sup> Furthermore, drug specific T cells secrete in vitro remarkably high amounts of interleukin-5, which is mainly involved in the maturation of eosinophils.<sup>7</sup> Since amitriptyline shares a common tricyclic nucleus with carbamazepine, the aforementioned immunological mechanisms may be implicated in the pathogenesis of hypersensitivity syndrome. It is also of interest that a genetically determined inability to detoxify the toxic arene oxide metabolic products of anticonvulsants, including carbamazepine, has been documented in many (but not all) hypersensitivity syndrome patients.<sup>2,8</sup> Cells from family members of affected patients show an increased in vitro sensitivity to these toxic metabolites.<sup>8</sup>

Drug withdrawal usually leads to total recovery, although rash and hepatitis may persist for weeks.<sup>2</sup> However, in patients receiving antidepressants, abnormal liver function tests in isolation represent a significant problem to the clinician. These disturbances fall into two categories: predicted dose related (for example suicidal overdose) and dose independent idiosyncratic (immune mediated) drug reactions.<sup>9</sup> The latter is usually the case with antidepressive agents. Clinical manifestations vary widely from minor elevations of aminotransferases to acute severe hepatitis.<sup>9</sup> Corticosteroids have been widely advocated in the management of hypersensitivity syndrome, despite the lack of controlled studies.<sup>10</sup>

Although erythema multiforme, angioneurotic oedema, and hyperpigmentation have been rarely described in patients treated with amitriptyline,<sup>1,3</sup> to the best of our knowledge, hypersensitivity syndrome related to amitriptyline administration has not as yet been reported. Moreover, neither the manufacturer (Dambergis-Tropon) nor the committee of adverse drug effects of the National Drug Organisation are at present aware of reports of such a side effect.

1 Srebrnik A, Hes JP, Brenner S. Adverse cutaneous reactions to psychotropic drugs. *Acta Derm Venereol* 1991;suppl 158:3-12.

2 Roujeau JC, Stern RS. Severe adverse cutaneous reactions to drugs. *N Engl J Med* 1994;331:1272-85.

- 3 Basler RS, Goetz CS. Synergism of minocycline and amitriptyline in cutaneous hyperpigmentation (letter). *J Acad Dermatol* 1985;12:577.
- 4 Strom BL, Carson JL, Halpern AC, *et al.* A population-based study of Stevens-Johnson syndrome: incidence and antecedent drug exposures. *Arch Dermatol* 1991;127:831-8.
- 5 Haruda F. Phenytoin hypersensitivity: 38 cases. *Neurology* 1979;29:1480-5.
- 6 Ray-Chaudhuri K, Pye IF, Boggild M. Hypersensitivity to carbamazepine presenting with a leukemoid reaction, eosinophilia, erythroderma, and renal failure. *Neurology* 1989;39:436-8.
- 7 Mauri-Hellweg D, Bettens F, Mauri D, *et al.* Activation of drug-specific CD4+ and CD8+ T cells in individuals allergic to sulfonamides, phenytoin, and carbamazepine. *J Immunol* 1995;155:462-72.
- 8 Shear NH, Spielberg SP. Anticonvulsant hypersensitivity syndrome. In vitro assessment of risk. *J Clin Invest* 1988;82:1826-32.
- 9 Davis M. Hepatotoxicity of antidepressants. *Int Clin Psychopharmacol* 1991;6:97-103.
- 10 Murphy JM, Mashman J, Miller JD, *et al.* Suppression of carbamazepine-induced rash with prednisone. *Neurology* 1991;41:144-5.