

CLINICAL AUDIT

Do junior doctors know where to insert chest drains safely?

J R Griffiths, N Roberts

Postgrad Med J 2005;81:456–458. doi: 10.1136/pgmj.2004.024752

Background: The safe insertion of a chest drain is a skill doctors across specialties require. Incorrect placement can lead to significant morbidity and even mortality.

Methods: This audit surveyed junior doctors working in a teaching hospital about their specialty and level of experience with intercostal drains. They were then asked to mark on a photograph where they would insert a chest drain for a pneumothorax in a non-emergency situation.

Results: Of the 55 junior doctors surveyed, 45% were outside the safe area of chest drain insertion as defined by the British Thoracic Society. The most common error was a choice of insertion site too low (24%).

Conclusions: In this audit 45% of juniors surveyed would have placed a chest drain outside the safe triangle recommended by the British Thoracic Society. The common mistake of a choice of insertion site too low should be discussed in postgraduate teaching programmes.

Chest drains are used in several clinical settings and doctors in nearly all specialties need to be capable of their safe insertion. Pneumothoraces are commonly seen in emergency departments, on acute medical takes, in intensive care units, and in trauma patients on orthopaedic and surgical wards. Hence most doctors will be exposed to intercostal drains regardless of specialty.

Incorrect insertion of a chest drain can have disastrous consequences. Perforation of both the right and left ventricle has been described.^{1,2} Examples of incorrect placement also include: the pericardium with subsequent tamponade,³ intrapulmonary including the contralateral hemi-thorax,^{4,7} and the liver.⁸

This study set out to assess junior doctors' knowledge of the correct anatomical landmarks used when inserting an intercostal chest drain (ICD). This area is known as the "triangle of safety"—bordered by the anterior border of the latissimus dorsi, the lateral border of the pectoralis major muscle, a line superior to the horizontal level of the nipple, and an apex below the axilla. The British Thoracic Society (BTS) guidelines clearly detail this triangle.⁹

METHODS

Fifty five junior doctors working at the Northern General Hospital, Sheffield were questioned. They were asked their grade, current specialty, whether they had experience of cardiothoracic surgery or respiratory medicine, and their level of experience regarding ICD insertion. This was split into four categories:

1. Performed unsupervised
2. Performed supervised
3. Observed
4. No experience

The doctors were then asked to mark on a diagram of the chest wall (fig 1) where they would insert a chest drain for a pneumothorax in a non-emergency situation. The results were analysed by a specialist registrar in cardiothoracic surgery to decide whether they were inside the triangle of safety.

RESULTS

Of the 55 doctors, 20 were PRHOs, 33 were SHOs (year 1 to year 6), and two were SpRs. Ten doctors were working in accident and emergency (A&E), 25 in a surgical specialty, and 20 in a medical specialty.

Figure 2 shows the results of chest drain placement. Twenty five doctors (45%) marked the diagram outside the safe triangle. The commonest site of incorrect placement was too low (24%).

Of the PRHOs questioned, six (30%) were correct and 14 (70%) were incorrect. Twenty two SHOs (67%) were correct and 11 (33%) incorrect and both SpRs correctly marked the diagram (fig 3).

In terms of experience of cardiothoracic surgery or respiratory medicine, where there is greater exposure to patients requiring ICD insertion, 27 (49%) doctors had experience of one or both specialties. All eight doctors with experience of cardiothoracic surgery were correct. Of the 15 with respiratory medicine experience, six (40%) were correct and nine (60%) incorrect. Four doctors had experience of both specialties—three were correct and one incorrect. Of the 28 doctors with no experience, 13 (46%) were correct and 15 (54%) incorrect (fig 4).

With regard to previous experience of ICD insertion, 11 doctors had no experience; 16 had observed ICD insertion; 11 had performed supervised insertion, and 17 doctors had inserted chest drains without supervision.

Of the 11 with no experience, three (27%) were correct and eight (73%) incorrect. Five of those doctors who had observed ICD insertion were correct (31%) and 11 were incorrect

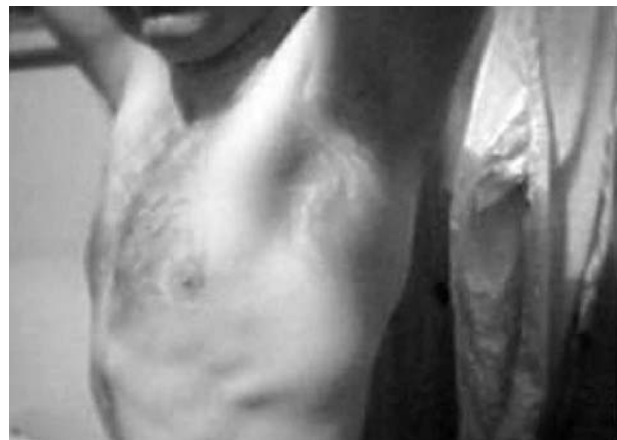

Figure 1 Photograph used for doctors to mark site of ICD insertion.

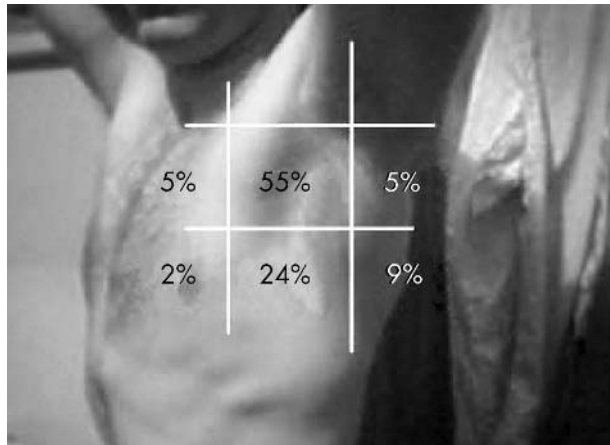

Figure 2 Diagram showing where doctors marked the photograph split into nine sections, the central square being in the triangle of safety.

(69%). Eight doctors who had performed ICD insertion under supervision correctly located the site for insertion (73%) but three (27%) did not. Three of the 17 doctors who had performed unsupervised chest drain insertion failed to locate the correct site for insertion (18%), however most doctors in this category were correct (14 of 17, 82%) (fig 5).

DISCUSSION

The BTS guidelines for the insertion of a chest drain⁹ state that in current hospital practice chest drains are used in many clinical settings and suggest that doctors in most specialties need to be capable of their safe insertion.

This study shows that many junior doctors are unaware of the anatomical landmarks for the safe insertion of intercostal chest drains.

It should be noted that insertion of a chest drain is not the mainstay of treatment for all pneumothoraces, observation only is advised for small primary pneumothoraces, which are asymptomatic and simple aspiration is recommended as the first line treatment of all primary spontaneous pneumothoraces requiring intervention.¹⁰

However, in large secondary pneumothoraces, especially in patients over 50 years of age, simple aspiration is associated with a higher risk of failure and hence tube drainage is recommended as appropriate initial treatment. It should also be noted that in the most recent BTS guidelines¹⁰ a large pneumothorax is defined by the presence of a rim of air greater than 2 cm between the chest wall and lung margin. This is a significant change from the 1993 guidelines in which

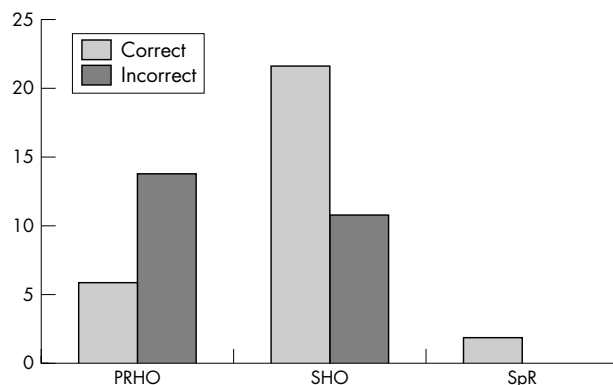


Figure 3 Bar graph showing whether diagram was correctly marked according to grade of doctor.

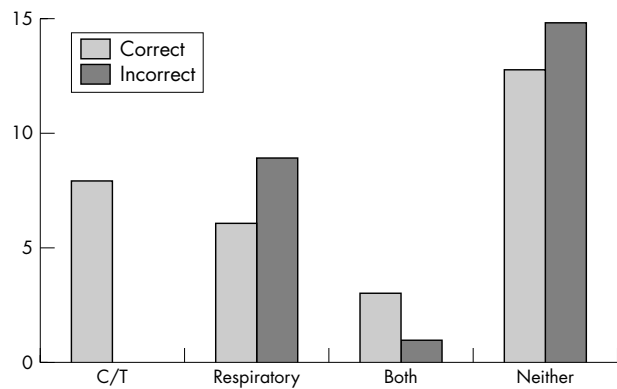


Figure 4 Bar graph showing whether experience of cardiothoracic surgery or respiratory medicine affected correct placement of ICD.

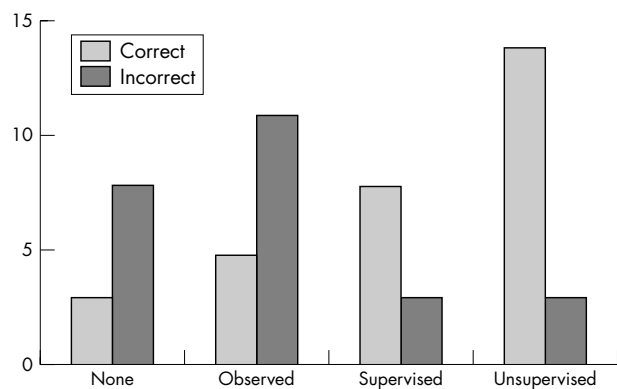


Figure 5 Bar graph showing effect of previous experience of ICD insertion on placement.

the size classification used tended to undersize the volume of pneumothorax.

Chest drain insertion is also the mainstay of treatment for the management of large traumatic pneumothoraces, and is certainly indicated for a tension pneumothorax, which has been initially decompressed. Any size of pneumothorax in a patient receiving positive pressure ventilation is also an indication for chest drain insertion.

Hence we agree with the BTS guidelines suggestion that doctors in most specialties should be capable of safe chest drain insertion.

This audit shows that 45% of junior doctors surveyed would have placed a chest drain outside the safe anatomical triangle recommended by the BTS, this is clearly an area for concern and suggests postgraduate education regarding chest drain insertion could be improved.

We believe postgraduate teaching programmes should make training on the insertion of intercostal drains a priority for all specialties.

One possible way of achieving this, at least on a local scale, is to ensure that a teaching session is devoted to the insertion of chest drains, including practical workshops using the clinical skills facility and led by cardiothoracic surgeons. After this is implemented into the postgraduate teaching curriculum, a subsequent re-audit would complete the audit cycle.

Authors' affiliations

J R Griffiths, N Roberts, Department of Cardiothoracic Surgery, Northern General Hospital, University Hospitals Sheffield, Sheffield, UK

Funding: none.

Conflicts of interest: none declared.

Correspondence to: Dr J Griffiths, Department of Accident and Emergency, Rotherham General Hospital, Moorgate Road, Rotherham, South Yorkshire S60 2UD, UK; jrgriffiths@doctors.org.uk

Submitted 8 June 2004

Accepted 1 September 2004

REFERENCES

- 1 **Abad C**, Padron A. Accidental perforation of the left ventricle with a chest drain tube. *Tex Heart Inst J* 2002;**29**:143.
- 2 **Kopec SE**, Conlan AA, Irwin RS. Perforation of the right ventricle: a complication of blind placement of a chest tube into the postpneumonectomy space. *Chest* 1998;**114**:1213–15.
- 3 **Hesselink DA**, Van Der Klooster JM, Bac EH, *et al.* Cardiac tamponade secondary to chest tube placement. *European Journal of Emergency Medicine* 2001;**8**:237–9.
- 4 **Yuncu G**, Aykanli D, Yaldiz S, *et al.* An unusual pulmonary perforation case after chest tube placement. *Acta Chir Hung* 1999;**38**:231–3.
- 5 **Rashid MA**, Wikstrom T, Ortenwall P. Mediastinal perforation and contralateral haemothorax by a chest tube. *Thorac Cardiovasc Surg* 1998;**46**:375–6.
- 6 **McConaghy PM**, Kennedy N. Tension pneumothorax due to intrapulmonary placement of intercostals chest drain. *Anaesth Intensive Care* 1995;**23**:496–8.
- 7 **Gerard PS**, Kaldawi E, Litani V, *et al.* Right-sided pneumothorax as a result of left sided chest tube. *Chest* 1993;**103**:1602–3.
- 8 **Tanaka S**, Hirohashi K, Uenishi T, *et al.* Surgical repair of a liver injury in a patient: accompanied with tricuspid regurgitation. *Hepatogastroenterology* 2003;**50**:523–5.
- 9 **Laws D**, Neville E, Duffy J. BTS guidelines for the insertion of a chest drain. *Thorax* 2003;**58**(suppl II):ii55–9.
- 10 **Henry M**, Arnold T, Harvey J. BTS guidelines for the management of spontaneous pneumothorax. *Thorax* 2003;**58**(suppl II):ii39–52.