

RENAL AND HEMATOLOGIC COMPLICATIONS OF ACUTE FALCIPARUM MALARIA IN VIETNAM*

CRAIG J. CANFIELD

Chief, Clinical Malaria Research Unit
Walter Reed Army Institute of Research
Washington, D.C.

MALARIA is a major medical problem of U.S. Army personnel in Vietnam. Although it ranks after diarrheal and common respiratory disease as a medical cause for admission to a treatment facility,† malaria requires longer hospitalization for treatment and convalescence and is probably the major cause of medical disability of the military population.

During the four-year interval from 1965 through 1968 there were more than 26,000 acute attacks of malaria in U. S. Army personnel in Vietnam (Table I). Naval, marine, and air force personnel are reported separately and thus are not included in these statistics. Most of the attacks were due to *Plasmodium falciparum*. The increase in malaria since 1965 reflects the increase in the number of men assigned to Vietnam and hence exposed to malaria. There have been 53 deaths in army personnel during this 4-year interval directly attributable to malaria and its complications. The major complications associated with a fatal outcome were acute renal insufficiency, cerebral malaria, and pulmonary edema. In individual cases, more than one of these complications were often present concurrently. It was therefore difficult to determine which was predominant. The decreased rate of mortality since 1965 was probably influenced by a change in antimalarial drug therapy. During the fall of 1965 the prevalence of resistance to chloroquine was not recognized and many patients were treated with chloroquine alone until resistance was documented. Then additional drugs were administered. Since 1966, combination therapy has been employed when the diagnosis of falciparum malaria was established—usually with quinine, pyrimethamine, and diaminodiphenylsulphone (DDS).

*Presented as part of a *Symposium on Malaria* sponsored by The Tropical Disease Center, St. Clare's Hospital, New York, N.Y. and The Merck Company Foundation, Rahway, N.J., held at the Center, May 17, 1969.

†Department of the Army, Office of the Surgeon General, Medical Statistics Agency.
This paper is Contribution No. 591 from the Army Research Program in Malaria.

TABLE I—MALARIA CASES IN U. S. ARMY PERSONNEL IN VIETNAM*

	<i>Number</i>	<i>Deaths</i>
1965	1,972	16
1966	6,655	14
1967	9,124	11
1968	8,616	12
Total	26,367	53

*Medical Statistics Agency, Office of The Surgeon General, U. S. Army Medical Corps.

TABLE II—ACUTE FALCIPARUM MALARIA IN VIETNAM:
MAJOR COMPLICATIONS

<i>Authors:</i>	<i>Sheehy and Reba¹</i>	<i>Blount²</i>
<i>Years</i>	<i>1965-1966</i>	<i>1966-1967</i>
<i>Total Cases</i>	<i>3,300</i>	<i>2,003</i>
Major complications:		
Renal	19	8
Cerebral	16	24
Pulmonary	3	0
Hematologic	*	21

*Not listed.

Many other patients developed complications but survived. No comprehensive documentation of complications is available for the U.S. Army. However several Army Medical Corps officers have accumulated data pertinent to the relative occurrence of complications in patients with malaria. Two separate series of patients are shown in Table II.^{1,2} The data from both of these reports were collected at the 85th Evacuation hospital at Qui Nhon during successive years of observation. The major complication recorded during the year 1965-1966 was acute renal insufficiency; 19 patients with this complication were seen. Several of the patients were evacuated to facilities for specialized treatment in the Philippines or Japan. However, during 1966-1967 only eight patients with renal complications were seen and none was evacuated for renal insufficiency. They had only mild azotemia and hem-

oglobinuria. The decreased incidence of renal insufficiency requiring dialysis has remained at a low level.

No comparable decrease in incidence has been reported for cerebral malaria. Criteria for diagnosis, however, are less rigid for cerebral malaria than for renal failure and it is therefore difficult to evaluate comparative changes in rates.

The other serious complication which has led to a fatal outcome is pulmonary edema. Patients with pulmonary edema have been observed who had no evidence of overhydration or cardiac decompensation.³ The condition is usually rapidly fatal and only an occasional patient has survived. Hematologic complications do not usually lead to death, but do prolong convalescence; they will be discussed later.

RENAL INSUFFICIENCY

Blackwater fever is a urinary manifestation of acute malaria. This term, however, refers simply to the passage of hemoglobin in the urine secondary to rapid or severe lysis of erythrocytes. The presence of blackwater fever in a patient with acute falciparum malaria does not imply an abnormality of renal function; rather it means that the plasma haptoglobin level has been exceeded and that free hemoglobin, or the products of its breakdown, are being excreted by the kidney. Blackwater fever is not necessarily associated with elevation of the blood urea nitrogen.

Oliguric renal failure is a functional abnormality—the decreased production of urine. Decreased production of urine does not necessarily accompany overt uremia in malaria; therefore we prefer the more simple term of acute renal insufficiency to describe the major renal complication of malaria.

Several features have been regularly observed in patients with acute renal insufficiency associated with falciparum malaria.^{1, 4, 5, 6}

Of these, intense parasitemia and severe hemolysis with hemoglobinuria are observed most frequently. In one series of 18 patients, nine had more than 10% of their red cells parasitized and 14 had severe hemolysis and hemoglobinuria.⁶ In these patients and others hemoglobinuria was present prior to the administration of quinine, and patients were subsequently treated with quinine without apparent increase in hemolysis.⁴⁻⁸

Dehydration is also commonly reported. Uncertainty of fluid-elec-

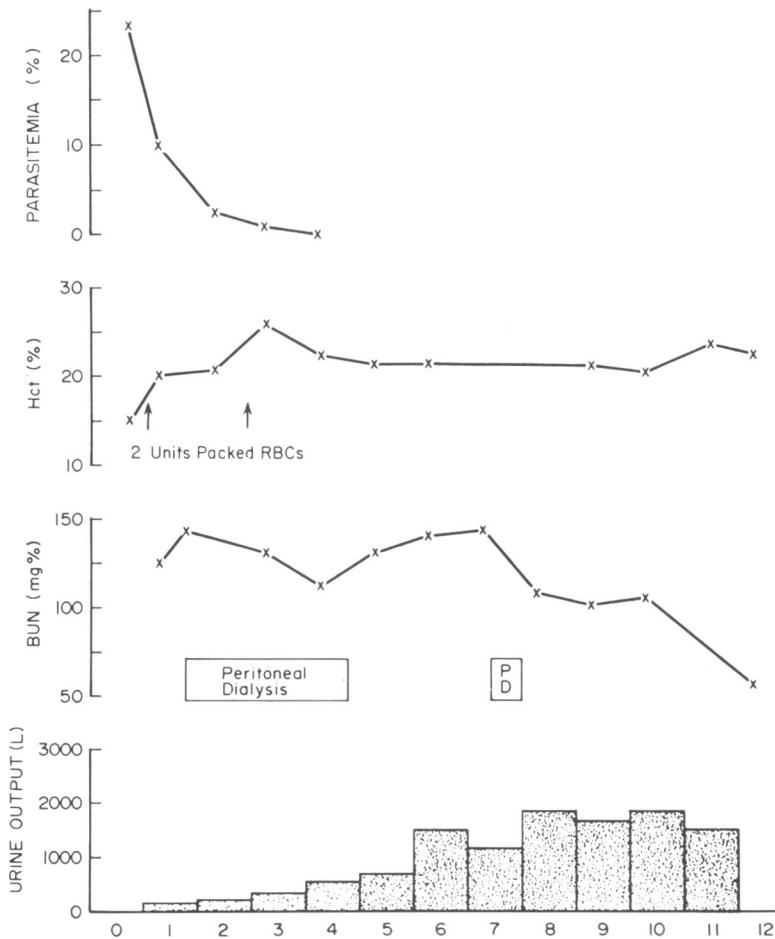


Fig. 1. The clinical course of a patient from Vietnam with acute falciparum malaria and renal insufficiency.

trolyte status makes this feature much more difficult to assess. Preinfection body weight is usually not known, urinary specific gravity is not increased as in simple dehydration, and hyponatremia or relative water excess is common even in uncomplicated malaria infections.⁹

The fourth feature, hypotension, is usually not recorded after the patient is hospitalized and placed in the supine position. However, orthostatic hypotension is common and may contribute to the pathogenesis of renal insufficiency.¹⁰

Finally, coagulation defects have been found in patients with recr-

descent falciparum malaria in the United States.¹¹ The degree of abnormality was usually related to the severity of the illness. In Vietnam, five patients with renal insufficiency due to malaria have been tested for consumptive coagulopathy and four had evidence of this process.⁶

The relation between these five features and the pathogenesis of acute renal insufficiency is unknown. Some of these features are known to be regularly present or essential for the production of acute renal failure in experimental animals. For example, in the methemoglobin ferrocyanide¹² and glycerol models¹³ of experimental acute renal failure, heme pigments in plasma and urine, dehydration, and sodium depletion are necessary for the regular production of renal failure. The relation between the numerous tubular casts in the experimental models and in patients with renal insufficiency secondary to malaria has not been defined.

Microscopic examination of percutaneous biopsy specimens from patients recovering from renal insufficiency associated with malaria showed minimal histologic alterations: hyaline and hemoglobin casts, tubular atrophy, and focal fibrosis.¹⁰ Iron-positive pigment was present in the epithelium of tubules and in interstitial cells.

Renal function studies have been performed in patients with varying degrees of functional impairment and azotemia. In nonazotemic patients (Thai civilian⁹ and American military¹⁴) renal function usually has been normal. Creatinine or urea clearances and PAH clearances were usually normal with normal filtration fractions.

Figure 1 illustrates some of the characteristics of the disease; it shows the clinical course of a 21-year-old patient who had acute falciparum malaria and renal failure. After a five-day illness, the patient was admitted to an army hospital in Vietnam. He had intense parasitemia (23 per cent) and severe hemolysis (hematocrit of 15 per cent, gross hemoglobinemia, and hemoglobinuria). He also had hypovolemia and hyponatremia, and his initial supine blood pressure was 92/74 mm. Hg. He had azotemia and oliguria. No tests for consumptive coagulopathy were performed.

The patient was treated with quinine, sulforthodimethoxine (Fanasil), and pyrimethamine. Subsequently he was given peritoneal dialysis for renal insufficiency. During the acute stages of the disease there was only a minimal decrease in the blood urea nitrogen with almost

three days of continuous dialysis. A subsequent dialysis during convalescence was followed by a prompt decrease in the blood urea nitrogen.

The initial slow response could have been due to decreased efficiency of dialysis or to an increase in the patient's catabolic rate. A markedly increased catabolic rate is suggested by the increased urinary excretion of urea nitrogen during the acute illness.¹⁰ Special studies in this and other patients have also shown decreased efficiency of dialysis which returns to normal as parasitemia declines.^{5, 8}

Quinine given intravenously in reduced amounts is recommended for patients from Vietnam who have malaria and acute renal insufficiency. The presence of hemoglobinuria is not a contraindication. The patient described above received 2.1 gm. of quinine during his first two days in the hospital. Quinine administered intravenously during a 1 hour period produced peak concentrations greater than 15 mg./l. but did not produce significant electrocardiographic changes. We now recommend that patients with falciparum malaria and renal insufficiency be treated with quinine (600 gm. per 24 hours) by constant infusion for several days until parasites have been eradicated and oral medication is tolerated. The patient should also be given pyrimethamine to decrease the possibility of relapse.

In the case that has just been described the renal insufficiency was managed with peritoneal dialysis. This treatment is satisfactory for most patients if used early in the course of the disease. Many other patients in Vietnam have been treated with hemodialysis.^{4, 6} Prior to deployment of the 629th Renal Unit to Vietnam in mid 1966, patients with renal insufficiency were taken out of the country. There were four deaths during evacuation or shortly thereafter. Since a renal unit was established in Saigon, earlier treatment has been possible and only one death has occurred during evacuation.

Earlier recognition of impending renal insufficiency in patients with severe infections and hemoglobinuria at the evacuation or field hospital has also been important. Patients so identified are treated with osmotic diuresis,² which has altered the progression of renal insufficiency in other conditions.¹⁵

In summary, acute renal insufficiency in patients from Vietnam who have falciparum malaria is generally associated with severe infections, severe hemolysis, derangements in electrolyte balance, hypoten-

sion, and consumptive coagulopathy. Prompt treatment with reduced amounts of quinine given intravenously and osmotic diuresis or dialysis has resulted in improved survival rates.

HEMATOLOGIC COMPLICATIONS

Hematologic complications of acute falciparum malaria include consumptive coagulopathy, severe or prolonged anemia, and leukopenia.

Coagulation studies, including specific factor assays, were performed on 31 American soldiers who had recurrences of acute falciparum malaria in this country.¹¹ All patients had abnormal prothrombin times or partial thromboplastin times, and 22 of the 31 had platelet counts of less than 150,000. The factor assays showed that V, VII, VIII, and X were depleted. Fibrinogen concentrations less than 200 mg./100 ml. were found in only 10 patients although the serial thrombin time was abnormal in all but two.

As noted above, the degree of abnormality of these coagulation studies is directly related to the severity of illness in each patient. Subsequent studies in human volunteers infected with falciparum malaria treated when symptoms first developed showed only mild thrombocytopenia.¹⁶ Treatment with heparin of patients seriously ill with malaria who had abnormal coagulation produced clinical improvement and partial correction of the coagulopathy within 12 to 24 hours. Concomitant antimalarial drug therapy confounds the role of anticoagulant therapy. Thrombi in various organs of moribund malaria patients suggest that there is a relation between consumptive coagulopathy and the pathophysiology of the disease. The depletion of coagulation factors may be an indication of thrombosis and correction with heparin should probably be attempted.

Approximately 20% of patients with acute falciparum malaria develop significant anemia, with hematocrit levels of less than 35%. The anemia may persist and may require prolonged convalescence.

The degree of anemia is usually related to the severity of the infection. However, patients may have mild infections and severe anemia; some in this group have erythrocytes deficient in glucose-6-phosphate dehydrogenase. Demonstration of this enzyme deficiency is complicated by the preferential lysis of deficient cells in infection and by hemolysis caused by antimalarial drugs. Thus, during the period of

TABLE III.—ACUTE FALCIPARUM MALARIA, FERROKINETIC STUDIES

<i>Patient</i>	<i>Serum iron (μg./100 ml.)</i>	<i>Plasma iron clearance (hr.)</i>	<i>Plasma iron Transport rate (mg./day/70 kg. man)</i>
1	98.0	1.42	39.9
2	90.0	1.65	29.1
3	35.4	0.33	69.8
4	38.0	0.68	31.9
5	37.7	0.38	47.0
6	30.8	0.55	26.1
7	35.0	0.56	42.5
8	57.0	0.90	42.5
9	72.0	0.63	70.1
10	25.1	0.44	29.6
11	41.1	0.95	30.7
12	30.0	0.44	41.1
13	19.4	0.47	22.6
Mean	46.9	0.72	40.2
Normal range	70-160	1-2	20-42

severe anemia and before a new population of cells has been generated, screening tests may not reveal the defect. Also, demonstration of other red cell abnormalities that might be associated with hemolysis, such as deficiency of glutathione reductase, is impractical in Vietnam.

A study of 13 patients with acute falciparum malaria treated with quinine, pyrimethamine and Fansil showed a mean decrease of 10 per cent in the hematocrit during the first two weeks of illness. A significant reticulocyte response did not occur until the 10th day of treatment.

Ferrokinetic studies were performed in these patients. Serum iron concentrations, plasma iron clearance times, and iron turnover data are shown in Table III. The data were obtained prior to treatment and show a normal ferrokinetic response to a demand for red cell formation. Serum iron concentrations were generally decreased. There was rapid clearance of the labeled iron, and calculated turnover rates were at the upper limit of normal. Subsequent red cell incorporation studies during antimalarial therapy are shown in Figure 2. Seven of the 13 patients had abnormally decreased incorporation of Fe^{59} into red blood

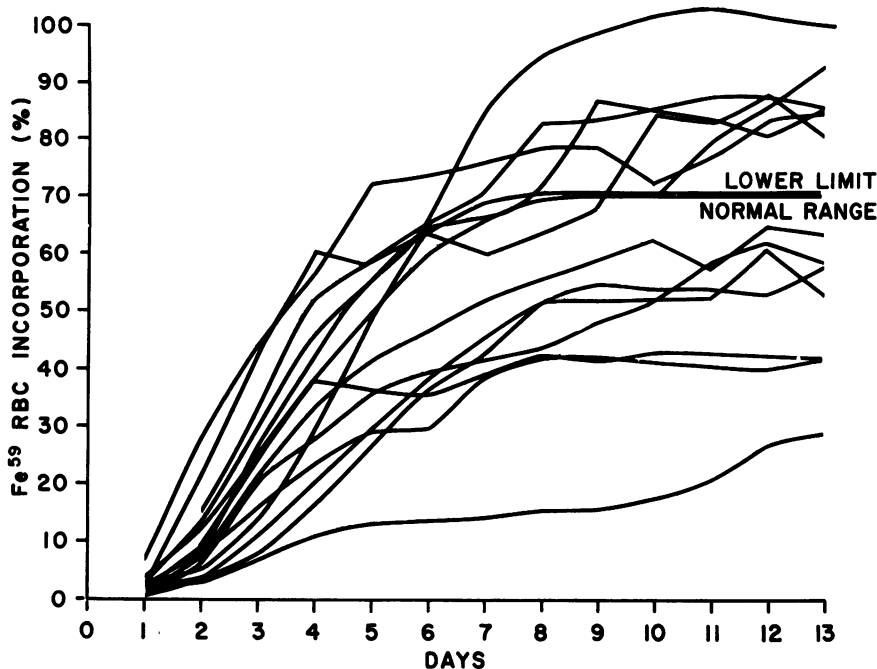


Fig. 2. Red blood cell incorporation of Fe^{59} in 13 patients from Vietnam with acute falciparum malaria during treatment with quinine, pyrimethamine, and sulfathodimethoxine.

cells. This abnormality could be due either to ineffective erythropoiesis or to preferential hemolysis of young cells. Preferential lysis of older cells would have produced a normal initial incorporation with a subsequent decrease. Random hemolysis would not produce the observed degree of abnormality without a marked decrease in hematocrit.

Further studies of anemia were designed to determine if the ferrokinetic abnormality might be due to the antifolate actions of pyrimethamine on the maturation of red blood cells.¹⁷ Thirty-six patients were studied with 9 in each of 4 groups. All patients received quinine and DDS. The patients in groups 1 and 2 received pyrimethamine, 50 mg. daily for three days, and those in groups 1 and 3 received 6 mg. of folic acid every 12 hours intramuscularly for 12 days. The study was double blind, placebos being administered when appropriate. Fe^{59} was given on the fourth day of study.

There was little difference in the average hematocrit decrease or

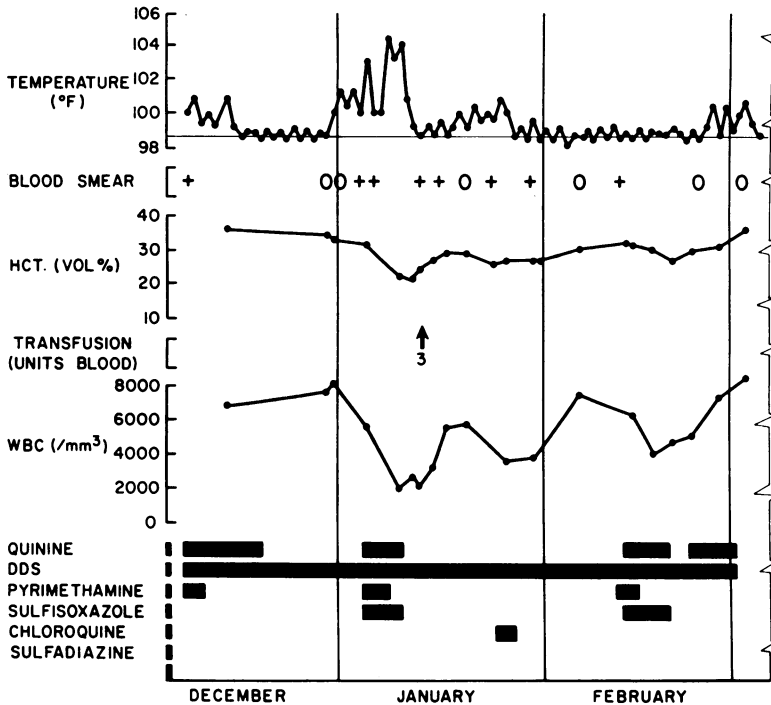


Fig. 3. The prolonged clinical course of a patient from Vietnam who had recurring falciparum malaria despite a variety of therapeutic regimens, finally treated with trimethoprim.

reticulocyte response in the four groups. However, the rate of clearance of parasites was more rapid in the two groups that received pyrimethamine regardless of treatment with folic acid.

The data obtained from the ferrokinetic studies show that plasma-iron transport rates were generally elevated but there was no significant difference between the treated groups. The plasma-iron transport rates were even greater than in the previous study and inversely proportional to the hematocrit on the day of the study. Although red blood cell incorporation was minimally decreased from normal in one third of the patients, the differences were equally distributed between the various treatment groups. The degree of abnormality was much less than in the previous study and suggested an improvement in the incorporation of iron after the fourth day of treatment.

We interpret the data as follows: during treatment for acute falciparum malaria the patients have an appropriate initial response to hemolysis, quantities of free iron are removed avidly from the plasma.

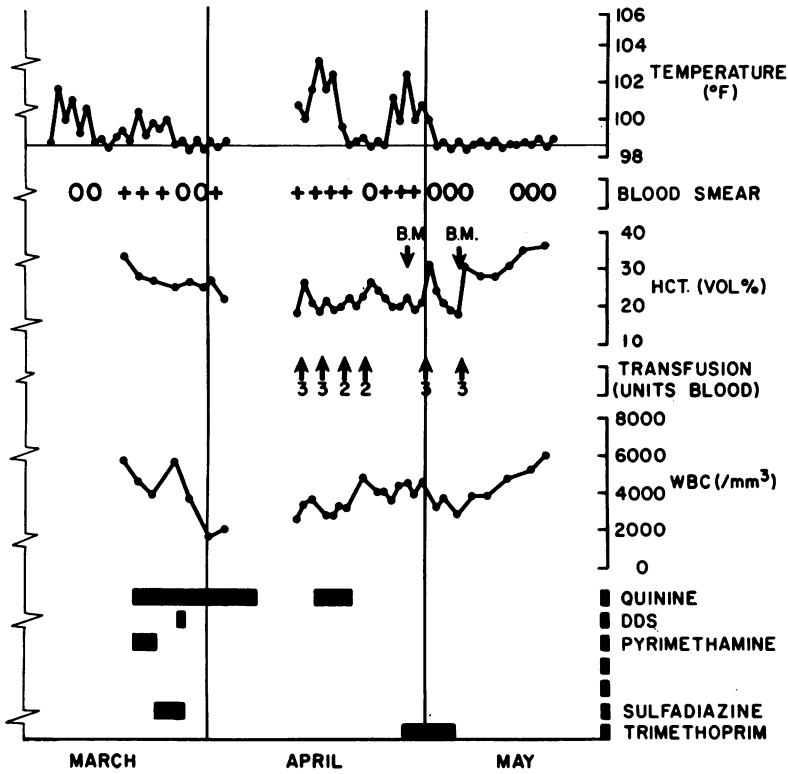


Fig. 3. Continued.

Formation or release of newly formed erythrocytes is impaired until the disease is controlled. In the usual patient who has only mild anemia pyrimethamine probably does not contribute significantly to this delayed erythrokinetic response.

However, pyrimethamine may inhibit erythropoiesis in the patient who has severe hemolysis and in whom the demand for red blood cell production is greatest. Study of the most anemic patient in each of the four different treatment regimens in the study described above showed that the patients who received pyrimethamine had a delay of three to four days in reticulocyte response when compared to the patients who did not receive pyrimethamine. The delay in reticulocytosis was not completely corrected by folic acid. The erythropoietic response in the patients who received folic acid was earlier than expected but the early response could have been due to the greater stimulus for

the production of red cells from the severe hemolysis.

These observations suggest a dependent relation between the administration of pyrimethamine and a delayed recovery from anemia in those patients who have had moderately severe hemolysis. Further study may show whether the concurrent administration of folic acid has a significant ameliorating effect on the anemia of patients who have severe hemolysis. Folic acid did not interfere with the therapeutic efficacy of pyrimethamine. Response to treatment was the same in patients treated with and without folic acid. During the 30-day period of observation, there were no clinical or parasitologic recurrences in any of the patients studied.

I should like to illustrate two additional hematologic complications of malaria and their treatment by describing a case of recurrent falciparum malaria that lasted 6 months.

Case report. The patient was a 25-year-old white male who entered the Central Highlands of Vietnam in October 1966 (Figure 3). He received weekly Chloroquin-Primaquin tablets while there. One month after his arrival he developed fever, chills, headache, and muscular aches. A diagnosis of falciparum malaria was made by peripheral blood smear and the patient was hospitalized in early December. His initial treatment consisted of quinine 600 mg. every eight hours; pyrimethamine 25 mg. three times a day; and diaminodiphenylsulphone (DDS) 25 mg. daily. The pyrimethamine was given for three days and the quinine for three weeks. Despite this therapy and continued DDS, the patient again developed fever, and parasitemia in January, 1967. Between that recrudescence and his transfer to the Walter Reed Hospital, Washington D.C., the patient continued to have intermittent fever and parasitemia despite a variety of antimalarial programs. On one occasion therapy was interrupted because of pancytopenia, thought to be drug-induced. He was admitted to Walter Reed General Hospital on April 13, 1967. Physical examination at the time of admission showed a young Caucasian male who was febrile, pale, and icteric. The spleen was palpable 2 cm. below the left costal margin. A blood smear showed *P. falciparum*. The hematocrit was 18 per cent; white count 2,200 cells/mm.³; platelet count 100,000/mm.³; and the reticulocyte count was 7.8%. The serum bilirubin was 2.8 mg./100 ml. direct reacting fraction. Serum urea nitrogen was 35 mg./100 ml. Assay for red blood cell G-6-PD was normal. Urine urobilinogen was positive

in 1:80 dilution. There was no significant urinary sediment. The patient had orthostatic hypotension, which improved after he received three units of whole blood. Two days after admission he developed a severe headache and his temperature increased to 103 degrees. He was given 600 mg. of quinine every eight hours; three units of blood were administered because of severe anemia. During the quinine therapy, the WBC count remained between 3,000 and 3,800 cells/mm.³ and the platelet count was 80 to 113,000/mm.³ Four additional units of blood were given because of continued hemolysis. On the fifth day of therapy the patient was afebrile and quinine was discontinued. The BUN had decreased to 13 mg./100 ml. Malaria smears were negative for two days, but again became positive on April 25 and the patient again became afebrile. A bone marrow examination obtained on April 28 showed erythrocytic hyperplasia with some dyspoiesis; granulocytic hypoplasia and malaria pigment were also present. Because of continued hemolysis and the lack of satisfactory response to previously administered antimalarial medication, trimethoprim 1,500 mg. daily was started on April 28 and was continued for seven days. After the fourth day of therapy, blood smears were negative for parasites and the patient was afebrile. During therapy the WBC count remained between 2,800 and 3,900 cells/mm.³ and the platelet count varied between 90,000 and 163,000/mm.³ Reticulocytes decreased from 13 to 1.5%. After five days of trimethoprim therapy, the bone marrow showed hypoplasia and megaloblastosis. After cessation of therapy, there was continued clinical improvement and all blood elements returned to normal.

Leukopenia occurred on four occasions in this patient and coincided with recurrences of the infection and antimalarial therapy. Such a response is not usual. Decreased numbers of white cells in the peripheral blood is a common initial finding. However, with effective treatment, the white cell count increases and it is usually greater than 4,000 cells/mm.³ by the fourth day of therapy. This patient had a progressive decline in the count of white blood cells with therapy on at least three occasions. The bone marrow showed granulocytic hypoplasia. Other patients under similar circumstances have shown a maturation arrest of the myelocytic series. These findings may indicate an idiosyncratic reaction to one of the drugs employed.

This patient also had a severe hemolytic process while being treated with quinine for the last recurrence. Parasite density counts were low

and did not account for the severe hemolysis. No evidence of a deficiency of glucose-6-phosphate dehydrogenase was found. The Coombs test was negative. However incubation of the patient's sera and normal red cells with quinine produced agglutination of the red blood cells (not observed with control sera). We therefore suspected that hemolysis in this patient was related to the administration of quinine and we treated him successfully with trimethoprim. The severe hemolytic episode occurred after prior courses of quinine not associated with comparable hemolysis. Quinine-associated hemolysis in patients from Vietnam had been seen previously after repeated courses of quinine. They have also shown a positive Coombs test.¹⁸ The absence of a positive Coombs test in this patient suggests an unusual antigen-antibody reaction.

In summary, hematologic complications of malaria or malaria therapy include decreased circulating platelets, erythrocytes, and leukocytes. Thrombocytopenia is seen in association with consumptive coagulopathy or rarely in association with drug therapy. Severe hemolysis, although generally related to intense parasitemia, may be associated with specific red cell enzyme defects or with the administration of quinine. The usual patient with hemolysis secondary to malaria infections has a delayed erythropoietic response until parasitemia has been eradicated. Pyrimethamine probably does not contribute to the delayed response unless anemia is severe. Leukopenia is common during the first few days of an acute attack of malaria, but the count of white blood cells approaches normal with therapy. A decrease in circulating leukocytes to levels less than 3000/mm.³ during therapy may represent an idiosyncratic reaction.

REFERENCES

1. Sheehy, T. W., and Reba, R. C. Complications of falciparum malaria and their treatment. *Ann. Intern. Med.* 66: 807-09, 1967.
2. Blount, R. E., Jr. Acute falciparum malaria: Field experience with quinine/pyrimethamine combined therapy. *Ann. Intern. Med.* 70:142-47, 1969.
3. Brooks, M. H., Kiel, F. W. Sheehy, T. W. and Barry, K. G. Acute pulmonary edema in falciparum malaria: A clinicopathological correlation. *New Eng. J. Med.* 279:732-37, 1968.
4. Yamauchi, H. and Hanchett, J. E. Acute Renal Failure Complicating South East Asia Falciparum Malaria (abstract). Third International Congress of Nephrology, Sept. 25-30, 1966, Washington, D. C.
5. Canfield, C. J., Miller, L. H., Bartelloni, P. J. Eichler, P. and Barry, K. G. Acute renal failure in *Plasmodium falciparum* malaria. *Arch. Intern. Med.* 122:199-203, 1968.

6. Stone, W. J. and Knepshild, J. Acute renal insufficiency in falciparum malaria. In preparation.
7. Rosen, S. Hano, J. E., Inman, M. M., Gilliland, P. F. and Barry, K. G., The kidney in blackwater fever. *Amer. J. Clin. Path.* 49:358-70, 1968.
8. Donadio, J. V., Jr., and Whelton, A. Quinine therapy and peritoneal dialysis in acute renal failure complicating malarial haemoglobinuria. *Lancet* 1: 375-79, 1968.
9. Miller, L. H., Makaranond, P., Sitprija, V., Suebsanguan, C. and Canfield, C. J. Hyponatremia in malaria. *Ann. Trop. Med. Parasit.* 61:265-79, 1967.
10. Brooks, M. H., Malloy, J. P., Barteloni, P. J., Tigertt, W. D., Sheehy, T. W. and Barry, K. G. Pathophysiology of acute falciparum malaria. *Amer. J. Med.* 43:735-50, 1967.
11. Dennis, L. H., Eichelberger, J. W., Inman, M. and Conrad, M. E. Depletion of coagulation factors in drug-resistant Plasmodium falciparum malaria. *Blood* 27:713-21, 1967.
12. Rosen, S. Mailloux, L. U., Lawson, N. J. and Teschan, P. E. Acute renal failure in the rat. *Lab. Invest.* 18:438-43, 1968.
13. Oken, D. E., Arce, M. L. and Wilson, D. R. Glycerol-induced hemoglobinuric acute renal failure in the rat. I. Micro-puncture study of the development of oliguria. *J. Clin. Invest.* 45:724, 1966.
14. Cirksena, W. J., McNeil, J. and Gilliland, P. F. Personal communication.
15. Barry, K. G. and Crosby, W. H., The prevention and treatment of renal failure following transfusion reactions. *Transfusion* 3:34-36, 1963.
16. Conrad, M. E. Pathophysiology of malaria. *Ann. Intern. Med.* 70:134-41, 1969.
17. Canfield, C., Keller, H. and Cirksena, W. Erythrokinetics during treatment of acute falciparum malaria. In preparation.
18. Adner, M. M., Alstatt, L. B. and Conrad, M. E. Coombs'-positive hemolytic disease in malaria. *Ann. Intern. Med.* 68:33-38, 1968.