

LETTERS

Remitting distal lower extremity swelling with pitting oedema in acute sarcoidosis

Remitting distal extremity swelling with pitting oedema is a clinical manifestation that may be observed in different rheumatic conditions such as RS₃PE syndrome,¹ polymyalgia rheumatica,² late onset undifferentiated spondyloarthropathy,³ ankylosing spondylitis,⁴ psoriatic arthritis,⁵ and more rarely in other rheumatic disease.⁵ In RS₃PE the swell-

ing with pitting oedema predominantly involves the upper extremities symmetrically.¹ This clinical finding may occur unilaterally in polymyalgia rheumatica and upper and lower limbs may be equally affected,² whereas in seronegative spondyloarthropathies it has been described more frequently in lower extremities with asymmetric involvement.^{3,4}

The oedema is characterised by a rapid response to small doses of corticosteroids.

The pathogenesis of swelling with pitting oedema has not been completely defined, but the distribution along the tenosynovial membranes suggests that it probably results from tenosynovitis.⁵

Sarcoidosis is a systemic granulomatous disease that is associated with rheumatic manifestations in 6% to 39% of patients.⁶ The most common form of arthritis occurs acutely, involves preferentially the ankles, and

Table 1 Demographic, clinical, and magnetic resonance imaging features of the five patients with acute sarcoidosis

	Patient 1	Patient 2	Patient 3	Patient 4	Patient 5
Sex/age at disease onset (y)	M/32	F/48	F/34	M/31	F/28
Pitting oedema of the dorsum of the feet	present	present	present	present	present
Systemic symptoms	low grade fever, fatigue	absent	low grade fever	low grade fever, fatigue	low grade fever, fatigue
Erythema nodosum	absent	present	absent	absent	present
ESR/CRP*	42/35	65/52	76/56	61/45	71/48
SACE concentration†	58	65	70	57	62
Bilateral hilar adenopathy (x rays)	present	present	present	present	present
Gallium scan	increased bilateral hilar uptake	not performed	not performed	not performed	not performed
Bronchoalveolar lavage	not performed	not performed	CD4+ lymphocytic alveolitis	CD4+ lymphocytic alveolitis	CD4+ lymphocytic alveolitis
Transbronchial biopsy	not performed	not performed	not performed	non-caseating granulomas	non-caseating granulomas
Foot and ankle MRI findings	not performed	mild joint synovitis, severe tenosynovitis of all extensor tendons	mild joint synovitis, severe tenosynovitis of all extensor tendons	mild joint synovitis, severe tenosynovitis of all extensor tendons	not performed

* ESR= erythrocyte sedimentation rate (mm 1st hour), CRP= C reactive protein (normal value: < 5 mg/l);

† SACE= serum angiotensin converting enzyme (normal value: 18-55 U/l).

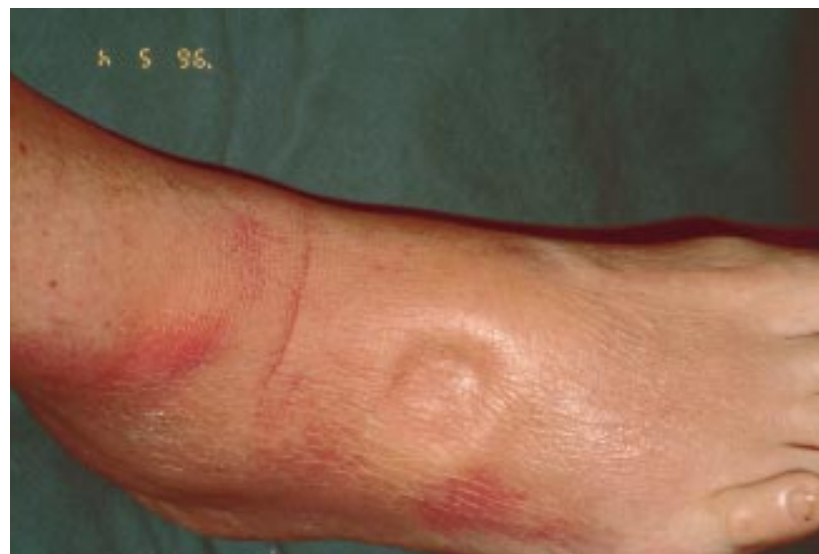

Figure 1 Patient 2. Soft tissue swelling of malleolar and perimalleolar areas with pitting oedema of the dorsum of the right foot. The distribution of the oedema follows the course of peroneal, tibialis, and extensor tendons of the foot.

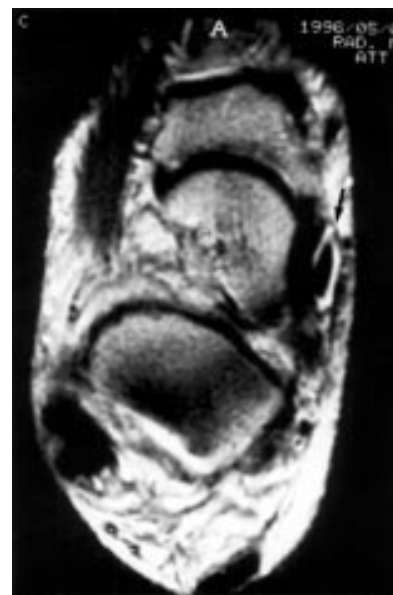


Figure 2 Patient 4. Right ankle axial magnetic resonance imaging (SE T2weighted): pronounced tenosynovitis of posterior tibial tendon (arrow). Subcutaneous oedema and mild joint synovitis with scanty intrarticular fluid may be observed.

it is often the initial feature of sarcoidosis.⁶ Frequently, erythema nodosum and bilateral hilar adenopathy are associated with arthritis (Lofgren's syndrome). Erythema nodosum may also be absent.⁷

Periarticular oedema and tenosynovitis accompanying arthritis have been emphasised in some reports.^{6,8-10} However, remitting distal lower extremity swelling with pitting oedema of the dorsa of the feet in patients with acute sarcoidosis has not been mentioned in previous reports.

We describe five patients with acute sarcoidosis who presented as first manifestation of the disease an impressive distal lower extremity swelling with pitting oedema of the dorsum of both feet.

We made a retrospective review of all patients with acute sarcoidosis seen in two Italian Divisions of Internal Medicine (Prato and Reggio Emilia Hospitals) over a two year period. The diagnosis and presenting clinical features were assessed by clinical examination and review of the patient's chart.

Remitting distal extremity swelling with pitting oedema was the presenting manifestation in five (29%) of 17 consecutive patients with acute sarcoidosis seen between January 1995 and December 1996.

Table 1 summarises the demographic and clinical characteristics of the five patients. All patients presented with pain and swelling of both ankles and feet.

The swelling and pitting oedema were most prominent over the dorsum of both feet and ankles, malleolar and perimalleolar areas were also involved (fig 1). In perimalleolar areas the oedema followed the distribution of tibialis and peroneal tendons. It is possible that pitting oedema in our series may have been present in some other cases, but less pronounced and not considered by the examiner.

Swelling and oedema completely resolved after a few days of corticosteroid treatment.

To investigate the structures responsible for the swelling and oedema we examined three patients by magnetic resonance imaging.

As reported by Olivieri *et al*⁵ in other rheumatic conditions associated with distal extremity swelling with pitting oedema, magnetic resonance imaging confirmed in three patients the clinical impression that a severe tenosynovitis of peroneal, tibialis, and extensor tendons was the main lesion responsible for the oedema in the subcutaneous and peritendinous ankle and foot soft tissues. A slight joint synovitis with scanty intrarticular fluid was present (fig 2).

Similar findings were reported by Kellner *et al*⁶ by using ultrasound to study ankle swelling in acute sarcoidosis. Sonographic features of tenosynovitis were detected in eight of 24 patients, only in two cases a concomitant arthritis was found.

In conclusion our cases confirm that a tenosynovitis is part of the spectrum of articular manifestations of sarcoidosis. Moreover, our clinical series suggest that distal extremity swelling with pitting oedema over the dorsum of feet may be the presenting feature of acute sarcoidosis. Consequently the disease may be included among the rheumatic disorders associated with remitting distal extremity swelling and pitting oedema.

FABRIZIO CANTINI
LAURA NICCOLI

2^a Divisione di Medicina, Ospedale di Prato

IGNAZIO OLIVIERI
Servizio di Reumatologia, Policlinico S
Orsola-Malpighi, Bologna

LIBERO BAROZZI
PIETRO PAVLICA
Servizio di Radiodiagnostica, Policlinico S
Orsola-Malpighi, Bologna

ALESSANDRO BOZZA
Istituto Pratese di Radiodiagnostica, Prato

PIER LUIGI MACCHIONI
ANGELA PADULA
CARLO SALVARANI
2^a Divisione di Medicina, Arcispedale S Maria
Nuova, Reggio Emilia, Italy

Correspondence to: Dr F Cantini, 2^a Divisione di Medicina, Ospedale di Prato, Piazza Ospedale, 1-50047, Prato, Italy.

- McCarty DJ, O'Duffy JD, Pearson L, Hunter JB. Remitting seronegative symmetrical synovitis with pitting edema. RS, PE syndrome. *JAMA* 1985;254:2763-7.
- Salvarani C, Gabriel S, Hunder GG. Distal extremity swelling with pitting edema in polymyalgia rheumatica. Report of nineteen cases. *Arthritis Rheum* 1996;39:73-80.
- Olivieri I, Padula A, Piarro A, Favaro L, Oranges GS, Ferri S. Late onset undifferentiated seronegative spondylarthropathy. *J Rheumatol* 1995;22:899-903.
- Olivieri I, Padula A, Favaro L, Piarro A, Oranges GS, Ferri S. Dactylitis with pitting oedema of the hand in longstanding ankylosing spondylitis. *Clin Rheumatol* 1995;14:701-4.
- Olivieri I, Salvarani C, Cantini F. Remitting distal extremity swelling with pitting edema: a distinct syndrome or a clinical feature of different inflammatory rheumatic diseases? *J Rheumatol* 1997;24:249-52.
- Spilberg I, Siltzbach LE, McEwen C. The arthritis of sarcoidosis. *Arthritis Rheum* 1969;12:126-37.
- Perruquet JL, Harrington TM, Davis DE, Viozzi FJ. Sarcoid arthritis in a North American Caucasian population. *J Rheumatol* 1984;11:521-5.
- Caplan HI, Katz WA, Rubenstein M. Periarticular inflammation, bilateral hilar adenopathy, and sarcoid reaction. *Arthritis Rheum* 1970;13:101-10.
- Kellner H, Spathling S, Herzer P. Ultrasound findings in Lofgren's syndrome: is ankle swelling caused by arthritis, tenosynovitis or periartthritis. *J Rheumatol* 1992;19:38-41.
- Mana J, Gomez-Vaquero C, Salazar A, Valverde J, Juanola X, Pujol R. Periarticular ankle sarcoidosis: a variant of Lofgren's syndrome. *J Rheumatol* 1996;23:874-7.

Further evidence that low androgen values are a cause of rheumatoid arthritis: the response of rheumatoid arthritis to seriously stressful life events

It is well established that androgen concentrations are low in patients with rheumatoid arthritis (RA).¹ There are three possibilities: (1) Low androgen values are a consequence of RA. (2) Low androgen values are a consequence of its treatment. (3) Low androgen values are a partial cause of RA.

Undoubtedly the facts are complex, but in what I take to be an excess of methodological correctness, Masi *et al*¹ write: 'The available evidence reviewed does not allow definitive response to the question of a primary versus secondary role of sex hormone perturbations in RA'. I shall treat the three above possibilities in turn to suggest that (in contrast with Masi *et al*) a definitive response is possible.

(1) Low androgen concentrations in men are a consequence of many forms of illness² including severe inflammatory disease,³ so it may be accepted that this is one cause of the low androgen values.

(2) Acute and chronic administration of exogenous glucocorticosteroids can lower testosterone and DHAS. (See Masi *et al* for reference). So this may be another cause of low androgens in patients so treated.

(3) However there are very substantial grounds for suspecting that low androgens are a partial cause of RA too: (a) RA is more common in women than in men. (b) RA is associated with HLA B 15,^{4,5} which in turn is associated with low androgen values in men.⁶ Hence the suggestion that low testosterone is a genetically determined precursor, rather than a consequence of RA or its treatment. A similar argument may be deployed in regard to HLA DR 4 in women.⁷ (c) RA abates in about 75% of cases during pregnancy. (See Masi *et al* for references). Some weeks to months after delivery, the disease flares in more than 90% of these patients. During pregnancy, increasing quantities of androgens are produced by the corpus luteum, placenta, and fetal testes and adrenal glands.⁸ According to this hypothesis, amelioration during pregnancy is caused by these hormones, and the subsequent relapse is caused by their withdrawal. (d) Controls have been shown to have higher testosterone concentrations than patients in case-control studies: these data are consistent with any of the three propositions above. But the point has been established in a longitudinal study too: women who later developed RA had significantly lower DHAS values than controls who did not later develop the disease.⁹ Such a finding, if it were confirmed would not be adequately explained by propositions 1 or 2. (e) Direct administration of testosterone to male¹⁰ and postmenopausal female patients¹¹ has resulted in improvement. It would be interesting to see the effect of such treatment for premenopausal patients.

In the attempt to further inculcate low testosterone values in the aetiology of RA, I wish to draw attention to further confirmatory evidence in the shape of two dramatic cases reported in the behavioural literature.

The first is that of an elderly female RA patient who survived a lightning strike during

a thunderstorm. Her walking stick was allegedly charred and her symptoms almost totally abated,¹² though they subsequently returned before her death. I can vouch for the authenticity of the substance of this story: the lady was my aunt and she certainly suffered a shock (though not necessarily an electrical one). She regarded her experience as the occasion of a miracle.

The second case was that of a 53 year old female RA patient who suffered the unexpected deaths of her son and husband.¹³ Her disease went into temporary remission within a week of the deaths.

Stress in both sexes leads to increased pituitary secretion of adrenocorticotrophic hormone. In men this causes reduced gonadal steroid production.³ In women, adrenocorticotrophic hormone activation of the adrenal cortex is suspected of leading to increased overall androgens.¹⁴ (In women, the main source of androgens is the adrenal gland whereas in men it is the gonads). So I suggest that these two cases illustrate the beneficial effects of androgens on RA.

There are two ways in which this could be tested: (1) If I am right, such seriously stressful life events would have an exacerbating effect on male patients. (2) If I am right, the beneficial effects of pregnancy should be more evident in women carrying male fetuses (because male fetuses secrete more androgens than female fetuses).

WILLIAM H JAMES
The Galton Laboratory, University College
London, Wolfson House, 4 Stephenson Way
London NW1 2HE

- Masi AT, Da Silva JA, Cutolo M. Perturbations of hypothalamic-pituitary-gonadal (HPG) axis and adrenal androgen (AA) functions in rheumatoid arthritis. *Baillière's Clin Rheumatol* 1996;10:295-332.
- Semple CG. Hormonal changes in non-endocrine disease. *BMJ* 1986;293:1049-52.
- Semple CG, Gray CE, Beastall GH. Adrenal androgens and illness. *Acta Endocrinol* 1987;16:155-60.
- Ollier W, Venables PJW, Mumford PA, Maini R, Awad J, Jaraquemada D, *et al*. HLA antigen association with extra articular rheumatoid arthritis. *Tissue Antigens* 1984;24:279-91.
- Jaraquemada D, Ollier W, Awad J, Young A, Silman A, Roitt IM, *et al*. HLA and rheumatoid arthritis: a combined analysis of 440 patients. *Ann Rheum Dis* 1986;45:627-36.
- James WH. Rheumatoid arthritis, the contraceptive pill, and androgens. *Ann Rheum Dis* 1993;52:470-4.
- Deighton CM, Watson M, Walker DJ. Rheumatoid arthritis, sex ratios, HLA-DR and testosterone. *Ann Rheum Dis* 1993;52:244.
- Buster JE, Simon JA. Placental hormones, hormonal preparation for and control of parturition and hormonal diagnostic of pregnancy. In: De Groot LJ, Besser GM, Cahill GF, *et al*, eds. *Endocrinology*. Philadelphia: Saunders, 1989:2043-73.
- Masi AT, Feigenbaum SL, Chatterton RT. Hormonal and pregnancy relationships to rheumatoid arthritis: convergent effects with immunologic and microvascular systems. *Semin Arthritis Rheum* 1995;25:1-27.
- Cutolo M, Balleri E, Giusti M, Intra E, Accardo S. Androgen replacement therapy in male patients with rheumatoid arthritis. *Arthritis Rheum* 1991;34:1-5.
- Booij A, Biewenza-Booij CM, Cornelis C, Jacobs JWJ, Bijlsma JWJ. Androgen as adjuvant treatment in postmenopausal female patients with rheumatoid arthritis. *Ann Rheum Dis* 1996;55:811-5.
- James WH. (Letter). *J Psychosom Res* 1995;39:507.
- Potter PT, Zautra AJ. Stressful life events' effects on rheumatoid arthritis disease activity. *J Consult Clin Psychol* 1997;65:319-23.
- Kemper TD. Social structure and testosterone. London: Rutgers University Press, 1990: 161.