

enzyme linked immunosorbent assay (ELISA) technique (Aesku Lab Diagnostika, Wendelsheim, Germany), which employs recombinant 93 kDa  $\alpha$ -fodrin as the antigen, and a home produced ELISA using as the antigen a synthetic  $\alpha$ -fodrin peptide corresponding to the 20 amino terminal residues of human  $\alpha$ -fodrin (RQKLEDSYRFQFFORDAEEL).

Only two (1.9%) patients with pSS had both IgA and IgG anti- $\alpha$ -fodrin antibodies. The home produced ELISA (anti-human IgA, IgM, and IgG horseradish peroxidase conjugate) confirmed these results with only four positive patient in the pSS group (n = 52). Among the 19 patients with IgA anti- $\alpha$ -fodrin antibodies, 15 patients also had anti-Ro60 antibodies and eight anti-La antibodies, while all six of the IgG positive sera contained anti-Ro60 and three of them anti-La antibodies.

## DISCUSSION

The autoantibody response against  $\alpha$ -fodrin as detected by the ELISA test does not appear to be a relevant serological marker of pSS. However, some discrepancies with immunoblotting or immunoprecipitation data need to be discussed.

Our findings confirm previous reports of the low sensitivity (<60% in the present study) of anti- $\alpha$ -fodrin antibodies for the diagnosis of pSS using ELISA or immunoprecipitation techniques<sup>3-5</sup> (table 1). Conversely, the present data are discordant with the results of some other studies,<sup>1-10</sup> which found a higher prevalence of these antibodies (up to 95% in one study) in patients with pSS using immunoblotting<sup>6,7</sup> or the same ELISA test as in our study.<sup>1,6,9,10</sup>

The low sensitivity of the ELISA methods could be related to the absence of dominant epitopes in either the synthetic oligopeptide or the recombinant  $\alpha$ -fodrin used in the commercial assay. Alternatively, a potential degradation of the recombinant protein cannot be ruled out. Thus the possibility of a lack of stability of the recombinant antigen led us to repeat the ELISA assay in all samples using a second kit from the same manufacturer, but with no improvement in the test sensitivity (data not shown). The reported discrepancies between different ELISA systems, which we also observed in the present study, would make such confirmation procedures mandatory.

The potential diagnostic value of anti- $\alpha$ -fodrin antibodies for patients with pSS without anti-Ro60/La antibodies appears to be very limited, given the large overlap between the presence of anti- $\alpha$ -fodrin and of anti-Ro60/La antibodies. Only four (3.7%) patients with pSS were positive for IgA or IgG anti- $\alpha$ -fodrin antibodies and negative for anti-Ro60/La.

The presence of anti- $\alpha$ -fodrin antibodies seems to be of little help in discriminating between pSS and other autoimmune diseases such as SLE or RA. The prevalence of IgA antibodies against recombinant  $\alpha$ -fodrin was in fact lower in pSS (17.7%) than in SLE (25%) or RA (23.3%). This apparent

lack of specificity of anti- $\alpha$ -fodrin antibodies, which has already been reported, requires confirmation using larger cohorts including various autoimmune diseases. Moreover, the presence of asymptomatic secondary SS in patients with RA or SLE cannot be ruled out. Thus all previous studies detected antibodies against  $\alpha$ -fodrin in subjects with primary or secondary SS (RA, SLE) (table 1).

In conclusion, the anti- $\alpha$ -fodrin antibodies detected by ELISA appear to be neither a sensitive nor a specific serological marker of pSS and the presence of such antibodies would seem to be of limited discriminatory value and of little interest in daily rheumatological practice.

## Authors' affiliations

C Sorder, J E Gottenberg, J Goetz, D Bengoufa, R-L Humbel, X Mariette, J Sibilia

Correspondence to: Professor J Sibilia, Service de rhumatologie, CHU Strasbourg- Hôpital de Hautepierre, 1, avenue mollière, 67098 Strasbourg Cedex, France; jean.sibilia@wanadoo.fr

Accepted 2 January 2005

## REFERENCES

- 1 Witte T, Matthias T, Oppermann M, Helmke K, Peter HH, Schmidt RE, et al. Prevalence of antibodies against alpha-fodrin in Sjögren's syndrome: comparison of 2 sets of classification criteria. *J Rheumatol* 2003;**30**:2157-9.
- 2 Vitali C, Bombardieri S, Jonsson R, Moutsopoulos HM, Alexander EL, Carsons SE, et al. Classification criteria for Sjögren's syndrome: a revised version of the European criteria proposed by the American-European Consensus Group. *Ann Rheum Dis* 2002;**61**:554-8.
- 3 Nordmark G, Rorsman F, Ronnblom L, Cajander S, Taussig MJ, Kampe O, et al. Autoantibodies to alpha-fodrin in primary Sjögren's syndrome and SLE detected by an in vitro transcription and translation assay. *Clin Exp Rheumatol* 2003;**21**:49-56.
- 4 Zandbelt MM, Vogelzangs J, van de Putte LBA, van Venrooij WJ, van den Hoogen FHJ. Anti-alpha-fodrin antibodies do not add much to the diagnosis of Sjögren's syndrome. *Arthritis Res Ther* 2004;**6**:R33-8.
- 5 Ruffatti A, Ostuni P, Grypiotis P, Botsios C, Tonello M. Sensitivity and specificity for primary Sjögren's syndrome of IgA and IgG anti-alpha-fodrin antibodies detected by ELISA. *J Rheumatol* 2004;**31**:504-7.
- 6 Haneji N, Nakamura T, Takio K, Yanagi K, Higashiyama H, Saito I. Identification of alpha-fodrin as a candidate autoantigen in primary Sjögren's syndrome. *et al. Science* 1997;**276**:604-7.
- 7 Watanabe T, Tsuchida T, Kanda N, Mori K, Hayashi Y, Tamaki K. Anti-alpha-fodrin antibodies in Sjögren syndrome and lupus erythematosus. *Arch Dermatol* 1999;**135**:535-9.
- 8 Witte T, Matthias T, Arnett FC, Peter HH, Hartung K, Sachse C, et al. IgA and IgG autoantibodies against alpha-fodrin as markers for Sjögren's syndrome. Systemic lupus erythematosus. *J Rheumatol* 2000;**27**:2617-20.
- 9 De Seze J, Dubucquoi S, Fauchais AL, Matthias T, Devos D, Castelnovo G, et al. Alpha fodrin autoantibodies in the differential diagnosis of multiple sclerosis and Sjögren syndrome. *Neurology* 2003;**61**:268-9.
- 10 De Seze J, Dubucquoi S, Fauchais AL, Hachulla E, Matthias T, Lefranc D, et al. Autoantibodies against  $\alpha$ -fodrin in Sjögren's syndrome with neurological manifestations. *J Rheumatol* 2004;**31**:500-3.

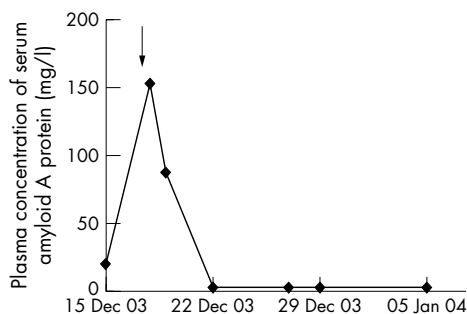
# Successful treatment of acute visual loss in Muckle-Wells syndrome with interleukin 1 receptor antagonist

T Alexander, O Klotz, E Feist, K Rüther, G-R Burmester, U Pleyer

Muckle-Wells syndrome (MWS) is a dominantly inherited autoinflammatory disease characterised by urticarial skin rash, intermittent fever, arthralgia, and the frequent development of systemic AA amyloidosis. It is caused by mutations in the gene known as *NALP3* or *CIAS*,

which encodes a member of the purine superfamily of death domain fold proteins that are implicated in the regulation of inflammation through activation of nuclear factor  $\kappa$ B (NF- $\kappa$ B) and regulation of interleukin 1 (IL1) processing.<sup>1,2</sup> Over recent years, therapeutic trials with the human recombinant

*Ann Rheum Dis* 2005;**64**:1245-1246. doi: 10.1136/ard.2004.032060



**Figure 1** Serial measurement of serum amyloid A concentration in one patient with MWS. The arrow indicates when treatment with anakinra began.

IL1 receptor antagonist anakinra have reported encouraging results in patients with various autoinflammatory syndromes.<sup>3,4</sup> We report here the unusual case of acute visual loss in a patient with MWS and its good response to anakinra.

### CASE REPORT

A 70 year old woman with a history of a MWS associated with the *NALP3* variant R260W was referred to our hospital with loss of vision in one eye that developed within days, accompanied by intermittent flash sensations.

On admission, she had an increased body temperature (38°C) and urticarial rashes as typical signs of a flare of MWS. Residual visual acuity at admission was limited to hand motion perception and light-darkness discrimination. A slit lamp examination showed regular pseudophakia on both eyes with an afferent pupillary defect of the left eye. Ophthalmoscopy of the left eye showed a pale optic nerve head oedema of 2 diopters. Pattern visual evoked potentials (VEPs) and flash VEPs of the affected eye were without responses. A kinetic visual field examination proved concentric constriction of the visual field of the left eye. Laboratory analysis showed a raised erythrocyte sedimentation rate of 36 mm/1st h and a C reactive protein of 32 mg/l.

Initial treatment with systemic high dose glucocorticoids and one cycle of plasmapheresis had no influence on the visual disturbance. The patient then consented to undergo a therapeutic trial of anakinra (Kineret; Amgen) given by subcutaneous injection at a dose of 100 mg daily, which is the dosage licensed for the treatment of rheumatoid arthritis.

Within 1 day of the first injection the rash and fever disappeared, and the patient reported a profound improvement in general wellbeing. The patient's sight of the left eye improved from hand movement upon referral to 0.3 within 10 days. In addition, the visual field defect recovered from band shaped to 50 degrees temporal and a vertical expansion of a maximal 20 degrees. The afferent pupillary defect persisted as well as VEP changes. As a serological marker, plasma concentration of serum amyloid A, which was markedly raised before treatment, normalised within 6 days and remained below 2 mg/l (normal <10 mg/l) on frequent testing for 3 weeks (fig 1).

### DISCUSSION

In this unusual and dramatic manifestation of MWS we observed a remarkable clinical remission, including recovery of the patient's visual acuity and visual field associated with a profound serological remission using the IL1 receptor antagonist anakinra.

To the best of our knowledge, this is the first description of acute visual loss in MWS. Being aware of the pale and swollen optic disc in our patient, we had to consider an anterior ischaemic optic neuropathy as a possible differential diagnosis. However, the clinical response using anakinra is strongly indicative for an association with an underlying inflammatory condition.

Visual disturbance is reported to be a clinical feature in patients with neonatal onset multisystem inflammatory disease (NOMID), an autoinflammatory disease that is also related to mutations in the *NALP3* gene.<sup>5</sup> Recent studies suggest that the same *NALP3* genetic defect may cause vastly different phenotypes of hereditary fever syndromes.<sup>6</sup> In this context, visual loss may possibly occur in patients considered to have MWS. The efficacy of anakinra in the treatment of visual disturbance in MWS strongly supports studies for this treatment of patients with NOMID, in which eye involvement is more common.

### Authors' affiliations

**T Alexander, E Feist, G-R Burmester**, Department of Rheumatology and Clinical Immunology, University School of Medicine Berlin, Germany

**O Klotz, K R  ther, U Pleyer**, Department of Ophthalmology Charit  , University School of Medicine Berlin, Germany

Correspondence to: Mr T Alexander, Charit   University School of Medicine Berlin, Schumannstr 20/21, D-10117 Berlin, Germany; tobias.alexander@charite.de

Accepted 28 December 2004

### REFERENCES

- Hoffman HM**, Mueller JL, Broide DH, Wanderer AA, Kolodner RD. Mutation of a new gene encoding a putative pyrin-like protein causes familial cold autoinflammatory syndrome and Muckle-Wells syndrome. *Nat Genet* 2001;**29**:301-5.
- Wang L**, Manji GA, Grenier JM, Al Garawi A, Merriam S, Lora JM, *et al*. PYPAF7, a novel PYRIN-containing Apaf1-like protein that regulates activation of NF-kappa B and caspase-1-dependent cytokine processing. *J Biol Chem* 2002;**277**:29874-80.
- Hawkins PN**, Lachmann HJ, McDermott MF. Interleukin-1-receptor antagonist in the Muckle-Wells syndrome. *N Engl J Med* 2003;**348**:2583-4.
- Hawkins PN**, Lachmann HJ, Aganna E, McDermott MF. Spectrum of clinical features in Muckle-Wells syndrome and response to anakinra. *Arthritis Rheum* 2004;**50**:607-12.
- Aksentjevich I**, Nowak M, Mallah M, Chae JJ, Watford WT, Hofmann SR, *et al*. De novo CIAS1 mutations, cytokine activation, and evidence for genetic heterogeneity in patients with neonatal-onset multisystem inflammatory disease (NOMID): a new member of the expanding family of pyrin-associated autoinflammatory diseases. *Arthritis Rheum* 2002;**46**:3340-8.
- Aganna E**, Martinon F, Hawkins PN, Ross JB, Swan DC, Booth DR, *et al*. Association of mutations in the *NALP3*/*CIAS1*/*PYPAF1* gene with a broad phenotype including recurrent fever, cold sensitivity, sensorineural deafness, and AA amyloidosis. *Arthritis Rheum* 2002;**46**:2445-52.