

CONCISE REPORT

Further evidence that a cartilage-pannus junction synovitis predilection is not a specific feature of rheumatoid arthritis

L A Rhodes, P G Conaghan, A Radjenovic, A J Grainger, P Emery, D McGonagle

Ann Rheum Dis 2005;64:1347–1349. doi: 10.1136/ard.2004.033688

Background: Qualitative differences in synovitis between the cartilage-pannus junction (CPJ) region and the adjoining suprapatellar pouch (SPP) have been reported in rheumatoid arthritis and the spondyloarthropathies.

Objective: To determine if the distribution of synovitis is the same in osteoarthritis (OA) using sensitive measures of inflammation derived from dynamic, contrast enhanced magnetic resonance imaging (DEMRI).

Methods: 20 subjects with established OA of the knee were recruited. Conventional MR images together with the DEMRI measurements were obtained. Areas of synovitis at the CPJ region and at a distant site in the SPP were calculated; differences in CPJ and SPP synovitis were determined using DEMRI parameters: the initial rate of contrast enhancement (IRE) and maximal enhancement (ME).

Results: The area of synovitis was significantly greater adjacent to the CPJ than in the SPP. IRE and ME measures were greater at the CPJ than the SPP.

Conclusions: The magnitude of synovitis at the CPJ is not disease-specific and applies across the spectrum of degenerative disease as well as inflammatory diseases.

Historically, quantitative regional differences in synovitis have not been recognised in synovial joints. Qualitative differences in synovitis between the cartilage-pannus junction (CPJ) region and the adjoining suprapatellar pouch (SPP) have been reported in rheumatoid arthritis (RA),^{1,2} possibly indicating that the CPJ has a fundamental role in the pathogenesis of RA.³ Our earlier work in RA and the spondyloarthropathies (SpA) has shown synovitis is not uniform within the SPP but generally is greater at the CPJ.¹ This might indicate common immunological mechanisms related to a cartilage directed immune response or common biomechanical factors at the pole of the patella determining the greater severity of synovitis.

Osteoarthritis (OA) refers to a heterogeneous group of disorders with common clinical and pathological features; it is strongly associated with aging, is the most prevalent joint disease, and has a strong biomechanical basis.^{4,5} Although synovial inflammation in OA appears to be a secondary process, synovitis is still common⁴; however, there are limited publications describing magnetic resonance imaging (MRI) measurements of synovitis in OA.^{6–10}

The purpose of this study was to determine whether the distribution of synovitis between the CPJ region and a distant region in the SPP was the same in OA as in the inflammatory arthropathies. Demonstration of a greater degree of synovitis at the CPJ in OA would support the concept that CPJ synovitis is not unique in RA, but due to common biomechanical and immunological factors in operation, even in degenerative arthritis.

METHODS

Twenty subjects with established OA of the knee were recruited consecutively. All subjects fulfilled the American College of Rheumatology criteria (clinical and radiographic) for OA. The study protocol was approved by the local ethical review committee, and all patients gave informed written consent to their participation in the study.

Magnetic resonance imaging and image processing

MRI of the knee was performed using a Philips 1.5 T Gyroscan ACS-NT whole body scanner (Philips Medical Systems, Best, the Netherlands) with a Philips quadrature knee coil; the knee was placed in the supine position. The dynamic, contrast enhanced MRI (DEMRI) sequence acquired 40 spoiled T₁ weighted gradient echo images from each of five sagittal slices before, during, and after the bolus injection of the contrast agent gadolinium diethylenetriamine pentaacetic acid (Gd-DTPA). The images were obtained using a repetition time of 11 ms, an echo time of 5.3 ms, and a flip angle of 60° that allowed the acquisition of 5 mm thick slices and a 5 mm gap between slices. The temporal resolution of the DEMRI measurements was 6 seconds for the individual images that constitute the DEMRI dataset. Gd-DTPA was administered at a dose of 0.1 ml/kg body weight 1 second after the acquisition of the first image in the dynamic series.

Commercial software (Analyze – Mayo Clinics, New York) and software developed in-house¹¹ were used to calculate values of maximal enhancement (ME) and the initial rate of contrast enhancement (IRE) on a pixel by pixel basis; these were displayed as colour overlays on conventional images showing anatomy (fig 1).

Measurements of MR parameters within the synovium at the CPJ and proximal SPP

Measurements were made on the midline sagittal slice at two sites as previously described.¹ Two rectangular regions of interest were defined: one at the superior pole of the patella positioned alongside the CPJ and the second at a remote site in the proximal SPP. Each region had identical superior-inferior dimensions (15 pixels) but variable anterior-posterior dimensions to accommodate the variable synovitis thickness in the sagittal plane (fig 1).

Osteophyte scoring

Unlike early OA and early SpA, where no CPJ region osteophytes were noted, not surprisingly osteophytes were noted in chronic OA; the effect of these on CPJ region synovitis was determined (fig 2). An experienced radiologist

Abbreviations: CPJ, cartilage-pannus junction; DEMRI, dynamic, contrast enhanced MRI; Gd-DTPA, gadolinium diethylenetriamine pentaacetic acid; IRE, initial rate of contrast enhancement; ME, maximal enhancement; MRI, magnetic resonance imaging; OA, osteoarthritis; RA, rheumatoid arthritis; SpA, spondyloarthropathies; SPO, superior pole patella osteophyte; SPP, suprapatellar pouch

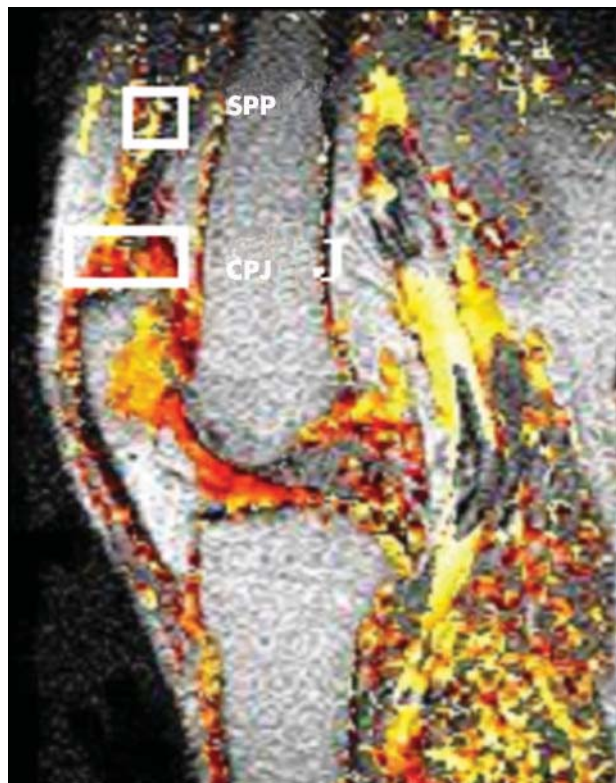


Figure 1 Conventional MR image acquired from the knee with superimposed colour data showing values of the IRE—pixels shown in yellow represent high IRE values while those in red show relatively lower values. Data were analysed in two regions of interest represented by white rectangles and located adjacent to the CPJ and the proximal SPP.

(AJG) used the whole organ semiquantitative OA knee scoring system (WORMS)¹² to score the MR data from a dedicated protocol of T₁ and T₂ weighted pre- and post Gd-DTPA sequences in three planes. The frequency of superior pole patella osteophytes (SPOs) in these patients was noted.

Statistical analysis

A paired *t* test was used to compare differences between the CPJ and the SPP, and independent *t* tests for differences between the CPJ and the SPO-CPJ. The intraobserver reproducibility for the delineation of regions of interest was calculated using intraclass correlation coefficients and found to be greater than 0.9, as had been observed in the previous study.¹

RESULTS

DEMRI parameters at the CPJ and SPP

A significantly larger area of synovitis was evident adjacent to the CPJ than the SPP, representing up to a sixfold difference in some cases. Both the IRE and the ME measures were significantly greater at the CPJ than at the SPP. Overall, these measures correlated with the observation that the synovial area at the CPJ was greater than at the SPP (table 1).

Effect of superior pole patella osteophytes

Radiological scoring highlighted SPOs ranging in size in several patients. Owing to the small number of patients, independent *t* tests did not show statistical significance; mean area values showed less synovitis at the CPJ in patients with SPOs, values of IRE and ME followed the same trend.

Table 1 Mean values of the sum of the DEMRI measures for enhancing pixels within the SPP

	CPJ v SPP		CPJ v SPO-CPJ	
	CPJ	SPP	CPJ	SPO-CPJ
Area (mm ²)	170.00	80.00	238	132
ME*	(p=0.0001) 353.25	148.21	(p=0.056) 473.56	293.221
IRE*	(p=0.0001) 3.38	1.26	(p=0.108) 4.87	2.84
	(p=0.0004)		(p=0.252)	

*The initial rate of enhancement (IRE) and maximal enhancement (ME) are shown in arbitrary units.

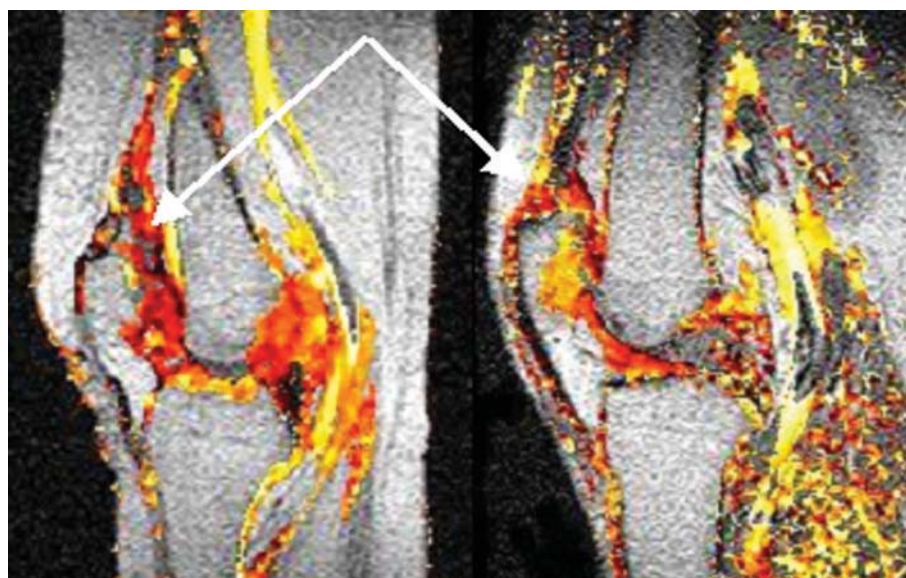


Figure 2 Comparison of CPJ and SPO-CPJ displacement of synovial tissue by superior patella osteophyte.

DISCUSSION

The purpose of this study was to determine whether the distribution of synovitis between the CPJ region and a distant region in the SPP was the same in OA as in the inflammatory arthropathies, where we have already reported a predilection for synovitis at the CPJ in both RA and the SpA.¹

The results presented here suggest that the magnitude of synovitis at the CPJ is not disease-specific and applies across the spectrum of degenerative disease as well as inflammatory disease. In addition to investigating synovial areas, this study also assessed other MRI measures of synovitis in the CPJ and SPP. Rates of contrast enhancement in RA have been shown to correlate with both inflammatory activity and blood vessel numerical density.¹³ We noted that IRE and ME measures, MRI surrogates of vascularity, were greater at the CPJ region. The consistent findings using different MRI measures all suggest that the phenotypic expression of synovitis seems to be dictated by common joint factors (biomechanical and immunological) across the spectrum of the rheumatic diseases rather than by specific CPJ features in RA.

MRI is complementary to arthroscopy for the assessment of synovitis. Although arthroscopy allows qualitative and biological assessment of synovitis by histology, it provides little information about the depth or volume of functional characteristics of synovitis. In this regard the ability of MRI to estimate the overall degree and distribution of synovitis may provide additional useful information. Although, MRI measures of synovitis correlate with histological grades, this was not formally assessed in the present study; but the findings of greater synovitis in OA in addition to that already reported in inflammatory arthritis at the CPJ, support the concept that synovitis at that site is not specific for RA, but represents a common joint response across all arthritides.

Although the differences between patients with osteophytes and those without must be viewed with some caution owing to the small numbers, the results show that their presence reduces the quantity of synovitis at the CPJ. The importance of this observation is not clear, but it may be that osteophytes affect the progression of synovitis at the CPJ by displacing synovial tissue from that site, thus affecting the distribution within the SPP.

In conclusion, this work reaffirms that synovitis is not randomly distributed in joints but shows a predilection for the CPJ region which is also a feature of OA. The implication of this study is that histological studies of the CPJ in RA that use tissue from the SPP from the same subjects as controls may not be adequate and that control tissue from the CPJ in other arthropathies is needed before it can be established that the CPJ is unique in RA.

ACKNOWLEDGEMENTS

Professor Conaghan is partially funded through a grant from the Arthritis Research Campaign. We are grateful to MSD UK for partial sponsorship of this study through an unrestricted educational grant and to the Medical Research Council, UK for funding.

Authors' affiliations

L A Rhodes, A Radjenovic, Academic Unit of Medical Physics, University of Leeds, Wellcome Wing, Leeds General Infirmary, Great George Street, Leeds LS1 3EX, UK

P G Conaghan, P Emery, D McGonagle, Academic Unit of Musculoskeletal Disease, Leeds General Infirmary, Great George Street, Leeds LS1 3EX, UK

A J Grainger, Department of Radiology, Leeds General Infirmary, Great George Street, Leeds LS1 3EX, UK

D McGonagle, Calderdale Royal Hospital, Salterhebble, Halifax HX3 0PW, UK

We, the authors, are not aware of any competing interests.

Correspondence to: Professor D McGonagle, d.g.mcgonagle@leeds.ac.uk

Accepted 17 February 2005

REFERENCES

- Rhodes LA**, Tan A-L, Tanner SF, Radjenovic A, Hensor EMA, Reece R, *et al*. Regional variation and differential response to therapy for knee synovitis in the cartilage-pannus junction and suprapatellar pouch in inflammatory arthritis. *Arthritis Rheum* 2004;**50**:2428–32.
- Benito MJ**, Murphy E, Murphy EP, van den Berg WB, FitzGerald O, Bresnihan B. Increased synovial tissue NF- κ B1 expression at sites adjacent to the cartilage-pannus junction in rheumatoid arthritis. *Arthritis Rheum* 2004;**50**:1781–7.
- Tak PP**, Bresnihan B. The pathogenesis and prevention of joint damage in rheumatoid arthritis. *Arthritis Rheum* 2000;**43**:2619–33.
- Felson DT**, Lawrence RC, Dieppe PA, Hirsch R, Helmick CG, Jordan JM, *et al*. Osteoarthritis: new insights. Part 1: the disease and its risk factors. *Ann Intern Med* 2000;**133**:635–46.
- Felson DT**, Zhang Y. An update on the epidemiology of knee and hip osteoarthritis with a view to prevention. *Arthritis Rheum* 1998;**41**:1343–55.
- Rhodes LA**, Grainger AJ, Keenan AM, Emery P, Conaghan PG. A comparison of quantitative and semi-quantitative MRI synovitis scores in knee osteoarthritis. *Rheumatology (Oxford)* 2004;**43**(suppl 2):ii63.
- Hill CL**, Gale DG, Chaisson CE, Skinner K, Kazis L, Gale ME, *et al*. Knee effusions, popliteal cysts, and synovial thickening: association with knee pain in osteoarthritis. *J Rheumatol* 2001;**28**:1330–7.
- Østergaard M**, Stoltenberg M, Løvgreen-Nielsen P, Volck B, Jensen CH, Lorenzen IB. Magnetic resonance imaging-determined synovial membrane and joint effusion volumes rheumatoid arthritis and osteoarthritis. Comparison with the macroscopic and microscopic appearance of the synovium. *Arthritis Rheum* 1997;**40**:1856–67.
- Fernandez-Madrid F**, Karvonen RL, Teitge RA, Miller PR, An T, Negendank WG. Synovial thickening detected by MR imaging in osteoarthritis of the knee confirmed by biopsy as synovitis. *Magn Reson Imaging* 1995;**13**:177–83.
- Fernandez-Madrid F**, Karvonen RL, Teitge RA, Miller PR, An T, Negendank WG. MR features of osteoarthritis of the knee. *Magn Reson Imaging* 1994;**12**:703–9.
- Reece RJ**, Kraan MC, Radjenovic A, Veale DJ, O'Connor PJ, Ridgeway JP, *et al*. Comparative assessment of leflunomide and methotrexate for the treatment of rheumatoid arthritis, by dynamic enhanced magnetic resonance imaging. *Arthritis Rheum* 2002;**46**:366–72.
- Peterfy CG**, Guermazi A, Zaim S, Tirman PFJ, Miaux Y, White D, *et al*. Whole-Organ Magnetic Resonance Imaging Score (WORMS) of the knee in osteoarthritis. *Osteoarthritis Cartilage* 2004;**12**:177–90.
- Gaffney K**, Cookson J, Blades S, Coumbe A, Blake D. Quantitative assessment of the rheumatoid synovial microvascular bed by gadolinium-DTPA enhanced magnetic resonance imaging. *Ann Rheum Dis* 1998;**57**:152–7.