

pharynx, sometimes with radiation to the ipsilateral ear and submandibular area. The pain was neither stabbing nor triggered by swallowing and eating. The attacks recurred about 10 times a day and lasted from several seconds to five minutes. During the year before admission, the attacks had become more frequent, and the duration of pain increased to 30 minutes. She had also felt foreign body sensations in her throat regardless of painful episodes. During the four months before admission, the painful episodes were occasionally accompanied by abdominal pain, diarrhoea, and syncope. The episodes of syncope recurred about twice a month. She had no hypertension or diabetes. There was no past history of infection or trauma. Neurological examination was normal. In particular, there were no definite abnormalities in deglutition, movement of the soft palate, and the gag reflex; there was no palpable mass or bruit in the neck, and no trigger zone was noted. Complete blood cell count and serum chemistry were normal. Antinuclear antibody and a serological test for syphilis were negative. Brain magnetic resonance imaging and cervical computed tomography showed a round mass in the upper portion of the left carotid space, compressing the parapharyngeal space forward (fig 1). Four vessel angiography showed a large aneurysm (3.9 × 3.0 cm) of the distal cervical portion of the left ICA (fig 2), which was located near the skull base above the Blaisdell line.⁶ There were no aneurysms elsewhere. A computed tomography scan of the neck showed no evidence of the elongated styloid process.

Treatment with phenytoin (300 mg a day) caused the paroxysmal pain to disappear completely within three days. Under general anaesthesia, the aneurysm was approached by a presternocleidomastoid cervicotomy without subluxation of the mandible or transection of the digastric muscle. The cutaneous incision was extended along the posterior border of the mastoid process. The aneurysm was found 5 cm above the carotid bifurcation. The anatomical relation between the aneurysm and the glossopharyngeal nerve was not identified in the surgical field. The aneurysm was resected, with replacement with a saphenous vein graft. Surgical and pathological findings indicated a true aneurysm. After surgery, there were no neurological deficits except incomplete Horner's syndrome on the left side. Postoperative angiography showed satisfactory reconstruction (fig 2). Phenytoin was not given after surgery. No episodes of pain or syncope recurred during the follow up period of six months after surgery.

Our case was characterised by episodic pain in the distribution of the glossopharyngeal nerve, sometimes associated with syncope, and a dramatic response to phenytoin. A huge aneurysm of the extracranial ICA was found to be the cause of the glossopharyngeal pain and syncope syndrome, which was confirmed by successful surgical resection. The syndrome of glossopharyngeal pain and/or syncope may be caused by a variety of conditions. In this case, glossopharyngeal neuralgia was considered to be unlikely because of the absence of a stabbing feeling, precipitating factors, or trigger zones. Also, there was no radiological evidence of mass lesions in the parapharyngeal space or the elongated styloid process.

The pathogenetic mechanism in our patient was considered to be similar to that involved in glossopharyngeal neuralgia and syncope. Sobol *et al*⁷ reported two cases of glossopharyngeal neuralgia-asystole syndrome associated with ipsilateral lesions of the parapharyngeal space, and postulated that parapharyngeal space lesions may induce neural irritation to the afferent pain fibres of the glossopharyngeal nerve and reflex within the nerve of Hering to produce the syndrome.

The causes of aneurysm of the ICA are multiple and include atherosclerosis, dysplasia, trauma, and infectious lesions.⁷ The cause in our patient was not known despite the histological examination. Welling *et al*⁸ reported that 41 of 1118 aneurysms of the peripheral arteries arose from the extracranial carotid system. Only four of them were saccular aneurysms of the ICA. Although aneurysms of the extracranial ICA do not usually produce neurological symptoms, they may result in potentially serious problems, such as cerebrovascular events, as a consequence of thromboembolic phenomena or impairment of flow in the proximal carotid artery. Isolated cranial neuropathies can also occur as the result of direct nerve compression.⁹ In this case, the aneurysmal parapharyngeal mass produced episodic glossopharyngeal pain and syncope.

Y-M Lim, S-A Lee

Department of Neurology, Asan Medical Center, University of Ulsan College of Medicine, Seoul, Korea

D-K Kim, G-E Kim

Division of Vascular Surgery, Asan Medical Center

Correspondence to: Dr Lee, Department of Neurology, Asan Medical Center, 388-1, Pungnap-dong, Songpa-gu, Seoul, 138-736, Korea; salee@www.amc.seoul.kr

References

- 1 Hermanowicz N, Truong DD. Cranial nerve IX (glossopharyngeal) and X (vagus). In: Goetz CG, Pappert EJ, eds. *Textbook of clinical neurology*. Philadelphia: Saunders, 1999:201-13.
- 2 Sobol SM, Wood BG, Conoyer JM. Glossopharyngeal neuralgia-asystole syndrome secondary to parapharyngeal space lesions. *Otolaryngol Head Neck Surg* 1982;90:16-19.
- 3 Cicogna R, Bonomi FG, Curnis A, *et al*. Parapharyngeal space lesions syncope-syndrome. A newly reflexogenic cardiovascular syndrome. *Eur Heart J* 1993;14:1476-83.
- 4 Bafaqeh SA. Eagle syndrome: classic and carotid artery types. *J Otolaryngol* 2000;29:88-94.
- 5 Minagar A, Sheremata WA. Glossopharyngeal neuralgia and MS. *Neurology* 2000;54:1368-70.
- 6 Blaisdell W, Claus R, Galbraith J, *et al*. Joint study of extracranial arterial occlusion, IV: a review of surgical considerations. *JAMA* 1969;209:1889-95.
- 7 Rosset E, Albertini JN, Magnan PE, *et al*. Surgical treatment of extracranial internal carotid artery aneurysms. *J Vasc Surg* 2000;31:713-23.
- 8 Welling RE, Taha A, Goel T, *et al*. Extra cranial carotid artery aneurysms. *Surgery* 1983;93:319-23.
- 9 Lane RJ, Weisman RA, Savino PJ, *et al*. Aneurysm of the internal carotid artery at the base of the skull: an unusual cause of cranial neuropathies. *Otolaryngol Head Neck Surg* 1980;88:230-2.

Acute hyperperfusion syndrome complicating EC-IC bypass

The extracranial-intracranial (EC-IC) arterial bypass study has been criticised for failing to select for patients with chronic haemodynamic insufficiency and for revascularisation

with low flow grafts, which may augment perfusion inadequately.¹ We report a case of EC-IC bypass in a patient with severe intracranial carotid stenosis and compromised cerebrovascular reserve, which was complicated by intraoperative hyperperfusion syndrome. Hyperperfusion syndrome as a result of EC-IC bypass is not well documented and its occurrence directly after bypass has not been reported before. We discuss the pathophysiology and prophylactic measures of this complication, with special attention to the nature of the bypass performed.

A 48 year old right handed woman presented with a four month history of recurrent transient ischaemic attacks characterised by left sided symptoms of perioral paraesthesia, hand numbness, and upper extremity weakness (grade 4/5). The attacks were refractory to treatment with ticlid, a platelet aggregation inhibitor, and at the time of admission to hospital she was having several episodes daily, each lasting up to 15 minutes. She was therapeutically heparinised, her blood pressure was augmented to 150-180 mm Hg with intravenous vasopressors, and florinef treatment was begun to expand her vascular volume. The transient ischaemic attacks persisted unabated despite three weeks of this regimen in the intensive care unit.

Preoperative T2 weighted magnetic resonance images revealed a few small scattered subcortical signal changes, but no evidence of a previous cerebrovascular event. Cerebral angiography showed severe right supraclinoid internal carotid artery and proximal right M1 stenoses with contribution to filling of the middle cerebral tree from pial collaterals. The cervical carotid arteries were normal. Transcranial Doppler studies with carbon dioxide vasodilatation challenge showed flow limiting stenosis with compromised cerebrovascular reserve.

On the basis of these data and the refractory nature of the symptoms, we decided to proceed with a high flow revascularisation procedure. An autologous saphenous vein graft was inserted into a proximal M2 branch and the external cervical carotid artery in end to side fashion. During this time the patient's systolic blood pressure was maintained between 160 and 180 mm Hg, and she had been cooled to 34°C and treated with 20% mannitol (100 g). An intraoperative angiogram, performed immediately after completion of the anastomoses, confirmed patency of the bypass graft and normal filling of the middle cerebral tree.

As we were preparing to close the craniotomy, approximately 45 minutes after flow was established through the bypass graft, the brain became massively swollen. A temporary clip was placed across the graft, and the brain relaxed, becoming soft with return of pulsatility. A second intraoperative angiogram showed evidence of hyperperfusion syndrome with the presence of a dense vascular blush throughout the middle cerebral tree (fig 1). Attempts to limit flow through the graft failed and a permanent clip was placed across the graft. Postoperative serial computed tomography showed intracranial haemorrhage and cerebral oedema with progressive mass effect, commensurate with a worsening neurological state. After discussions with the family, aggressive supportive measures were withdrawn and the patient died.

Symptoms of intracranial stenotic lesions are usually haemodynamic in aetiology and develop after the collateral blood supply fails

to support metabolic demands despite maximum oxygen extraction. Management of patients refractory to treatment with antiplatelet or anticoagulant agents, blood pressure augmentation, and blood volume expansion is difficult. There is a high risk of stroke, and several studies have argued strongly in favour of EC-IC bypass in these patients. Consequently, a decision was made in this case to carry out a high flow bypass from the external carotid artery to an M2 branch of the middle cerebral artery. The long nature of the lesion in the supraclinoid carotid, extending into the proximal M1 segment, was judged not amenable to angioplasty. We failed to consider seriously the use of a low flow bypass graft.

Hyperperfusion following cerebral revascularisation is well recognised, particularly in the context of carotid endarterectomy. Its occurrence secondary to EC-IC bypass is not surprising. Intracerebral haemorrhages can complicate both superficial temporal artery to middle cerebral artery (STA-MCA) and saphenous vein EC-IC bypasses for carotid occlusive disease, but evidence for hyperperfusion as the underlying cause of these haemorrhages is not established. A dense perfusion blush on the intraoperative angiogram documented hyperperfusion following connection of the EC-IC bypass in this case (fig 1). In chronically ischaemic brain, hyperperfusion syndrome is thought to arise as a result of disturbed cerebral autoregulation.² The vasculature is maximally dilated and following restoration of flow vascular reactivity is impaired and unable to vasoconstrict appropriately, to protect the capillary bed against the increased perfusion pressure. Low signal oedematous changes and cerebral haemorrhage result, as was evidenced on postoperative computed tomography in this case.

Several factors led to the development of hyperperfusion syndrome in our case. Preoperatively we failed to recognise that altered microvascular permeability of the chronically hypoperfused brain may lower the safe threshold for ischaemia and hypertension.³ Despite neuroprotective measures, temporary occlusion of the M2 branch for the bypass may have resulted in a serious degree of ischaemia, and our routine practice of modestly raising the patient's blood pressure during temporary clipping may have been detrimental in this setting. Given the increased susceptibility of the chronically ischaemic

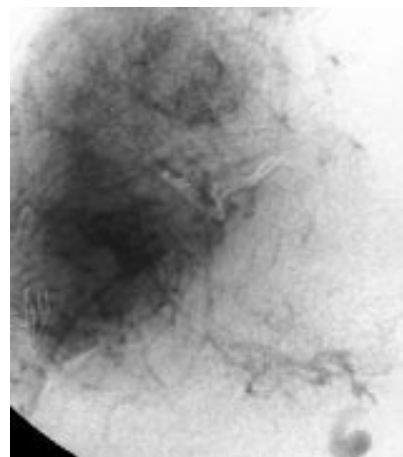


Figure 1 Intraoperative right carotid artery angiogram showing hyperperfusion, as evidenced by a dense vascular blush in the middle cerebral artery distribution.

blood brain-barrier to injury, the choice of a high flow bypass was in retrospect an error. Depending on the diameter of the graft, saphenous vein bypass grafts provide flows to 110 ml/min.⁴ By comparison, STA-MCA bypasses generate flows through the graft in the range of 10 to 60 ml/min (mean, 28 ml/min).⁵ Revascularisation is instituted to rescue tissue with blood flows of 20–25 ml/100 g/min from dropping to 10–15 ml/100 g/min leading to cell death.⁶ This incremental augmentation of blood flow can be achieved by a low flow STA-MCA bypass with a lower risk of complications. Over time, adaptation will occur, allowing increased flow through the bypass graft to be tolerated more safely than if an ischaemic brain is subjected acutely to these high flows.

Patients with intracranial stenosis and compromised cerebrovascular reserve—highlighted as a group most likely to benefit from EC-IC bypass—are at high risk for hyperperfusion syndrome. Strict attention to judicious choice of bypass conduit, minimising ischaemic time for the anastomosis, optimal neuroprotection, and meticulous control of blood pressure and intravenous fluids is mandatory to minimise complications of hyperperfusion syndrome and optimise the potential benefit of EC-IC bypass in these patients.

S I Stiver, C S Ogilvy

Cerebrovascular Surgery, Neurosurgical Service, Massachusetts General Hospital and Harvard Medical School, Boston, Massachusetts, USA

Correspondence to: Dr Shirley I Stiver, Beth Israel Deaconess Medical Center, Boston, Massachusetts, USA; sstiver@caregroup.harvard.edu

References

- 1 **Awad IA**, Spetzler RF. Extracranial-intracranial bypass surgery: a critical analysis in light of the International Cooperative Study. *Neurosurgery* 1986;**19**:655–64.
- 2 **Bernstein M**, Fleming JFR, Deck JHN. Cerebral hyperperfusion after carotid endarterectomy: a cause of cerebral hemorrhage. *Neurosurgery* 1984;**15**:50–6.
- 3 **Sakaki T**, Tsujimoto S, Nishitani M, et al. Perfusion pressure breakthrough threshold of cerebral autoregulation in the chronically ischemic brain: an experimental study in cats. *J Neurosurg* 1992;**76**:478–85.
- 4 **Sundi TM**, Piegras DG, Marsh WR, et al. Saphenous vein bypass grafts for giant aneurysms and intracranial occlusive disease. *J Neurosurg* 1986;**65**:439–50.
- 5 **Spetzler R**, Chater N. Microvascular bypass surgery. Part 2. Physiological studies. *J Neurosurg* 1976;**45**:508–13.
- 6 **Yoshimoto Y**, Kwak S. Superficial temporal artery-middle cerebral artery anastomosis for acute cerebral ischemia: the effect of small augmentation of blood flow. *Acta Neurochir (Wien)* 1995;**137**:128–37.

A Japanese case of steroid responsive myopathy with deficient chondroitin sulphate

In 1998, Al-Lozi *et al* described a case of steroid responsive myopathy with deficient chondroitin sulphate C that had not been reported before.¹ The patient developed diffuse bulbar and systemic weakness with respiratory failure. While muscle biopsy showed only a moderate degree of type 2 atrophy with one small perimysial, perivascular mononuclear cell infiltration, immunocytochemistry showed an absence of chondroitin sulphate C in the

endomysium. Prednisone treatment resulted in a marked increase in muscle strength. Here we report another case of this interesting and treatable muscle disorder.

Case history

A Japanese woman first developed neck muscle weakness, dysphasia, and weight loss at the age of 42 years. She was diagnosed as having anorexia nervosa and was placed on antidepressive drug treatment. Her symptoms worsened and after a few months she developed weakness in all of her limbs, sluggish speech, and diplopia, and began having difficulty with breathing. She presented in our outpatient clinic in 1993 at the age of 43.

Her personal and family histories were negative for neuromuscular disorders. On physical examination, she was very thin (height 162 cm; weight 32 kg), and her temperature was 38.1°C. Coarse crackles were heard in the right lower lung. Neurological examination revealed dysarthria, dysphasia, bilateral ptosis, limitation of extraocular movements in all directions, proximal muscle weakness of all four limbs, and generalised hyporeflexia. Her muscle tone, sensory perception, and autonomic system were normal, as was her cognitive function.

Laboratory tests showed signs of inflammation (white blood count 9000/ μ l, C reactive protein 3.2 mg/dl), considered to be the result of mild aspiration pneumonia in the right lower lung on chest x ray. There was also hypoproteinaemia. Blood gas analysis revealed hypoxia, with a P_{aO_2} of 8.05 kPa, a P_{aCO_2} of 9.27 kPa, and a blood pH of 7.392. Other blood constituents were normal, including creatinine kinase, aldolase, antiacetylcholine receptor antibody, antinuclear antibody, lactic acid, and pyruvic acid. Urinalysis, ECG, and cerebrospinal fluid examination were also normal, as was brain magnetic resonance imaging.

Electromyography (EMG) showed myogenic discharges in both biceps brachii, the left rectus femoris, and in both sternocleidomastoid muscles. Motor and sensory nerve velocities were normal in the median, ulnar, tibial, peroneal, and sural nerves. Repetitive stimulation tests of the facial and deltoid muscles gave normal results. A tensilon test was negative.

Because she was clinically diagnosed as having atypical oculopharyngeal myopathy with respiratory failure, a biopsy was performed on the right rectus femoris muscle. On histochemical examination, a moderate degree of type 2 atrophy was identified (fig 1A). Immunohistochemical investigation using antibodies to CD3, CD4, CD8, CD68, and CD22 (Dako Denmark; catalogue Nos 054, 105, 036, 044, and 093) failed to show the presence of infiltrating inflammatory cells (data not shown).² At this time, the origin of the patient's disorder remained undetermined.

The patient was given prednisone orally in a dose of 60 mg/day and her symptoms markedly improved. By day 7, the diplopia, dysphagia, and dyspnoea had resolved. After four months, she was discharged with no remaining neurological deficit. Her prednisone dosage was gradually reduced and eight years later, at the time of writing, she was taking a maintenance dose of 20 mg every other day and showed no neurological deterioration.

Because the clinical features of steroid responsive myopathy with deficient chondroitin sulphate C—first reported in 1998¹—were similar to those in our case, we carried out an immunohistochemical study using a monoclonal antibody to chondroitin sulphate