

CASE REPORT

Pelvic inflammatory disease associated with *Enterobius vermicularis*

T Tandan, A J Pollard, D M Money, D W Scheifele

Arch Dis Child 2002;86:439-440

A case of pelvic inflammatory disease in a sexually non-active 13 year old girl is described, with evidence of pinworms as the cause. Albendazole treatment cleared the infestation but the patient suffered subsequent bouts of lower abdominal pain. The literature is reviewed regarding abdominal pathology associated with ectopic migration of pinworms.

Pelvic inflammatory disease involves inflammation of the endometrium, fallopian tubes, pelvic peritoneum, and contiguous structures caused by ascent of organisms to the normally sterile upper genital tract. A majority of cases are caused by *Chlamydia trachomatis*, but many other organisms have been implicated. We describe a case of an adolescent girl with pelvic inflammatory disease caused by *Enterobius vermicularis* and discuss the diagnosis, management, and implications of this infection.

CASE REPORT

A 13 year old girl presented to the emergency room with a five day history of vomiting, diarrhoea, fever, and abdominal pain. She was not sexually active and had a normal menstrual cycle (menarche 11 years). She had suffered in the past from migraine and recurrent Bell's palsy but had been well before onset of this illness. Her spare time was spent figure skating and she earned money as a babysitter for 6-12 year old children.

At presentation, the girl was afebrile but appeared pale and unwell. Physical examination revealed notable tenderness in the right lower quadrant, guarding, and rebound tenderness. White blood cell count was $11.7 \times 10^9/l$; the differential count

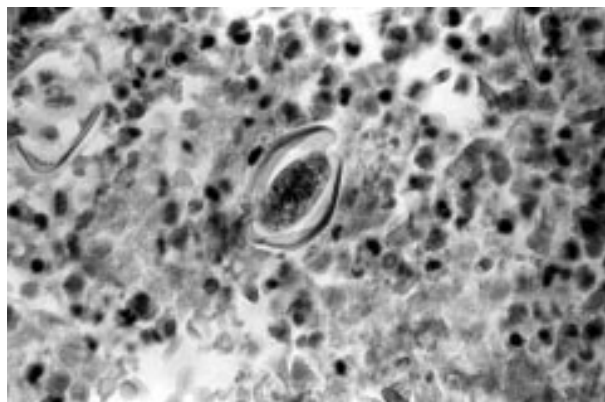


Figure 1 The hard shelled egg of *E vermicularis* is prominent centrally, surrounded by inflammatory cells including eosinophils (biopsy specimen of the pelvic peritoneum; haematoxylin and eosin stain, 400 \times).

showed an eosinophilia of $0.82 \times 10^9/l$ rising to $2.2 \times 10^9/l$ over the next four days.

A right ovarian cyst and pelvic free fluid were seen on ultrasound examination, prompting gynaecological investigation. At laparoscopy a 2-3 cm right ovarian functional cyst was seen; there were signs of chronic inflammation with a yellow-green exudate in the pelvic peritoneum. Uterus and fallopian tubes appeared normal. Histological examination of the inflamed pelvic peritoneum showed an eosinophilic infiltrate and pinworm ova (see fig 1). Coagulase negative staphylococci were isolated from the pelvic fluid and cloxacillin commenced following antibiotic sensitivity testing. These organisms were thought to have been carried to the peritoneum by the worms. The patient was treated with two 400 mg doses of albendazole administered one week apart. The family contacts also received a dose of mebendazole.

The postoperative course was complicated by an *E coli* urinary tract infection which responded to cephalexin treatment. The abdominal pain rapidly improved with use of non-steroidal anti-inflammatory drugs (diclofenac sodium) and the girl was discharged home. On review six months later, she had undergone three further laparoscopies for recurrent right lower quadrant abdominal pain, but there was no evidence of persistent *Enterobius* infection or pelvic inflammation. Uterus, ovaries, and fallopian tubes were reported as normal, with no obvious scarring or adhesions.

DISCUSSION

Enterobius vermicularis (pinworm or threadworm) is a common intestinal parasite, perhaps affecting 10% of North Americans per year.¹ Pinworm infections predominantly occur in young children (5-10 years), who present with perianal and perineal pruritis, but adults may also be affected.² Despite this high prevalence, enterobiasis is not usually considered to be a serious disease, although ectopic infections, seen most commonly in females, can cause significant morbidity.¹ It is likely that the enterobius infection in our patient was an occupational hazard of working as a babysitter, and that she acquired infection either from direct contact with the children or via contaminated fomites.

The 2-4 week life cycle of *E vermicularis* occurs normally in the lumen of the human gastrointestinal tract. Transmission is faecal-oral as a result of self contamination of hands, or ingestion of contaminated fomites. The outer proteinaceous layer of the egg dissolves on exposure to digestive secretions, releasing larvae into the duodenum; the adult worms inhabit the distal small and proximal large bowel, where mating occurs. At night, the gravid female migrates to the anal verge to deposit as many as 10 000 eggs. The eggs embryonate within hours and remain viable for 20 days. These eggs may then infect the same or a new susceptible host through anal-oral transmission, or via "retroinfection". In the latter instance, the larvae migrate from the anal verge back into the gastrointestinal tract where they mature, mate, and continue their life cycle.¹

The chief symptom of classical pinworm infection is pruritis ani, caused by mechanical irritation and allergic reaction, and is often manifest as irritability, insomnia, and enuresis. These features were not present in our patient. Ectopic infections result from spread of larvae from the anal margin to a wide variety of ectopic sites. The local inflammatory response or secondary bacterial infection cause symptoms and clinical presentation. Direct inoculation of larvae may result in infection of distant sites such as the external auditory meatus or conjunctiva, but occasionally the parasites reach internal ectopic sites. Ascent of larvae from the perineum into the female genital tract is the most common, and was the probable route of entry into the peritoneum of our case. Such navigational errors by the parasite may result in fallopian tube infiltration,^{3,4} salpingo-oophoritis,^{5,6} tubo-ovarian abscess,⁷ or granulomata of the vulva, vagina,⁸ uterus,⁹⁻¹¹ fallopian tubes,² or ovaries,¹² and even the human embryo.^{13,14}

Escape of worms through the fallopian tubes into the peritoneal cavity can lead to pelvic^{10,12,15} or abdominal peritonitis,^{12,16,17} or granulomata of the pelvic peritoneum.^{11,13,18} Following entry into the peritoneum, formation of enterobius granulomata in or on the liver,^{19,20} spleen, or kidney may occur.^{1,2}

Another possible means of ectopic spread into the peritoneum is perforation of the intestine or appendix, allowing penetration of the pinworms through the damaged intestinal wall into the peritoneal cavity. This secondary route of parasite migration helps to account for the reported cases of ectopic infection occurring in males.²

Girls with *E. vermicularis* infection have an increased incidence of urinary tract infection, probably because of migration of worms into the urethra and bladder, and this may have accounted for the urinary tract infection in our patient. Transfer of enteric or cutaneous organisms to these normally sterile sites along with the pinworms has been documented previously,²¹ and may be the explanation for the isolation of bacteria from the peritoneum of our patient.

Such ascending genital tract infection in the presence of lower abdominal, adnexal, and cervical motion tenderness fits the definition of pelvic inflammatory disease (PID).²² *Chlamydia trachomatis*, *Neisseria gonorrhoeae*, bacteroides, and *Mycoplasma* sp. are the most common causes of PID, but the presence of eosinophilia might suggest pinworm disease.

In our case pathological examination of the peritoneal biopsy showed an abundance of eosinophils, and a moderate number of eggs with features typical of *E. vermicularis*. Classically, the ova are 25 × 50 microns, are covered in a thick shell, and have an asymmetric configuration with one flattened side.² The eggs are much more resistant to degradation than the adult worms.^{2,10} The worms are difficult to demonstrate in pathological specimens and granulomas may contain only eggs, presumably because the worms are more susceptible to destruction by the immune system.

Enterobius vermicularis is readily killed with antiparasitic therapy. Reinfection, primarily a result of the ongoing spread of eggs/larvae, which are not affected by the drugs (only adult worms are killed), requires administration of a second dose. Family members and sexual contacts also require therapy to prevent reinfection and spread of disease. Albendazole is better tolerated than piperazine and more effective than mebendazole,²³ and may be preferable for ectopic *Enterobius* infection because of the poor systemic absorption of mebendazole. Careful handwashing and environmental decontamination are also probably important in reducing transmission.

The sequelae of PID, including chronic pelvic pain (18%), ectopic pregnancy (relative risk increased tenfold), and tubal infertility (up to 20% after one episode) with intra-abdominal scarring,²² highlight the potential importance of ectopic enterobiasis in females. One previous case of infertility was attributed to the pinworm.²⁴ Our patient has suffered with

chronic abdominal pain since the initial presentation, prompting multiple surgical interventions and may be at risk of future problems with infertility, ectopic pregnancy, and continuing abdominal-pelvic pain.

Although most pinworm infections are minor, ectopic infections in the female genital tract can be a diagnostic challenge and may have long term implications for reproductive health.

ACKNOWLEDGEMENTS

AJP was funded by the Pediatric Infectious Disease Society through an unrestricted educational grant from Pfizer Inc.

Authors' affiliations

T Tandan, A J Pollard, D W Scheifele, Division of Infectious Diseases and Department of Paediatrics, BC's Children's Hospital, Vancouver, British Columbia, Canada

D M Money, Department of Obstetrics and Gynecology, BC's Women's Hospital, Vancouver

Correspondence to: Dr A J Pollard, University Department of Paediatrics, University of Oxford, Level 4, John Radcliffe Hospital, Oxford OX3 9DU, UK; ajpollard@compuserve.com

Accepted 4 February 2002

REFERENCES

- Russell LJ. The pinworm, *Enterobius vermicularis*. *Prim Care* 1991;**18**:13-24.
- Sun T, Schwartz NS, Sewell C, et al. Enterobius egg granuloma of the vulva and peritoneum: review of the literature. *Am J Trop Med Hyg* 1991;**45**:249-53.
- Tsung SH, Loh WP. Invasion of the fallopian tube by *Enterobius vermicularis*. *Ann Clin Lab Sci* 1979;**9**:393-5.
- Schnell VL, Yandell R, Van Zandt S, et al. Enterobius vermicularis salpingitis: a distant episode from precipitating appendicitis. *Obstet Gynaecol* 1992;**80**:553-5.
- Kogan J, Alter M, Price H. Bilateral Enterobius vermicularis salpingo-oophoritis. *Postgrad Med* 1983;**73**:305,309-10.
- Erhan Y, Zekioglu O, Ozdemir N, et al. Unilateral salpingitis due to *Enterobius vermicularis*. *Int J Gynecol Pathol* 2000;**19**:188-9.
- Khan JS, Steele RJ, Stewart D. Enterobius vermicularis infestation of the female genital tract causing generalised peritonitis. Case report. *Br J Obstet Gynaecol* 1981;**88**:681-3.
- Chung DI, Kong HH, Yu HS, et al. Live female *Enterobius vermicularis* in the posterior fornix of the vagina of a Korean woman. *Korean J Parasitol* 1997;**35**:67-9.
- al-Rufaie HK, Rix GH, Perez Clemente MP, et al. Pinworms and postmenopausal bleeding. *J Clin Pathol* 1998;**51**:401-2.
- Pearson RD, Irons RP Sr, Irons RP Jr. Chronic pelvic peritonitis due to the pinworm *Enterobius vermicularis*. *JAMA* 1981;**245**:1340-1.
- McMahon JN, Connolly CE, Long SV, et al. Enterobius granulomas of the uterus, ovary and pelvic peritoneum. Two case reports. *Br J Obstet Gynaecol* 1984;**91**:289-90.
- Sinniah B, Leopairut J, Neafie RC, et al. Enterobiasis: a histopathological study of 259 patients. *Ann Trop Med Parasitol* 1991;**85**:625-35.
- Knuth KR, Fraiz J, Fisch JA, et al. Pinworm infestation of the genital tract. *Am Fam Physician* 1988;**38**:127-30.
- Mendoza E, Jorda M, Rafel E, et al. Invasion of human embryo by *Enterobius vermicularis*. *Arch Pathol Lab Med* 1987;**111**:761-2.
- Dalrymple JC, Hunter JC, Ferrier A, et al. Disseminated intraperitoneal oxyuris granulomas. *Aust N Z J Obstet Gynaecol* 1986;**26**:90-1.
- McDonald GS, Hourihane DO. Ectopic *Enterobius vermicularis*. *Gut* 1972;**13**:621-6.
- Chandrasoma PT, Mendis KN. Enterobius vermicularis in ectopic sites. *Am J Trop Med Hyg* 1977;**26**:644-9.
- Vinuela A, Fernandez-Rojo F, Martinez-Merino A. Oxyuris granulomas of pelvic peritoneum and appendicular wall. *Histopathology* 1979;**3**:69-77.
- Little MD, Cuellar CJ, D'Alessandro A. Granuloma of the liver due to *Enterobius vermicularis*. Report of a case. *Am J Trop Med Hyg* 1973;**22**:567-9.
- Nutting SA, Murphy F, Inglis FG. Abdominal pain due to *Enterobius vermicularis*. *Can J Surg* 1980;**23**:286-7.
- Simon RD. Pinworm infestation and urinary tract infection in young girls. *Am J Dis Child* 1974;**128**:21-2.
- Pletcher JR, Slap GB. Pelvic inflammatory disease. *Pediatr Rev* 1998;**19**:363-7.
- Coulaud JP, Rossignol JF. Albendazole: a new single dose antihelminthic. Study in 1455 patients. *Acta Trop* 1984;**41**:87-90.
- Neri A, Tadir Y, Grausbard G, et al. Enterobius (*Oxyuris*) vermicularis of the pelvic peritoneum—a cause of infertility. *Eur J Obstet Gynecol Reprod Biol* 1986;**23**:239-41.