

PITUITARY DISEASE: PRESENTATION, DIAGNOSIS, AND MANAGEMENT

A Levy

iii47

J Neurol Neurosurg Psychiatry 2004;75(Suppl III):iii47–iii52. doi: 10.1136/jnnp.2004.045740

The diagnosis of pituitary disease is generally uncomplicated. This is despite the high prevalence of occult pituitary adenomas in the general population, the widespread use of high definition imaging techniques, and the broad range of intra- and perisellar lesions that can mimic pituitary adenomas. Follow up and optimisation of pituitary hormone replacement is also relatively straightforward, but management of visual impairment, reduced fertility, coarsened facial features, arthritis, obesity, headaches, and obstructive sleep apnoea is often much more troublesome. The Pituitary Foundation (internet search term: “Pit Pat”) provides important opinion and information, and reassures patients that they are not alone.

In this brief overview, the presentation, classification, and general investigation of pituitary lesions is followed by a discussion of the diagnosis and management of specific secretory subtypes.

PRESENTATION OF PITUITARY ADENOMAS

Inappropriate pituitary hormone secretion and visual field deficits are the most characteristic presenting features of pituitary adenomas. Less specific symptoms such as headache, and subtle signs of pituitary hormone deficiency with peripheral endocrine organ hypofunction characterised by amenorrhoea, loss of libido, and lethargy, are also common. Lymphocytic hypophysitis, pituitary apoplexy, and evidence of more extensive disease such as cranial nerve palsies, temporal lobe epilepsy, hydrocephalus, and cerebrospinal fluid (CSF) rhinorrhoea are fortunately rarer. An exaggerated “physiological” trophic response to prolonged hypothyroidism presenting with visual field defects is well described but is, like pituitary carcinoma, very rare.

CLASSIFICATION OF PITUITARY ADENOMAS

Pituitary adenomas are classified by size and hormone secretory subtype. So-called “silent adenomas”, in which abnormal hormone gene activity is not accompanied by excessive hormone secretion, tend to be more aggressive than truly inactive adenomas. Erosion of the sellar walls and cavernous sinus invasion also suggest a more invasive nature, but estimation of mitotic index and subclassifications based on genetic and ultrastructural studies are research tools without significant clinical utility.

GENERAL INVESTIGATIONS

Imaging

Magnetic resonance imaging (MRI) scanning of the pituitary region, involving fine cuts and sagittal and coronal reconstruction, is the gold standard imaging method for pituitary disease. Some patients find the noise, confined space, and extended duration of MRI examination uncomfortable, however, and calcified lesions such as craniopharyngiomas may be more easily identified with computed tomography (CT). Gadolinium enhancement of pituitary MRI can be helpful for small microadenomas.

Visual fields

Progressive deterioration of visual fields is often the principle neurological criterion on which surgical management decisions are based. Humphrey computerised visual fields are useful even if there appears to be no contact between the optic pathways and pituitary mass. This is because field defects may reflect previous impingement, potential vascular shunting, or displacement of the chiasm following decompression. As dense bitemporal loss may reduce binocular field by only 25%, Esterman fields are important to objectively assess fitness to drive (internet search term: “DVLA”).

Hormone changes

Symptoms and signs of pituitary hormone deficiency are more subtle than those seen in primary end organ failure (table 1). Syndromes of pituitary hormone excess are described below.

Correspondence to:
Dr Andy Levy, Henry
Wellcome Labs for Integrative
Neuroscience &
Endocrinology, University of
Bristol, Dorothy Hodgkin
Building, Whitson Street,
Bristol BS1 3NY, UK;
a.levy@bris.ac.uk

Table 1 Diagnosis of pituitary hormone deficiency

- ▶ **Glucocorticoid deficiency:**
Provided the patient has not taken exogenous glucocorticoids for at least 24 hours, a single plasma cortisol of <495 nmol/l measured one hour after a 250 µg intramuscular or intravenous bolus of adrenocorticotrophic hormone (ACTH, synacthen) indicates deficiency
- ▶ **Thyroid hormone deficiency:**
Free thyroxine (FT4) at or below the bottom of the normal range indicates deficiency: thyrotrophin values (TSH) are frequently within the "normal" range. A patient who is listless and gaining weight and whose FT4 and TSH are both near the lower limit of the normal ranges is likely to have secondary hypothyroidism and may benefit from a trial of thyroxine replacement
- ▶ **Sex hormone deficiency:**
Amenorrhoea in women and tiredness and loss of libido in men. Erectile function is often impaired and both sexes become infertile with suppressed or low normal concentrations of gonadotrophins (FSH and LH). In women, no confirmatory tests are usually necessary. In men, low circulating testosterone concentrations indicate deficiency
- ▶ **Growth hormone deficiency:**
The peak GH secretory response to a bolus of GH releasing hormone (1 µg/kg) given at the beginning of a 30 minute infusion of arginine (0.5 g/kg) is a safer and more potent GH secretagogue than insulin induced hypoglycaemia.¹¹ Measured every 15 minutes for 2 hours from time zero, failure to reach 20 mU/l (in our practice) indicates deficiency
- ▶ **Vasopressin deficiency:**
Transient polyuria, nocturia, and thirst following pituitary surgery is usually sufficient to make the diagnosis of diabetes insipidus. Formal water deprivation testing is rarely required

FSH, follicle stimulating hormone; GH, growth hormone; LH, luteinising hormone; TSH, thyroid stimulating hormone.

PROLACTINOMAS

Diagnosis

Oligomenorrhoea or amenorrhoea, reduced fertility, loss of libido, erectile dysfunction and in the oestrogen primed female breast, galactorrhoea, are typical.

By definition, microprolactinomas are less than 10 mm in diameter and are contained entirely within the intact sella turcica (fig 1). Microprolactinomas remain unchanged or decrease in size over time, with a small chance of complete, spontaneous resolution. Significant expansion is very rare. Circulating prolactin concentrations are often indistinguishable from those seen in other common conditions (table 2).

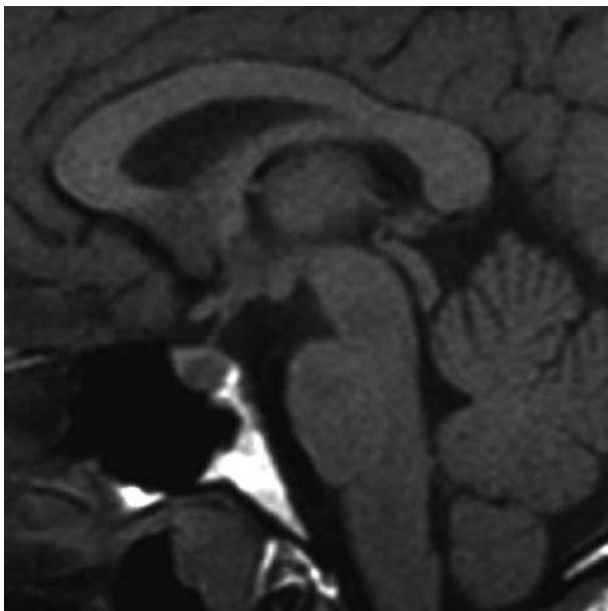


Figure 1 Magnetic resonance image (MRI) of a microprolactinoma.

Table 2 Typical causes of mild hyperprolactinaemia mimicking microprolactinoma

- ▶ Hormonally inactive pituitary adenoma causing pituitary stalk compression
- ▶ Mammotroph adenoma (that is, growth hormone adenoma co-expressing prolactin)
- ▶ Antidopaminergic drugs (metoclopramide, domperidone, risperidone, sulpiride, phenothiazines, SSRIs)*
- ▶ Stress (for example, acute anxiety about impending venesection)*
- ▶ Polycystic ovarian syndrome*

*Especially in the presence of a coincidental microadenoma. SSRIs, selective serotonin reuptake inhibitors.

Macroprolactinoma

A prolactin value of ≥ 5000 mU/l is highly suggestive of a macroprolactinoma (fig 2). In very large pituitary adenomas, the laboratory should be specifically asked to dilute the preoperative prolactin serum sample to disclose the "high dose hook effect"—responsible for the falsely low prolactin in the two-site chemiluminometric assay found in up to 14% of cases.

A macroprolactinoma producing relatively low concentrations of prolactin (for example, 2000–4000 IU/l) may be indistinguishable from an endocrinologically inactive adenoma reducing dopamine flow to normal lactotrophs by compressing the pituitary stalk. Dopamine analogues reduce prolactin values in both and careful follow up in the longer term is required to identify behavioural differences, such as size reduction in a macroprolactinoma and slow growth in an endocrinologically inactive adenoma. In this scenario, a degree of diagnostic uncertainty is more acceptable than potentially unnecessary surgery.

Treatment

The vast majority of microprolactinomas and macroprolactinomas respond to ergot derived dopamine receptor agonists

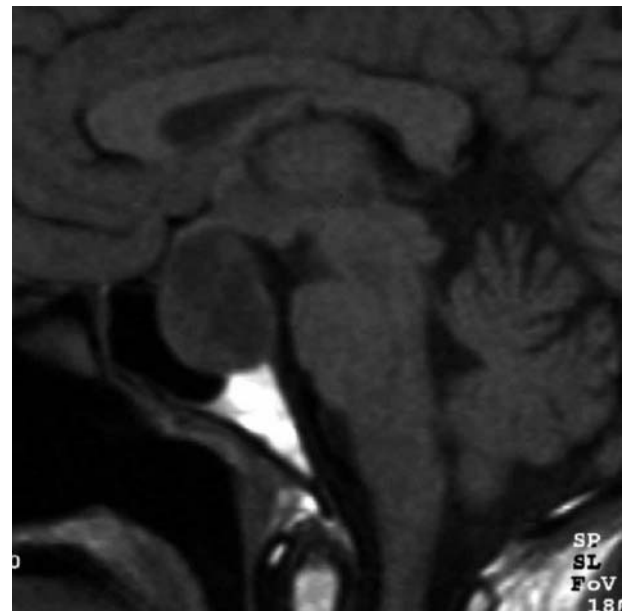

Figure 2 MRI of a typical macroadenoma displacing and compressing the optic chiasm. The lower limit of the sella is typically level with the junction of the upper third and lower two thirds of the pons. In this case, the floor of the fossa may also be eroded.

such as cabergoline or bromocriptine. For many patients cabergoline has a more satisfactory side effect profile than bromocriptine, and at doses used for pituitary disease, psychoses and clinically significant fibrotic reactions are rare. Microprolactinomas change little in size with treatment but macroprolactinomas can be expected to shrink, sometimes quite dramatically. Although not teratogenic, dopamine receptor agonists are withdrawn as soon as pregnancy is confirmed and visual fields checked at intervals to identify the small proportion of women whose macroprolactinomas enlarge significantly.

It is important that the objectives of microprolactinoma treatment are kept in mind. In a patient with galactorrhoea, reducing prolactin concentrations with dopamine analogues is clearly central, but for women in whom the problem of hyperprolactinaemia relates only to suppressed oestrogen values, sex hormone replacement may be more appropriate. No treatment at all, or specific management of osteoporotic risk with selective oestrogen receptor modulators or bisphosphonates, for example, may be a perfectly acceptable option for otherwise asymptomatic post-menopausal women. There is no link between oestrogen use and prolactinoma formation and no evidence that concurrent oestrogen use worsens prolactinoma outlook.¹

Surgery is reserved for occasional patients who cannot tolerate dopamine agonists, who suffer pituitary apoplexy during treatment, or whose macroprolactinomas are otherwise non-responsive.

SOMATOTROPH ADENOMAS

Diagnosis

The diagnosis of active acromegaly is based on continuing somatic changes (table 3) and confirmed by finding two or more raised basal growth hormone (GH) values. A random growth hormone of < 1 mU/l (< 0.4 µg/l) with normal insulin-like growth factor 1 (IGF-1) essentially excludes active disease. In borderline cases the diagnosis can be established by demonstrating failure of a 75 g glucose load to suppress GH concentrations to < 2 mU/l during the subsequent two hours. An MRI of the pituitary usually discloses the adenoma.

TREATMENT FOR ACROMEGALY

Surgery

Microadenectomy or macroadenoma decompression is approached transsphenoidally in most patients. Increasingly,

endoscopic surgery allows the entire surgical field to be viewed and tumour tissue that would otherwise be inaccessible with rigid instruments to be safely resected. Nevertheless, complete return of GH concentrations to normal is not often achieved.²

Specific complications of transsphenoidal surgery such as CSF leak, hypopituitarism, and some degree of nasal discomfort are for the most part predictable. Biochemically, transient diabetes insipidus is unusual after transsphenoidal surgery but mild SIADH (syndrome of inappropriate vasopressin secretion) for a week or two postoperatively is relatively common. Glucocorticoid cover for potential secondary hypoadrenocorticalism is unnecessary.

The efficacy of pituitary surgery rests entirely with the innate skill of the surgeon. This can be honed by experience and polished by continued practice but cannot be achieved through enthusiasm alone. In the opinion of the author, moral responsibility for the outcome of surgery rests with the referring physician.

Radiotherapy

The two- to fivefold reduction in pituitary adenoma relapse rate³ offered by adjuvant LINAC radiotherapy is offset by the short term inconvenience of fractionated treatment, the slow rate of reduction of excessive hormone secretion, the risk of hypopituitarism, and the small but unequivocal increase in incidence of second tumours within the radiation field (up to 2% over 20 years). The principle disincentive, however, is the widespread perception, not supported by convincing data, that pituitary radiotherapy might adversely affect cognitive function and levels of anxiety and depression. As a result adjunctive radiotherapy is increasingly reserved for tumours that extend beyond the safe operative field and are thought to pose an ongoing threat. Gamma knife radiosurgery does not appear to be associated with significantly higher cure rates or fewer complications, but may be more convenient to deliver than conventional radiation.

Drug treatment

Somatostatin analogues

Parenteral long acting somatostatin analogues reduce IGF-1 concentrations to normal in up to two thirds of acromegalics, and in a minority, tumour volume diminishes. Symptoms of acromegaly such as headaches, sweating, and arthralgia decrease with treatment but the discomfort of

Table 3 Prominent symptoms of acromegaly

- ▶ Growth of hands and feet: successive wedding ring enlargements and requirement for wider and sometimes longer shoe fittings is typical
- ▶ Coarsening of facial features: enlargement of distal nasal cartilage leading to a slightly globular nasal shape, prominence and eversion of the lower lip, and an increasing tendency to bite the tongue and cheeks
- ▶ Carpal tunnel syndrome: bilateral and recurrent in untreated disease
- ▶ Snoring and obstructive sleep apnoea: a major problem sometimes requiring continuous positive airways pressure or surgery
- ▶ Jaw growth: prognathism, separation of teeth, malocclusion, and temporal joint arthralgia are common; restoration of occlusion by advancement of the maxilla rather than recession of the mandible reduces the chance of exacerbating obstructive sleep apnoea
- ▶ Osteoarthritis and arthralgia: premature and widespread, this is often a significant ongoing problem for patients that once established is not ameliorated by effective control of acromegaly
- ▶ Headache: occasionally dramatically responsive to somatostatin analogues, headaches affect at least 50% of acromegalics and closely mimic classical migraine, lateralised or global headaches, and tension headache
- ▶ Excessive sweating: a prominent and inexplicable symptom in some patients
- ▶ Dismorphophobia: a distressing preoccupation with defects in appearance

injections and gastrointestinal side effects such as colic, diarrhoea, or constipation can be limiting.⁴ Somatostatin analogue induced biliary abnormalities such as sediment, sludge, and gallstones rarely become symptomatic. Particularly if used first line, the cost of this treatment modality is a major consideration when long term disease control is being considered.

Dopamine analogues

Dopamine analogues are effective in reducing GH and IGF-1 in a minority of acromegalic patients. Cabergoline is more effective than bromocriptine and is said to be able to restore IGF-1 to within the normal range in a little over 35% of acromegalic patients.⁵

GH receptor antagonists

Pegvisomant is the first of a new class of GH receptor antagonists that work by inhibiting functional dimerisation of GH receptors. Preliminary results suggest that it may be the most effective medical treatment for acromegaly reported to date.⁶

Other treatments

Impaired glucose tolerance, hypertension, and hyperlipidaemia should be vigorously treated and great care taken to ensure that joints are suitably protected, particularly in the working population. Assistance from rheumatologists, chest physicians, and orthopaedic and maxillofacial surgeons may be required for treatment of arthritis, carpal tunnel syndrome, obstructive sleep apnoea, and prognathism.

Screening for malignancies

A consensus about cancer risk in acromegaly has yet to emerge, but data tend to support a real but relatively modest increase in colorectal cancer risk.⁷ Some centres screen acromegalic patients at diagnosis and offer a further colonoscopy at 55 years of age.

CORTICOTROPH ADENOMAS

Diagnosis

The lack of specificity of many of the phenotypic characteristics of Cushing's syndrome (table 4), quantitative rather than qualitative biochemical changes, and cyclical disease makes this one of the more absorbing pituitary adenoma pathologies to diagnose and manage effectively. Prognostic markers of the efficacy of treatment, the best of which is the

requirement for exogenous glucocorticoids for more than a year after surgical adenectomy, are relatively unreliable, and the significant relapse rate after seemingly adequate treatment encourages use of the term remission rather than cure.⁸

Some patients develop the neuropsychiatric and physical characteristics of Cushing's remarkably abruptly, but many seem unable to clearly identify a time before the onset of disease. Investigations seek firstly to confirm hypercortisolaemia, then to identify the source.

Establishment of hypercortisolaemia

The widely used low dose overnight dexamethasone suppression test is non-specific and insensitive. The best screening test for hypercortisolaemia currently available is the 24 hour urine-free cortisol (UFC), and the definitive test is the dexamethasone suppressed corticotrophin releasing hormone (CRH) test.⁹ Patients are given 8 × 0.5 mg dexamethasone tablets to take at six hourly intervals at home starting at midday and ending two days later at 6 am. Two hours after the last dose of dexamethasone, a 100 µg bolus of CRH (strictly 1 µg/kg) is given intravenously and 15 minutes later a single blood cortisol of > 38 nmol/l distinguishes hypercortisolaemia from pseudo-Cushing's and normal subjects. The source of hypercortisolaemia is established as described (table 5).

Treatment

Surgery

Transsphenoidal adenectomy, sometimes preceded in florid disease by several weeks of medical management, is the treatment of choice. Success is often accompanied by a period of dry, peeling skin and postoperative requirement for exogenous glucocorticoids. If hypercortisolaemia persists, early repeat exploration and/or radiotherapy or laparoscopic bilateral adrenalectomy may be required.

Drugs

Metyrapone or ketoconazole (an inhibitor of sterol synthesis in fungi that also blocks mitochondrial P450 dependent enzyme systems) are titrated against cortisol values. Mitotane and aminoglutethimide are less widely used. In acute steroid psychoses or when a patient is unable to tolerate oral treatment, the intravenous inducing agent etomidate at 1/30th of its anaesthetic dose is dramatically effective.

Table 4 Some relatively specific clinical characteristics of Cushing's syndrome

- ▶ Proximal myopathy: present in only 20% of patients, but a relatively specific sign best elicited by asking patients to stand from sitting without using their hands; standing from squatting is impaired in simple obesity
- ▶ Centripetal fat distribution: the fat pad over the upper back and filling in of the temporal and supraclavicular fossae is more typical of hypercortisolaemia than simple obesity
- ▶ Neuropsychiatric symptoms: impairment of short term memory and exaggeration of premonitory personality traits; happy people become very happy and vice versa
- ▶ Striae: present in simple obesity, but dark purple striae 1 cm across, distributed over the buttocks, arms, and breasts as well as the lower abdomen, suggest hypercortisolaemia
- ▶ Easy bruising: patients often acknowledge this when asked but bruises are rarely evident in clinic
- ▶ Skin thinning: this is not prominent in pituitary dependent Cushing's as ACTH driven adrenal androgen production is protective
- ▶ Hirsutism: hypercortisolaemia is associated with hypertrichosis—that is, increased hair growth located in non-androgen dependent areas, as well as androgen dependent (male pattern) hirsutism
- ▶ Osteopenia, if demonstrable on DEXA scanning, may help distinguish hypercortisolaemia from obesity, where bone mineral density tends to be well preserved.

DEXA, dual energy x ray absorptiometry.

THYROTROPHIN AND OTHER GLYCOPEPTIDE HORMONE SECRETING ADENOMAS

Bioactive glycopeptide hormone secretion is rare. Thyrotrophin (TSH secreting) pituitary adenomas are characterised by hyperthyroidism without TSH suppression. In many cases TSH concentrations are within the “normal” range or only minimally raised. Antithyroid treatment is inappropriate and tends to provoke further growth of these relatively aggressive lesions. Although usually sensitive to somatostatin analogues, the efficacy of medical treatment tends to wane with time.

PITUITARY APOPLEXY

Haemorrhage or infarction of the pituitary may be clinically benign or present catastrophically with severe headache, meningism, vomiting, reduction in visual fields, diplopia, impairment of consciousness, or death. It frequently mimics other intracranial pathologies and a high index of suspicion is required, particularly as CT identifies pituitary haemorrhage in only about half of those scanned. The normal pituitary can be affected under some circumstances, but endocrinologically inactive adenomas underlie at least half of all cases. The necessity and urgency of surgical decompression depends very much on the presence, and rate and direction of change, of visual symptoms. Many cases are managed entirely conservatively, with replacement of pituitary hormones if and when required.

LYMPHOCYTIC HYPOPHYSITIS

Lymphocytic hypophysitis is a rare condition typically associated with pregnancy but described in both sexes and most ages. The pituitary gland is expanded by an infiltrate of lymphocytes, plasma cells, and macrophages leading in a proportion of cases to impaired pituitary function.¹⁰ The diagnosis is worth considering in the differential diagnosis of a macroadenoma presenting during pregnancy or within six months of delivery as spontaneous resolution of the mass, but not necessarily the associated hypopituitarism, may occur. Although believed to be mediated by autoimmune mechanisms, there is no evidence that immunosuppressive treatment alters the outcome of presumed or histologically confirmed disease, or that anti-pituitary antibody measurements are prognostically or diagnostically useful.

CRANIOPHARYNGIOMA

Craniopharyngiomas are calcified, cystic, suprasellar tumours arising from epithelial and squamous cell remnants of the craniopharyngeal duct, which closes in early pituitary embryogenesis to give rise to Rathke’s pouch by disconnecting Rathke’s cleft from the stomodeum (fig 3). They usually present as one or more cysts filled with oily proteinaceous

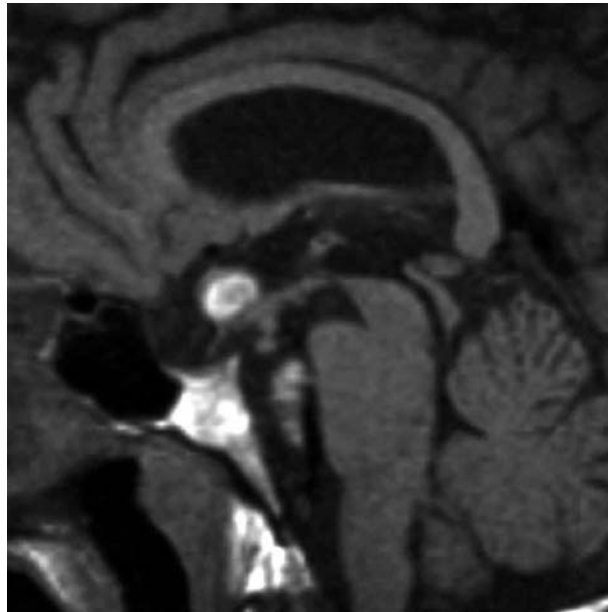


Figure 3 Midline MRI of a craniopharyngioma remnant.

material rich in cholesterol crystals, arising in the region of the pituitary stalk and projecting into the hypothalamus and expanding horizontally, apparently along the paths of least resistance.

Craniopharyngiomas have a bimodal distribution with a peak in childhood around the age of 9 years and a further peak in late middle age. Typical presenting symptoms in paediatric practice are headache, vomiting, visual disturbance, diabetes insipidus, and growth deceleration, which lead to delayed puberty, short stature, and panhypopituitarism. Owing to the proximity of these tumours to the chiasm and hypothalamus, their size before diagnosis (often exceeding 3 cm in diameter) and their tendency to recur, visual deficits, permanent diabetes insipidus, panhypopituitarism, and hypothalamic injury with obesity, somnolence, and loss of volition are relatively common. Adjunctive radiotherapy following partial resection reduces recurrence rate.

RATHKE CLEFT CYST

When the rostral invagination of the stomodeum, Rathke’s pouch, is pinched off during embryogenesis, the remaining vesicular structure often involutes completely. Remnants may persist as a cleft lined by cuboidal epithelium that can expand to form an uncalcified cystic or polycystic lesion with intra- and suprasellar components. These lesions mimic endocrinologically inactive adenomas or craniopharyngiomas

Table 5 Identification of the source of hypercortisolaemia

- ▶ Dexamethasone suppression: any degree of suppression of circulating cortisol in response to dexamethasone suggests pituitary dependent disease
- ▶ ACTH: high values suggest ectopic ACTH secretion (such as lung or pancreatic carcinoids) and undetectable ACTH suggests adrenal dependent disease; in pituitary dependent disease values are often normal or moderately elevated, but may be undetectable
- ▶ MRI: incidental pituitary lesions ≤ 3 mm in diameter are present in almost 10% of the general population; conversely, pituitary MRI is normal in 20% of proven Cushing’s disease—hence the exhortation “do not use a localising procedure before you’ve carried out a diagnostic test”
- ▶ Inferior petrosal sinus sampling with CRH stimulation: a central to peripheral ACTH ratio of more than 2, increasing to more than 3 following a peripheral CRH bolus, is highly specific for pituitary dependent disease

ACTH, adrenocorticotrophic hormone; CRH, corticotrophin releasing hormone; MRI, magnetic resonance imaging.

Table 6 Pituitary hormone replacement

- ▶ **Glucocorticoid:**
Hydrocortisone 15 mg am and a further 5 mg no later than 4 pm (or 10 mg on waking, 5 mg at lunchtime and 5 mg at 4 pm) to mimic normal diurnal variation in circulating cortisol. Patients are asked to double the dose for 2–3 days if stressed physically or psychologically. In practice, however, physiologically significant hypoadrenalism (adrenal crisis) in secondary hypoadrenalism is rare
- ▶ **Thyroid hormone:**
L-thyroxine 100–125 µg daily as a single dose. Average replacement is 112 ± 19 µg daily
- ▶ **Sex hormones:**
Women
If fertility is not required, sex hormone replacement with cyclical oestrogens and progestogens is used until the age of the natural menopause (50–51 years). If fertility is required gonadotrophin treatment should be coordinated by a specialist centre
Men
Testosterone is replaced as a mixture of testosterone esters (Sustanon intramuscularly) or testosterone enanthate (100 mg every 2 weeks or 250 mg every 3 weeks). Testosterone implants last for up to 4–5 months. Transdermal gel or patches, or oral testosterone undecanoate, are generally less effective but may suit some patients
If fertility is required, spermatogenesis can be induced with chorionic gonadotrophin (LH) and FSH/human menopausal gonadotrophin injections 3 × weekly for at least 6 months. Semen samples can be frozen after successful induction
- ▶ **Growth hormone:**
GH is given by daily subcutaneous injection, titrated over 3 months to bring IGF-1 concentrations into the middle of the normal range and continued for a further 6 months. If an improvement of more than 7 points on the QoL-AGHDA questionnaire is elicited, the treatment can be continued in the longer term. Generally, symptoms of deficiency are non-specific, and the benefits of replacement subtle, slow to develop but nevertheless tangible (internet search term: “NICE start page” or “National Institute for Clinical Excellence”)
- ▶ **Vasopressin:**
DDAVP nasal spray (1–3 puffs daily) or tablets (200 µg once or twice daily) is not strictly necessary, as diabetes insipidus following pituitary surgery is usually mild and transient, but is useful temporarily if the patient is uncomfortable. Patients should be warned about over-replacement and treatment withdrawn at intervals to see whether the condition has resolved, as it does in most cases

DDAVP, 1-deamino(8-D-arginine) vasopressin; FSH, follicle stimulating hormone; GH, growth hormone; LH, luteinising hormone; QoL-AGHDA, quality of life adult growth hormone deficiency assessment.

but have a particularly low recurrence rate after partial excision.

FAMILIAL CANCER SYNDROME INVOLVING THE PITUITARY

There are three familial conditions associated with pituitary adenoma formation: multiple endocrine neoplasia type 1, Carney complex, and isolated familial acromegaly.¹

Multiple endocrine neoplasia type 1 (MEN-1)

This is an autosomal dominant condition associated principally with tumours of the parathyroid, pancreas and, in approximately 45% of patients, the pituitary. Collagenomas, lipomas, lentiginosis, and multiple angiofibromas of the dermis are also common and MEN-1 kindreds are at increased risk of thyroid epithelioma, adrenal gland, foregut carcinoid tumours, and tumours of the central nervous system, such as spinal ependymoma.

Carney complex

This is a rare autosomal dominant condition characterised by myxomas of the heart, skin, and breast, spotty skin pigmentation, schwannomas, ovarian cysts, adrenal, testicular and thyroid tumours, and in 6–21% of patients, pituitary adenomas.

Isolated familial acromegaly

These individuals tend to develop acromegaly or gigantism at a relatively young age. The pattern of chromosomal loss of heterozygosity has some similarities to those found in MEN-1 and Carney complex.

A guide to diagnosis of pituitary hormone deficiency and replacement is shown in table 6.

REFERENCES

- 1 Levy A, Lightman SL. Molecular defects in the pathogenesis of pituitary tumors. *Frontiers in Neuroendocrinology* 2003;**24**:94–127.
- ▶ **A comprehensive review of pituitary tumour pathogenesis, including the familial pituitary cancer syndromes.**
- 2 Melmed S, Vance ML, Barkan AL, et al. Current status and future opportunities for controlling acromegaly. *Pituitary* 2002;**5**:185–96.
- ▶ **An overview of treatment options in acromegaly.**
- 3 Marcou Y, Plowman PN. Stereotactic radiosurgery for pituitary adenomas. *Trends in Endocrinology and Metabolism* 2000;**11**:132–7.
- ▶ **A review of the efficacy of pituitary radiotherapy.**
- 4 McKeage K, Cheer S, Wagstaff AJ. Octreotide long-acting release (LAR): a review of its use in the management of acromegaly. *Drugs* 2003;**63**:247–9.
- ▶ **A review of somatostatin analogue efficacy in acromegaly.**
- 5 Racine MS, Barkan AL. Medical management of growth hormone-secreting pituitary adenomas. *Pituitary* 2002;**5**:67–76.
- ▶ **A review of medical treatment for acromegaly.**
- 6 Stewart PM. Pegvisomant: an advance in clinical efficacy in acromegaly. *Eur J Endocrinol* 2003;**148**(suppl 2):S27–32.
- ▶ **A review of adjuvant medical treatment for acromegaly, including pegvisomant.**
- 7 Orme SM, McNally RJ, Cartwright RA, et al. Mortality and cancer incidence in acromegaly: a retrospective cohort study. United Kingdom acromegaly study group. *J Clin Endocrinol Metab* 1998;**83**:2730–4.
- ▶ **Retrospective cohort study of cancer risk in 1362 patients with acromegaly.**
- 8 Invitti C, Giraldi FP, de Martin M, et al. Diagnosis and management of Cushing's syndrome: results of an Italian multicentre study. Study group of the Italian Society of Endocrinology on the pathophysiology of the hypothalamic-pituitary-adrenal axis. *J Clin Endocrinol Metab* 1999;**84**:440–8.
- ▶ **Retrospective multicentre study of 426 patients with Cushing's syndrome.**
- 9 Yanovski JA, Cutler GBJ, Chrousos GP, et al. Corticotropin-releasing hormone stimulation following low-dose dexamethasone administration. A new test to distinguish Cushing's syndrome from pseudo-Cushing's states. *JAMA* 1993;**269**:2232–8.
- ▶ **Description of a highly sensitive and specific test of hypercortisolaemia.**
- 10 Bellastella A, Bizzarro A, Coronella C, et al. Lymphocytic hypophysitis: a rare or underestimated disease? *Eur J Endocrinol* 2003;**149**:363–76.
- ▶ **Well referenced review of lymphocytic hypophysitis.**
- 11 Biller BM, Samuels MH, Zagar A, et al. Sensitivity and specificity of six tests for the diagnosis of adult GH deficiency. *J Clin Endocrinol Metab* 2002;**87**:2067–79.