

Familial persistent ductus arteriosus

R P MARTIN, N R BANNER, AND R RADLEY-SMITH

Department of Paediatric Cardiology, Harefield Hospital, Middlesex

SUMMARY The occurrence of isolated persistent ductus arteriosus in three generations of one family with surgical correction is described. The high incidence of the malformation in this family suggests autosomal dominant inheritance rather than a polygenic mode of inheritance.

It is generally accepted that the inherited contribution to most forms of congenital heart disease has a polygenic mode of transmission. The familial occurrence of persistent ductus arteriosus is well recognised. Two large surveys of relatives of patients with persistent ductus arteriosus showed a low recurrence rate of between 1 and 2.5% in the subsequent generation.^{1,2} Case reports on individual families, however, have shown a much higher recurrence rate, and while this might represent case clustering with a polygenic inheritance, different forms of inheritance probably occur in these families.

Documented reports of persistent ductus arteriosus in three generations are rare;³ this report details a family with a high incidence of persistent ductus arteriosus, involving three generations in the absence of consanguinity. The early generations of this family were previously reported by Burman.⁴

Case reports

Two siblings presented to our unit with isolated persistent ductus arteriosus, and the strong family history obtained led to an investigation of the family's medical records. The Figure shows the pedigree of this family. The two affected children (IV₁ and IV₂) are the only children of the non-consanguineous marriage of III₆ and III₇. The girl (IV₁) presented at 3 years with an asymptomatic cardiac murmur. There was a high volume pulse and the typical continuous murmur of a persistent ductus arteriosus. Echocardiography and cardiac catheterisation confirmed the presence of isolated persistent ductus arteriosus with a pulmonary artery pressure of 24/10 mm Hg (mean pressure 13 mm Hg). The persistent ductus arteriosus was ligated and divided, and the girl remains asymptomatic with no cardiac murmurs.

The boy (IV₂) presented at 4 months with failure

to thrive, vomiting, and breathlessness during feeding. Examination revealed a collapsing pulse with clinical evidence of left ventricular hypertrophy. There was a harsh, long, grade 4/6 systolic murmur audible at the left sternal edge and pulmonary area with no diastolic murmur. A loud third heart sound was present with accentuation of the pulmonary component of the second sound. Investigation showed isolated persistent ductus arteriosus with a large left to right shunt and pulmonary hypertension. The pulmonary artery pressure was 50/22 (mean 30) mm Hg compared with an aortic pressure of 90/25 (mean 44) mm Hg. At the age of 6 months ligation and division of a short wide persistent ductus arteriosus was performed. He is now asymptomatic with a quiet pulmonary ejection murmur.

The mother (III₆) of these children is 25 years old and presented in infancy with cardiac failure associated with a persistent ductus arteriosus. Ligation of the ductus was performed at 1 year and she is now asymptomatic and normal on examination. She is the only child resulting from the non-consanguineous marriage of II₅ and II₆. Her father (II₅) had isolated persistent ductus arteriosus with appreciable pulmonary hypertension confirmed by cardiac catheterisation. In 1957, at the age of 28 years,

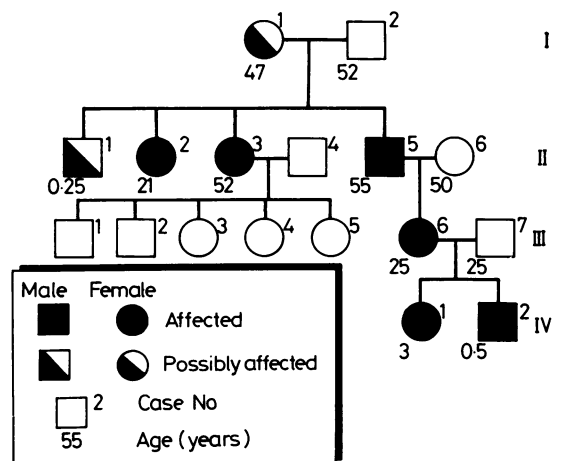


Figure Family history of two siblings who presented with isolated patent ductus arteriosus.

ligation of the ductus was performed and he lived until 1984 when he died of a non-cardiac cause.

He (II₅) had three siblings and both his sisters (II₂ and II₃) had surgically proved persistent ductus arteriosus. The first sister (II₂) had a persistent ductus arteriosus ligated in 1954 at 21 years. She died in the early postoperative period and it was considered on clinical grounds that she had established pulmonary vascular disease. The other sister (II₃) had a persistent ductus arteriosus diagnosed at the age of 24 and ductal ligation was performed in 1957. She is alive and well with five unaffected children. The other sibling (II₁) died during the early 1930s when 3 months old. The certified cause of death was acute bronchitis and marasmus. No cardiac abnormality was diagnosed.

There are no known cases of persistent ductus arteriosus in previous generations. The great grandfather (I₂) died at the age of 52 from pneumonia. The great grandmother (I₁) died at the age of 47 from cardiac failure. She presented in atrial fibrillation with peripheral and pulmonary oedema. No murmurs were documented, but a mitral valve lesion was suspected. Chest x ray showed considerable cardiomegaly with unusual 'right atrial enlargement'. No autopsy information is available. It is possible that her cardiac condition was due to Eisenmenger's syndrome related to a persistent ductus arteriosus.

Discussion

Persistent ductus arteriosus is a heterogenous condition. It may occur in association with complex congenital heart disease, with multiple abnormalities in other systems, or as an isolated defect. Environmental factors play a role in its pathogenesis—for example, in the maternal rubella syndrome or hypoxia (high altitude or neonatal respiratory distress syndrome)—and a genetic contribution is well recognised.

Large surveys of patients with a persistent ductus arteriosus show a low recurrence rate in siblings and children with a female predominance^{1 2} consistent with a polygenic mode of inheritance. Animal studies have supported the hypothesis of polygenic inheritance.⁵ A number of case reports have documented families where the incidence of per-

sistent ductus arteriosus is higher than might be expected with a polygenic mode of inheritance. Most reports have concerned normal parents with multiple affected siblings,⁶ and while this might represent case clustering with polygenic inheritance, it is possible that autosomal recessive inheritance is operating. The family in this report has well documented cases of isolated persistent ductus arteriosus with high frequency in three generations. Both males and females are affected in the absence of consanguinity. This pattern of inheritance is highly suggestive of autosomal dominant inheritance and is less likely to occur with polygenic inheritance.

This pattern of inheritance is uncommon as no similar families have been reported from this country. Burman's report concerned the same family when persistent ductus arteriosus was documented in two generations.⁴

Thus, while most cases of persistent ductus arteriosus seem to be multifactorial in origin with polygenic heredity influences interacting with environmental factors, a subgroup of patients exist with a much stronger genetic component. The recognition of such subgroups has obvious importance for the counselling of the couples concerned regarding risks of recurrence and in the wider context reminds us that what seems to be a single anatomical lesion is actually a heterogenous condition with diverse environmental and genetic causes.

References

- 1 Zetterquist P. *A clinical and genetic study of congenital heart defects*. Sweden: University of Uppsala, 1972:1-80.
- 2 Wilkins JL. Risks of offspring of patients with patent ductus arteriosus. *J Med Genet* 1969;6:1-3.
- 3 Lynch HT, Grisson RL, Magnuson CR, Krush A. Patent ductus arteriosus; study of two families. *JAMA* 1965;194(2):115-8.
- 4 Burman D. Familial patent ductus arteriosus. *Br Heart J* 1961;23:603-4.
- 5 Patterson DF, Pyle RL, Buchanan JW, Trautvetter E, Abt DA. Hereditary patent ductus arteriosus and its sequelae in the dog. *Circ Res* 1971;29:1-13.
- 6 Wei J, Chang YC, Ko GC, Shieh SM. Familial patent ductus arteriosus. *Am J Cardiol* 1984;54:235-6.

Correspondence to Dr R Radley-Smith, Department of Paediatric Cardiology, Harefield Hospital, Harefield, Middlesex UB9 6JH

Received 19 May 1986