

Computed tomography in severe protein energy malnutrition

K C HOUSEHAM AND J F K DE VILLIERS

Departments of Paediatrics and Child Health and Diagnostic Radiology, Faculty of Medicine, University of the Orange Free State, Bloemfontein, Republic of South Africa

SUMMARY Computed tomography of the brain was performed on eight children aged 1 to 4 years with severe protein energy malnutrition. Clinical features typical of kwashiorkor were present in all the children studied.

Severe cerebral atrophy or brain shrinkage according to standard radiological criteria was present in every case. The findings of this study suggest considerable cerebral insult associated with severe protein energy malnutrition.

The possible long term effect of protein energy malnutrition on the developing brain remains a controversial issue. Stoch and Smythe, in a now famous series of articles, showed retardation of intellect and reduced head circumference that indicated impaired brain growth in long term follow up of individuals who had been severely undernourished during infancy.¹⁻⁴ Moodie *et al* in a 15 year follow up of patients with kwashiorkor in Cape Town, South Africa, found that both patients and controls had lower than average scholastic achievement and problems with social adjustment.⁵ Their findings suggested that other environmental factors have greater effect. Dobbins, in a recent review of infant nutrition and its effect on later achievement, concluded that brain growth is indissolubly linked with body growth.⁶ Promotion of somatic growth in the period before the second and even third birthday is important in his opinion to ensure good brain growth.

Severe cerebral atrophy was found initially on a computed tomogram of a child with kwashiorkor admitted to the paediatric wards of the Pelonomi Hospital in Bloemfontein. A review of the published works revealed that this finding had not been reported previously, although an echoencephalographic study had shown dilated ventricles in infants with kwashiorkor but not in infants with marasmus.⁷ Subsequent to this initial observation, a further seven children admitted with severe malnutrition and clinical signs of kwashiorkor or marasmic kwashiorkor were examined by computed tomography of the brain.

Patients and methods

Eight children aged 1 to 4 years (median 17.5 months) were studied. All but one were boys and all were admitted primarily for management of severe protein energy malnutrition.

All were growth retarded, with growth variables less than the third centile of the National Center for Health Statistics⁸ (Table). In four the body mass was less than 60% of expected weight for age, indicating severe malnutrition or marasmic kwashiorkor. Head circumference was measured in five and was normal for age in four. In the other child the head circumference was appropriate for mass and height, both of which were far below the normal for age. In

Table Nutritional and growth variables in the eight cases admitted primarily for management of severe protein energy malnutrition

Case No	Variable		
	Mass (NCHS centile)	Head circumference (NCHS centile)	Albumin (g/l)
1	<3	N	15
2	<60% EW	<3	18
3	<3	N	14
4	<3	—	18
5	<60% EW	N	10
6	<60% EW	—	23
7	<3	N	18
8	<60% EW	—	18

NCHS=National Center for Health Statistics;⁸ EW=expected weight for age; N=normal.

three patients the head circumference was not recorded but head size was regarded as appropriate for body size on clinical examination. Serum albumin concentrations were extremely low in all eight patients and in seven were below 20 g/l.

All had clinical features of kwashiorkor, such as generalised oedema, skin lesions, and hair changes. All were typically apathetic and withdrawn on admission. One child had generalised convulsions intermittently over a period of five days after admission, despite treatment with anticonvulsants. Examination of cerebrospinal fluid and serum biochemistry showed no abnormality, and no definite cause for the convulsions was found. Another child had shortlived convulsions on admission when critically ill with pneumonia and presumed septicaemia. At this time he had an uncompensated metabolic acidosis (pH 7.17) and hyponatraemia (sodium concentration 108 mmol/l). Hyponatraemia was presumed to be the cause of the convulsion.

Most (six of the eight) had diarrhoea on admission, but this responded to standard treatment and had resolved at the time of computed tomography. One patient, aged 4 years, was admitted initially for kwashiorkor, but further investigation revealed polyposis coli with juvenile polyps that affected the entire colon. He had a severe protein losing enteropathy, which resulted in his malnourished state.

At the time of computed tomography all were stable clinically, were normally hydrated, and had normal acid base and electrolyte values. Most were scanned one to two weeks after admission. The tomograms of the brain were performed according to standard procedure without sedation or contrast. Consent for computed tomography was obtained from the parents in each case.

Results

The findings on computed tomography were identical in all eight children. There was pronounced enlargement of the ventricles and cerebral sulci (Figures 1, 2, and 3), indicating a severe degree of cerebral atrophy or 'brain shrinkage'. The cerebellum was relatively spared (Fig. 4) and did not show the severe degree of volume loss seen in the cerebral hemispheres. No other abnormalities were evident on computed tomography.

All children were discharged after periods of admission to hospital of between four and six weeks, without gross neurological deficit, apart from the child with prolonged convulsions, who had residual spasticity. The child with juvenile polyposis was readmitted one month later, at which time a total

colectomy was performed. The protein losing enteropathy resolved postoperatively with improvement in the nutritional state. Long term follow up of these patients is not available.

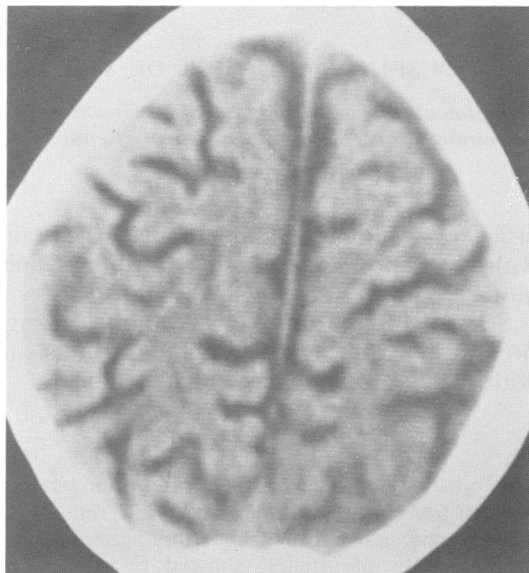


Fig. 1 *Computed tomogram of case 3, showing wide cerebral sulci.*

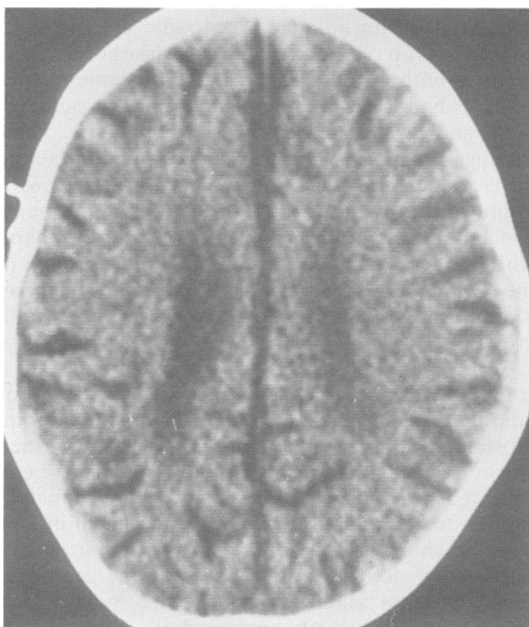


Fig. 2 *Computed tomogram of case 5, showing widened cerebral sulci and enlarged ventricles.*

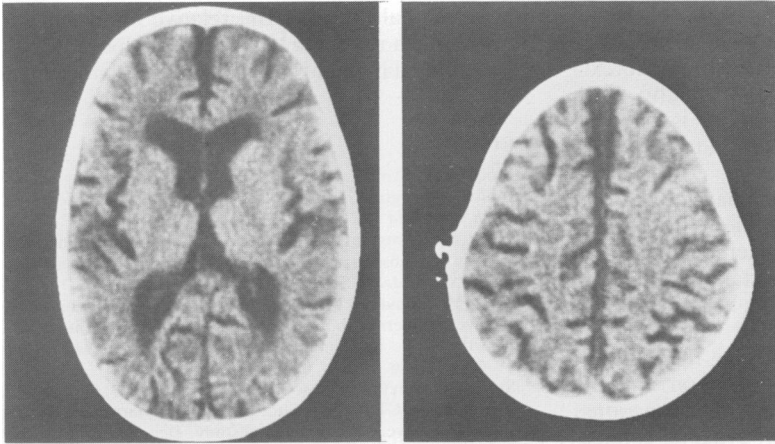


Fig. 3 *Computed tomograms of case 6, showing diffuse cerebral atrophy or shrinkage.*

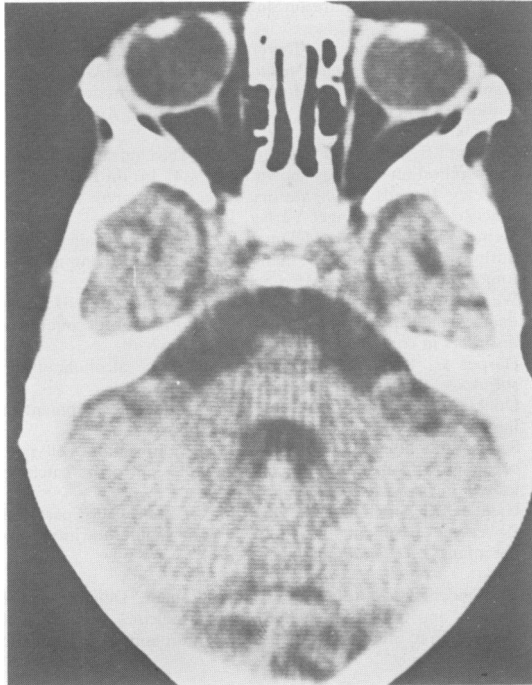


Fig 4 *Computed tomogram of case 6, showing relative sparing of the cerebellum.*

Discussion

The findings of this small study indicate a loss of brain volume associated with severe protein energy malnutrition in young children. The loss of brain volume is almost certainly the result of cerebral

atrophy rather than a temporary reduction in brain interstitial fluid volume. The latter could produce a similar though less severe picture. The fact that these patients were well hydrated with normal serum electrolyte concentrations and had a lowered serum colloid osmotic pressure due to hypoalbuminaemia at the time of computed tomography makes this unlikely in our opinion. It is accepted that cerebral atrophy could have resulted from metabolic, haemodynamic, or infective causes in these ill children. The fact that all had severe cerebral atrophy without evidence of any other abnormality, however, strongly suggests an association with the present of severe protein energy malnutrition, which was the common factor in all eight children.

Computed tomography allows the easy demonstration of ventricular size and the appearance of the cerebral sulci.⁹ Before the development of computed tomography the only reliable method of showing cerebral atrophy was pneumoencephalography. It must be emphasised that cerebral atrophy shown by computed tomography is a strictly morphological observation. There is not necessarily a direct correlation with the functional capacity of the brain.⁹

Studies have shown that intellectual functions may be well preserved in patients with radiologically or pathologically shown cerebral atrophy, while profoundly demented patients may have morphologically normal brains.⁹ Cerebral atrophy or loss of brain substance has been shown with advancing age in otherwise normal individuals.¹⁰ On the other hand, cerebral atrophy may be associated with pathological conditions such as neurodegenerative disorders—that is, mucopolysaccharidoses, mucopolipidoses, and the leucodystrophies—in

childhood.¹¹ Cerebral atrophy, or brain shrinkage, has been found to be associated with severe nutritional deficiency states in adults, such as anorexia nervosa and Wernicke's encephalopathy with alcohol abuse.¹² In these states there is selective reduction of white matter and reduced brain weight at postmortem examination.

What then is the importance of the brain shrinkage found in all eight children studied? It has been shown that the human brain undergoes a growth spurt from the mid-trimester of gestation until 2 or 3 years of age.¹³ Neuronal numbers reach their full complement between the 10th and 20th weeks of gestation. Increase in brain substance thereafter is the result of massive glial multiplication and the process of myelination.¹³ Of considerable functional importance is the development of synaptic connections and the growth of dendritic trees at this time. The considerable loss of brain substance and, by inference, myelin during this critical period shown in the malnourished children studied may indicate permanent damage to their developing brains. Animal experiments have shown that failure of synaptogenesis and reduction in the degree of dendritic complexity produced by undernutrition at this time is probably irreversible.¹⁴ Follow up studies of these children would be of interest to assess if the cerebral atrophy is a persistent finding. Such a long term study is currently being undertaken and we hope to report the findings in due course.

Of particular interest is the report that five of the 20 infants with severe malnutrition in infancy studied by Stoch and Smythe had abnormal computed tomograms at 20 to 24 years of age.¹⁵ The subtle signs of underdevelopment in the temporo-parietal region on computed tomography correlated positively with tests for disturbance of visuomotor organisation when compared with the remaining 15 individuals in whom computed tomograms were normal.

In conclusion, the findings of this small series further support the view that severe protein energy malnutrition in early childhood is a factor likely to result in reduced intellectual potential. Many environmental factors, including nutrition together with inherent genetic potential, play an important part in determining the final outcome of the

developmental process. The relative importance of nutrition with regard to the ultimate achievement of the individual in later life remains to be determined.

References

- 1 Stoch MB, Smythe PM. Does undernutrition during infancy inhibit brain growth and subsequent intellectual development? *Arch Dis Child* 1963;**38**:546-52.
- 2 Stoch MB, Smythe PM. The effect of undernutrition during infancy on subsequent brain growth and intellectual development. *S Afr Med J* 1967;**41**:1027-30.
- 3 Stoch MB, Smythe PM. 15 year developmental study on effects of severe undernutrition during infancy on subsequent physical growth and intellectual functioning. *Arch Dis Child* 1976;**51**:327-36.
- 4 Stoch MB, Smythe PM, Moodie AD, Bradshaw D. Psychosocial outcome and CT findings after gross undernourishment during infancy: a 20 year developmental study. *Dev Med Child Neurol* 1982;**24**:419-36.
- 5 Moodie AD, Bowic MD, Mann MD, Hansen JDL. A prospective 15 year follow-up study of kwashiorkor patients. *S Afr Med J* 1980;**58**:671-6.
- 6 Dobbing J. Infant nutrition and later achievement. *Nutr Rev* 1984;**42**:1-7.
- 7 Vahlquist B, Engsner G, Sjögren I. Malnutrition and size of the cerebral ventricles. *Acta Paediatr Scand* 1971;**60**:533-9.
- 8 Hamil PVV, Drizdl TA, Johnson CL, et al. Physical growth: National Center for Health Statistics percentiles. *Am J Clin Nutr* 1979;**32**:607-29.
- 9 Claveria LE, Moseley IF, Stevenson JF. The clinical significance of "cerebral atrophy" as shown by C.A.T. In: du Boulay GH, Moseley IF, eds. *Computerised axial tomography in clinical practice*. Berlin: Springer-Verlag, 1977:213-7.
- 10 Steiner I, Gomori JM, Melamed E. Progressive brain atrophy during normal aging in man: a quantitative computerised tomography study. *Isr J Med Sci* 1985;**21**:279-82.
- 11 Wende S, Ludwig B, Kishikawa T, et al. The value of CT in diagnosis and prognosis of different inborn neurodegenerative disorders in childhood. *J Neurol* 1984;**231**:57-70.
- 12 Harper C, Kril J. Pathological changes in alcoholic brain shrinkage. *Med J Aust* 1986;**144**:3-4.
- 13 Dobbing J, Sands J. Quantitative growth and development of human brain. *Arch Dis Child* 1973;**48**:757-67.
- 14 Sands J, Dobbing J, Gratrix CA. Cell number and cell size: organ growth and development and the control of catch-up growth in rats. *Lancet* 1979;ii:503-5.
- 15 Handler LC, Stoch MB, Smythe PM. CT brain scans: part of a 20-year development study following gross undernutrition during infancy. *Br J Radiol* 1981;**54**:953-4.

Correspondence to Professor K C Househam, Department of Paediatrics and Child Health, Faculty of Medicine, University of the Orange Free State, PO Box 339, Bloemfontein 9300, Republic of South Africa.

Received 12 January 1987