

Spastic hemiparesis and presumed prenatal embolisation

A A ASINDI, J B P STEPHENSON, AND D G YOUNG

Royal Hospital for Sick Children, Glasgow

SUMMARY An infant with clinical evidence of prenatal right subclavian arterial occlusion subsequently developed left hemiparesis with cystic infarction of the territory of the right middle cerebral artery. Perinatal strokes have not been reported with signs of limb ischaemia at birth; this finding may be a warning of possible simultaneous cerebral infarction.

Embolic^{1,2} and thrombotic³ events, as well as primary haemorrhagic lesions in association with congenital vascular malformations or tumours¹ cause strokes or cerebral infarction in neonates and the fetus.² Strokes occurring early in fetal life result in cortical neuronal loss and architectural changes ranging from hydranencephaly to porencephaly⁴; if they occur later in gestation or in infants born at term, they are characterised by cystic changes similar to those found after cerebral infarction in adults.¹ Infarction due to thromboembolic disease may not be limited to the brain; other organs or parts may be obstructed simultaneously.¹ The detection of external vascular obstruction such as peripheral cyanosis and an absent pulse in a limb should therefore raise the possibility that a vascular occlusion of a more vital part (such as the brain) had occurred at the same time.

We report an infant who presented with short lived cyanosis of the fingers and an absent pulse in the right upper limb; these were the only abnormal findings in the neonatal period but she was subsequently discovered to have had an infarct of the ipsilateral part of her brain.

Case report

A baby Asian girl was born in Scotland at term following an uneventful pregnancy and labour. The placenta was described as incomplete with ragged membranes. The antenatal history was unremarkable.

The infant's birth weight was 2760 g, length 55.5 cm, and head circumference 33.5 cm. Apgar scores were 9 and 10 at one and five minutes, respectively. Cyanosis of the right fingers and limitation of movement of the right upper limb were noted. No pulses were palpable in the right upper

limb but elsewhere they were normal. The arm and forearm circumferences, measured at midpoints, were 1.0 cm smaller on the right than on the left. The rest of the physical examination was unremarkable.

Plain radiographs of the cervical spine, chest, and right shoulder were normal. A full blood count on day 1 yielded the following results: haemoglobin concentration 223 g/l; packed cell volume 63%; white cell count $20.2 \times 10^9/l$ and platelet count $80 \times 10^9/l$. Viral studies were all negative. A splint was applied to the affected limb.

On the second day of life the tip of the right ring finger had become dark blue, though the other fingers were viable. Doppler ultrasound scan of the affected limb detected pulsation in the right subclavian artery to the outer border of the first rib, but not beyond. Over the next 72 hours the Doppler pulsation became audible in the axillary artery down to the radial artery and pulses could be felt. The infant remained otherwise well.

On discharge at the age of 2 weeks movements in the affected limb had considerably improved and all the pulses were palpable. The range of active movements of the left limbs were within normal limits. Because the improvement was so rapid no further investigations were carried out. The child subsequently failed to attend the follow up clinic.

At the age of 7 months the infant was brought back to the clinic the mother complaining that since the age of 4 months the child had had limited use of her left limbs; she had otherwise been well. A full neurological examination showed a left spastic hemiparesis and left hemianopia. The head circumference had dropped to the 10th centile having been on the 25th centile at birth. Her right upper limb was normal, as was her social behaviour. Computed tomography brain scan at the age of 7 months showed a cystic lesion in the area of the right middle cerebral artery with shrinkage of the right hemisphere (figure). When reviewed at 17 months of age, she could only move about by shuffling on her bottom but she appeared cognitively normal and no seizures had been observed.

Discussion

The presence of muscle wasting in the ischaemic

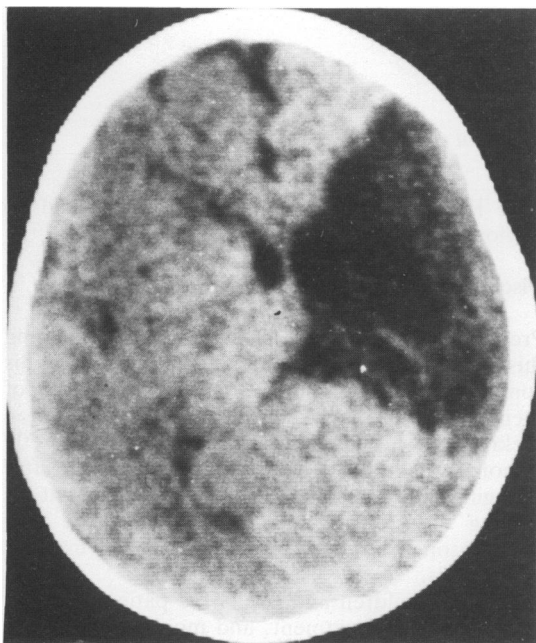


Figure Computed tomogram at 7 months old showing large cystic structure (presumed infarct) in area of right middle cerebral artery.

limb at birth strongly suggested a prenatal vascular occlusion. Although signs of cerebral impairment were not detectable during the neonatal period, we assume that the two ischaemic events occurred simultaneously in utero, as the presumed obstruction occurred in vessels derived from a common trunk—the innominate artery—through which the emboli could have passed. Apart from the limb ischaemia, the absence of signs of an acute illness after birth rule out the possibility of an intracranial event occurring postnatally.

It is known that cerebral infarcts occur in the fetus and in neonates.^{1,5} Cyanotic congenital heart disease,^{1,5} the placenta, and choriohaemangiomas have been suspected as sources of emboli. Factors which encourage formation of thrombi include asphyxia with hypotension, polycythaemia,³ and intravascular coagulopathy due to infection.¹

A case of prenatal stroke has been described in association with haemolytic anaemia of the fetus caused by Rhesus incompatibility.² In none of the three cases of prenatal infarcts described by Ment *et al* could the cause be explained.⁵ In our patient there were no maternal or fetal factors to establish the cause or the origin of the thrombi or emboli. Perhaps the placenta, which was described as

incomplete with a ragged membrane, could have trapped platelets as the infant's count was low.

Rapid lysis of thromboemboli occurs in neonates because of high concentrations of circulating fibrinolysins,⁶ which may explain why the pulse in the limb was established within 72 hours of birth.

Neonates with cerebrovascular accidents usually present with lethargy, hypotonia, cardiopulmonary failure, and death. Survivors go on to develop hemiplegia, epilepsy, and mental handicap.^{1,5} The degree of morbidity seems to be associated with the predisposing disease and not with the cerebral infarct per se.¹ In addition, the age at which symptoms appear varies. Most infants become symptomatic on the first day and die within the first month,^{1,5} but a few present later. One infant born at term in the series described by Ment *et al* developed poor vision and spastic quadriplegia at 9 weeks of age.⁵ Before that the infant had been asymptomatic apart from microcephaly noted at 2 weeks of age. Computed tomography of the brain at 4 weeks showed multiple prenatal infarcts. Our case was similar to this in that there was a delay in the evolution of the cerebral symptoms. The head circumference was normal at birth (25th centile) but had fallen to the 10th centile when she was reviewed at 7 months.

Barmada *et al* described two babies who died of cerebral infarcts in association with multiple extracranial thromboemboli, but made no attempt to describe the signs and symptoms noted before death.¹ We know of no reports associating signs of vascular occlusion of a limb at birth with a cerebral infarct and we recommend that infants with such signs should have an ultrasound scan or computed tomogram of the brain.

References

- 1 Barmada MA, Mooney J, Shuman RM. Cerebral infarcts with arterial occlusion in neonates. *Ann Neurol* 1979;6:495-502.
- 2 Clarke RM, Linell EA. A case report: prenatal occlusion of the internal carotid artery. *J Neurol Neurosurg Psychiatry* 1954;17:295-9.
- 3 Amit M, Camfield PR. Neonatal polycythaemia causing multiple cerebral infarcts. *Arch Neurol* 1980;37:109-10.
- 4 Myers RE. Experimental models of perinatal brain damage: relevance of human pathology in Gluck L, ed. *Intrauterine asphyxia and the developing fetal brain*. Chicago: Year Book Medical Publishers, 1977:37-9.
- 5 Ment LR, Duncan CC, Ehrenkraz RA. Perinatal cerebral infarction. *Ann Neurol* 1984;16:559-68.
- 6 Mahansandana C, Hathaway WE. Circulating anticoagulants in newborn: relation to hypercoagulability and the idiopathic respiratory distress syndrome. *Pediatr Res* 1973;7:670-3.

Correspondence to Dr AA Asindi, Fraser of Allander Unit (Paediatric Neurology), Royal Hospital for Sick Children, Yorkhill, Glasgow G3 8SJ, Scotland.

Received 7 May 1987