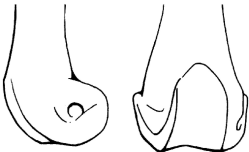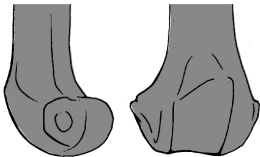


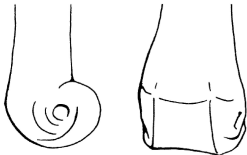
*Saguinus*



*Ignacius*



*Cynocephalus*



Medial

Anterior