

PAPERS AND ORIGINALS

 α_1 -Antitrypsin Deficiency and Neonatal HepatitisC. A. PORTER, ALEX P. MOWAT, P. J. L. COOK, D. W. G. HAYNES, K. B. SHILKIN,
ROGER WILLIAMS*British Medical Journal*, 1972, 3, 435-439

Summary

Five out of 28 infants investigated in a regional survey of neonatal hepatitis were found to have genetically-determined deficiency of α_1 -antitrypsin (ZZ phenotype). The clinical course and pathological changes varied considerably. All five infants had an acute hepatitis-like illness, and although this subsided cirrhosis later developed in three cases. The remaining two infants had minimal abnormalities of the liver function tests at 12 and 18 months of age, and one had increased hepatic fibrosis. Australia antigen was found in the serum of three infants, and Australia antigen or antibody in one or both parents of these and of one further case whose serum was negative. It is suggested that the association of neonatal hepatitis with α_1 -antitrypsin deficiency may be commoner than previously realized and that Australia antigen acts as a trigger factor in these cases.

Introduction

In the serum of man and other primates there exist substances that inhibit the action of trypsin and other proteolytic enzymes. By electrophoresis Jacobssen (1955) showed that about 90% of the trypsin inhibitory capacity of serum is due to an α_1 -globulin, hence named α_1 -antitrypsin. Genetic deficiency of α_1 -antitrypsin was first reported by Eriksson (1965) in severe pulmonary emphysema of early and middle adult life, the pattern of inheritance being autosomal recessive.

Many genetically-determined variants of α_1 -antitrypsin can be shown by starch-gel electrophoresis, appearing as distinct bands which have been assigned letters of the alphabet according to mobility. Normal individuals have M bands and thus have the phenotype MM. Homozygous-deficient individuals have slow-moving faint Z bands, while heterozygotes usually have both M and Z bands, the MZ phenotype, though SZ, XZ, and other phenotypes occasionally occur (Fagerhol and Laurell, 1970). The first report of liver disease in association with α_1 -antitrypsin deficiency was by Sharp *et al.* (1969) in two brothers with cirrhosis, while Johnson and Alper (1970) found low levels in four infants with neonatal hepatitis, two of whom later developed cirrhosis.

In January 1971 we began a survey of neonatal hepatitis in the South-East Metropolitan Regional Hospital Board area to determine the aetiological importance of viruses and other possible harmful environmental and familial factors. To our surprise we found five instances of α_1 -antitrypsin deficiency (ZZ phenotype) among the first 28 infants investigated. The variable course of hepatitis in these five cases is reported in this paper together with the possible significance of Australia antigen in the pathogenesis of the condition.

Methods

By appropriate tests the following causes of neonatal hepatitis were excluded: syphilis, cytomegalovirus, rubella, herpes simplex, toxoplasmosis, galactosaemia, and other inborn errors of metabolism. Every effort was made to exclude biliary atresia, including the use of ^{131}I -labelled rose bengal (Sharp *et al.*, 1967). The parents were interviewed in their homes and details were taken of all illnesses in themselves and their families and sera were obtained.

α_1 -Antitrypsin electrophoresis on plasma or serum was performed by a modification of the method of Fagerhol (1969), whereby gels of 14.5% Connaught starch at PH 5.0 were run for seven hours at 30 milliamperes. Serum was also examined for Australia antigen and its associated antibody by means of immunodiffusion, immunoelectrophoresis, complement fixation (Zuckerman, 1970), and passive haemagglutination (Shulman, 1970).

King's College Hospital and Medical School, London S.E.5

C. A. PORTER, M.B., M.R.C.P., Research Fellow, Dept. of Child Health

ALEX P. MOWAT, M.B., M.R.C.P., Consultant Paediatrician

D. W. G. HAYNES, PH.D., Biochemist

K. B. SHILKIN, M.B., F.R.C.P., Lecturer in Morbid Anatomy

ROGER WILLIAMS, M.D., F.R.C.P., Director, Liver Unit

M.R.C. Human Biochemical Genetics Unit, University College,
London W.C.1

P. J. L. COOK, M.B., B.CHIR., Medical Officer

Findings

In each case electrophoresis showed homozygous α_1 -antitrypsin deficiency (ZZ phenotype). Parents were heterozygotes with MZ or SZ phenotypes (see Table).

The five infants were born at or near term after pregnancies that were uneventful except for minor maternal illnesses— influenza-like illness in Case 1, pharyngitis and rhinitis in Case 2, cystitis in Cases 3 and 4. All had an uneventful perinatal course except one (Case 1). This infant was delivered by caesarian section because of fetal distress and required resuscitation at birth and treatment for symptomatic hypoglycaemia at 24 hours.

α_1 -Antitrypsin Phenotypes in Parents and Siblings

Case No.	Mother	Father	Siblings
1	MZ	MZ	{ MZ MZ
2	Y,Z*	MZ	MY,*
3	SZ	MZ	MS
4	MZ	MZ	—
5	MZ	MZ	{ MZ MZ MZ

* Y₁ is probably a new, very slow electrophoretic variant of α_1 -antitrypsin which is under investigation.

Jaundice with pale stools and dark urine developed in three infants during the 2nd week of life and at the 8th week in the remaining two. No itching was noticed. Biochemical investigations gave definite evidence of an underlying hepatitis. The subsequent course of the hepatitis varied considerably. Two infants (Cases 2 and 4) made an apparently complete clinical recovery over a period of about six months, although one of these (Case 4) continued to have slight hepatomegaly. In two others (Cases 3 and 5) jaundice decreased progressively and had disappeared by 6 and 8 months respectively (Fig. 1). With this their general condition also improved although hepatosplenomegaly persisted, and in both cases liver biopsy showed definite evidence of cirrhosis. The remaining patient (Case 1) never gained weight satisfactorily, and jaundice and hepatosplenomegaly persisted until his death from a respiratory infection at the age of 11 months. At necropsy there was evidence of biliary cirrhosis and of narrow extrahepatic bile ducts, as detailed below.

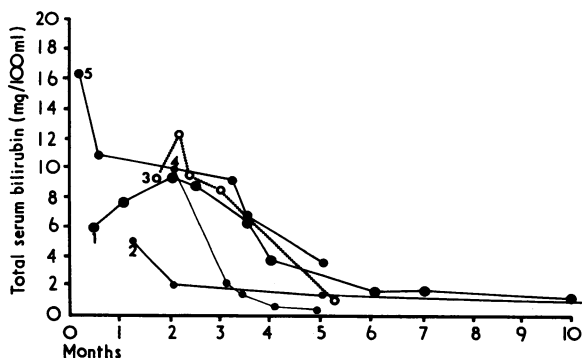


FIG. 1—Total serum bilirubin concentrations in the five patients.

Australia antigen was found in the serum in cases 2, 3, and 4 at the first testing but not subsequently (Fig. 2). It was also found in the parents of Case 3 at the same time as in the infant, subsequent tests showing disappearance of the antigen with, in the mother, appearance of antibody. The father of Case 4 had Australia antigen and antibody in the

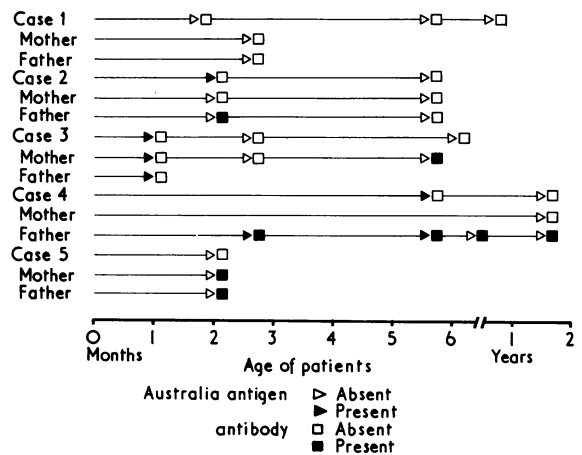


FIG. 2—Australia antigen and antibody findings in the serum of patients and their parents.

serum for a prolonged period. The father of Case 2 also had antibody at the time of the first test, and antibody was present in both parents in Case 5. Thus evidence of infection by Australia antigen was present in 4 of the five families. In no case was there a history of chronic liver disease or emphysema in parents, siblings, or more distant relatives.

Case Histories

Case 1.—This male infant weighed only 2,100 g at birth. At 12 days he became jaundiced, with pale stools and dark urine, and hepatosplenomegaly was noted. Liver function tests showed serum total bilirubin 6 mg/100 ml, serum alanine aminotransferase 131 IU/ml, and alkaline phosphatase 17 K.A. U/100 ml. Percutaneous liver biopsy at four weeks showed normal lobular architecture with severe cholestasis, a few giant cells, and a mild portal tract infiltrate. A four-week course of prednisone had no effect, and a further biopsy at four months showed evidence of large duct obstruction with widening of the portal areas, considerable bile duct proliferation, and polymorphonuclear neutrophil leucocyte infiltration (Fig. 3). A course of phenobarbitone was started at five months to increase production or release of α_1 -antitrypsin by the liver, but this had no effect. At the age of 7 months he weighed only 4,500 g. Prednisone was reinstated but with no benefit, and he died at

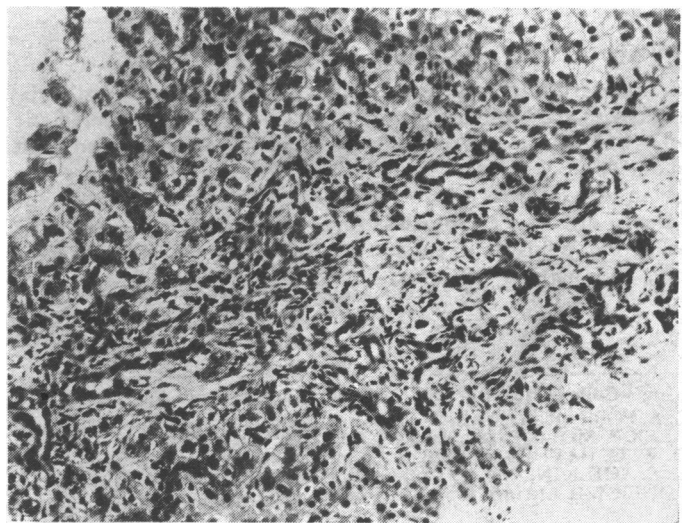


FIG. 3—Case 1. Needle biopsy specimen at 4 months. Portal area is widened, containing many small bile ducts and mixed inflammatory cell infiltrate including polymorphs. (Haematoxylin and eosin. $\times 170$.)

11 months from an acute respiratory tract infection. At necropsy there was no pulmonary emphysema. The liver was large, yellow-green in colour, and finely granular in appearance. The gall bladder was normal but the common bile duct and hepatic ducts appeared narrower than normal, and this was confirmed on radiographs after injection of contrast medium, which also showed narrowing of the intrahepatic bile ducts. Histologically the appearances were those of secondary biliary cirrhosis with intensive proliferation of small bile ducts and disruption of the liver architecture without true nodular regeneration (Fig. 4). Sections taken near the hilum of the liver showed the main bile ducts to be patent but smaller than normal. The mother was 33 years old and had no previous significant illness. The father, a heavy smoker, had symptoms of chronic bronchitis. There were two healthy siblings.

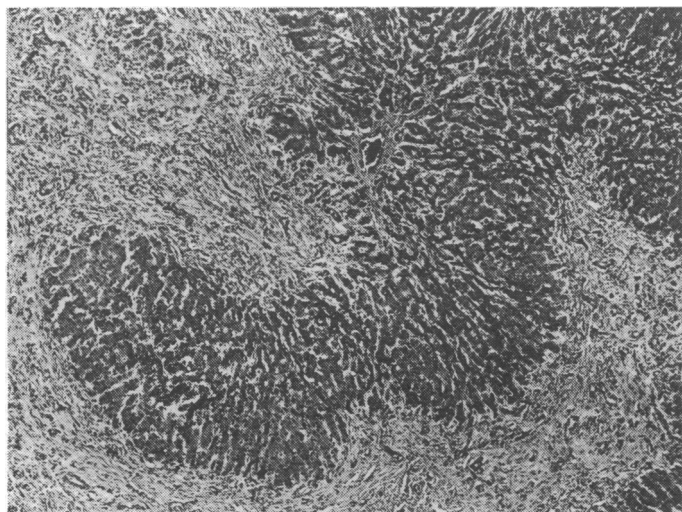


FIG. 4—Case 1. Liver specimen at necropsy showing features of secondary biliary cirrhosis with regularly outlined islands of hepatic parenchyma and with numerous small bile ducts in the broad fibrous bands. (Haematoxylin and eosin. $\times 40$.)

Case 2.—This male infant weighed 3,000 g at birth. He became jaundiced in the second week of life and when investigated at two months had hepatosplenomegaly. Liver function tests were: serum total bilirubin 2.3 mg/100 ml, alkaline phosphatase 320 IU/ml, serum alanine aminotransferase 120 IU/ml. Percutaneous liver biopsy showed a resolving neonatal hepatitis with some multinucleated giant cells. A few mononuclear cells were present within most portal areas, there was a moderate degree of canalicular bile stasis, and many pigment-filled phagocytes were seen in the sinusoids. Subsequently the jaundice decreased over a period of 10 weeks, and when last assessed at the age of 12 months there were no abnormal physical signs. Liver function tests were normal except for a slightly raised serum alkaline phosphatase (224 IU/ml). The mother was 23 years old and had no previous significant illnesses. The father, who had antibody to Australia antigen in his serum, was healthy. There was one healthy sibling.

Case 3.—This female infant weighed 4,200 g at birth. Jaundice and hepatosplenomegaly were first noted at 10 days. Liver function tests showed serum total bilirubin 8.8 mg/100 ml, alkaline phosphatase 28 K.A. U/100 ml, and serum alanine aminotransferase 351 IU/ml. A percutaneous liver biopsy at three weeks of age showed severe inflammation in both portal tracts and hepatic lobules. Some portal tracts were widened and minimal fibrosis was present. Cholestasis was prominent and occasional multinucleated large hepatocytes were seen (Fig. 5). Phenobarbitone 15 mg three times daily was prescribed, and subsequently the serum bilirubin fell. Weight gain was satisfactory but the hepatosplenomegaly remained unchanged, and dilated veins carrying blood away from the umbilicus became evident on the anterior abdominal wall. At 6 months of age the serum total bilirubin was 0.9 mg/100 ml, and the alkaline phosphatase >350 IU/ml. A further liver biopsy showed well-developed cirrhosis with severe inflammatory activity (Fig. 6). The mother, who had Australia antigenaemia, was 29 years old and had an illness diagnosed as

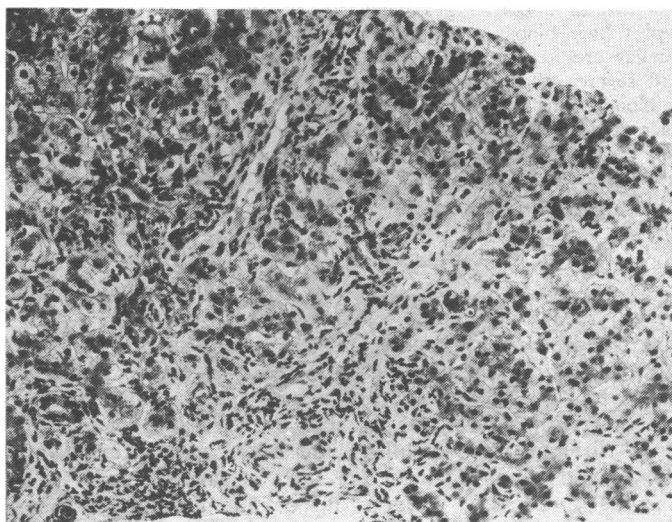


FIG. 5—Case 3. Needle biopsy specimen at 6 weeks showing inflammation in portal area extending into parenchyma and with many swollen and multinucleated hepatocytes. (Haematoxylin and eosin. $\times 150$.)

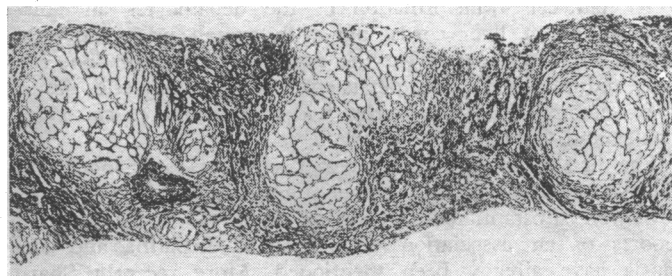


FIG. 6—Case 3. Needle biopsy specimen at 6 months showing well-developed cirrhosis with regeneration nodules. (Reticulin preparation. $\times 40$.)

hepatitis 10 years before the birth of the child. The father, who also had Australia antigenaemia, was healthy, and there was one sibling who was also healthy.

Case 4.—This male infant weighed 2,500 g at birth and progressed satisfactorily until 8 weeks of age when jaundice and hepatomegaly were noticed. The serum total bilirubin was 7.5 mg/100 ml, the serum alkaline phosphatase 53 K.A. U/100 ml, and the serum aspartate aminotransferase 77 Frankel U/ml. At 12 weeks of age a percutaneous liver biopsy showed the appearances of neonatal hepatitis, with mononuclear and polymorphonuclear leucocyte infiltration in the portal areas and a few focal areas of infiltration in the lobules; single hepatocytes were necrotic, and others were enlarged and multinucleated. Canalicular bile stasis was prominent. The jaundice disappeared over four weeks and normal weight gain was then resumed. At 18 months of age he was developing satisfactorily but the liver was still enlarged and the serum alkaline phosphatase (214 IU/ml) and alanine aminotransferase (100 IU/ml) were still abnormal. A further liver biopsy showed no evidence of active inflammation or cholestasis, but there was an increase in portal tract fibrosis. The mother, aged 33, had had jaundice for three weeks at the age of 11. The father, who had both Australia antigen and antibody in his serum, had no significant past illness. There were no siblings.

Case 5.—This female infant weighed 3,200 g at birth. Jaundice, which had first been noted at 24 hours, deepened during the 6th week and became obstructive in type. When referred at 3 months of age she weighed 4,600 g and had definite hepatosplenomegaly. The serum total bilirubin was 9.1 mg/100 ml, serum alanine aminotransferase 270 IU/ml, and alkaline phosphatase 500 IU/ml. Percutaneous liver biopsy showed intralobular and portal inflammation, portal oedema with some bile duct proliferation, cholestasis, and the presence of giant multinucleated hepatocytes with a few foci of haemopoietic tissue. After phenobarbitone therapy the serum bilirubin level returned to normal but the other

biochemical abnormalities persisted, as did the hepatomegaly. A repeat liver biopsy at 6 months showed pronounced distortion of lobular architecture, with extensive fibrosis and nodule formation and severe inflammatory activity. The mother, aged 36, had had a blood transfusion of three pints (1.7 l.) after a postpartum haemorrhage three years before the birth of this child. She had no other significant past illnesses, and neither had the father, although both had antibody to Australia antigen in their serum. There were three healthy siblings.

Discussion

The syndrome of neonatal hepatitis (Craig and Landing, 1952; Thaler and Gellis, 1968) has been described in association with several aetiological factors, including intrauterine infection with rubella, herpes simplex, varicella, cytomegalovirus, listeria, and syphilis; infestation with *Toxoplasma gondii*; and metabolic disorders such as galactosaemia. In at least 50% of cases, however, no definite aetiological factor can be identified although a virus infection is widely presumed. A familial incidence in neonatal hepatitis has also been noted (Laplane *et al.*, 1964), the suggested mode of inheritance being autosomal recessive (Danks and Bodian, 1963). In all aetiological groups the histological picture is similar, with giant-cell transformation of the hepatocytes and disorganization of liver cords, but with overall preservation of lobular architecture and varying degrees of inflammation, bile duct reduplication, and persistence of haemopoietic tissue. The outcome, however, varies widely (Shiraki *et al.*, 1966; Thaler and Gellis, 1968).

The first clinical association of disease in association with α_1 -antitrypsin deficiency—namely, emphysema in adults—is now well substantiated (Hutchison *et al.*, 1971). The initial reports of an association with neonatal hepatitis and cirrhosis have already been mentioned. More recently Sharp (1971) added a further 11 cases to his original series. There is also a recent report of two siblings who developed both neonatal hepatitis and pulmonary emphysema (Glasgow *et al.*, 1971). One progressed to liver failure and portal hypertension by the age of 3 years. From then onwards until his death at the age of 11 he also had recurrent pulmonary infection. Necropsy showed emphysema and a perilobular cirrhosis with a reduction of intralobular bile ducts. The other sibling at the age of 12 had a hard liver with normal liver function tests and some reduction in respiratory reserve. A third sibling was healthy. Two adults have also been reported to have had both pulmonary and hepatic disease (Pederson *et al.*, 1969; Gherhardi, 1971), but in most adult cases with emphysema secondary to α_1 -antitrypsin deficiency there is no clinical evidence of hepatic involvement, although Aagaens (1971) detected a significant rise of serum alanine aminotransferase in some of these patients. All these disease states have been found with the ZZ phenotype, where this has been determined. Heterozygotes for the Z gene have about 60% of normal α_1 -antitrypsin and appear to escape serious disease, although a greater than expected incidence of emphysema has been suggested (Lieberman, 1969).

How α_1 -antitrypsin deficiency is associated with liver disease is not known. The sole source of the glycoprotein appears to be the liver, as judged by the sharp fall in serum levels after hepatectomy in experimental animals and the rise after liver transplantation in one patient with the deficiency state (Sharp, 1971). Serum α_1 -antitrypsin levels are normal or increased in cirrhosis due to other causes. Hepatic tissue from subjects with homozygous deficiency when stained with a specific fluorescent-tagged antibody to α_1 -antitrypsin shows bright fluorescent deposits in the hepatocytes, especially in the periportal areas (Aagaens, 1971; Sharp, 1971). Similar but less extensive deposits are seen in the hepatocytes of heterozygotes. Globular vacuolated structures thought to correspond to the fluorescent deposits have been shown in the hepatic cytoplasm by electron microscopy (Lieberman

et al., 1972; Sharp 1971). The primary abnormality may therefore be an inability of the hepatocyte to release the protein rather than a defect in its production.

The presence of the protein in the serum may have a protective role. In vitro it inhibits elastase, collagenase, chymotrypsin, fungal and leucocyte proteases, as well as trypsin (Ohlsson, 1971a, 1971b). Intercurrent infection with release of enzymes from disintegrating leucocytes or bacteria and resultant breakdown of collagen and elastin in the pulmonary parenchyma is suggested as one of the possible mechanisms for the production of the pulmonary emphysema (Kueppers and Bearn, 1966). Similar trigger factors may be necessary for the development of liver disease, and in this context the finding of Australia antigen in the serum of three of these infants and of antibody to Australia antigen in the parents of another child is of great interest. The exact significance of Australia antibody in the serum is uncertain, for it is found in only a small percentage of patients with Australia-antigen-positive hepatitis, but its presence can probably be taken as a marker of infection with the antigen at some time (Lander *et al.*, 1971). Certainly all the present five infants had an acute hepatitis. Further follow-up will be necessary to determine whether cirrhosis is the inevitable outcome of neonatal hepatitis associated with α_1 -antitrypsin deficiency.

Because of its action as an enzyme-inducing agent phenobarbitone was tried in three patients (Cases 1, 3, and 5), but like Sharp (1971) we found no increase in the serum levels of α_1 -antitrypsin. Short courses of steroids do not appear to have been beneficial, but their use over long periods requires evaluation. Administration of natural exogenous α_1 -antitrypsin is impracticable (Makino and Reed, 1969) and no satisfactory synthetic agent with antiprotease activity has yet become available.

The lack of any effective form of therapy makes genetic counselling important. The frequency of the homozygote-deficiency state in Britain is thought to be 1 in 4,000 live births (P. J. L. Cook, unpublished data, 1971). Parents of an affected child can be told that in subsequent pregnancies they have a 1:4 chance of having a child with the homozygous-deficiency state, but more accurate guidance about the likelihood of the child developing either liver or pulmonary disease cannot be given. There is as yet no method for detection of the deficiency state by examination of amniotic fluid, although work on this is in progress.

We are indebted to Professor C. E. Stroud for his support and encouragement, and to Dr. Trevor Mann for his help in the regional hepatitis survey. Our thanks are also due to Dr. O. D. Fisher, Dr. M. E. R. Stoneman, Dr. C. H. C. Upjohn, Dr. A. Robinson, and Dr. W. J. Appleyard for allowing us to study patients under their care, and to the parents who co-operated so fully. This investigation was supported by a grant from the King's College Hospital Medical School research committee.

References

- Aagaens, Ø. (1971). Personal communication.
- Craig, J. M., and Landing, B. H. (1952). *Archives of Pathology and Laboratory Medicine*, **54**, 321.
- Danks, D., and Bodian, M. (1963). *Archives of Diseases in Childhood*, **38**, 378.
- Eriksson, S. (1965). *Acta Medica Scandinavica*, Suppl. No. 432, p. 1.
- Fagerhol, M. K. (1969). *Scandinavian Journal of Clinical and Laboratory Investigation*, **23**, 97.
- Fagerhol, M. K., and Laurell, C. B. (1970). In *Progress in Medical Genetics*, Vol. 7, p. 96. New York, Grune and Stratton.
- Glasgow, J. F. T., Hercy, A., Levison, H., Lynch, M. J., and Sass-Kortsak, A. (1971). *Pediatric Research*, **5**, 427.
- Gherhardi, G. J. (1971). *Human Pathology*, **2**, 173.
- Hutchison, D. C. S., Cook, P. J. L., Barter, C. E., Harris, H., and Hugh-Jones, P. (1971). *British Medical Journal*, **1**, 689.
- Jacobsson, K. (1955). *Scandinavian Journal of Clinical and Laboratory Investigation*, Suppl. No. 14, p. 57.
- Johnson, A. M., and Alper, C. A. (1970). *Pediatrics*, **46**, 921.
- Kueppers, F., and Bearn, A. G. (1966). *Proceedings of the Society for Experimental Biology and Medicine*, **121**, 1207.
- Lander, J. J., Giles, J. P., Zucchi, R. H., and Krugman, S. (1971). *New England Journal of Medicine*, **285**, 303.
- Laplane, R., Graveleau, D., Lods, C., and Noum, I. (1964). *Pediatric*, **19**, 217.

Lieberman, J. (1969). *New England Journal of Medicine*, 281, 279.
 Lieberman, J., Mittman, C., and Gordon, H. W. (1972). *Science*, 175, 63.
 Makino, S., and Reed, C. E. (1969). *Journal of Laboratory and Clinical Medicine*, 74, 987.
 Ohlsson, K. (1971a). *Scandinavian Journal of Clinical and Laboratory Investigation*, 28, 219.
 Ohlsson, K. (1971b). *Scandinavian Journal of Clinical and Laboratory Investigation*, 28, 251.
 Pederson, J. T., Weeke, B., and George, J. (1969). *Danish Medical Bulletin*, 16, 283.

Sharp, H., Krivit, W., and Lowman, J. T. (1967). *Journal of Pediatrics*, 70, 46.
 Sharp, H. L., Bridges, R. A., Krivit, W., and Freier, E. M. (1969). *Journal of Laboratory and Clinical Medicine*, 73, 934.
 Sharp, H. L. (1971). *Hospital Practice*, 6, 83.
 Shiraki, K., Okamoto, Y., and Takatsu, T. (1966). *Paediatrica Universitatis Tokyo*, 12, 41.
 Shulman, V. R. (1970). *American Journal of Medicine*, 49, 619.
 Thaler, M. M., and Gellis, S. S. (1968). *American Journal of Diseases of Children*, 116, 257.
 Zuckerman, A. J. (1970). *Bulletin of the World Health Organization*, 42, 957.

Effect of Electric Convulsion Therapy on Urinary Excretion of 3', 5' Cyclic Adenosine Monophosphate

K. HAMADAH, HELEN HOLMES, G. B. BARKER, G. C. HARTMAN, D. V. W. PARKE

British Medical Journal, 1972, 3, 439-441

Summary

Electric convulsion therapy (E.C.T.) was used in the treatment of 13 women inpatients suffering from depressive symptoms. Twelve of the patients showed a significant increase in urinary excretion of 3', 5' cyclic adenosine monophosphate (cAMP) on the day of treatment, whereas four controls who received all or part of the preliminary treatment but no electric shock showed a reduction. The results of this study are consistent with the hypothesis that the antidepressant action of E.C.T. is mediated through an increased production of cAMP in brain tissue.

Introduction

Abnormally low excretion of 3', 5' cyclic adenosine monophosphate (cAMP) has been reported in patients with depressive illness (Abdulla and Hamadah, 1970; Paul *et al.*, 1970). Abdulla and Hamadah suggested that depressive illness is due to a severe fall in the intracellular level of cAMP in all tissues, including those of the central nervous system. Several factors have been found to influence cAMP levels in body fluids and tissues. An increase in the urinary level has been noted after the administration of tricyclic antidepressants, and these have been shown to be inhibitors of cAMP phosphodiesterase (Abdulla and Hamadah, 1970; Ramsden, 1970). Recent studies by Kodama *et al.* (1971) on brain slices suggest that imipramine, desipramine, and amitriptyline stimulate the formation of cAMP. Electrical stimulation has also been found to increase the level of cAMP in cerebral cortical slices (Kakiuchi *et al.*, 1969; Shimizu *et al.*, 1970), and this response was synergistic with that of histamine or noradrenaline but was prevented by previous treatment with a methylxanthine such as theophylline (Kakiuchi *et al.*, 1969; Sattin and Rall, 1970).

Electric convulsion therapy (E.C.T.) has long been accepted as an effective form of treatment in some types of depression, and we therefore decided to examine the effect of E.C.T. on the urinary excretion of cAMP.

Patients and Methods

The investigation was carried out on 14 women inpatients at Tooting Bec Hospital suffering from depressive symptoms who were judged clinically to require treatment with E.C.T. The only additional criteria for selection were the willingness and the ability of the patients to co-operate in the investigation. Patients with heart or kidney diseases were excluded. The age range was from 24 to 61 years. Throughout the period of the study the patients were given a diet that lacked foods which might affect indole and catecholamine excretion (Paul *et al.*, 1970). No alcohol was permitted and tea and coffee intake was stabilized. Patients were clinically assessed on the day before E.C.T., on the day of treatment, and on the following day to detect any sudden or pronounced change in mood. All participants received antidepressants or tranquillizers, or both, the doses of which were fixed throughout the period of the study.

E.C.T. was administered regularly between 09.30 and 11.00 hours on Tuesdays and Fridays. All patients received 0.6 mg of atropine sulphate as premedication half to one hour before treatment. In 11 patients, who received a total of 19 treatments, the convulsion was modified by the intravenous injection of 60-70 mg of methohexitone sodium and 25-50 mg of suxamethonium chloride immediately before E.C.T. In the last two patients in the E.C.T. group, who received a total of seven treatments, the convulsion was modified by the intravenous injection of 250 mg of thiopentone sodium and 30-50 mg of suxamethonium bromide. The E.C.T. was administered with an Ectonus mark 3 A.C. mains model (Ectron Ltd.). The electrodes (Ectonus head-band) were lightly soaked in Ectronolyte solution and applied bitemporofrontally. The rotary control was used to apply the potential in a series of increasing steps, reaching a maximum of 140 V; the current was passed for about one second. The patients were well oxygenated with 100% oxygen.

On three occasions patients received all the preliminary treatment but for various reasons, including instrument failure, no shock was delivered. As they had experienced the anticipatory anxiety and had received atropine sulphate, methohexitone sodium, suxamethonium chloride, but not the electric shock they were regarded as controls on these occasions. A fourth patient, who received the atropine sulphate but panicked before further treatment could be given and refused it, was regarded as a separate control. Thus the controls (see Table) were achieved by chance rather than design. It was felt to be unacceptable on ethical grounds to enlarge this control group.

Twenty-four-hour specimens of urine (07.00-07.00 hours) were collected for up to three days before the first E.C.T. to establish a baseline for each individual patient and to determine the day-to-day variation of cAMP excretion. Twenty-four-hour specimens were also collected on the day of E.C.T., for two days after E.C.T., and, where appropriate, on the days between subsequent treatments. The total urinary output over each

Tooting Bec Hospital, London S.W.17

K. HAMADAH, M.B., D.P.M., Psychiatrist
 HELEN HOLMES, B.Sc., Research Assistant
 G. B. BARKER, M.B., D.P.M., Consultant Psychiatrist

University of Surrey, Guildford, Surrey

G. C. HARTMAN, DIP. TECH., Lecturer in Biochemistry
 D. V. W. PARKE, PH.D., F.R.I.C., Head of Biochemistry Department