

CASE REPORT

Discospondylitis and Orchitis Associated with High *Brucella* Titre in a Dog

G.I. ANDERSON AND A.G. BINNINGTON

Department of Clinical Studies, Ontario Veterinary College, University of Guelph, Guelph, Ontario N1G 2W1

Summary

A case of discospondylitis and orchitis associated with high *Brucella* titre in a dog is presented. Clinical signs included intermittent pain, poor appetite and a decreased level of physical activity. Radiographic evidence of discospondylitis was found. Histopathological findings on the testes are included. Treatment regime and clinical progress are given. Diagnosis and treatment of *B. canis* are described and a brief review of the treatment of discospondylitis is presented.

Résumé

Disco-spondylite et orchite associées à un taux élevé d'anticorps à l'endroit de *Brucella*, chez un chien

Cet article présente un cas de disco-spondylite et d'orchite associées à un taux élevé d'anticorps à l'endroit de *Brucella*, chez un chien qui manifestait les signes cliniques suivants: douleur intermittente, anorexie et réduction de l'activité physique. Des radiographies démontrèrent des lésions de disco-spondylite. L'article énumère les lésions testiculaires microscopiques; il donne aussi le genre de traitement qu'on administra au chien et les progrès cliniques qu'il enregistra; il décrit également le diagnostic et le traitement de la brucellose canine; il présente enfin une brève revue du traitement de la disco-spondylite.

Introduction

Brucella canis infection in bitches causes abortion and infertility, whilst in males, infertility is due to abnormal sperm production with decreased motility. Male dogs may show signs of

orchitis, epididymitis and scrotal swelling (1,2,3). In systemic *Brucella* infection lymphadenitis, splenitis, nephritis and osteomyelitis/discospondylitis may occur (3).

Information on the incidence of *B. canis* is scarce. A recent survey of 2 000 dogs in southern Ontario, indicates that 0.3% of sera tested showed serological evidence of *B. canis* infection (4), but only one animal had a tube agglutination titre greater than 1:200. Results of a serological survey in Quebec using 341 dogs suggest that 1.6% of dogs had a significant titre with the mercaptoethanol tube agglutination test (5). Only two dogs showed titres of greater than 1:200, which is considered indicative of active infection (3,6,7,8). This unusual case is reported here to draw attention to the ability of *B. canis* to cause discospondylitis in the dog in Canada.

Case History

A three year old Golden Retriever cross intact male dog was presented at the Ontario Veterinary College (OVC) with a history of episodes of pain for four months. The owner reported that the dog did not exhibit signs of pain at rest but that the level of voluntary exercise had reduced along with the appetite.

Four months prior to presentation the dog had been treated for orchitis with a seven day course of oral tetracyclines. At that time the referring veterinarian had noticed one testis to be enlarged and painful on palpation. There was no evidence of scrotal dermatitis. In the four month period between the onset of signs and presen-

tation at OVC the dog was seen by the referring veterinarian for episodes of stiffness and pain involving the shoulder or the cervical region. Radiographic examination of both regions had revealed no lesions. Results of hematological and blood chemistry examinations performed on these occasions were within normal limits.

Clinical Signs

On physical examination the dog was in good bodily condition although it was reported to have lost weight in the month prior to presentation. It was afebrile (38.7°C) with a dry haircoat and mild bilateral otitis externa. On deep palpation of the anterior abdomen, it exhibited discomfort but failed to react to any other manipulation or palpation. However, on being lifted from the examination table, the dog exhibited pain associated with the movement of the thoracolumbar (T-L) spine. Deep digital palpation of this area elicited pain and inconsistently reproducible crepitus. Neurological examination revealed no abnormalities.

Laboratory Findings

A complete blood count, biochemical profile, urinalysis and fecal examination were performed. (Tables I,II,III,IV and V). Radiographic examination was carried out under droperidol-fentanyl¹ sedation.

The results of hematology, biochemical profile and urinalysis were normal. The endoparasitic infection *Ancylostoma caninum*, *Trichuris vulpis*, *Toxocara canis* was treated with an anthelmintic preparation.²

¹Innovar-vet, Pitman-Moore Ltd., Scarborough, Ontario.

²Pyr-A-Pam plus, Rogar/STB division of BTI Products Inc., London, Ontario.

TABLE I
HEMATOLOGICAL VALUES ON INITIAL
PRESENTATION OF A DOG WITH ORCHITIS
AND DISCOSPONDYLITIS

Complete Blood Count	Test	Normal Values at OVC
WBC ($10^9/L$)	9.3	6.6 - 1.84
RBC ($10^{12}/L$)	7.18	5.5 - 8.2
Hb (g/L)	178	126 - 194
Hct (L/L)	0.47	0.37 - 0.55
MCV (fL)	66	62 - 70
MCH (pg)	24.6	22 - 25
MCHC (g/L)	371	330 - 360

Radiological Results

Abnormalities were not seen on abdominal radiographs. On the thoracolumbar radiographs there was narrowing of the intervertebral disc space at T12-T13 with sclerosis of adjacent articular surfaces and spondylosis ventrally on both vertebral bodies. A small lytic area was seen on the cranial articular surface of T13. The lytic area was presumed to be due to osteomyelitis and the spondylitis due to instability between the two vertebral bodies.

Serological Results

With the prior history of orchitis and current radiographic evidence of discospondylitis, blood was taken for a *B. canis* screening test [rapid slide agglutination test-serum aspartate transaminase (SAT)].³ The result was positive. Further blood was submitted for the tube agglutination test [mercaptoethanol tube agglutination test (ME-TAT)]. The ME-TAT yielded a titre of 1:400.

Treatment and Results

The dog was discharged from OVC with a positive SAT but whilst still awaiting the ME-TAT result. Home treatment consisted of oral tetracycline hydrochloride⁴ at 60 mg/kg divided into three daily doses, until confirmation of the SAT by the mercaptoethanol tube agglutination test was received. After one week of antibiotic therapy there was clinical improvement. When the ME-TAT titre of 1:400 was received, the dog returned for a six day course of dihydrostreptomycin⁵ intramuscularly at 20 mg/kg twice daily (9,10). Oral

TABLE II
DIFFERENTIAL WHITE BLOOD CELL COUNT ON
PRESENTATION OF A DOG WITH ORCHITIS
AND DISCOSPONDYLITIS

	Normal Values at OVC			
	($10^9/L$)	(%)	($10^9/L$)	(%)
Basophils	0	0%	0.0- 0.2	0- 1%
Eosinophils	0.56	6%	0.0- 1.9	0-14%
Immature PMNs	0.47	5%	0.0- 1.0	0- 5%
Lymphocytes	1.86	30%	0.8- 5.6	10-40%
Mature PMNs	4.5	49%	3.9-12.0	46-76%
Monocytes	0.93	10%	0.1- 1.8	1-14%

tetracycline hydrochloride was continued during this second period of hospitalization and the dog was castrated. Due to lack of libido, semen samples were not obtained from the dog before castration.

Radiographs taken on readmission showed further spondylitic bridging ventral to T12-T13 and increased sclerosis of the endplates. Oral tetracyclines were continued for 25 days. The dog continued to improve clinically at home and eight weeks posttreatment remained free of pain and active.

A telephone recheck five months after cessation of treatment found the dog asymptomatic. Repeat serology posttreatment, unfortunately, was not obtainable as the owner and dog had moved out of the district.

Histopathological Findings

The testes removed at surgery were grossly normal measuring approximately 4 cm in diameter. Lesions in both testes were similar, consisting of diffuse tubular degeneration and atrophy. There was very little evidence of spermatogenesis. Interstitial edema and postnecrotic foci were seen between the tubules. The epididymal lesions were characterized by multifocal lymphocytic and mononuclear cell infiltrations in the interstitium (11). The epididymal epithelium was normal. Intracellular *B. canis* organisms were not observed on Gram stained preparations of testicular tissue. A histopathological diagnosis of chronic multifocal interstitial orchitis and epididymitis was made.

Discussion

Brucella canis may cause inapparent infection or discospondylitis and orchitis as in this dog. Diagnosis in this case was based on the history of orchitis, discospondylitis, testicular and epididymal lesions in conjunction with the positive SAT and ME-TAT. Suspicious animals can first be screened using the rapid slide agglutination test available in a commercial kit. The SAT gives a percentage of false positives but is efficient in identifying negative, or noninfected, dogs (1). Serum samples positive on SAT should be

TABLE III
SERUM CHEMISTRY RESULTS ON PRESENTATION OF A DOG WITH ORCHITIS AND DISCOSPONDYLITIS

Test	Normal Range at OVC
A:G Ratio	0.6 - 1.20
Albumin (g/dL)	24 - 36
Amylase (μ/L)	740 - 1670
Calcium (mmol/L)	2.57 - 2.97
Cholesterol (mmol/L)	3.23 - 7.89
Conjugated bilirubin ($\mu\text{mol L}$)	0.0 - 3
CPK (μ/L)	30 - 250
Creatinine ($\mu\text{mol/L}$)	60 - 110
Free Bilirubin ($\mu\text{mol/L}$)	0 - 0.3
Glucose (mmol/L)	3.8 - 5.9
Phosphorus (mmol/L)	0.81 - 1.87
SAP (U/L)	40 - 350
SAST (U/L)	8 - 38
SALT (U/L)	9 - 45
Total bilirubin ($\mu\text{mol/L}$)	0 - 3
Total protein (g/L)	52 - 69
Urea (mmol/L)	1.8 - 10.4

³Canine Brucellosis Diagnostic Test, Pitman-Moore, Inc., Washington Crossing, New Jersey.

⁴Tetracycline HCl, Sounds, Div Terram Pharmaceuticals Ltd., Toronto, Ontario.

⁵U Streptomycin injection, Pfizer Canada Inc., Montreal, Quebec.

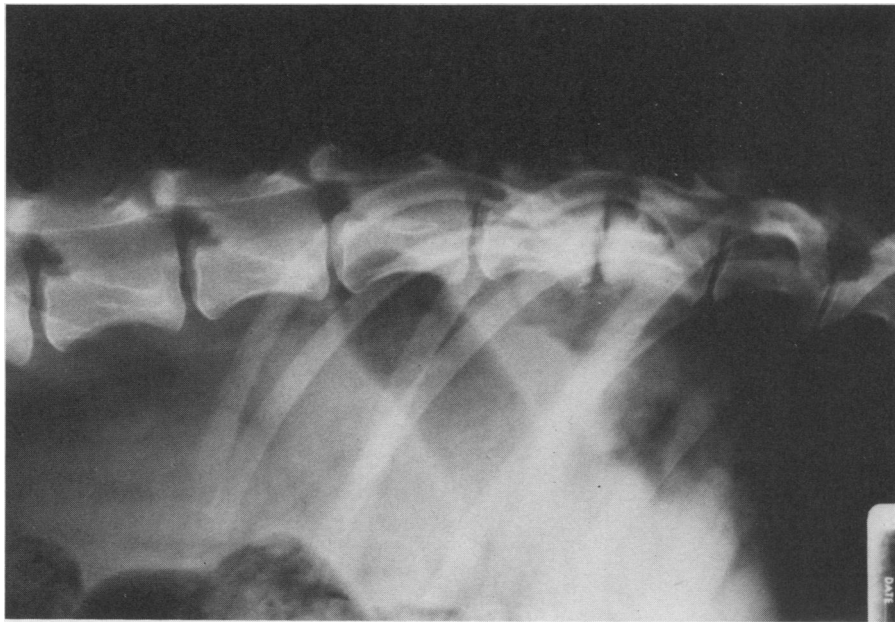


FIGURE 1. Thoracolumbar spine. The disc space at T12-13 is narrowed, the vertebral end plates are sclerotic and roughened and early ventral bridging between T12-T13 is seen. Small lytic area is present on cranial articular surface of T13.

checked using the mercaptoethanol tube agglutination test. Sera giving reactions in dilutions of 1:200 or greater are considered positive, in accordance with the guidelines established by the World Health Commission on Brucellosis (3,6,12,13). To make a definitive diagnosis, culture of *B. canis* from semen, testicular tissues or blood, or visualization of intracellular *Brucella* organisms in the testicular tissue sections would be necessary. Attempts at semen collection and cultures of tissues in this case were unsuccessful. However, these attempts were made after initiation of antibiotic therapy. In chronic cases of brucellosis, the bacteremia is intermittent so even serial blood cultures may be unsuccessful (1,2).

Although *B. canis* organisms were not seen on histopathological sections, the lesions are compatible with those of *B. canis* epididymitis and orchitis. Again, antibiotic therapy prior to castration, may have interfered with testicular cultures and/or visualization of the organism on Gram-stained sections.

Although the dog had a ME-TAT of 1:400 indicative of active infection and osteomyelitis, orchitis and epididymitis all highly suggestive of *B. canis* infection, a presumptive diagnosis only can be made (1).

Brucella canis, being an intracellular organism, can be difficult to eliminate, especially from prostatic and osseous tissue (2). The response to combination antibiotic therapy is similar to previous reports (9,10). To establish whether the organism had truly been eliminated in this case, serial serology at bimonthly intervals would be necessary (2). Unfortunately, as the owner and dog moved out of the district, this was not possible. A tele-

phone report made five months post-treatment found the dog to be clinically normal and active; presumptive evidence only that, at that stage, the dog was free of *B. canis* infection and back pain. In the healing of discospondylitis vertebral fusion or bridging occurs resulting in the elimination of instability and pain (12,14).

Dogs in which there was minimal neurological dysfunction, have been successfully treated with antibiotics alone, although curettage and antibiotics give more reliable results where there is a single lesion (14,15,16). In dogs with marked neurological dysfunction, treatment has involved hemilaminectomy, vertebral immobilization and prolonged antibiotic treatment. Success rates in dogs with neurological dysfunction were much lower.

Two cases of *B. canis* discospondylitis have been treated successfully with laminectomy, curettage and a 30 day course or oral tetracycline hydrochloride (17). The ME-TAT titre fell from 1:200 at surgery to 1:40, 28 weeks post-surgery in one case with good clinical improvement.

Prognosis with discospondylitis depends on two factors: (a) the ease with which the infecting organism can be eliminated from body tissues and (b) the degree of neurological dysfunction present.

In this dog there were no neurological deficits despite the chronicity of the

TABLE IV
URINALYSIS OF FREE FLOW SAMPLE ON PRESENTATION OF A DOG WITH ORCHITIS AND DISCOSPONDYLITIS

<i>Urinalysis</i>	
Acetone	— negative
Blood	— negative
Bile	— negative
Glucose	— negative
Gross appearance	— slightly cloudy
	— dark yellow
pH	— 6.0
Protein	— negative
Sp gr	— 1.055
<i>Cytology</i>	
Bacteria	— occasional
Bacteria in catheterized sample	— nil
Crystals	— low numbers triple phosphate crystals
Erythrocytes	— nil
Glitter cells	— low numbers
Neutrophils	— 3-4 cells per high power field
Renal epithelial cells	— nil
Squamous epithelial cells	— occasional
Transitional cells	— occasional
Urine culture	— no bacterial growth achieved

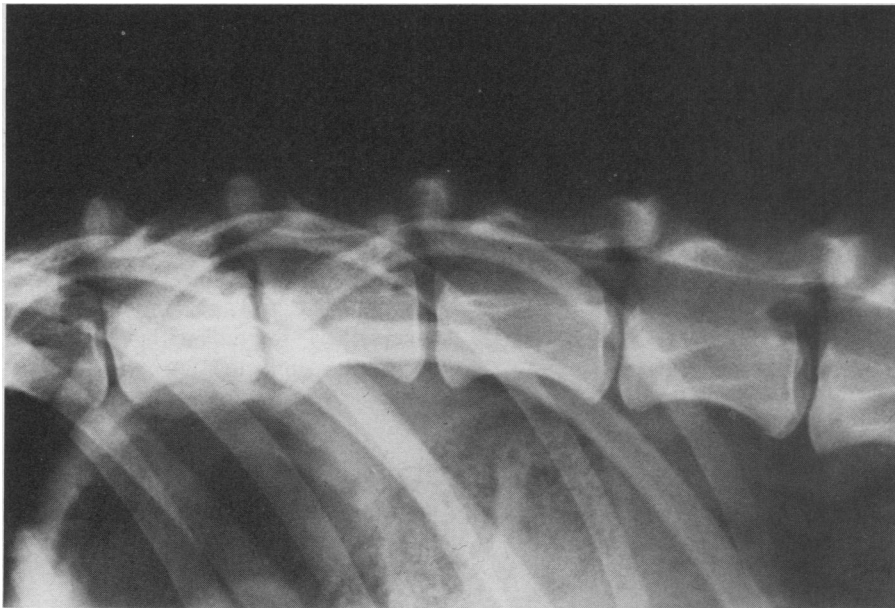


FIGURE 2. Radiograph taken ten days after initial examination. There is increased bridging ventrally, decreased roughening and increased sclerosis of end plate areas of both T12 and T13.

signs. *Brucella canis*, however, can be very difficult to eliminate from all tissues because of its intracellular nature. Despite the early clinical improvement with tetracyclines and dihydrostreptomycin, recurrence is still possible. Serial negative blood cultures, falling titres and radiographic evidence of healing would be necessary before success could be claimed. Whenever there is a history of orchitis and discospondylitis occurring in the dog, there should be a high index of suspicion of *B. canis* involvement and *Brucella* serological testing is indicated.

References

1. CARMICHAEL LE. Canine brucellosis — an annotated review with selected cautionary comments. *Theriogenology* 1976; 6: 105-116.
2. FLORES-CASTRO R, CARMICHAEL LE. Canine brucellosis: current status of methods of diagnosis and treatment. *Gaines Vet: Symposium in Conjunction with Texas A&M University Veterinary College*, 1977; 27: 17-24.
3. HUBBERT NL, BECH-NELSON O, BARTA O. Canine brucellosis: comparison of clinical manifestations with serological test results. *J Am Vet Med Assoc* 1980; 177: 168-171.
4. BOSU WTK, PRESCOTT JF. A serological survey of dogs for *Brucella canis* in southwestern Ontario. *Can Vet J* 1980; 21: 198-200.
5. HIGGINS R, HOQUET F, BOURQUE R, GOSSELIN Y. A serological survey for *Brucella canis* in the province of Quebec. *Can Vet J* 1979; 20: 315-317.
6. FREDRICKSON LE, BARTON CE. A serologic survey for canine brucellosis in a metropolitan area. *J Am Vet Med Assoc* 1974; 165: 987-989.
7. MUNFORD RS. *Brucella canis* infects man. *J Am Med Assoc* 1975; 231: 1267.
8. THIERNAN AB. Brucellosis in stray dogs in Detroit. *J Am Vet Med Assoc* 1980; 177: 1216-1217.
9. JENNINGS PB, CRUMRINE MH, LEWIS GE, FARISSBL. The effect of a two-stage antibiotic regime on dogs infected with *Brucella canis*. *J Am Vet Med Assoc* 1974; 164: 513-514.
10. LEWIS GE, CRUMRINE MH, JENNINGS PB, FARISSBL. Therapeutic value of tetracycline and ampicillin in dogs infected with *B. canis*. *J Am Vet Med Assoc* 1973; 163: 239-241.
11. RHOADES HE, MESFIN GM. *Brucella canis* infection in a kennel. *Vet Med Small Anim Clin* 1980; 75: 595-599.
12. HUOV L, TROY G, TURNWALD G. Discospondylitis in the dog — 27 cases. *J Am Vet Med Assoc* 1978; 173: 275-280.
13. CANINE BRUCELLOSIS: Current status. J.A. Baker Institute Report. Ithaca: New York State College of Veterinary Medicine. September 1976.
14. GAGE ED. Treatment of discospondylitis in dogs. *J Am Vet Med Assoc* 1975; 166: 1164-1169.
15. KORNEGAY JN. Canine discospondylitis. *Compend Contin Educ Small Anim Pract* 1979; 1: 930-933.
16. KORNEGAY JN, BARBER DL. Discospondylitis in dogs. *J Am Vet Med Assoc* 1980; 177: 337-341.
17. HENDERSON RA, HOERLEIN BF, KRAMER TT, MEYER ME. Discospondylitis in three dogs infected with *Brucella canis*. *J Am Vet Med Assoc* 1974; 165: 451-454.

DEMANDE DE FONDS DE RECHERCHE

Nous invitons les demandes de fonds de recherche sur les maladies animales au Canada. Les demandes doivent nous parvenir avant le **30 novembre**.

Pour plus de renseignements et pour obtenir des formules de demande, s'adresser au:

Secrétaire

La fondation canadienne pour la recherche vétérinaire

339, rue Booth

Ottawa (Ontario) K1R 7K1