

Rectal biopsy at an earlier stage of the procedure might have provided the correct diagnosis. The possibility of amœbic colitis was certainly thought of and the stools were repeatedly examined in different institutions for the presence of cysts, but none was found. This man's travels in the past twenty years had not extended beyond two of the more select suburbs of Sydney! Features of this illness simulating Crohn's disease provided an impressive contrast for those cases in which Crohn's disease was diagnosed as something else.

The diagnosis of Crohn's disease involving the large bowel can still be difficult, but greater familiarity with the unusual clinical pattern it may adopt will help to achieve a higher rate of diagnosis.

**BIBLIOGRAPHY**

Atwell J D, Duthie H L & Goligher J C (1965) *Brit. J. Surg.* 52, 966  
 Crohn B B, Ginzburg L & Oppenheimer G D (1932) *J. Amer. med. Ass.* 99, 1323  
 Crohn B B & Yarnis H (1958) *Regional Ileitis*, 2nd ed. New York & London  
 Fallis J C (1968) *Canad. J. Surg.* 11, 449  
 Fone D J (1966) *Med. J. Aust.* i, 865  
 Hollings R M (1964) *Med. J. Aust.* i, 639  
 Lockhart-Mummery H E & Morson B C (1964) *Gut* 5, 493  
 Van Patter W N, Barga J A, Dockerty M B, Feldman W H, Mayo C W & Waugh J M (1954) *Gastroenterology* 26, 347

**Extended Resection for Carcinoma of the Splenic Flexure**

by Mark J Killingback FRCS FRACS (Sydney, Australia)

This paper reports 2 cases of carcinoma of the colon where the orthodox limits of resection have been extended.

**Case 1** Man aged 64

Five months' pain in the left costal margin which was interpreted as pleurisy. Chest X-rays showed elevation of the left diaphragm and, later, irregularity of the diaphragm on the left side. A barium meal was normal but the follow-through showed deformity of the splenic flexure. A barium enema showed a large filling defect which appeared to be a carcinoma.

*At operation* a large tumour of the splenic flexure was found involving the structures in the left upper quadrant, including the lateral aspect of the abdominal surface of the diaphragm and inner part of the chest wall. There were no metastases. Laparotomy was extended into a thoraco-abdominal incision and a left hemicolectomy was carried out. This included removal of the spleen, tail of pancreas, the anterior

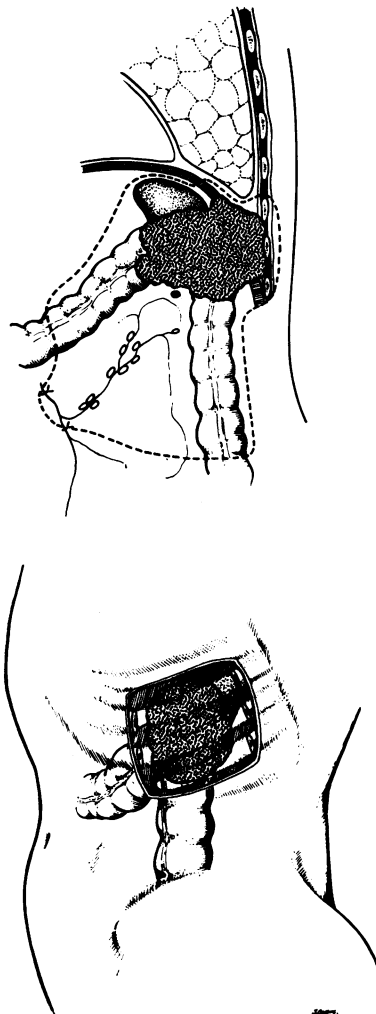


Fig 1 Case 1 Drawing showing extent of the tumour and the en bloc resection

portion of the perinephric fat and en bloc resection of the lateral third of the diaphragm with a segment of chest wall containing the 9th, 10th and 11th ribs with the intervening intercostal muscles (Fig 1). An end-to-end anastomosis of the colon was carried out. The diaphragmatic remnant was attached at a higher level above the chest wall defect, and the defect closed with a monofilament nylon darn.

*Pathology:* The tumour was 7 cm in length and of average histological grading. There was marked inflammatory change around the tumour which extended to, but did not actually invade, the periosteum of the excised ribs. One lymph node near the tumour contained a metastasis.

**Case 2** Man aged 31

Sixteen-year history of ulcerative colitis which began with ischiorectal abscesses. At 25 years of age, radiological and endoscopic diagnosis had confirmed

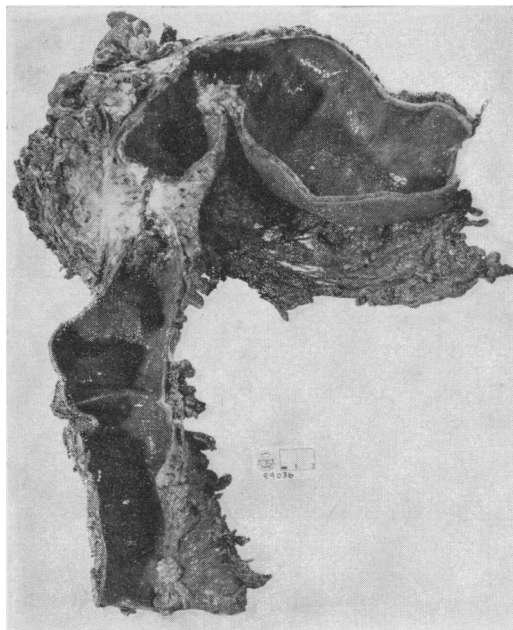


Fig 2 Case 2 Specimen showing the two carcinomas (posterior aspect), the larger one invading pericolic tissues

the presence of ulcerative colitis and one year prior to operation he had suffered an exacerbation of this. At the age of 31 he complained of some pain in the left upper quadrant of the abdomen, and barium enema showed a long stricture of the upper descending colon and a filling defect of the splenic flexure.

At laparotomy a large tumour mass was found in the left upper quadrant of the abdomen with invasion of the surrounding diaphragm and chest wall. Using a thoraco-abdominal incision a left hemicolectomy was undertaken with excision of the spleen, tail of pancreas, anterior layer of perinephric fat and portions of the diaphragm and chest wall including three ribs in this area. Because of the extent of the operation involved in the resection, a transverse colostomy was established, and the distal sigmoid colon also brought through the lower part of the wound as a colostomy. The chest wall defect was not repaired, but the margins of the chest wall were sutured to the outer parietal muscles to stop herniation of abdominal contents. The diaphragm was again attached above the chest wall defect. Subsequently this patient underwent right hemicolectomy and ileorectal anastomosis leaving a rectal stump of 12 cm.

**Pathology:** The specimen showed two carcinomas, and changes of chronic ulcerative colitis (Fig 2). The tumour was of average grade malignancy and examination of 36 lymph nodes showed no metastases. There was a marked inflammatory response around this tumour, and actual tumour substance did not invade the periostium and bone of the excised ribs.

Neither patient suffered post-operative complications, the first patient leaving hospital on

the 18th post-operative day and the second patient on the 16th post-operative day. Both are now living apparently free of metastases more than three years after resection.

Surgeons well know how close to the diaphragm and inner chest wall the splenic flexure of the colon lies. Local extension of a primary colonic carcinoma in this region may therefore involve these tissues at a relatively early stage of the disease. On the basis of these 2 cases I would recommend that its use be considered in subsequent cases as it appears to have a place in extended cancer surgery of the colon.

### Ischæmic Enterocolitis in the Newborn

by H H Nixon FRCS  
(Hospital for Sick Children,  
Great Ormond Street, London WC1)

Some years ago the newborn infants admitted to our unit would be referred when the diagnosis of organic intestinal obstruction was all too obvious. The recognition of the early intermittent obstructive course of Hirschsprung's disease was probably the first reason for referring less clear-cut cases. We now receive a considerable proportion of patients who prove not to have organic obstruction (34 of about 120 in two years in my own unit).

These functional obstructions have many causes, for example, neurogenic ileus from sepsis or from cerebral birth trauma. They may imitate small intestinal obstruction or behave more like large bowel obstruction, such as Hirschsprung's disease. Some are associated with a necrotizing lesion of the mucosa of a progressive and potentially fatal nature. It does not seem clear yet whether this ischæmic enterocolitis is a consequence of functional obstruction or whether the two conditions are distinct but not recognizably different at their onset (Table 1).

Table 1  
Functional intestinal obstruction of newborn 1967-8: 34 cases (excluding Hirschsprung's disease)

Predominant clinical picture:	No. of cases
(1) Pseudo-Hirschsprung's disease	8
(2) Small bowel obstruction	12
(3) Enterocolitis:	
Perforation	3
Diarrhoea	2
(4) Cerebral birth trauma	3
(5) Septicæmia	2
(6) Hæmolytic disease	4
Total	34