

Section of Neurology

President J E A O'Connell FRCS

Meeting November 6 1969

President's Address

Cerebrospinal Fluid Mechanics

by J E A O'Connell MS FRCS
(*St Bartholomew's Hospital, London EC1*)

Claude Bernard described blood and lymph as the *milieu interne* of the organism. There are no lymphatics in relationship with the central nervous system and there is a barrier between blood and brain. An important part of the *milieu interne* of the central nervous system is thus the cerebrospinal fluid. I hope this makes the topic I have chosen for my address a suitable one even though my remarks concern physical rather than chemical aspects of the fluid. I have been interested in the CSF pressure and circulation for a very long time and I have been fortunate during recent years in having at St Bartholomew's Hospital closely associated colleagues who have maintained my interest in the subject.

Although the existence of fluid on the surface of the brain beneath the membranes surrounding it had been noted by Egyptian physicians in the seventeenth century BC, it was not until three thousand years later that the first clear description of the fluid within the brain in its ventricles was provided by Nicola Massa in 1536 (Millen & Woollam 1962, Clarke & O'Malley 1968). In 1692 Valsalva observed the presence of spinal fluid in dogs (Veits 1935). When in 1764 Domenico Cotugno (Veits 1935) described the fluid which surrounds the spinal cord and brain and its continuity with that in the ventricles, CSF had for the first time been recognized and described. Cotugno's contribution had been largely overlooked until it was brought to notice by Magendie in 1827, as not the least admirable part of the French physiologist's own work in this field. With this basic anatomical knowledge established, studies on the production and absorption of the fluid proceeded during the nineteenth century. However, before the new knowledge

could be utilized in clinical practice, it was necessary that CSF be readily obtainable from the living patient. The introduction of lumbar puncture by Quincke in 1891 made this possible and, in the words of Ravaut, a technique of 'veritable biopsy of the nervous system was opened up'. Quincke had from the first recommended estimation of the pressure of the fluid at lumbar puncture. The introduction of ventriculography by Dandy in 1918 made the estimation of ventricular pressure increasingly frequent. Thus neurologists and neurosurgeons were provided with the opportunity of both examining the CSF and observing its pressure during the investigation of their patients. In this way interest was stimulated and increasingly sophisticated techniques were applied to elucidate the problems of the third circulation. Before passing to a consideration of the CSF pressure and circulation, which forms the basis of this address, what is believed to be the modern view of the mechanism of its production and absorption will be briefly reviewed.

CSF is a secretion produced by the choroid plexuses and not an ultrafiltrate of the plasma. Some believe that the choroidal epithelium shows histological features suggestive of secretory activity. The chemical composition of the fluid differs significantly from that of an ultrafiltrate of the plasma with higher concentrations of sodium, chloride and magnesium than has a plasma dialysate and on the other hand lower concentrations of potassium, calcium, urea and glucose (Davson 1967). Metabolic energy is expended in the transfer of sodium by the adenosine triphosphatase system and chloride by the carbonic anhydrase system and production of the fluid is diminished by drugs, such as dinitrophenol and acetazolamide which block the transport of these ions (Woodbury 1965). Finally perfusion experiments reveal that the rate of production of CSF is independent of

ventricular pressure within the range of 0–200 mm of CSF.

The rate of absorption of CSF has been shown by perfusion experiments to be directly proportional to the pressure in the system at levels between 68 and 200 mm fluid, absorption ceasing at pressures below the former figure. The fluid and all its constituents pass unselected and unchanged through the very permeable membrane of the arachnoid villi – so-called bulk flow. An osmotic effect of the serum proteins does not exist in this process of absorption since, were the CSF protein not absorbed through the villi, its concentration in the fluid would steadily rise in view of the absence of lymphatics within the dura mater (Davson 1969, personal communication).

CEREBROSPINAL FLUID PRESSURE

CSF pressure is the positive pressure exerted by the fluid throughout its containing spaces and as measured with the body in the horizontal lateral position. Its average normal adult value measured at lumbar puncture is 150 mm saline (Masserman 1935, Merritt & Fremont-Smith 1937). Values between 60 and 180 mm are considered normal by most authors. The factors responsible for the normal CSF pressure are as follows:

(1) *Forces responsible for production and absorption:* As already mentioned the rate of secretion by the choroid plexus is independent of intraventricular pressure, whereas the rate of absorption is directly proportional to this pressure, absorption ceasing at 68 mm when the pressure falls below that in the intracranial venous sinuses (Cutler *et al.* 1968). A positive CSF pressure is thus assured.

(2) *Hydrostatic pressure:* When, in the sitting position, the pressure is simultaneously measured in the lumbar and cisternal regions the values are not similar as they would be in the horizontal position, the lumbar pressure being greater than the cisternal one by a figure equal to the vertical distance between the two needles (Loman 1934). However, if the lumbar pressure is measured in the lateral and then in the sitting position the

increase in pressure will be considerably less than the height of the column of fluid above the lumbar needle would lead one to expect. In fact only 40% of the expected increase in pressure occurs (Masserman 1935). Was the CSF pressure not in some way related to atmospheric pressure no alteration in lumbar pressure would occur on a change of position from the horizontal to the vertical. The relationship, or venting, is brought about through the venous system. The venting is, however, incomplete and the hydrostatic effect of the column of fluid is thus limited.

(3) *Pressure in the veins in the cranium and spinal canal:* Since the pressure in these thin-walled vessels is fully transmitted to the CSF spaces it contributes significantly to the fluid pressure. In fact Verjaal (1944) has described the measurement of the CSF pressure as a ‘non-bloody determination of venous pressure’. A rise or fall in intrathoracic pressure is transmitted to the venous system and a corresponding rise or fall in CSF pressure occurs; thus of course is explained the effects of coughing, straining, &c, on the pressure. The relationship is well illustrated by an experiment of Verjaal to show the change in CSF pressure which occurs when from the lateral position a patient is rotated into prone and supine ones (Fig 1). In the prone position the pressure falls by 80 mm and in the supine one it rises by the same figure. The right atrium is separated from the vertebral venous plexus by a distance of 8 cm. Thus the changes in CSF pressure corresponded exactly with those of spinal venous pressure.

Experiments to demonstrate the effect of centrifugal forces on the CSF pressure similarly indicate the close relationship between the venous and fluid pressures. During a change in velocity or direction of motion forces may act on a moving body which are many times greater than the force of gravity. When an accelerative force increases the effective weight of the body threefold it is three times as powerful as the force of gravity (3 *g*). The effects of such forces on the CSF and venous pressures have been investigated (Rushmer *et al.* 1947) by rotating cats on a

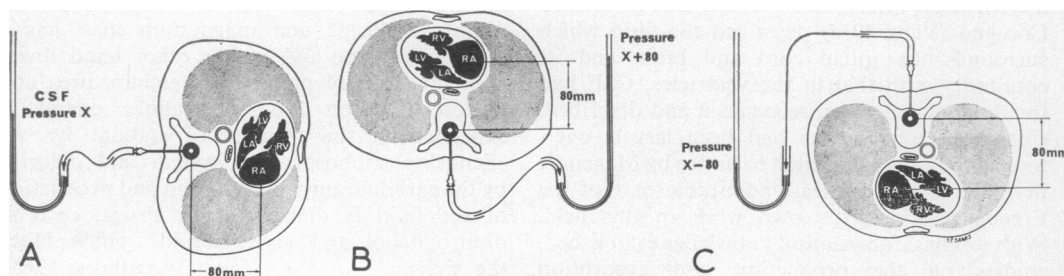


Fig 1 Alterations in CSF pressure produced by change of position from lateral, A, to supine, B, and prone, C

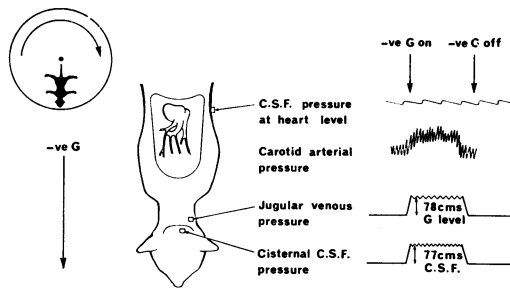


Fig 2 Effect of radial acceleration on CSF and venous pressures

centrifuge. Forces of between $-6 g$ and $+6 g$ were developed and variations in CSF pressure of from 80 cm above to 190 cm below normal were produced. Throughout this range the alterations in CSF and venous pressures were simultaneous and of the same magnitude at head and neck level, and both remained relatively unaltered at heart level (Fig 2).

(4) *Volume of arteriolar and capillary portions of the intracranial vascular bed and cerebral blood flow:* The effects of variations in the blood flow in this area are seen in the fall in the CSF pressure which occurs with syncope and on hyperventilation and the rise in the pressure which follows intravenous histamine injection, hypoxia, hypercapnia and possibly the administration of certain anaesthetic agents.

(5) *Rhythmic variations:* Finally, CSF pressure varies rhythmically with both cardiac and respiratory activity as a result of changes in the volume of the vascular bed which these occasion. These fluctuations appear to have received little attention over many years. This was probably due to the fact that they had, for the most part, been observed only at lumbar puncture, using a fine-gauge needle attached to a standpipe manometer. With this technique the cardiac variation is but 1–2 mm and the respiratory one only slightly greater. Observation of the pressure fluctuations during ventricular puncture showed that those occasioned by cardiac and respiratory activity were very much greater in the ventricles than were those seen at lumbar puncture (O'Connell 1943, 1953). Thus in a series of measurements in more than 125 patients the average fluctuation with cardiac systole was 18.5 mm and with respiration 28.5 mm. It became obvious that the difference between the findings at lumbar and ventricular puncture was due, in considerable measure, to the different dimensions of the lumbar puncture needle and the ventricular cannula. The cross-sectional area of the lumbar puncture needle utilized was less than 1 mm^2 while that of the ventricular cannula was over 3 mm^2 . A model was constructed to

determine how the bore of a channel connecting a source of fluctuating pressure with a manometer influenced the transmission of pressure changes. It was found that the smaller the bore of the connexion the less completely were the changes transmitted. Moreover, for a connexion of given bore rapid fluctuations were less well transmitted than slower ones. From these experiments it was calculated that the average true pulse variation in CSF pressure was 45 mm and the average true respiratory one 35 mm. When such rhythmic variations summate a pressure swing of 80 mm results (Fig 3). Such a figure is a considerable fraction of the normal total CSF pressure in the horizontal position and the rhythmic variations must therefore be regarded as contributing to the maintenance of this pressure.

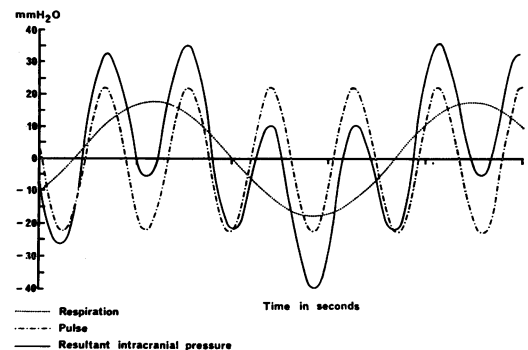


Fig 3 Curves showing fluctuations in CSF pressure with cardiac and respiratory activity and the effect of their summation

Since these observations were made during ventriculography and many of the patients subjected to this procedure had raised intracranial pressure it was possible that the observed rhythmic variations were greater than those occurring normally. However, they have been confirmed in both animals and man utilizing isovolumetric electromanometers (Goldensohn *et al.* 1951, Bering 1955). At St Bartholomew's Hospital Currie *et al.* (1967) recorded intraventricular pressure with a radiotelemetric device. A small container, which can be placed under a head dressing, holds a battery-powered oscillating circuit or radio transmitter. Pressure fluctuations falling upon a metal plate in relationship with the circuit vary the inductance of coils within it and thus the frequency of the oscillations. These are transmitted to a nearby aerial and radio receiver and converted into a written record. This technique made possible the continuous recording of the pressure, without fluid displacement from the ventricles, over long periods. In the record from a patient with

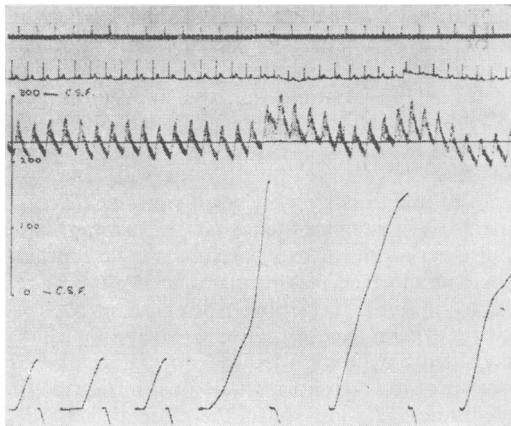


Fig 4 Radiotelemetric recording of CSF pressure

Parkinson's disease (Fig 4) the pulse variation lies between 40 and 50 mm CSF and that with respiration at rest 10–15 mm CSF, increasing to 50 mm on deep inspiration. It is thus clear that considerable rhythmic variations in CSF pressure with cardiac and respiratory activity occur normally. It is true, however, that their magnitude is increased by factors which raise the mean level of the pressure.

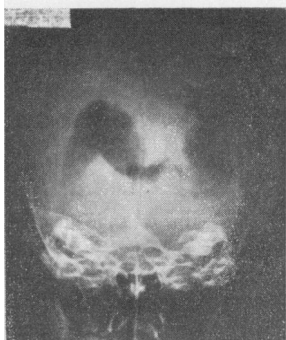
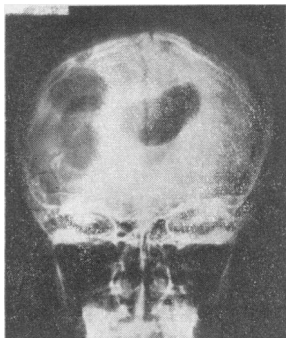


Fig 5 Case 1 Ependymoma of lateral ventricle: pre-operative ventriculogram

What is the relative importance of the various factors which contribute to the maintenance of CSF pressure? The position was well expressed by Antoni (1946): 'The pressures in the sub-arachnoid space, arteries, capillaries and venous nets have each within their own anatomical regions their respective but variable levels – the various pressures mutually reacting upon one another.' One can only add that since absorption of CSF ceases at pressures below that in the superior sagittal sinus (65–70 mm fluid) the venous pressure accounts for almost 50% of the average normal CSF pressure (150 mm) in the horizontal position. Hydrostatic pressure would be relatively unimportant in this position, and the remaining 50% of normal pressure would depend upon the secretory force, the arteriolar and capillary blood flow and the rhythmic increases in pressure with cardiac and respiratory activity.

THE CEREBROSPINAL FLUID CIRCULATION

The experimental work of Dandy & Blackfan (1914) showed that the fluid is formed in the ventricles and that when an obstruction to its flow develops the ventricle or ventricles proximal to this dilate. Obstructions occasioned by pathological processes regularly confirm these experimental observations. Indeed if even a portion of the temporal horn is separated from the remainder of a lateral ventricle it may become enormously dilated. This has been described following war wounds (Cairns *et al.* 1947); it may also follow intracranial surgical procedures:

Case 1 PB, boy aged 11.

He had had symptoms of raised intracranial pressure for a short period and on examination papilloedema without focal signs. Radiology revealed suture diastasis and ventriculography a mass in the body of the right lateral ventricle (Fig 5). An ependymoma was excised from the trigonal area with a

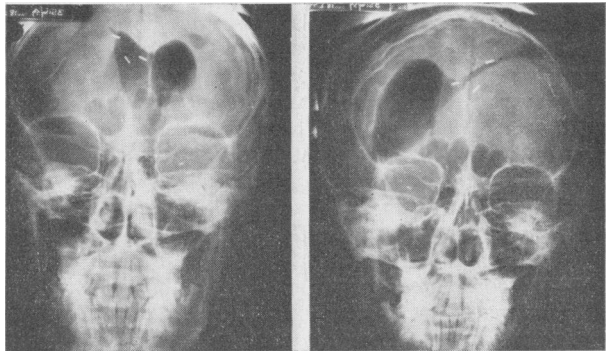


Fig 6 Case 1 Obstructive hydrocephalus of temporal horn: ventriculogram

segment of the choroid plexus to which it was adherent. Symptoms were relieved though there was a residual functional defect.

Three years later he returned with a recurrence of pressure symptoms and investigation showed a large cyst in the right temporal lobe (Figs 6, 7). Exploration revealed an enormously dilated right temporal horn separated from the body of the lateral ventricle by a thin membrane, through which bubbles of oxygen could be seen (Fig 8). A pedunculated tumour nodule a few millimetres in diameter was attached to the ependyma immediately above the membrane. The choroid plexus, membrane and tumour nodule were excised and the patient has remained well for the subsequent ten years.

Such cases indicate the power of the secretory pressure of the choroid plexus in the presence of an obstruction but they provide no measure of it in the normal state.

The total volume of CSF in man of course increases with growth and in the adult it lies between 100 and 160 ml (Lups & Haan 1954). Taking 135 ml as an average figure, 35 ml is contained in the ventricles and 100 ml in the subarachnoid space. Of the subarachnoid fluid 25 ml lies in the cranium and 75 ml in the spinal canal.

There have been widely differing opinions as to the rate of production and absorption of CSF. Some have suggested that in man as little as 20 ml is produced in twenty-four hours, while others suggest a figure of over 800 ml in this

period. The problem has been clarified by the elegant experiments of Pappenheimer and his colleagues (Pappenheimer *et al.* 1962). In these ventriculocisternal perfusion with artificial CSF was carried out in unanaesthetized animals. A known concentration of a substance of high molecular weight such as inulin, which does not diffuse into the nervous system and leaves the cerebrospinal spaces by bulk flow through the villi, was added to the perfusate entering the ventricle. Its concentration was then estimated in the fluid collected from the cistern and the amount of CSF added to the perfusate could thus be calculated. For example, if the concentration of inulin has fallen by 50% the rate of CSF production is the same as that of the experimental perfusion. Pappenheimer's perfusion technique has been utilized in man by Cutler *et al.* (1968), as well as other workers. Their observations suggest that the CSF production in man may be 500 ml per 24 hours. Thus, where the total volume of CSF is 135 ml it could be changed completely four times in 24 hours. However, it is widely accepted that the spinal fraction of the CSF lies in a backwater and circulates more slowly than the cranial fraction. The latter with a volume of 60 ml could be completely changed eight times in 24 hours. The process is thus an active one.

What can be said of the mechanism of the normal CSF circulation? Is it a pulseless flow

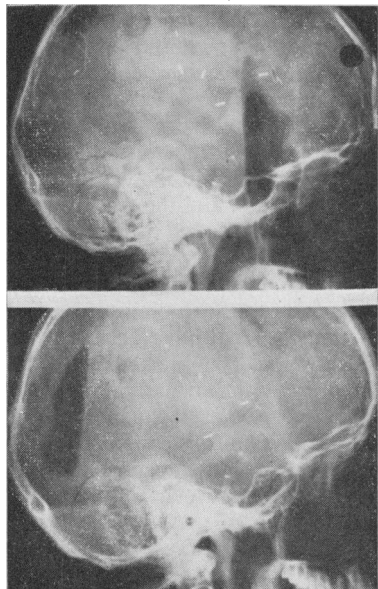


Fig 7 Case 1 Obstructive hydrocephalus of temporal horn: cystogram

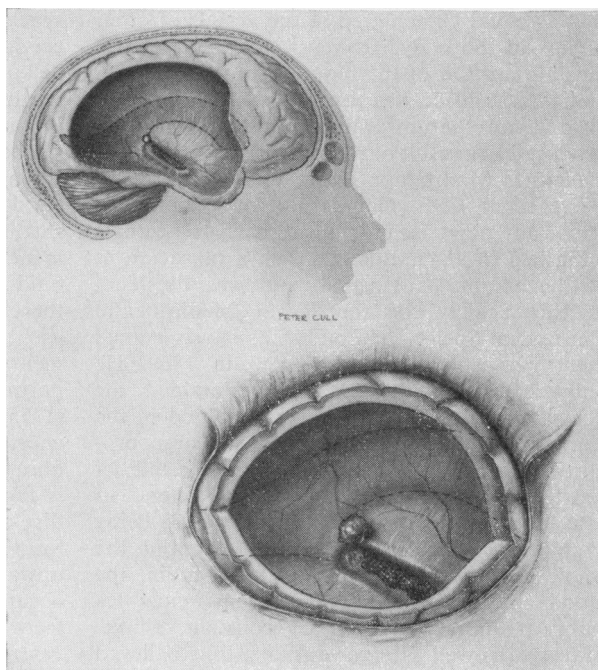


Fig 8 Case 1 Obstructive hydrocephalus of temporal horn: operative findings

from choroid plexus to arachnoid villi occasioned by the secretory pressure of the former? Is the passage of the fluid through the ventricles and subarachnoid space uninfluenced by its environment? Or do the rhythmic changes in the vascular bed in this environment play a part in the circulation? Does movement of the fluid occur when intracranial vessels dilate and CSF pressure rises?

The *Monro-Kellie* hypothesis has influenced thought in these matters for many years. Alexander *Monro Secundus* is so called because he was the second of the three Alexander *Monros* who in succession occupied the Chair of Anatomy at Edinburgh University for 126 years. He himself was Professor for 50 years and his father and son each held the position for 38 years. In 1783 a monograph on the structure and functions of the nervous system by this second member of the dynasty was published. In this it was stressed that the brain lay in a rigid container, the contents of which were at all times of the same volume. Since the brain was incompressible the volume of blood in the cranium must remain constant. In 1824 *George Kellie*, one of *Monro's* former pupils, described experiments which he considered supported the opinions of his master. Thus the hypothesis so often referred to came into existence. It should be noted that *Kellie's* experiments did not entirely support *Monro's* view. He found that it was not possible by profuse hæmorrhage to empty or nearly empty the vessels of the brain in the same way as could be achieved in the vessels of other organs of the body. However, he noted that 'a sensible portion of the blood' could be drained, and that its place was taken by both 'extra and intra vascular serum'; this serum he believed was produced as a result of the hæmorrhage.

Neither *Monro* nor *Kellie* was aware of the existence of CSF. *George Burrows* made this important point clear in his *Lumleian Lectures* published in 1846. *Burrows* was a physician at *St Bartholomew's Hospital* and was President of this Society, or the *Royal Medical and Chirurgical Society of London* as it was named then, just a hundred years ago in 1869. He pointed out that those who maintained the doctrine of a constant quantity of blood in the cranium had failed to consider the large proportion of the contents which consisted of 'extravascular serum' (CSF) and refers to *Magendie's* estimate of this volume as being from 2 to 5 ounces. He goes on to state that the whole contents of the cranium—the brain, the blood and the extravascular serum—must together at all times have a nearly constant volume. *Burrows*, as well as other authors, thus believed that the volume of blood in the cranium could increase if CSF was displaced to make room for

it. For some reason their view for long remained overshadowed by that of *Monro* and *Kellie*. *Burrows's* post-mortem observations were particularly concerned with the increased volume of intracranial blood produced by disease and revealed by congestion of cerebral vessels and in the reduction of the volume of intracranial blood with the collapse of these vessels in cases of death from hæmorrhage. However, physiological variations in the volume of intracranial blood occur rhythmically with cardiac and respiratory activity and rhythmic displacements of CSF result.

Modern neuroradiological techniques provide the evidence that such movements of CSF occur. The ventricles and subarachnoid spaces are regularly demonstrated in the investigation of patients following the injection of positive and negative contrast media for myelography, ventriculography and pneumoencephalography. The use of an image intensifier permits careful study of the spaces thus outlined and cine and videotape records can be made to allow subsequent analysis of the movements occurring within them. I have been fortunate in having *Dr George du Boulay* as a colleague. He has given much thought to such studies (*du Boulay 1966*) and given me the opportunity of observing his investigations in progress and of studying his recordings with him.

These studies reveal considerable pulsatile movement in the spinal subarachnoid space synchronous with the pulse and maximal in the cervical region. Since there is no such movement distal to a spinal block the pulsations must result from expansion of intracranial vessels. Similarly in the large subarachnoid cisterns at the base of the brain, movements of considerable extent are seen, in particular upward and downward movements in the pontine cistern. In the smaller cerebral subarachnoid spaces no movement has been observed, possibly because no fluid levels are present here, and the technique is therefore inadequate to display movements in such areas. In the ventricular system no movement is visible in the lateral ventricles in the normal. This is contrary to the findings of *Bering (1955)*: his view that the CSF pulse arises in the choroid plexus is thus not supported by these observations. The third, unlike its lateral ventricle is compressed during cardiac systole and CSF is displaced caudally from it into the aqueduct and fourth ventricle. In the latter ventricle itself upward and downward movement of the fluid occurs. This may be due to the access of fluid from above as well as the compression of the ventricle by surrounding structures.

The origin of the CSF pulse and the movements associated with it appears, in large measure,

to lie in the systolic expansion of the cerebrum and its arteries. This acts upon a background of pressure due to the factors already discussed including the fluctuations induced by respiratory activity through the venous pressure. Approximation of the thalami compresses the third ventricle and occasions displacement of CSF to the aqueduct and fourth ventricle (Fig 9). The escape of fluid from the lateral ventricles during systole is prevented by the compression of the third ventricle and no movement is visible in them. The supratentorial subarachnoid space is therefore compressed by the expanding cerebrum. CSF is displaced caudally to the safety valve of the spinal canal and the movement of fluid seen in the pontine cistern and the spinal subarachnoid space is thus explained. Would it not also be displaced to the other low pressure area – the sagittal sinus, and its lateral lacunæ – where much of its absorption occurs through the arachnoid villi? Here both the pressure waves and fluid movement could contribute to absorption. In support of such a view are the site of the lateral lacunæ of the sinus at the vertex of the skull, the carpet of villi which clothes the floor of each lacuna (O'Connell 1934) and the erosion of the skull in this area occasioned by both lacunæ and enlarged villi – the so-called arachnoid granulations (Fig 10).

These observations suggest the physiological concept of a dynamic CSF circulation in place of that of a slow percolation of the fluid from the choroid plexuses to the arachnoid villi. The pressure fluctuations must contribute to absorption, bearing in mind that this process depends entirely upon the difference between the pressures

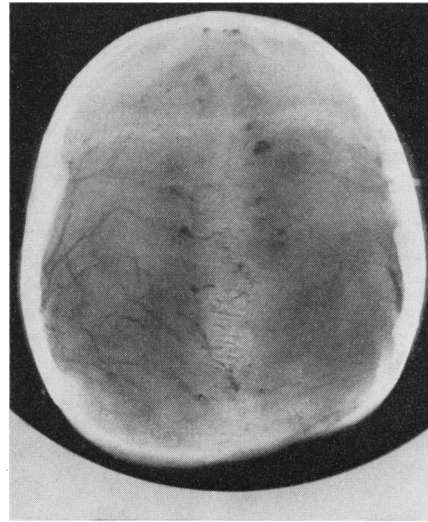

Fig 10 Vault of skull: erosions produced by arachnoid granulations and lateral lacunæ

in the subarachnoid space and in the intracranial venous sinuses. Movement of the fluid resulting from the pressure changes could facilitate absorption by occasioning displacement towards the absorptive area. From the pathological viewpoint it would seem that this dynamic concept aids in the understanding of certain cystic collections of CSF which can occasion compression of the brain and spinal cord. These cysts occur in the subarachnoid space – both intracranial and intraspinal, in the spinal extradural space, and within the brain and spinal cord. Examples of each will be described.

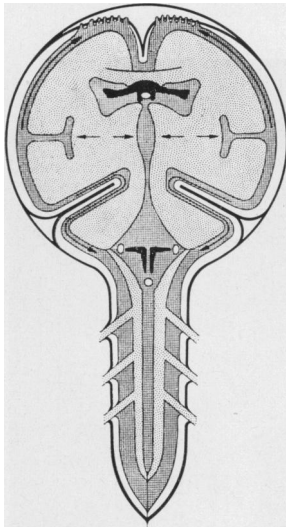


Fig 9 Diagram of cerebrospinal fluid spaces indicating possible directions of CSF displacements

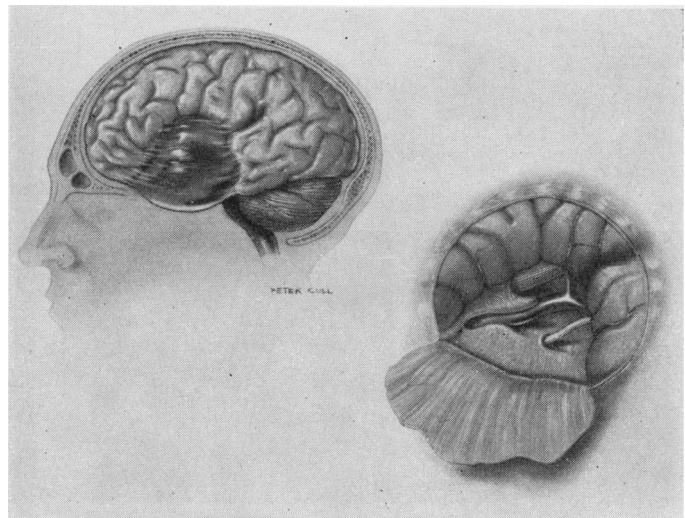


Fig 11 Case 2 Intracranial subarachnoid cyst: operative findings

**COLLECTIONS OF CEREBROSPINAL FLUID
OUTSIDE THE NERVOUS SYSTEM**

Subarachnoid Cysts

Intracranial cysts: It has for long been recognized by neurological surgeons that neoplasms may obstruct the subarachnoid space and lead to localized accumulations of CSF. The most common such lesion is the cyst which covers the postero-inferior aspect of an acoustic neurinoma. Occasionally a convexity meningioma is associated with wide local distention of the subarachnoid space by fluid, so that the tumour is dissected from the cerebrum over much of its surface and lies in a sac of fluid. Since only a

fraction of the subarachnoid space is closed by such neoplasms, the circulation of the CSF proceeds normally in other areas; the obstruction is thus by-passed, there being no general increase in CSF pressure. The secretory force which occasions distention of a ventricle or ventricles proximal to an obstruction is not active here. A local force must thus be responsible for the development of the cyst and this could well be the fluctuating CSF pressure or CSF pump. Intracranial subarachnoid cysts may occur in the absence of such neoplastic obstructions in the CSF pathways and three examples will be briefly described.

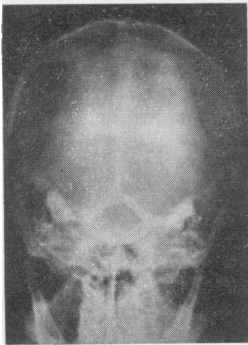
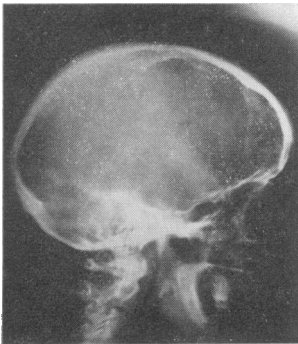


Fig 12 Case 3 Intracranial subarachnoid cyst: skull X-ray

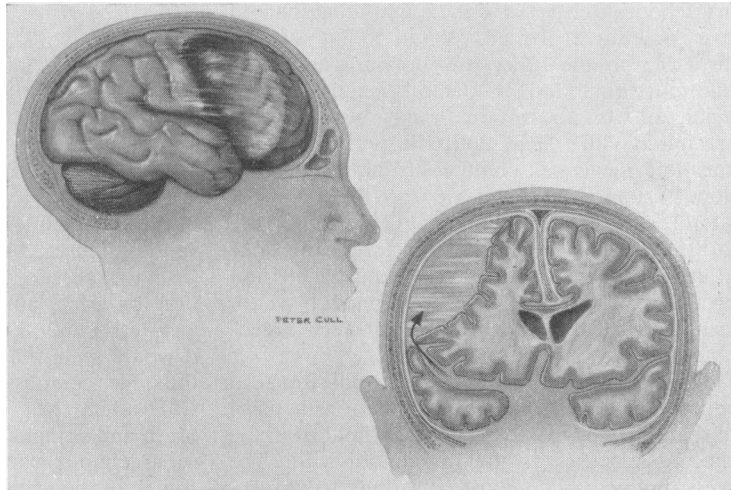


Fig 13 Case 3 Intracranial subarachnoid cyst: operative findings

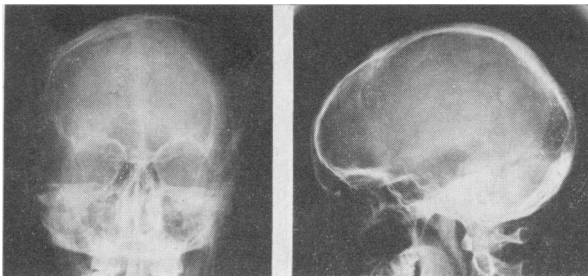


Fig 14 Case 4 Intracranial subarachnoid cyst: skull X-ray

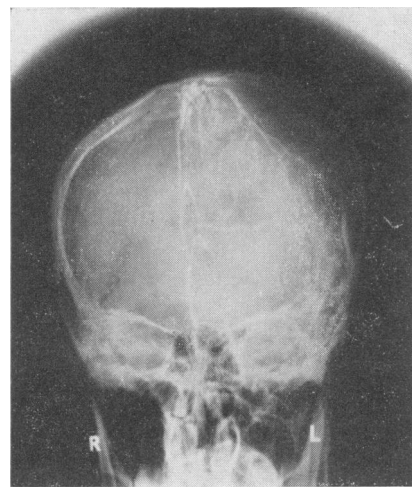


Fig 15 Case 4 Intracranial subarachnoid cyst: carotid angiogram

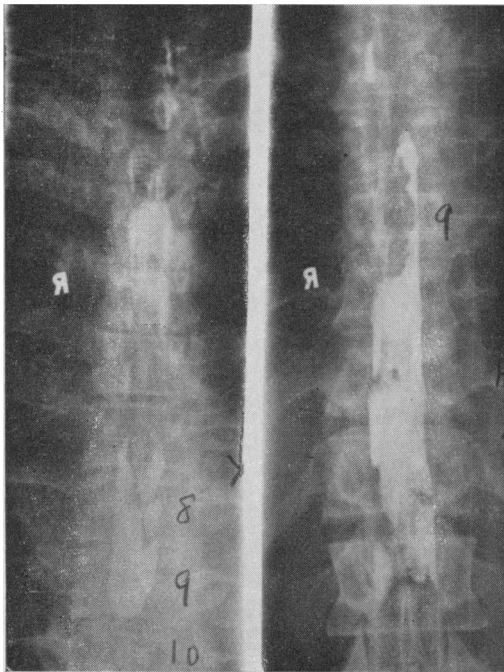


Fig 16 Case 5 Spinal subarachnoid cyst: myelogram

Case 2 A girl of 7 had been noticed for eighteen months to have a symptomless swelling in the left anterior temporal region. Radiologically there was elevation and thinning of the skull in the affected area and there was a localized EEG abnormality. Exploration revealed a large subarachnoid cyst widely opening the sylvian fissure (Fig 11). In the subsequent ten years the bony swelling disappeared.

Case 3 A woman of 55 had had frequent headache for ten years and was noticed to have a swelling in the right frontoparietal region. Skull films revealed an area of thinning and elevation of the skull in this area (Fig 12) where there was a localized EEG abnormality. Exploration revealed a subarachnoid cyst filled with clear colourless fluid (protein 80 mg/100 ml). Inferiorly fluid entered the cyst from the sylvian fissure (Fig 13). This communication was plugged, and the thickened arachnoid excised. Post-operatively she continued to have headache.

Case 4 A 16-year-old boy had lost consciousness for some minutes on two occasions during a twelve-month period. His parents considered that he had always been slow and clumsy in using his right hand. Examination showed a mild spastic weakness of the right arm, and skull films elevation and thinning of the right parietal region where angiography showed a large extracerebral mass (Figs 14, 15). Craniotomy exposed a cyst containing clear colourless fluid (protein 21 mg/100 ml). Its outer wall was of thickened arachnoid adherent to the dura mater and its deep wall cerebrum covered by thin pia mater except centrally where white matter was exposed. The cavity

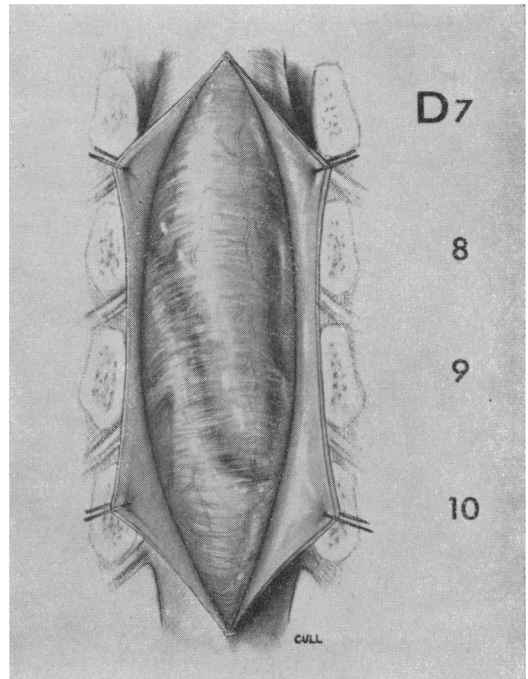


Fig 17 Case 5 Spinal subarachnoid cyst: operative findings

was drained into the ventricle. Post-operatively signs disappeared and he remains well with no recurrence of epilepsy.

It is suggested that these cysts, like those related to intracranial neoplasms, develop proximal to local obstructions in the subarachnoid channels as a result of distention produced by rhythmic pressure changes.

Spinal subarachnoid cysts: Cystic collections in the subarachnoid space also occur in the spinal canal lying on the dorsal surface of the spinal cord. Since they usually communicate freely with the subarachnoid space rostrally it has been suggested that they be called subarachnoid pouches.

Case 5 A 56-year-old man complained of back and perineal pain, weakness, numbness and tingling in his legs and unsteadiness of gait. The symptoms had increased in severity over six months. Examinations showed increasing evidence of a spinal cord compression at the 9th dorsal segment. Myelography, both lumbar and cisternal, showed an arachnoid pouch at the level of the ninth dorsal vertebra (Fig 16). There was also evidence of scattered arachnoiditis below the fifth dorsal vertebral level. This pouch had produced a complete subarachnoid block, the cisternal CSF protein being 30 mg/100 ml and the lumbar 300 mg/100 ml. Laminectomy revealed a wide subarachnoid space crossed by a septum, above which

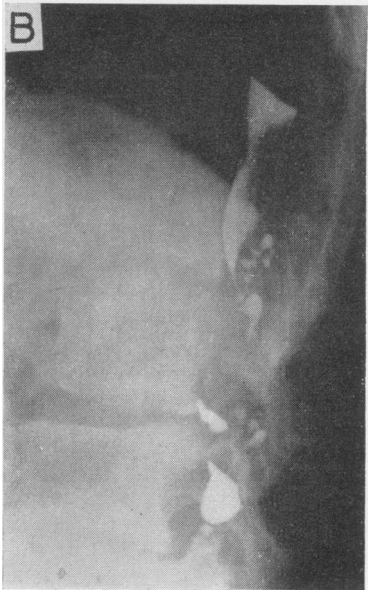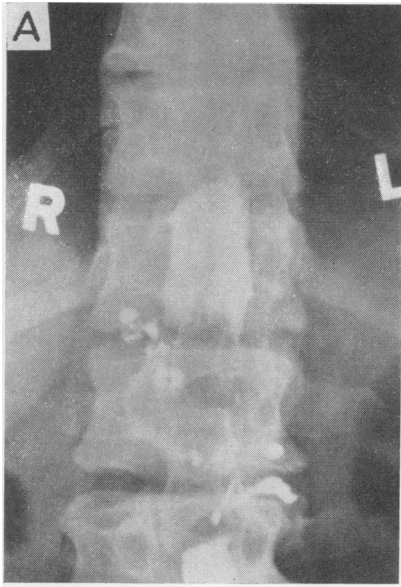


Fig 18A, B Case 6 Spinal extradural cyst: myelogram

the cord was flattened (Fig 17). The arachnoid septum was excised and the patient made a complete recovery, remaining well six years later.

Why should such pouches develop in a CSF backwater, the spinal subarachnoid space, from which no appreciable absorption of the fluid takes place? Some force dilates the subarachnoid space proximal to the obstruction to form the pouch and with its enlargement compression of

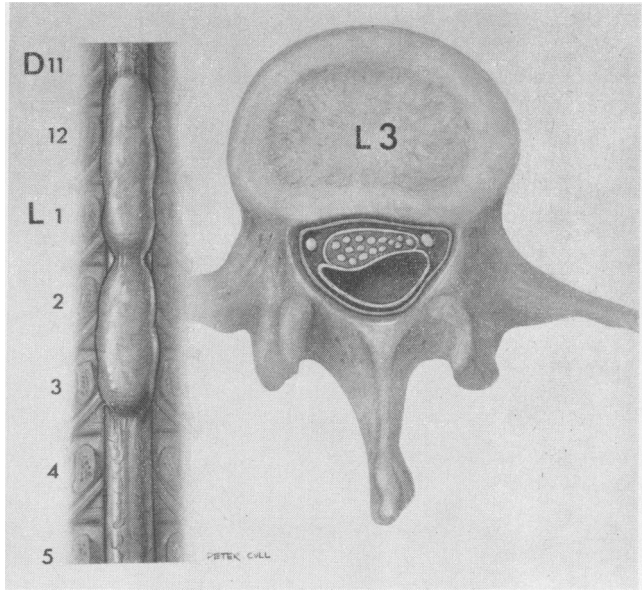


Fig 19 Case 6 Spinal extradural cyst: operative findings

the spinal cord occurs. The rhythmic pressure fluctuations in the fluid column above the obstruction could be the force responsible.

Spinal Extradural Cysts

Several types of spinal cysts lying in the extradural space and containing CSF are known to occur. Examples of two of these will be described.

Case 6 A 54-year-old man gave a history of transient pains in the anterior thighs five years previously. Progressive weakness of the legs followed and there was associated tingling and numbness, but no sphincter disturbance. Examination showed atrophy and weakness of both lower limbs, maximal in the quadriceps and adductor muscles, with reduction of sensibility below the second lumbar dermatome and absent knee and ankle jerks. There was no subarachnoid block, the CSF protein being 110 mg/100 ml. Myelography showed a mass posterior to the theca at the level of the last dorsal and upper lumbar vertebrae (Figs 18A, B). At laminectomy a tense thin-walled extradural cyst was found and contained clear fluid with a protein content of 80 mg/100 ml. It communicated with the subarachnoid space through dural openings on each side close to the dural sheaths of the first lumbar nerves (Fig 19). The cyst, 15 cm in length, was dissected from the dura and excised completely. Histologically its wall resembled dura mater. Over thirteen years post-operatively the severe quadriceps wasting and weakness persist, but other symptoms have remained relieved.

Case 7 A 24-year-old woman had had lumbosacral pain for five months and a rapidly progressing weakness and numbness of her legs, which rendered her

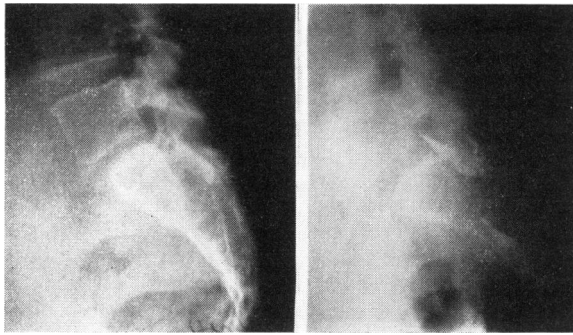


Fig 20 Case 7 Spinal extradural cyst: spinal film and myelogram

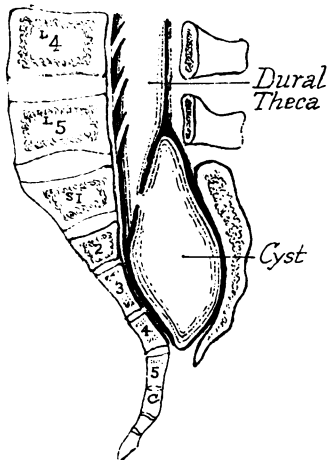


Fig 21 Case 7 Spinal extradural cyst: operative findings

unable to walk. There was no sphincter disturbance. Examination showed a severe atonic paraparesis with a reduction of all sensory modalities below the third lumbar dermatome. Radiology showed widening of the sacral canal and myelography a sacral cyst in communication with the subarachnoid space (Fig 20). At operation an extradural cyst was found extending from the fifth lumbar to the fourth sacral vertebra and lying on the posterior aspect of the theca (Fig 21). Proximally it communicated with the subarachnoid space through a median valvular opening – fluid readily flowing into the cyst from above but not in the reverse direction. The cyst was excised and complete recovery followed.

It seems probable that a congenital defect in the dura mater was present in these cases. However, since symptoms arose in adult life and progressively increased, some force responsible for the enlargement of the cysts related to the dural defects seems necessary. Again, perhaps this force is provided by the rhythmic fluctuations in CSF pressure.

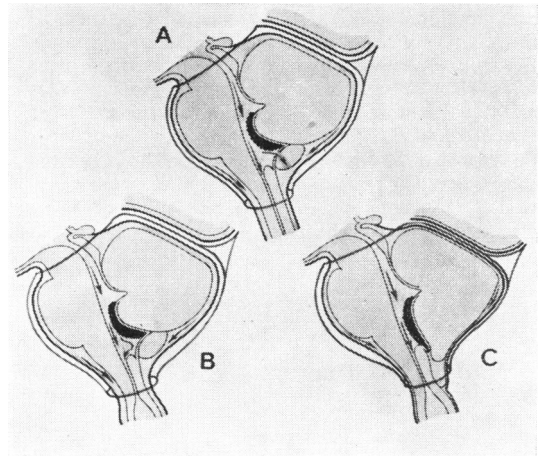


Fig 22 Hydromyelia and syringomyelia. A, normal state. B, occlusion of foramen of Magendie. C, Tonsillar herniation or ectopia

COLLECTIONS OF CEREBROSPINAL FLUID WITHIN THE CENTRAL NERVOUS SYSTEM

Intramedullary collections – hydromyelia and syringomyelia: In recent years the pathology of hydromyelia and syringomyelia has aroused the interest of neurosurgeons (Gardner & Angel 1959, Newton 1962, 1969, Appleby *et al.* 1968). New light has been thrown on the pathogenesis of the lesion in some of these cases. Typically the cavity in the spinal cord and brain stem is a dilated central canal or a diverticulum of this – a syrinx – and contains a fluid identical with CSF (Fig 22). It is suggested that dilation of the central canal may occur when it communicates with the fourth ventricle and when the escape of CSF from the ventricle is prevented by a membrane occluding the foramen of Magendie. It could also occur when the escape of CSF from the posterior fossa is prevented by tonsillar herniation or ectopia. In both circumstances the pulse wave forces fluid into the central canal and hydromyelic distension of it occurs. I know that

Dr du Boulay and Dr Shah are studying this problem and I will not refer to it further here. In some cases encouraging results have followed surgical treatment designed to decompress the region of the foramen magnum and facilitate discharge of CSF from the fourth ventricle.

Intracerebral collections – paraventricular cysts: Collections of CSF may develop in the white matter of the cerebral hemisphere in relationship with the lateral ventricle and occasion the clinical picture of a space-occupying lesion.

Case 8 A 45-year-old man had for five years noticed a progressively increasing weakness of his right leg. Examination revealed only a severe spastic paresis of the right leg with an extensor plantar response. Electroencephalography showed a left parietal focus of delta activity and carotid angiography an avascular mass in the same area. At craniotomy the gyri were widened and flattened and a cavity containing clear fluid (protein 20 mg/100 ml) was tapped at 2 cm from the surface. The cortex was incised and a large smooth-walled cyst entered, over 100 ml of fluid being evacuated (Fig 23). The lining was everywhere smooth

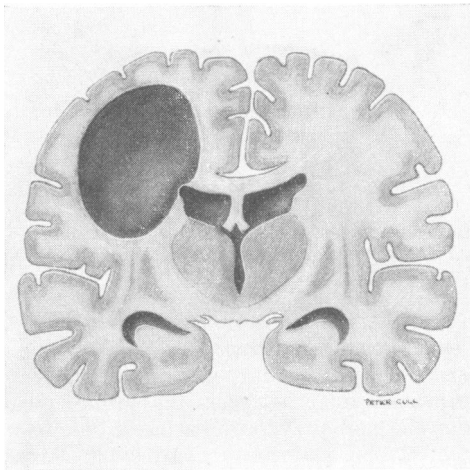


Fig 23 Case 8 *Paraventricular cyst: operative findings*

and pale except at one point where an oval vesicle of the ependyma of the lateral ventricle, some 5 mm in length, projected into it. The cyst cavity and the lateral ventricle were brought into communication by a linear incision. Complete recovery occurred and persists after ten years.

Why should the cerebrum be progressively compressed by a collection of CSF within it? In the presence of a defect in the ependyma or subependymal tissues it is possible that, as a result of the rise in intraventricular pressure during cardiac systole, CSF is forced outwards into the centrum ovale. If a valvular opening

may be assumed, an increasing collection of fluid slowly develops.

Summary

Cerebrospinal fluid pressure is, in a given position, not constant but fluctuates rhythmically with changes in the calibre of intracranial vessels. These pressure changes are associated with displacements of cerebrospinal fluid within the cranium and spinal canal. It is believed that both the pressure changes and the fluid displacements assist in the maintenance of the cerebrospinal fluid circulation. In addition, they may explain the development of certain cystic collections of cerebrospinal fluid which progressively enlarge – deforming the cranium or compressing the brain or spinal cord.

Acknowledgement: I am indebted to the Department of Medical Illustration of St Bartholomew's Hospital, and particularly to Mr Peter Cull, for the preparation of the illustrations in this paper.

REFERENCES

- Antoni N (1946) *Acta med. scand. Suppl.* 170, 439
 Appleby A, Foster J B, Hankinson J & Hudgson P (1968) *Brain* 91, 131
 Bering E A jr (1955) *Arch. Neurol. Psychiat. (Chic.)* 73, 165
 Burrows G (1846) *On Disorders of the Cerebral Circulation.* London
 Cairns H, Daniel P, Johnson R T & Northcroft G B (1947) *Brit. J. Surg. War Surgery Suppl.* 1, 187
 Clarke E S & O'Malley C D (1968) *The Human Brain and Spinal Cord.* Berkeley & Los Angeles
 Currie J C M, Riddle H & Watson B W (1967) *J. Physiol.* 189, 22P
 Cutler R W P, Page L, Galicich J & Watters G V (1968) *Brain* 91, 707
 Dandy W E (1918) *Ann. Surg.* 68, 5
 Dandy W E & Blackfan K D (1914) *Amer. J. Dis. Child.* 8, 406
 Davson H (1967) *Physiology of the Cerebrospinal Fluid.* London
 du Boulay G H (1966) *Brit. J. Radiol.* 39, 255
 Gardner W J & Angel J (1959) *Clin. Neurosurg.* 6, 131
 Goldensohn E S, Whitehead R W, Parry T M, Spencer J N, Grover R F & Draper W B (1951) *Amer. J. Physiol.* 165, 334
 Kellie G (1824) *Trans. med.-chir. Soc. Edinb.* 1, 84
 Loman J (1934) *Arch. Neurol. Psychiat. (Chic.)* 31, 679
 Lups S & Haan A M F H (1954) *The Cerebrospinal Fluid.* Amsterdam
 Magendie F (1827) *J. Physiol. exp. path. (Magendie)* 7, 66
 Masserman J H (1935) *J. comp. Neurol.* 61, 543
 Merritt H H & Fremont-Smith F (1937) *The Cerebrospinal Fluid.* Philadelphia & London
 Millen J W & Woollam D H M (1962) *The Anatomy of the Cerebrospinal Fluid.* London
 Monro A (1783) *Observations on the Structure and Functions of the Nervous System.* Edinburgh
 Newton E J (1962) *J. Neurol. Neurosurg. Psychiat.* 25, 185
 (1969) *Ann. roy. Coll. Surg. Engl.* 44, 194
 O'Connell J E A (1934) *Brain* 57, 484
 (1943) *Brain* 66, 204
 (1953) *Brain* 76, 279
 Pappenheimer J R, Heisey S R, Jordan E F & Downer J de C (1962) *Amer. J. Physiol.* 203, 763
 Quincke H (1891) *Verh. dtsh. Kongr. inn. Med.* 10, 321
 Rushmer R F, Beckman E L & Lee D (1947) *Amer. J. Physiol.* 151, 355
 Verjaal A (1944) *Geneesk. Bl.* 11, 41c, 965
 Viets H R (1935) *Bull. Hist. Med.* 3, 701
 Woodbury D M (1965) In: *Physiology and Biophysics.* Ed. T C Ruch & H D Paton. Philadelphia; p 942