

Volkman's Ischaemia*

Sir HERBERT SEDDON, C.M.G., D.M., M.A., F.R.C.S., F.A.C.S.(HON.)

[WITH SPECIAL PLATE]

Brit. med. J., 1964, 1, 1587-1592

It is a distinction to be invited to deliver a lecture such as this, but for me this occasion, when we are met to honour the memory of Ruscoe Clarke, is particularly welcome. It gives me the opportunity to express what I have felt over many years, my admiration for the Accident Hospital in Birmingham, where Ruscoe Clarke made his name.

Although the value of special hospitals is increasingly and often rightly being questioned, it is undeniable that in the development of medicine, particularly in Great Britain, their influence has been profound. They came into being to meet particular needs, and were staffed by men who had set themselves to deal with some unusually baffling or urgent afflictions. A notable example is the National Hospital for Nervous Diseases, Queen Square, which recently celebrated its centenary. In years the Accident Hospital is still a youngster; in achievement it has attained adult stature. It seems to me that Ruscoe Clarke epitomizes all that is good, and how much there is, in Birmingham's and William Gissane's great venture.

I confess with sorrow, and with growing consciousness of how much poorer I am because of it, that I never knew Ruscoe Clarke intimately. My tribute to him cannot therefore be personal, though what I have learned has moved me deeply.

Here was a man who from his student days pursued a well-charted course unmarred by fruitless digression and never becalmed in a Sargasso Sea of sloth or dull routine. By ordinary reckoning it was tragic that he was cut off at the age of 51, but renown has been achieved in far shorter lives.

We live in deeds, not years; in thoughts, not breaths;
In feelings, not in figures on a dial.
We should count time by heart-throbs. He most lives
Who thinks most—feels the noblest—acts the best.¹

Clinical research is one of the toughest disciplines. The care of the sick demands unremitting attention; it cannot be put in the strait-jacket of a time-table, and it is never more urgent and unpredictable than in the treatment of accidents. Research calls for an orderly way of life, freedom from distraction, and time for reflection. These are incompatibles. But we all know men who have combined arduous clinical work with patient and fruitful investigation. Ruscoe Clarke was one of them; they are the salt of the earth.

Sometimes this harmony arising out of irreconcilables has its roots in religious conviction. Christianity furnishes us with many great examples. Ruscoe Clarke was an ardent Communist. To me this is incomprehensible; yet in this Laodicean day we are rebuked by the sincerity of a devotion which was worthy of a nobler faith and which may have inspired his work. One of his junior colleagues told me that "his political views were well known, but we all respected the way in which he expressed them only when required or when invited to do so. Indeed

he advised me against using him as a referee in case I were judged to share his views." This same man wrote: "He was an unsuspectedly kind and sympathetic man and gave a number of lame dogs unobtrusive but most valuable help; he had a very good idea how people felt and thought inside." A splendid tribute.

VOLKMANN'S ISCHAEMIA

Volkman's ischaemia is one of those horrible complications of injury that we say ought not to occur. The plain fact is that it does so, sometimes because it is inevitable, more often because of some lapse in vigilance. It is worth looking this ugly spectre straight in the face, and I propose to speak first about its morbid anatomy, then aetiology and prevention, and, lastly, though briefly, of the treatment of the established condition.

Morbid Anatomy

The lesion of Volkman's ischaemia is a circumscribed deep-seated affection of voluntary muscle and to a lesser degree of other tissues in the ischaemic zone. In its grossest form it differs from gangrene only in that the necrotic area is encased in a fibrous envelope with more or less normal superficial tissues. The general shape of the infarct—for that is what it is (Tavernier, Dechaume, and Pouzet, 1936)—is an ellipsoid with its main axis in the length of the limb (Seddon, 1956). It can vary in size from a few centimetres to almost the full length of a segment of a limb, and the severity of the damage can be anything from mild fibrosis up to total necrosis; and, as might be expected, the damage is greatest at the centre and least at the periphery.

The level of the infarct is variable, though it most often occurs in the distal two-thirds of the forearm or leg. Naturally, this depends on the level of the vascular damage. In the case depicted in Fig. 1 a severe mining injury at the wrist caused an ischaemia limited to the intrinsic muscles of the hand.

Muscle

These changes are so striking that they have for long overshadowed those in other tissues.

Reversible Damage.—The clinical behaviour of many patients with Volkman's ischaemia is alone sufficient to prove that recovery from mild ischaemia can and often does occur. Most of us have seen patients with the usual forearm ischaemia with, initially, more or less extensive paralysis of the extensor muscles which clears up within a few months. It is because of this that we must wait before contemplating any operative treatment. Elsewhere (Seddon, 1956) I have given a full account of a boy of 5 who presented with a total paralysis of the forearm

* Fourth Ruscoe Clarke Memorial Lecture delivered at the Royal College of Surgeons of England on 23 May 1963.

¹ Philip James Bailey: *Festus*.

and yet recovered good power in all of his muscles in just under one year. It is not justifiable to carry out the repeated biopsies that would be required to show exactly what happens histologically; but, fortunately, the process of regeneration after muscle ischaemia in animals, first observed by Kirby (1892), has been worked out very thoroughly by Clark and Blomfield (1945), and a few incidental observations that I have made show that the same process may occur in a feeble way at the periphery of a massive infarct; and it appears that regeneration is not dependent on the muscle being innervated (Saunders and Sissons, 1953).

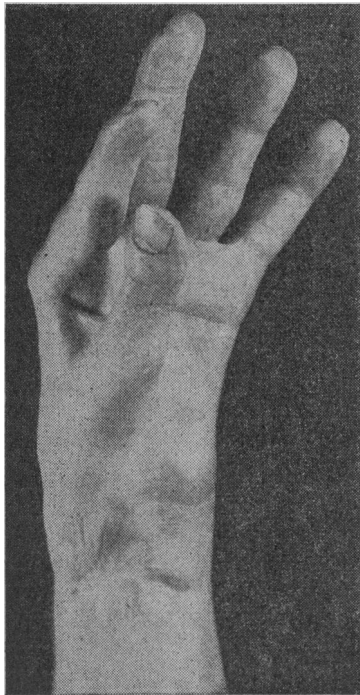

FIG. 1.—Ischaemia of intrinsic muscles of hand resulting from severe injury at the wrist in a miner who was under the care of Professor J. I. P. James, by whose courtesy this photograph is reproduced. (T.W. 74096. R.N.O.H.)

Mild Fibrosis.—This is usually a fairly diffuse change which does not preclude spontaneous recovery of the muscle; it reveals itself clinically by the development of a contracture in muscles whose power gradually returns to something approaching normal. The extensor muscles of the forearm often recover completely, while the flexors recover useful power but are shortened. The clinical picture is contracture, and contracture alone.

Severe Fibrosis.—Here the fibrosis is so profound that the muscle is virtually destroyed. For all practical purposes the muscles become converted into a shortened fibrous mass. The clinical picture is contracture plus paralysis.

Necrosis.—The muscle is completely dead, and when contracture occurs it is not in the necrotic part but in the less ischaemic fibrotic muscle that envelops it. From this same fibrous layer phagocytic invasion of the necrotic core takes place and it is possible that the necrotic tissue may be removed completely, the muscle then finishing up as a fibrotic band. However, if this absorption does not take place the necrotic muscle becomes a glutinous or pulpy mass which may calcify so that the centre of the lesion is like toothpaste or almost solid grit (Special Plate, Figs. 1 and 2). Many years later a large cyst may form; I have never seen this, but two examples in the lower limb have been described by Gallie and Thomson (1960).

Nerve

Next in importance are the ischaemic changes in nerve.² Their frequency in the forearm—it is much the same in the leg—is indicated in Fig. II, and it will be noted that the ulnar nerve, lying at the periphery of the infarct, is rather less vulnerable than the median and more likely to recover spontaneously. As might be expected, the severity of the nerve damage depends on the degree of muscle ischaemia.

There has been some controversy about what happens to nerves in Volkmann's ischaemia. Some observers—for example,

Bateman (1962, pp. 95–98)—have supposed that they are compressed by the fibrotic muscle, and if attention is confined to the median nerve in the forearm to the exclusion of all others it certainly looks like that—superficially. The points against this theory are the following:

(a) The paralysis comes on immediately, long before fibrosis begins. If it is the swelling of the forearm muscles that damages the nerve initially, the compression being kept up by the subsequent

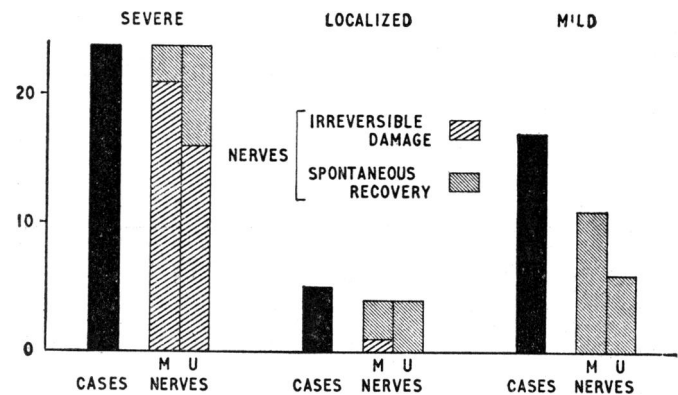


FIG. II.—Frequency of ischaemic involvement of the median and ulnar nerves.

fibrosis, then one ought to expect transient paralysis due to swelling alone in the numerous fractures that cause pronounced oedema but not ischaemia. This has not been recorded.

(b) Involvement of the ulnar nerve, though less frequent than that of the median, occurs fairly regularly, and, as we have found repeatedly on exploration, the nerve lies at the edge of the infarct and is rarely encased by fibrous tissue. The posterior tibial nerve may be similarly affected proximal to the ankle, and exploration at this level does not usually reveal evidence of compression. Lastly, in one patient whose arm was so severely damaged that amputation was necessary I found that the infarct extended well down into the palm of the hand; and here, as appears in Figs. 3 and 4 (Special Plate), the nerve showed ischaemic changes at a level where there was no muscle at all to compress it. However, it is possible that the intense fibrosis of the muscles surrounding the median nerve in the forearm may add to its troubles by strangulation, so aggravating the damage produced by the original ischaemia. I do not therefore reject the stories of recovery of the median nerve after incision of the forearm muscles and decompression of the nerve.

(c) The strongest proof that the nerves are damaged by ischaemia is the peculiar appearance they present histologically (Special Plate, Fig. 4). There is an extensive, sometimes complete, replacement of the Schwann tubes by collagen, which is not the appearance of a nerve damaged by compression alone (Holmes, Hight, and Seddon, 1944). Moreover, identical ischaemic collagenization has been observed in the median nerve as a result of injury of the anterior interosseous artery, the surrounding muscles not being ischaemic (Seddon and Holmes, 1945).

Mild ischaemia causes no more than Wallerian degeneration indistinguishable from that following severance or compression of a nerve. But it is rarely possible to prove this in man because one cannot tamper with nerves unless they are irreparably damaged. The fact that good recovery occurs with considerable frequency is in itself sufficient proof of the benignancy of the damage. I obtained histological confirmation in two cases, by biopsy of a small branch of the median nerve during the course of an exploration of the forearm.

In more severe ischaemia the nerve is shrunken (Special Plate, Fig. 5), often over several centimetres, to about half of its normal diameter, and then it is likely that the damage is permanent. The narrowing is greatest in the centre of the ischaemic zone, whereas the supposedly harmful fibrosis is always more extensive. However, this narrowing alone should not be accepted as the sole criterion. Exploration of these nerves is done with the circulation arrested. When the nerve is exposed the pressure bag should be deflated and the vascularity of the nerve observed. If it flushes well then there is

² In our earlier work on this subject we were remiss in having failed to study the papers of Tavernier and his colleagues (listed in the references), which contain what appears to be the first clear account of the ischaemic nature of the nerve lesions in Volkmann's syndrome.

Sir HERBERT SEDDON: VOLKMANN'S ISCHAEMIA

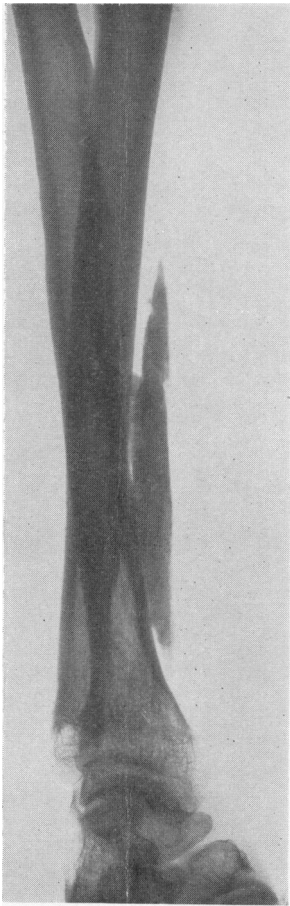


FIG. 1.—An infarct that has calcified.

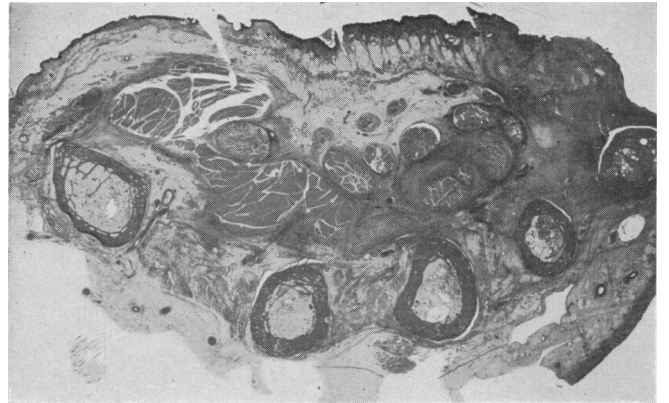

FIG. 3A

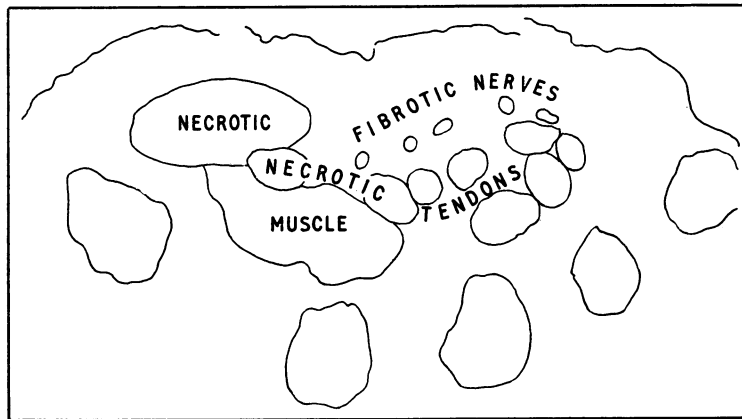


FIG. 3B

FIGS. 3A, 3B.—The distal end of an enormous infarct involving the whole of the forearm. The thenar muscles are necrotic, and the branches of the median nerve, which are not compressed by anything, show the collagenization characteristic of ischaemia. The flexor tendons are also necrotic.

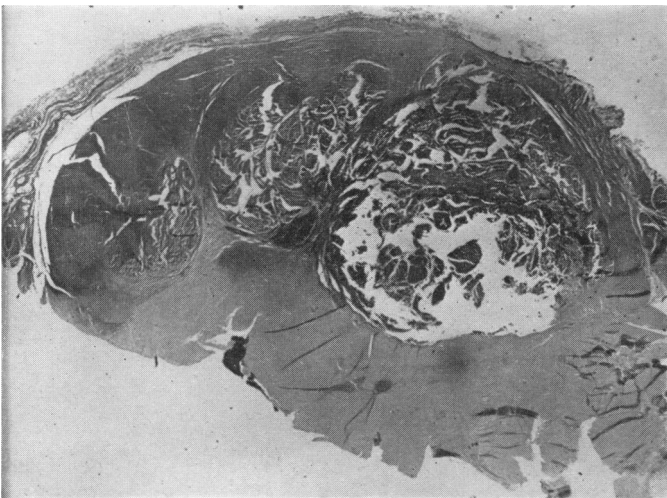


FIG. 2

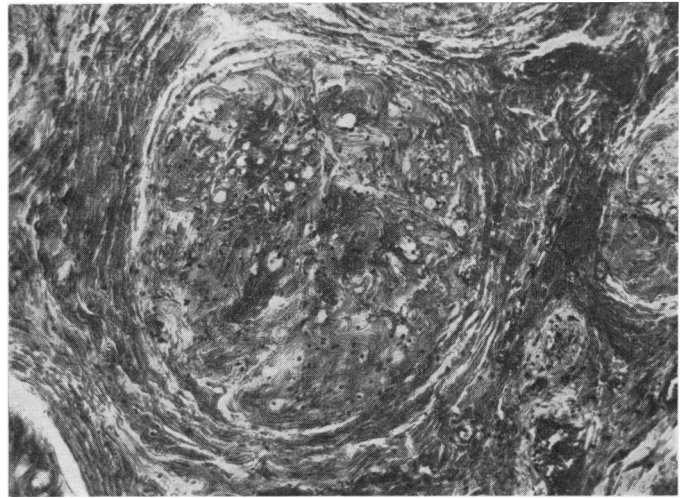


FIG. 4

FIG. 2.—Section of a calcified infarct.

FIG. 4.—Section of one of the digital nerves shown in Fig. 3.

FIG. 5.—A shrunken ischaemic median nerve in the mid-forearm. (Reproduced by permission of the British Editor of the *Journal of Bone and Joint Surgery*.)



FIG. 5

Sir HERBERT SEDDON: VOLKMANN'S ISCHAEMIA

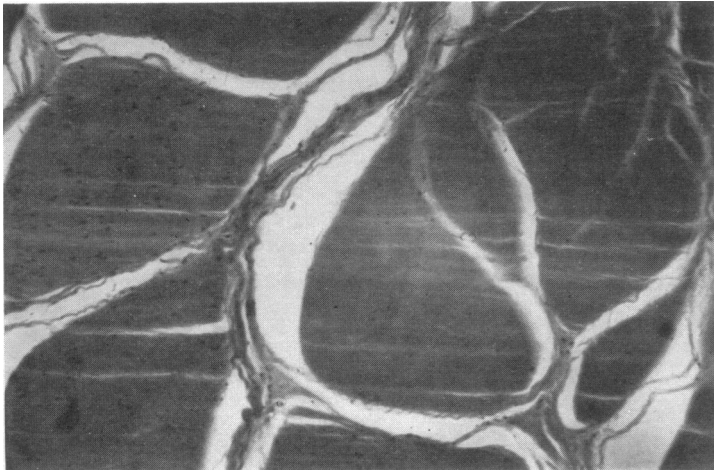


FIG. 6.—Ischaemic tendon: right half of photomicrograph.

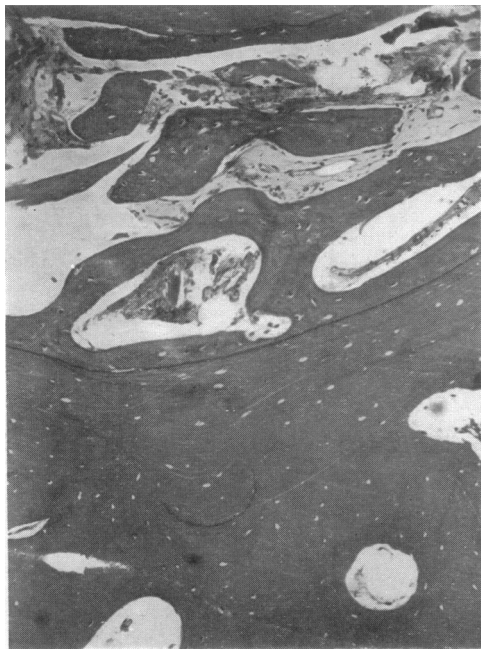

FIG. 7.— Ischaemic bone: the bone in the lower half of the field is completely acellular.

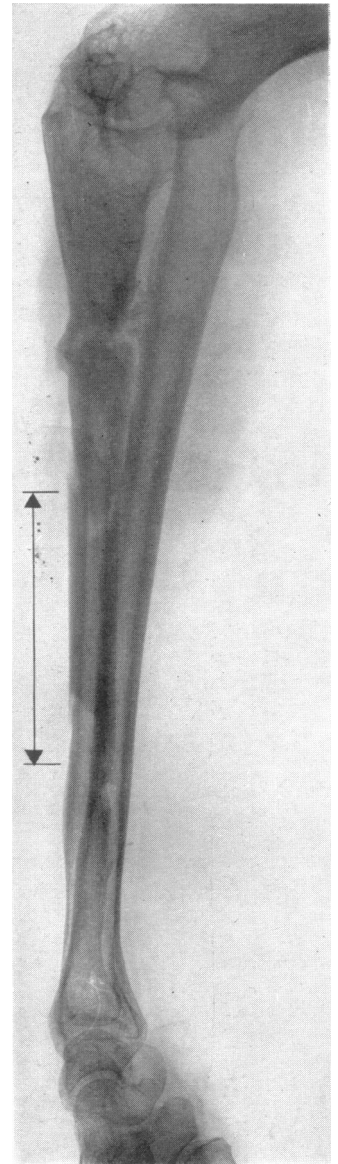


FIG. 8.—Infected Volkmann's ischaemia. The bone involved in the infarction has separated as a sequestrum (indicated by arrows).

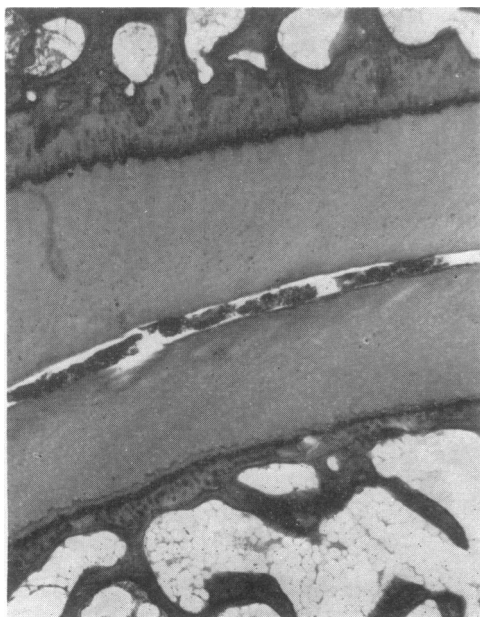


FIG. 9.—Articular cartilage in the ischaemic zone. The lower layer of cartilage is almost completely acellular.



FIG. 10.— Ischaemic changes in subcutaneous tissues. The fat has been largely replaced by fibrous tissue.

a possibility of spontaneous recovery and no repair should be undertaken. If, on the other hand, a reach of the nerve remains a dirty yellowish white, and if through magnifying spectacles no small vessels can be observed in it, then the damage is permanent.

In the centre of a massive infarct a nerve may be frankly necrotic, so completely dead as to show no morphological change except dissolution of the Schwann cells. However, it must never be assumed that because there is gross damage of the flexor muscles in the forearm, the median nerve, running through the middle of the infarct, is inevitably destroyed. The vulnerability of nerve is considerably less than that of muscle, and in a few cases in which it was necessary to excise almost all of the muscles in the anterior compartment of the forearm preliminary examination of the median nerve showed that it was not completely ischaemic; it was left alone and recovery occurred.

Involvement of other tissues is far less important but not without interest.

Other Tissues

Tendon.—A very extensive infarct may cause necrosis of tendons (Special Plate, Figs. 3 and 6), but this is usually of no practical consequence because with damage of such extreme severity the limb will be totally useless and better amputated.³ Indeed, it was only in the examination of amputation specimens that I came across these changes. There is, however, another sort of damage to tendons that can plague the surgeon when he sets about the reconstruction of an ischaemic limb. At the edge of the infarct there is always a zone of fibrosis and not infrequently its distal pole is very near the wrist or ankle. The consequence then is that fibrous tissue forms in tendon sheaths, gluing the tendons together and so spoiling the field for tendon transplantation. In the lower limb the characteristic deformity after ischaemia of the calf is equinus or equino-varus. The deformity—as in the forearm—is due to contracture of the muscles, but if an exploration is performed with a view to correcting it a formidable obstacle is the dense mass of adhesions at the back of the ankle-joint involving the flexor tendons.

Bone.—Ischaemia involving bone was mentioned by Nario (1938) in his description of ischaemia produced experimentally in dogs. It is usually unimportant (Special Plate, Fig. 7) and cannot be detected either clinically or radiographically. But if there happens to be a fracture at the same level as the infarct the bone will unite either slowly or not at all. Volkman's ischaemia of the forearm is common in India and the Middle East, as a result of bone-setters having applied tight splints for a forearm fracture. A young Indian friend of mine collected over 50 such cases in a little under two years. It is difficult

³ Mr. Geoffrey Fisk has recently told me of a patient of his who suffered what appeared to be ischaemic damage confined to tendons at the wrist. He has permitted me to publish the details, which are as follows:

A boy born in 1953 suffered from severe haemophilia. In August 1958 he was admitted to hospital with multiple haemorrhages, one being in the right forearm. There was bleeding into the elbow; the forearm was tense and extremely tender. When an attempt was made to extend the wrist and fingers the child screamed and there was hyperaesthesia in the distribution of the median nerve. A flexion contracture of the wrist and fingers gradually developed; it was improved a little by splinting, but some shortening remained. No open operation was contemplated on account of the severity of the haemophilia, but in September 1962 it was decided to remedy the contracture, the bleeding being controlled by the administration of antihæmophilic globulin. It was thought that a muscle slide might be the most appropriate operation. The muscles were found to be normal, and it was not until the flexor tendons were exposed just proximal to the wrist that the cause of the contracture was discovered. The tendons of the flexor profundus digitorum were found to be necrotic and adherent to the periosteum over the front of the radius. After they had been severed the contracture was greatly reduced except that of the middle finger. Here it was found that the sublimis tendon was adherent to the median nerve, and when this tendon had been liberated and lengthened the fingers could be straightened out almost completely.

to get these fractures to unite. Sometimes the presence of an open wound leads to infection of the infarct, and then a most striking change occurs in the ischaemic bone, which separates as a sequestrum (Special Plate, Fig. 8).

Cartilage.—The ischaemia may also affect articular cartilage (Special Plate, Fig. 9), which becomes acellular. It may perhaps damage epiphysal cartilage too; the shortening of the severely ischaemic limb in the child is well recognized. Alas, in the one amputation specimen in which I was able to look for evidence of this damage, I found none.

Subcutaneous Tissues.—To complete the picture, though it is not of much consequence, it is just worth mentioning that even subcutaneous fat can be invaded by the fibrosis. Here is a section of the hypothenar eminence in a case of ischaemia that came to amputation (Special Plate, Fig. 10). All the subcutaneous fat has been replaced by scar tissue.

Causation

It has now been pretty well settled that arterial damage is the chief cause of Volkman's ischaemia, and the more one looks for it the more frequently it is found. This damage may be anything from complete severance of an artery to a minimal injury that sends the vessel into spasm, and it is indeed the latter that is so peculiarly noxious. It is possible that an intact artery may be obstructed by compression in a confined space. The anterior tibial syndrome is in this category, and I have seen Volkman's ischaemia in the forearm as a consequence of hæmophilic bleeding. Roller injuries, such as children sometimes suffer when they are caught up in an old-fashioned mangle, or workmen trapped by machinery, can produce a condition indistinguishable from Volkman's contracture, though here, for all we know, the violent external compression may throw the brachial artery or its branches into spasm.

There is a curious group of cases in which muscle ischaemia is not produced by violence but by a combination of anoxaemia and what in a normal person would be no more than tolerable pressure. Patients poisoned by coal-gas may show patches of the most profound ischaemia in those parts of the body in contact with the ground. We have also seen this happen with barbiturate poisoning. It is proper to include these cases here because the changes, both gross and microscopical, are those of Volkman's ischaemia and the treatment of the contracture is the same too.

Prevention

It is fractures—and above all in more sophisticated countries the supracondylar fracture of the humerus in children—that usually cause Volkman's ischaemia. Everyone is now aware of the danger of tight external splints; nevertheless disasters sometimes occur after osteotomy of the tibia for some simple deformity, plaster-of-Paris having been used for the post-operative fixation and perhaps not split. Acute flexion of the elbow after reduction of a supracondylar fracture is now generally avoided too. Yet in spite of this there continues to be a steady little trickle of cases of ischaemia (Table I).

The arterial damage is often a consequence of the primary injury, though it may be aggravated, perhaps even induced, by the reduction of the fracture.

The features of impending ischaemia are familiar; there is no need to dwell on them, though I think it is of interest to note their relative frequency (Table II). I would draw your attention to the unreliability of the state of the pulse. Perhaps the most trustworthy sign is painful limitation of extension of the digits.

Because these symptoms and signs do not invariably appear immediately after the injury, or after reduction of the fracture,

TABLE I.—Causes of Volkman's Ischaemia in Upper Limb

Fractures	
Shaft of humerus	1
Supracondylar	22
" and lower third of radius and ulna	3
Fracture of elbow with and without dislocation	3
Idem, and forearm	1
Monteggia	2
Olecranon	1
Shafts of radius and ulna	7
Plating of fracture of radius and ulna	1
Ulna, double	1
Lower end of radius and ulna	1
Various	
Division of brachial artery	3
Roller injury (compression by metal plates, 1)	4
Deep wound at wrist	1
Scald	1
Carbon monoxide poisoning	2
Barbiturate poisoning	1

TABLE II.—Mode of Onset of Volkman's Ischaemia in Upper Limb

Pain	9	Pulse absent	8
Paralysis	22	Contracture	4
Pallor or cyanosis	7	Unknown or indeterminable	18

Frequently there is more than one feature.

it is imperative that a patient should be kept under the closest observation, in hospital, for a few days. I leave it to those with better first-hand knowledge than mine to say how long this period should be; but it is pertinent to observe that the first threatening signs may appear during the third day, and my friends with great experience in the treatment of fractures tell me that after a supracondylar fracture with considerable displacement the period of strict surveillance should be three days.

Exploration of the Damaged Vessel

Unless some simple manœuvre—that is, a change of position or abandonment of reduction of the fracture—quickly abolishes the signs of ischaemia the surgeon should not hesitate to explore the site of vascular damage. Sometimes there is a torn artery, and the problem then is one of repair before thrombosis has occurred distally. Simple ligation may be safe. As Lipscomb and Burselson (1955) and Ottolenghi (1961) have pointed out, the fractured humerus may damage the nerves as well as the artery.

There may be a haematoma, but its presence is often irrelevant; more usually the vessel is found to be in spasm. Of the methods that have been attempted for restoring the circulation only three call for serious comment. By far the most important is incision of the deep fascia over the threatened muscle. One of the curious features of impending ischaemia is the great swelling of the affected muscle, which, after decompression, may be such as to prevent closure of the skin. As Benjamin (1957) has observed, this release alone may suffice.

Kinmonth (1952), Kinmonth and Simeone (1952), and Kinmonth, Hadfield, Connolly, Lee, and Amoroso (1956) have found that the only drug reasonably effective in relieving arterial spasm is papaverine, and a supply ought always to be available where emergency surgery is performed. Yet Kinmonth *et al.* (1956) report only two cases of impending Volkman's contracture in which the drug seemed to be of any value, and I have records of four in which it was used and proved ineffective. It may be that in Volkman's ischaemia the arterial lesion is singular in being intrinsic, and therefore resistant to a muscle paralyzant. However, Kinmonth makes the point, and has repeated it to me, that because the spasm is myogenic time must be allowed for the papaverine to soak into the artery. His experience with goats (unpublished work), following on that with monkeys, has convinced him that the thicker the wall of the vessel the longer the time required for the drug to act. My own feeling is that patience of the order of at least 20 minutes may be out of place in a disorder in which distal thrombosis can occur so easily and spread so rapidly.

Let us suppose that everything has failed—the application of warm normal saline solution to the artery, incision of the deep fascia, the application of 2½% papaverine (and let us hope that a completely futile sympathetic block will not have been done); what further steps can be taken? If the contused segment of the artery can be identified then it should be excised. The effect may be dramatic. First the proximal spasm suddenly disappears and the artery gushes blood. The distal end may then follow suit, but here a clot may be visible in the mouth of the vessel; if it is very gently and cautiously extracted with fine forceps success is heralded by another gush of bright blood. It is then usually safe to tie the ends of the vessel. When the surgeon examines the excised segment he may find it filled with a clot that has formed in response to damage of the inner wall of the vessel.

Undoubtedly the most important factor in dealing with impending ischaemia is awareness of the condition by every member of the surgical team and a readiness to act boldly without spending more than a little time on minor measures.

Treatment of Established Ischaemia

This is a subject that I have dealt with elsewhere (Seddon, 1956, 1960), and I do not propose to present you with more than a summary.

Whereas prevention calls for vigilance and swift action, the treatment of established ischaemia requires patience and caution. The reason for this is simple—the tendency for some recovery to occur, particularly in ischaemic nerve.

Splinting.—Correction of the contracture by splinting must be attempted. In the forearm the apparatus should give good control of the fingers and yet be removable; the best I know is that shown in Fig. III, which is a refinement of the splint devised by Michel (1924). If paralysis of the small muscles of the hand indicates that there has been an ischaemic lesion of a main nerve trunk denervation atrophy should be prevented by frequent galvanic stimulation.

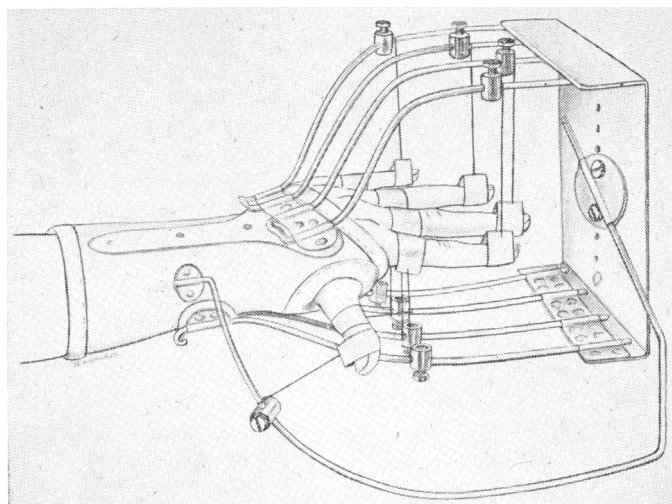


FIG. III.—A splint that may be used for the correction of an ischaemic contracture. (Reproduced by permission of the British Editor of the *Journal of Bone and Joint Surgery*.)

The final pattern of damage gradually emerges, and by the sixth month it will have become clear. On a few occasions I have carried out an operation between the third and the sixth month, but on the whole it seems wiser to wait for the longer period. Further delay is undesirable because then contractures secondary to the primary one in the muscle may develop and, unless the splinting and mobilization have been very assiduous, there may be irreversible stretching of certain

structures, of which the most important are the dorsal hoods of the proximal interphalangeal joints of the fingers.

Clinical Classification

It is remarkable that one can make any sort of classification of the ultimate damage, because the ischaemia can vary so much both spatially and in intensity.

In making the repeated examinations on which the final picture of the damage is based more than on anything else the observer must distinguish sharply between the signs indicative of muscle damage and those of the paralysis due to nerve involvement.

The extremes are easily recognizable. In the mildest cases the contracture yields rapidly to correction by splinting; the loss of power, whether in the ischaemic muscle or in the distribution of nerves traversing the ischaemic zone, is only of short duration and any loss of sensibility is transient. The patient recovers with a useful if slightly wasted arm. If he is a child there is a possibility that in adolescence the forearm muscles will become short, their longitudinal growth not keeping pace with that of the bones; perhaps ten or more years after the accident a muscle slide may be required for correction of a contracture that has slowly reappeared.

At the other extreme are those limbs that have suffered overwhelming injury; the fractures may be important, but in the cases that have come my way the significant damage has been to the main vessels and nerves in the axilla. Because of the direct damage to nerves it may not be easy to say how much of the paralysis is ischaemic in origin. However, the woodiness of the forearm muscles and the rapid onset of rigidity of the wrist and hand soon indicate the severity of the ischaemia. It can be confirmed very simply by exploratory incision, and if on both sides of the forearm the muscles are reduced to necrotic pulp then amputation at an appropriate level is the only sensible remedy. I mention these cases chiefly because several that have been under my care had over a period of months been receiving futile treatment for a limb which, apart from its envelope, was gangrenous.

Many cases of Volkman's ischaemia of forearm muscles fall between these extremes, and they are roughly of three types—mild 17, localized 5, severe 28.

1. Diffuse but Moderate Ischaemia

The main feature here is contracture; nerve involvement is not great and clears up spontaneously. Within a few months there is a fair return of power in all the affected muscles and, at the finish, all that remains is to correct the contracture that has resisted splinting. Here, *par excellence*, is the indication for a muscle slide. I limit it to cases of this kind; unlike Scaglietti, I see no use for its employment where there has been destruction of the forearm flexor muscles. Of 14 cases in which forearm muscle slides were used, correction was maintained in 7, and partial relapse (in no case disabling) occurred in 7.

The operation, if properly done—and this means a dissection from the elbow to the wrist, and from the subcutaneous border of the ulna across the interosseous membrane to the lateral surface of the radius—is one of the most satisfying in reconstructive surgery.

Theoretically, selective tendon-lengthening is a more logical operation, and Lipscomb (1956) reported that it had been carried out 21 times at the Mayo Clinic. I am reluctant to

disturb tendons in an area where the lesion has already produced some fibrosis, and I suspect, though cannot prove it, that lengthening a tendon weakens the power of the muscle more than an operation that does not alter the length of the whole contractile unit.

2. Intense but Localized Muscle Damage

This is rare, but there is no mistaking the clinical picture. The paralysis settles down to a pair of muscles—those deepest in the forearm, flexor digitorum profundus and flexor pollicis longus—and it is in these that the contracture develops. Because the median nerve is on the fringe of the zone of infarction and because the ulnar nerve is well away from it, nerve involvement is not usually of consequence. At, say, six months, by which time the condition will be clearly apparent, a localized excision of the affected muscles will give complete correction of the contracture and the residual disability will be small, hardly worth remedying by tendon transplantation (Fig. IV).

3. Widespread Necrosis or Fibrosis

This last group is the most troublesome, cases in which there is almost total destruction of the forearm flexor muscle mass, often with serious involvement of the main nerves and sometimes with extension of the infarct into the dorsal compart-

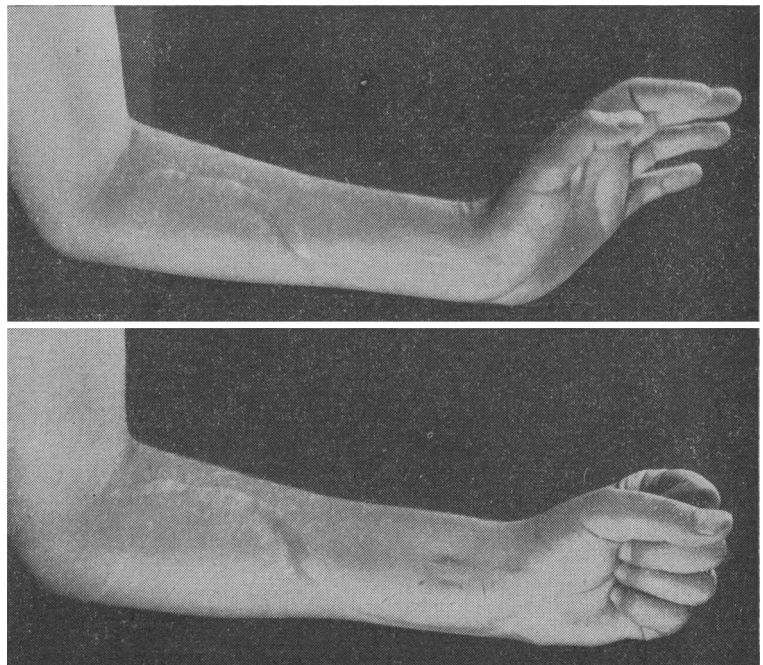


FIG. IV.—*Top*: Contracture due to ischaemia localized to flexor digitorum profundus and flexor pollicis longus (Professor J. I. P. James's case). *Bottom*: The result after excision of these two muscles. (Reproduced by permission of the British Editor of the *Journal of Bone and Joint Surgery*.)

ment where the deeply situated muscles are affected—namely, those serving the thumb.

I am now satisfied that the best treatment for the muscle is excision of the infarct (Table III), though I no longer remove flexor carpi ulnaris because of the danger to the ulnar artery, which may be the only sizable vessel conveying blood to the hand. As I have already indicated, the median nerve must first be exposed because it may be found that, in spite of its unhealthy surroundings and moderately attenuated appearance, small blood-vessels are present throughout its length, and there is then a chance that spontaneous recovery will occur.

TABLE III.—Excision of Muscle and Reconstruction

	Limited	Subtotal	Total
Excisions = 25	4	17	4
Contracture corrected	4	17	3
Tendon transplantation	2	15	2
Nerve repair	1	8	3
Result:			
Success	4	14	4
Failure		2	1

TABLE IV.—Ulnar-to-median Nerve Pedicle Grafts

	Total	Sensory Recovery	Motor Recovery
Children	6	6	4
Adults	3	2	1

The correction of the contracture by excision of the destroyed muscles is the easiest part of the surgical programme. After an interval of about three months restoration of flexion of the fingers can be achieved by transplantation of the short

radial extensor of the wrist into flexor digitorum profundus, the tendons of the superficial flexor being excised. We have not found it essential to transplant anything into the long flexor of the thumb, though we have done the operation.

The chief problem is what to do when electrical stimulation and inspection of the nerve or nerves reveal that they are hopelessly damaged. The well-known ulnar-to-median nerve pedicle graft (Table IV), the first stage of which may be carried out at the time of the muscle excision, gives good results in children in terms of restoration of power in the thenar muscles and of sensibility in the skin of the hand supplied by the median nerve. But the patient is left with an ulnar paralysis which in itself is disabling; and in an affair of this severity there is nothing to spare for transplantation

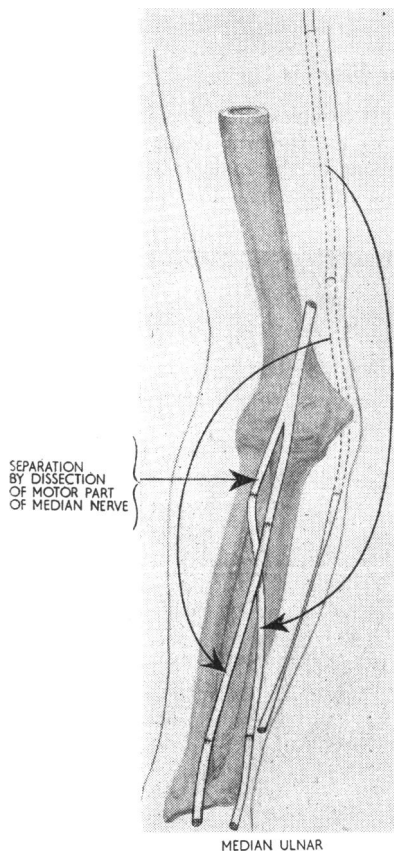


FIG. V.—Free autogenous nerve-grafting for repair of ischaemia of the median and ulnar nerves. (Reproduced by permission of the Editor of the *Revue de Chirurgie Orthopédique*.)

in the manner advocated by Brand to restore the intrinsic muscle control of the fingers. There may be a solution in an operation that I have tried in one case and which, to my delight, turned out successfully. As I shall explain more fully in a moment, even a free nerve graft can survive in a child's forearm

after excision of the ischaemic muscle, and, as shown in Fig. V, two pieces of the ulnar nerve may be used—one to bridge the defect in the median nerve and the other to unite the functionless motor stump of the median in the upper forearm to the distal end of the ulnar. The child on whom I performed this operation now has a useful hand and good active flexion of the metacarpo-phalangeal joints. However, the ulnar nerve may, respond on stimulation, or inspection of it may show that it is not hopelessly damaged. It is then best to use a free graft (Table V) obtained by splitting the motor division off the rest of the median nerve and using it to bridge the gap lower in the forearm. It was the success following this operation that tempted me to embark on the double repair that I have just mentioned.

TABLE V.—Free Nerve Grafts

	Total	Sensory Recovery	Motor Recovery	Recent Operation or Unknown
Median to median :				
Children	5	4	4	1
Adults	2	1		1
Ulnar to ulnar and median :				
Child	1	1	1	

Conclusion

I have described to you the salient feature of Volkman's ischaemia, chiefly in the upper limb, with a wealth of detail that this condition ought not to deserve. But, as our French colleagues (Postel and Geneste, 1956) showed us some time ago, this skeleton must be pulled out of the cupboard and exposed to view. The threat of ischaemia in the limbs is always with us; it can be countered only by constant awareness and courageous action. I believe it will be found more commonly in the lower limb than we at present suspect.

For years now the Birmingham Accident Hospital has been making valuable contributions to our knowledge of the effects of injury. To-day we remember Ruscoe Clarke and his pioneer work there, and the best tribute I can pay him is to make my small offering towards a better understanding of one of the cruellest catastrophes that can befall those whom we treasure most, our children.

REFERENCES

- Bateman, J. E. (1962). *Trauma to Nerves in Limbs*. Saunders, Philadelphia and London.
- Benjamin, A. (1957). *J. Bone & Surg.*, **39B**, 711.
- Clark, W. E. Le Gros, and Blomfield, L. B. (1945). *J. Anat.*, **79**, 15.
- Gallie, W. E., and Thomson, S. (1960). *Canad. J. Surg.*, **3**, 164.
- Holmes, W., Highet, W. B., and Seddon, H. J. (1944). *Brit. J. Surg.*, **32**, 259.
- Kinmonth, J. B. (1952). *Brit. med. J.*, **1**, 59.
- Hadfield, G. J., Connolly, J. E., Lee, R. H., and Amoroso, E. C. (1956). *Brit. J. Surg.*, **44**, 164.
- and Simeone, F. A. (1952). *Ibid.*, **39**, 333.
- Kirby, E. (1892). *Beitr. path. Anat.*, **11**, 302.
- Lipscomb, P. R. (1956). *Surg. Gynec. Obstet.*, **103**, 353.
- and Burleson, R. J. (1955). *J. Bone & Surg.*, **37A**, 487.
- Michel, L. (1924). *Rev. Orthop.*, **3**, 349.
- Nario, C. V. (1938). *J. int. Chir.*, **3**, 87.
- Ottolenghi, C. E. (1961). *Wiederherstellungschir. u. Traum.*, **6**, 60.
- Postel, M., and Geneste, R. (1956). *Rev. Chir. orthop.*, **42**, 514. Discussion, *ibid.*, p. 840.
- Saunders, J. H., and Sissons, H. A. (1953). *J. Bone & Surg.*, **35B**, 113.
- Seddon, H. J. (1956). *Ibid.*, **38B**, 152.
- (1960). *Rev. Chir. orthop.*, **46**, 149.
- and Holmes, W. (1945). *Brit. J. Surg.*, **32**, 389.
- Tavernier, L. (1938). *J. int. Chir.*, **3**, 129.
- and Dechaume, J. (1937). *Lyon chir.*, **34**, 117.
- — and Pouzet, F. (1936). *J. Méd. Lyon*, **17**, 815.