

Section of Medicine

President Sir Ronald Bodley Scott KCVO FRCP

Meeting May 28 1968

Philip Ellman Lecture

The Lungs in Rheumatoid Arthritis

by Professor J G Scadding MD FRCP
(*Institute of Diseases of the Chest,
Brompton Hospital, London*)

Philip Ellman, whose work this lecture is intended to commemorate, died just over eight years ago. He was above all a clinician, interested in the problems of individual patients. His contributions to the science of medicine were those of an astute clinical observer, endowed with the gift of describing his observations clearly, both in speech and in writing. His principal interests were in two fields: the chronic respiratory diseases, including tuberculosis, and the rheumatic diseases. He participated actively in the meetings of this Section and of the Clinical Section of this Society. It was at a joint meeting of this Section and the Section of Physical Medicine in 1947 that he referred for the first time to the possibility that chronic lung changes might be associated in some specific way with rheumatoid arthritis, mentioning briefly a case of rheumatoid arthritis with splenomegaly, hepatomegaly, lymphadenopathy and leukopenia, and widespread radiographic changes in the lungs which at necropsy were found to be due to 'a curious chronic fibrosing broncho-pneumonic lesion' (Ellman 1947). Subsequently, he published further clinical and pathological contributions to knowledge at this meeting-point of his two main interests. There is now a very large literature on the associations between rheumatoid arthritis and changes in the lung and pleura; and many of the authors who have written on this difficult subject have started by referring to these early observations of Philip Ellman's. It therefore seems appropriate to devote this lecture to this subject. I propose to consider, first, the evidence which suggests that

certain types of morbid change in the lungs and pleura may be related in some way to rheumatoid arthritis; and, second, the possible nature of any such relationship.

Respiratory Disease Associated by Chance with Rheumatoid Arthritis

It is important, at the outset, to recognize that rheumatoid arthritis is a common disease; hence, it is to be expected that a proportion of patients with any other disease will suffer also from rheumatoid arthritis. Kellgren *et al.* (1953) found in a survey of an urban population that 1.4% of men and 3.3% of women had clinical evidence of rheumatoid arthritis; in the sixth decade of life the proportions were as high as 4% and 9% respectively. It has been suggested that patients with rheumatoid arthritis may be especially prone to common respiratory diseases (Aronoff *et al.* 1955, Walker 1967). Walker (1967) found a significantly higher incidence of illnesses diagnosed as chronic bronchitis and pneumonia in men with rheumatoid arthritis as compared with men with degenerative joint disease. In both sexes, he found 'bronchiectasis' more frequently in rheumatoid arthritis patients; in most, the symptoms attributed to bronchiectasis had preceded the onset of the arthritis. These findings would generally be interpreted in terms of a predisposition of patients suffering from one disease to develop another, aetiologically distinct, disease.

Pleuropulmonary Disease Possibly Related to Rheumatoid Arthritis

A possible relationship between lung and joint changes, beyond a chance association, has been suggested in relation to three types of disease of the lungs or pleura in patients with rheumatoid arthritis. These are:

- (1) Nodules having a histological structure similar to that of the subcutaneous nodules of rheumatoid arthritis ('rheumatoid nodules').
- (2) Pleural effusions, sometimes associated with pleural nodules or plaques.
- (3) Widespread diffuse chronic inflammatory changes in the peripheral gas-exchanging part of the lungs, leading to fibrosis.

Nodules in Lung and Pleura

The appearance of multiple, radiographically evident nodules in the lungs of persons who, having been exposed to dust, have radiographic evidence of pneumoconiosis and also suffer from rheumatoid arthritis constitutes the well-recognized Caplan's syndrome. Much more rarely, rather similar nodules have been described in patients with rheumatoid arthritis, without pneumoconiosis and without unusual dust exposure.

Caplan (1953) first observed multiple, round, well-defined opacities, scattered over the lung-fields but tending to a peripheral distribution, in the chest radiographs of a very small proportion of coalminers claiming pneumoconiosis disability benefit. The appearance differed from that of the usual type of progressive massive fibrosis in several respects; in the wide distribution and multiplicity of the nodules, in being associated with relatively slight disability, and in developing rapidly, often in men who had only a mild simple pneumoconiosis. It was found to occur in men who had clinical evidence of rheumatoid arthritis, and an epidemiological study confirmed this association (Miall *et al.* 1953). Gough *et al.* (1955) showed that these nodules contained necrotic collagen and dust, and many of them had a histological structure resembling that of rheumatoid nodules. Subsequently, similar nodules have been described in subjects with rheumatoid arthritis exposed to asbestos (Rickards & Barrett 1958, Telleson 1961) and to dust in a variety of other industries; in iron-founding (Caplan *et al.* 1958), in tile-making (Hayes & Posner 1960), in boiler-scaling (Campbell 1958), and in manufacture of artificial grinding-wheels (Posner 1960). It has been shown also that coal-miners with simple pneumoconiosis showing certain types of unusually coarse generalized nodular radiographic pattern show a high prevalence of rheumatoid arthritis and of positive tests for rheumatoid factor in the blood-serum even in those without arthritis (Caplan *et al.* 1962).

The subcutaneous nodule of rheumatoid arthritis has a characteristic histological structure, consisting in a central zone of fibrinoid necrosis, an intermediate zone of histiocytes and fibroblasts, radially disposed in palisade fashion where they abut on the necrotic zone, and a peripheral

zone of connective tissue with lymphocytes and plasma cells (Collins 1937, Bennett *et al.* 1940). Nodules of similar structure have been reported in a variety of internal organs, including the lungs, of patients with rheumatoid arthritis. Normal lungs seem considerably less liable than those affected by dust to develop such nodules, but sufficient cases have been reported to permit some generalizations about rheumatoid nodules (defining this term histologically) in previously normal lungs. They occur more frequently in men than in women; of published cases which I have reviewed, 19 were in men and 10 in women. The nodules are generally subpleural in situation, and may involve the pleura itself. In some of the reported cases, nodules have been found in several internal organs as well as the lungs, e.g. heart, pericardium and spleen (Gruenwald 1948); heart, diaphragm and kidneys (Bevans *et al.* 1954); heart (Christie 1954); sclera, heart, spleen and cerebral dura mater (Maher 1954); but in most, they have been described in the lungs only. In the lungs, they are usually multiple, but often appear successively. They are generally 1-2 cm in diameter, but may be considerably larger; in Case 3 of Christie (1954) a massive encapsulated nodule in the right upper lobe was 7 cm in diameter, and in a case reported by Mattingley (1964) a thoracotomy was undertaken on a provisional diagnosis of carcinoma. Not infrequently they cavitate, the necrotic central part presumably undergoing liquefaction and being discharged into an airway (Dumas *et al.* 1963, Locke 1963, Noonan *et al.* 1963, Yates 1963, Portner & Gracie 1966, Ramirez-R & Campbell 1966, Stengel *et al.* 1966, Burrows 1967, Panettiere *et al.* 1968). They may also ulcerate into the pleura causing spontaneous pneumothorax or hydro-pneumothorax (Morgan & Wolfel 1966, Portner & Gracie 1966, Burrows 1967, Rubin *et al.* 1967) or even pyopneumothorax (Davies 1966); and in several cases, mentioned below, pleural effusions and subpleural or pleural nodules have co-existed. In Case 2 of Burrows (1967) intrapulmonary nodules were found concurrently with the first symptoms of the arthritis, but in other reported cases they have appeared at variable times after the arthritis. I have observed one case in which nodules were first observed in the lungs several years before the first symptoms of rheumatoid arthritis:

Case 1¹ A woman, then aged 32, was first found at routine radiography in 1956 to have small rounded shadows in the upper zones of both lungs. As she had previously had tuberculous lymphadenitis of the neck, treated surgically, these shadows were thought to be

¹I am indebted to Dr E G Pyne, who referred this patient to me, for detailed information about the earlier part of her illness

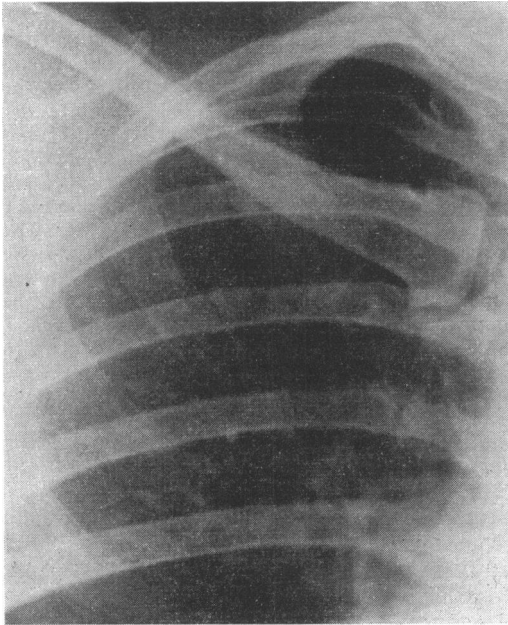


Fig 1 Case 1 Radiograph, February 1959, showing upper zone of right lung; the round shadow had been present, with little change, for three years

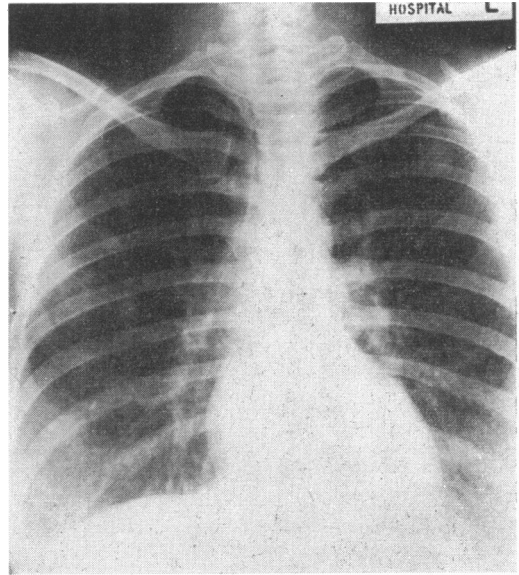


Fig 2 Case 1 Radiograph of chest, November 1959, showing further round shadows in both lungs

due to tuberculous foci and antituberculosis chemotherapy was given for sixteen months; but tubercle bacilli were not found, either at this time or subsequently, in spite of repeated attempts. The shadows remained unchanged (Fig 1) until September 1959, when they increased in size and a number of new ones appeared, especially in the middle zone of the right lung (Fig 2). Further antituberculosis treatment was

given, but in September 1960 a focus in the right upper zone cavitated (Figs 3 and 4). In March 1961, at a diagnostic thoracotomy several hard nodules were felt in all lobes of the right lung, several appearing as flat white plaques, just below the pleura. One was removed for biopsy, and showed a necrotic centre surrounded by fibrous tissue with patchy peripheral round-cell infiltration but no specific features (Fig 5).

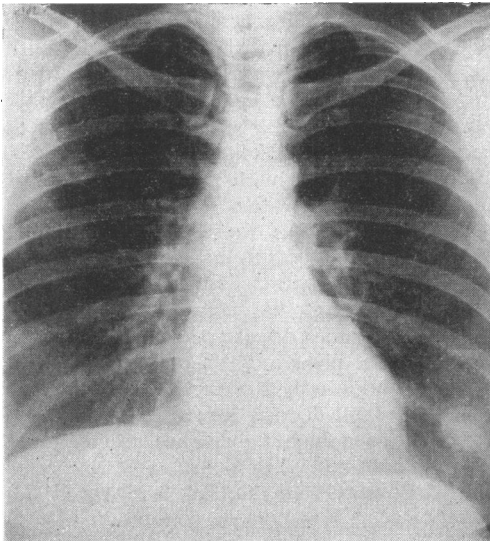


Fig 3 Case 1 Radiograph of chest, September 1960, showing enlargement of some of the round shadows

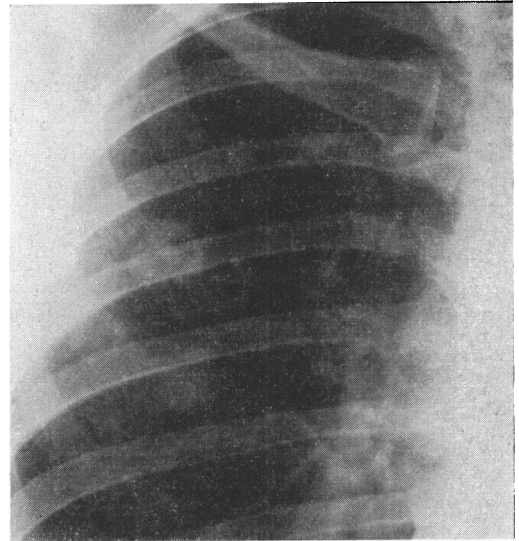


Fig 4 Case 1 The same, upper part of right lung only, to show cavitation in a nodule

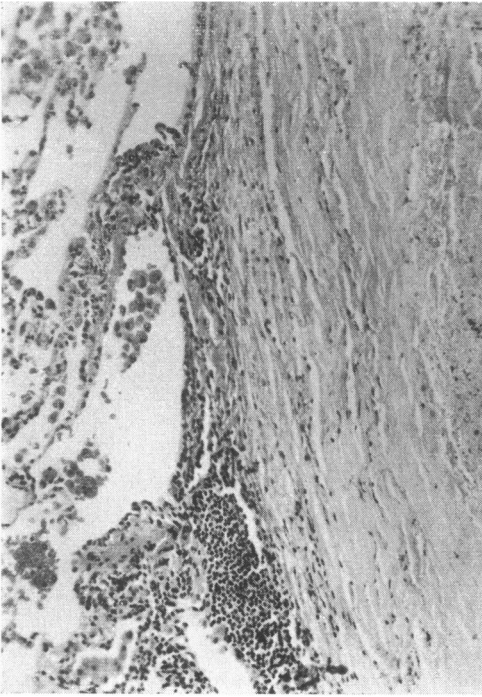


Fig 5 Case 1 *Histology of nodule removed by thoracotomy. A necrotic centre is surrounded by featureless fibrous tissue, with some lymphocytic infiltration at its periphery. H & E. $\times 120$*

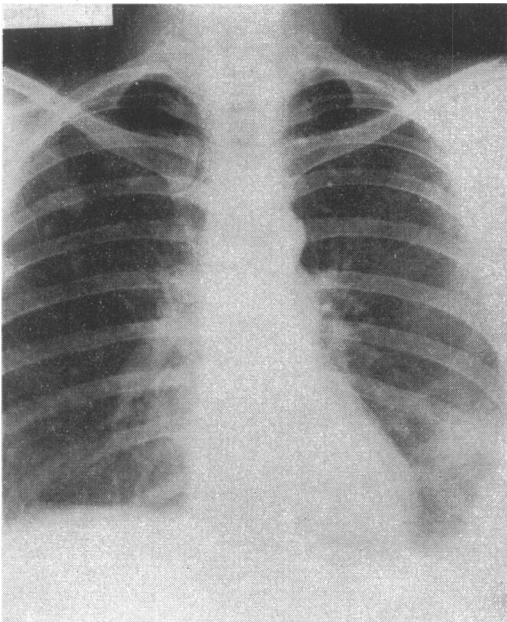


Fig 6 Case 1 *Radiograph of chest, August 1962, showing residual pleural thickening on the left side, and persistent nodules*

In April 1961, the first joint symptoms appeared, when the metacarpophalangeal joint of the right index finger became swollen and painful. The rheumatoid latex fixation test (LFT) was positive and the differential agglutination titre (DAT) was 1:16. By August 1961, the arthritis had involved both hands and wrists, elbows, feet and shoulders, and in September 1961 a left pleural effusion and subcutaneous nodules on the elbows had appeared. The DAT was now strongly positive, at a titre of 1:2,048. The pleural effusion had a glucose content too low to be estimated by the routine method. Under treatment which included small doses of prednisolone, the symptoms of the rheumatoid arthritis were controlled, and the pleural effusion slowly absorbed (Fig 6). In April 1968, 6½ years later, the nodules were still evident in the chest radiograph, though considerably smaller, especially on the right side.

Pleural Changes

Pleural adhesions have been noted to be unusually frequent at necropsy in cases of rheumatoid arthritis. They were found by Baggenstoss & Rosenberg (1943) in 22 of 30 cases, and by Fingerma & Andrus (1943) in 23 of 61 cases. Aronoff *et al.* (1955) found pleural adhesions much more commonly at necropsies in cases of rheumatoid arthritis than in a control group; and Sinclair & Cruickshank (1956) found that 61 of 90 rheumatoid arthritis patients as compared with 20 of 90 control subjects had unexplained pleural adhesions at necropsy.

During life, pleural effusions not attributable to any of the commonly recognized infective or neoplastic causes have been reported frequently in patients with rheumatoid arthritis. Evidently, it is necessary to demonstrate either a higher incidence than in a suitably chosen control group or some feature or features which distinguish effusions in patients with rheumatoid arthritis from others before it can be suggested that pleural effusion may be specifically related to rheumatoid arthritis. Walker & Wright (1967), studying 516 patients with rheumatoid arthritis and 301 with degenerative joint disease, found that among the males those with rheumatoid arthritis had a significantly higher incidence of a history of pleurisy within five years of the onset of the joint symptoms; pleural effusions not attributable to other disease occurred during the course of the arthritis in 7.9% of men and 1.6% of women, and in only 2 of the 301 patients with degenerative joint disease. Review of 65 reported cases confirms a higher incidence among men; 53 were in men and 12 in women.

Carr & Power (1960) and Carr & Mayne (1962) first reported a low glucose content in pleural effusions in patients with rheumatoid arthritis. In 8 of 9 cases investigated, the glucose level was less than 17 mg/100 ml. This has subsequently

been confirmed in small numbers of cases by Berger & Seckler (1966), Dodson & Hollingsworth (1966), and Portner & Gracie (1966), though Walker & Wright (1967) found a low glucose content in only 2 of 8 cases. The glucose content of pleural effusions apparently associated with rheumatoid arthritis was measured in 3 patients under my care; in 2 (one of whom is mentioned above) it was less than 25 mg/100 ml, the lowest limit of the method used, and in the third it was estimated on two occasions and found to be 26 and 23 mg/100 ml. Synovial fluids from joints affected by rheumatoid arthritis have been found to have a similarly low glucose content (Ropes & Bauer 1953, Ropes *et al.* 1960). Dodson & Hollingsworth (1966) and Carr & McGuckin (1968) showed that the glucose content of 'rheumatoid' pleural effusions was very little or not at all raised by glucose administration which raised the blood glucose level. Dodson & Hollingsworth (1966) found that there was no blockade of the transport of D-xylose into the pleural fluid. Carr & McGuckin (1968) found that in malignant pleural effusions the glucose content followed blood levels, and that in both 'rheumatoid' and malignant pleural effusions urea levels followed blood levels; *in vitro*, pleural fluids from patients with rheumatoid arthritis showed no unusual glycolytic activity.

In a number of reported cases, as in the one described above, pleural effusions have been associated with subpleural intrapulmonary rheumatoid nodules (Ellman *et al.* 1954, Flatley 1959, Robertson & Brinkman 1961, Ward 1961, Sieniewicz *et al.* 1962, Berger & Seckler 1966, Davies 1966, Ferguson 1966, Portner & Gracie 1966 - 2 cases, Stengel *et al.* 1966, Burrows 1967, Rubin *et al.* 1967). Biopsy of the thickened parietal pleura may show a histological pattern suggestive of a rheumatoid nodule (Berger & Seckler 1966, Portner & Gracie 1966, Verhaeghe *et al.* 1967), or nonspecific fibrosis (Davies 1966, Dodson & Hollingsworth 1966 - 2 cases, Carr & McGuckin 1968 - 2 cases). Walker & Wright (1967) found needle biopsy 'helpful' - presumably in showing histological changes resembling those of a subcutaneous rheumatoid nodule - in 4 of 11 cases. Open biopsy and decortication, including the visceral pleura, more often shows a 'rheumatoid' pattern, at least in parts of the thickened pleura, or associated subpleural nodules (Lee *et al.* 1959 - Case 1, Cudkowicz *et al.* 1961, Berger & Seckler 1966, Brunk *et al.* 1966, Portner & Gracie 1966), but even this may show nonspecific changes only (Carr & Mayne 1962 - 2 cases).

The evidence suggesting that pleural effusion may be specifically related to rheumatoid arthritis is thus not only concurrence with this

disease and failure to find any of the usual causes of pleurisy, but also, in some cases, a peculiarly low glucose content, a feature which has also been observed in rheumatoid synovial fluids, and the frequent finding of a further association with subpleural or pleural 'rheumatoid' nodules or with patchy histological changes in the thickened pleura reminiscent of such nodules.

Chronic Pulmonary Fibrosis

Since Philip Ellman's first reference to 'a curious chronic fibrosing broncho-pneumonic lesion' in a patient with rheumatoid arthritis, there have been many references to pulmonary fibrosis in such patients. These have been reviewed by Rubin (1955) and by Stack & Grant (1965). Histologically, they fall into the general category which is often described as 'diffuse interstitial fibrosis' but which I prefer to call 'fibrosing alveolitis' (Scadding 1964). A brief description of the clinical, radiological and functional changes associated with this sort of lung change is necessary before the observed facts about its concurrence with rheumatoid arthritis can be discussed.

Fibrosing alveolitis may be defined as a disease characterized by an inflammatory process in the lung beyond the terminal bronchiole having as its essential features (a) cellular thickening of alveolar walls with a strong tendency to fibrosis, and (b) large mononuclear cells, presumably of alveolar origin, within the alveolar spaces. Other histological changes may be present, such as hyperplasia of lymphoid follicles; admixture of other cell types in the alveolar contents; in acute cases, hyaline membrane formation in alveoli and bronchioles; and in the more chronic ones, varying degrees of disorganization of lung structure leading to such changes as honeycombing, lining of remaining air-spaces with cuboidal epithelium, and apparent or real excess of smooth muscle. But these are inconstant and do not constitute part of the defining characteristics. My colleague, K F W Hinson, and I have recently correlated histology with clinical features and course in a series of 16 patients having lung biopsies conforming to the general definition of fibrosing alveolitis, and followed thereafter for at least two years or until death (Scadding & Hinson 1967). Histologically, these cases could be ranged, without evident discontinuity, between two polar types. At one end of the range were cases conforming to the description by Liebow *et al.* (1965) of 'desquamative interstitial pneumonia'; we proposed that this should be referred to as the desquamative type of fibrosing alveolitis. It was characterized by relatively little thickening of alveolar walls, the most prominent feature being the very large

numbers of large mononuclear cells in the alveoli; affected parts of the lungs were uniformly involved, and destructive changes such as honeycombing were not seen. Radiologically, these cases showed either band-like opacities above the somewhat raised diaphragm, or patchy consolidation, usually with some indefinite mottling elsewhere in the lung-fields. At the other end of the range, we recognized a 'mural' type, in which the most prominent change was thickening of alveolar walls, often predominantly fibrotic; there were generally fewer cells within the air-spaces, and these were predominantly of phagocytic type; and destructive changes with gross fibrosis and honeycombing, often patchily distributed, might be prominent. Radiologically, these cases usually showed widespread punctate or mottled opacities with or without more or less widespread 'honeycomb' appearances. It was not surprising to find that among patients submitted to lung biopsy those in whom changes of the 'desquamative' type were found might show some suppression of activity of the disease under corticosteroid treatment and even might improve spontaneously, while those in whom the 'mural' pattern was observed generally showed neither response to corticosteroid treatment nor spontaneous improvement. While cases of these two contrasted histological types thus differed in a consistent manner, the majority of the cases reviewed showed a mixed histological pattern, so that we did not consider that our material provided any justification for assuming that the variations in histological pattern corresponded to differences in pathogenesis. A 'desquamative' pattern can certainly proceed to a 'mural' pattern; it seems possible that the 'mural' pattern may be present throughout the disease, or may develop as an end-result of processes characterized by other histological patterns in their earlier stages, but evidence relevant to this point is hardly ever available. At present, one can only speculate about the pathogenesis of this sort of lung change. Accordingly, as a clinician, I use the term 'fibrosing alveolitis' to imply that I know or believe that a histological change conforming to this general pattern is present in the lungs, adding the adjectives 'desquamative' or 'mural' only if there is evidence justifying the opinion that one of these variants of the general pattern is present; and these terms carry no aetiological implications.

The principal symptom associated with fibrosing alveolitis is dyspnoea on exertion; in some cases, cough is troublesome, out of proportion to the scanty expectoration. Clubbing develops in most, but not all, cases; it is not related to variations of histological pattern, and was observed in equal proportions, about 63% of

those with slight and with severe alveolar wall thickening in the series studied by Scadding & Hinson (1967). Crepitations are the characteristic physical sign, being observed in nearly all cases, irrespective of histological type; they are nearly always most numerous at the bases of the lungs, and may be heard only at this site. Analysis of the functional disorder shows combinations of restrictive ventilatory defects and defects in gas transfer. There is a tendency for the restrictive ventilatory defect, due to diminution in effective size and in compliance of the lungs, to be more prominent in the desquamative type; and for the defect in gas transfer, due to wide variations in ventilation/perfusion ratios, to be more prominent in the mural type.

A survey of some of the published reports of fibrotic lung changes in patients with rheumatoid arthritis suggests that when histological appearances have been described they conform to the general description of the mural type of fibrosing alveolitis, and that in those without histological information the clinical and radiological findings have been compatible with changes of this type. I have personally observed 15 patients with rheumatoid arthritis and lung fibrosis, not attributable to any of the commonly recognized causes. In only 4 of these has histological evidence been available. I quote 2 of these, to illustrate the clinical, radiological and pathological picture.

Case 2 A man started to have pain in the small joints of the hands, the elbows, the shoulders and the knees at the age of 61. About two years later, he noticed increasing dyspnoea on exertion, with a feeling of tightness in the chest on inspiration. He had only slight

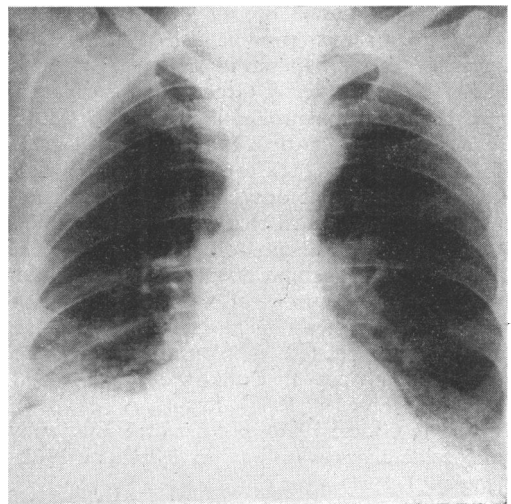


Fig 7 *Case 2 Radiograph of chest, showing irregular opacities above the diaphragm at the bases of both lungs*

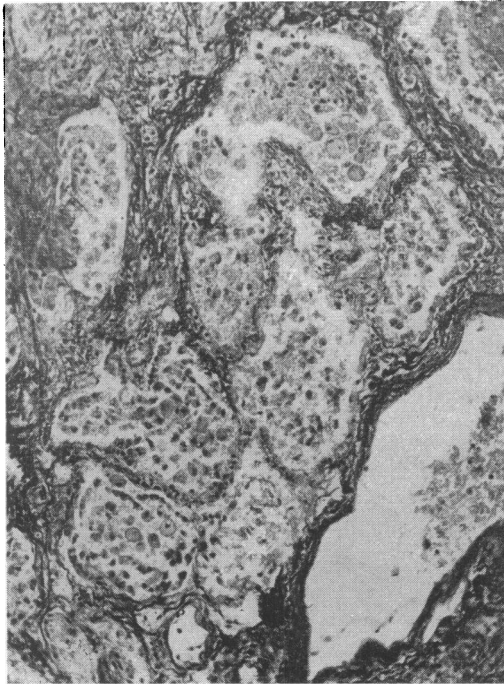


Fig 8 Case 2 Histology of the lung at necropsy, showing cellular and fibrotic thickening of alveolar walls, with cells of several types in alveolar spaces. *Hæmatoxylin & van Gieson.* $\times 95$

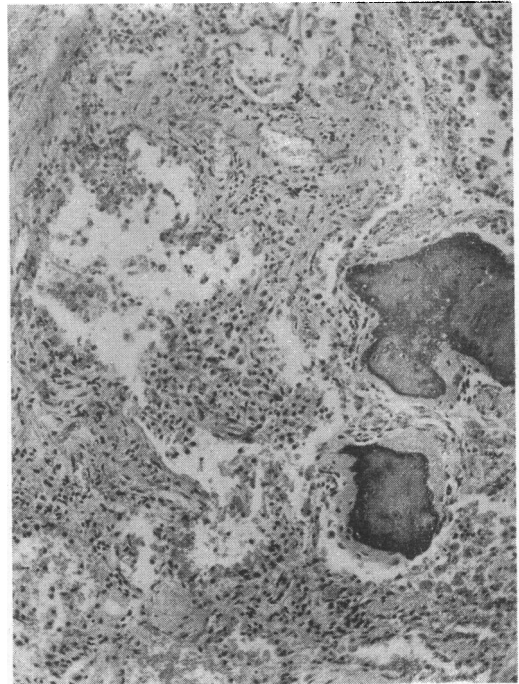


Fig 9 Case 2 The same, showing organization of alveolar exudate and two small foci of ossification. *H & E.* $\times 95$

cough with scanty mucoid sputum. During the next year, he lost more than 20 lb (9 kg) in weight. He was admitted to Brompton Hospital at the age of 64. There was some swelling of the proximal interphalangeal joints of the hands and of the right knee, and limitation of movement of the elbows and of the left shoulder. Radiographs of the hands showed loss of bone density near the interphalangeal joints and some small erosions in two fingers. The latex fixation test for rheumatoid factor (LFT) was very strongly positive, as was the DAT to a titre of 1:128. There was no clubbing of the fingers. Fine crepitations were heard over the lower parts of the lungs. Chest radiography showed mottled shadowing above the diaphragm in both lungs (Fig 7).

Tests of lung function showed a moderate restrictive ventilatory defect, the forced vital capacity (FVC) being 2.5 litres of which the volume expired in the first second (FEV₁) was 2.1 litres; and a moderate defect in gas transfer, the carbon monoxide transfer factor by the steady state method (T_{co}) being 8.2 ml/min/mmHg at the high minute ventilation of 15.3 litres at rest and 12.3 at a minute ventilation of 31.2 litres on exercise. Prednisolone, starting at 30 mg/day, produced relief of the joint symptoms, but no change in the dyspnoea, the tests of lung function, or the radiographic appearances of the lungs. Rather less than a year later, he died with an exacerbation of respiratory symptoms probably due to an intercurrent infection.

At necropsy¹, which was limited to the thorax, there were dense scattered pleural adhesions; the lungs were firm and felt nodular. Microscopically, there was cellular and fibrotic thickening of alveolar walls, patchily distributed (Fig 8); many alveoli contained masses of cells of varied types; in some alveoli organization of exudate was adding to the fibrosis, and in a few there were small foci of ossification (Fig 9); and there was some terminal bronchopneumonia.

Case 3 In 1950, a man then aged 37 was investigated for dyspepsia and found to have a duodenal ulcer. At this time he was noticed to have persistent crepitations and an abnormal radiographic pattern at the bases of the lungs. He had gross clubbing of the fingers which he had first noticed many years earlier. Pain in the joints, principally the hands, knees, shoulders and ankles, began in 1952. In December 1953 a chest radiograph showed changes similar to those observed three years earlier, consisting in fine reticulonodular shadowing, throughout the right and in the lower part of the left lung. In 1956 nodules appeared on the elbows. I first saw him at Brompton Hospital in 1958, when he was aged 44. He was now complaining chiefly of dyspnoea on exertion which had been increasingly troublesome for six months. There was very gross drumstick clubbing of the fingers and toes;

¹I am indebted to Dr Eunice Hurworth for information about the necropsy findings

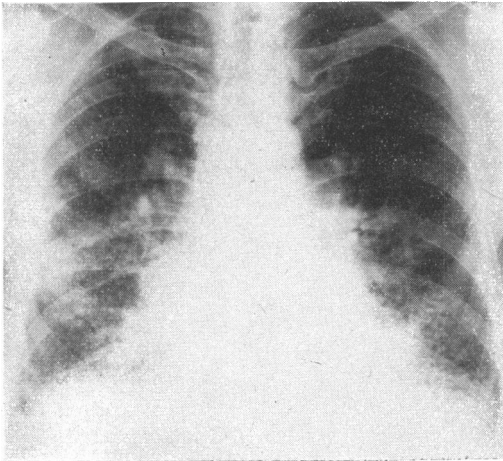


Fig 10 Case 3 *Radiograph of chest, December 1958, showing mottling throughout the right and in lower two-thirds of the left lung, with some 'honeycombing' at the bases*

slight limitation of movement of the shoulders, neck, hips and ankles; crepitus in the left knee with some free fluid; a large subcutaneous nodule on the right elbow; and thickening of the left olecranon bursa. There were persistent crepitations at the bases of the lung.

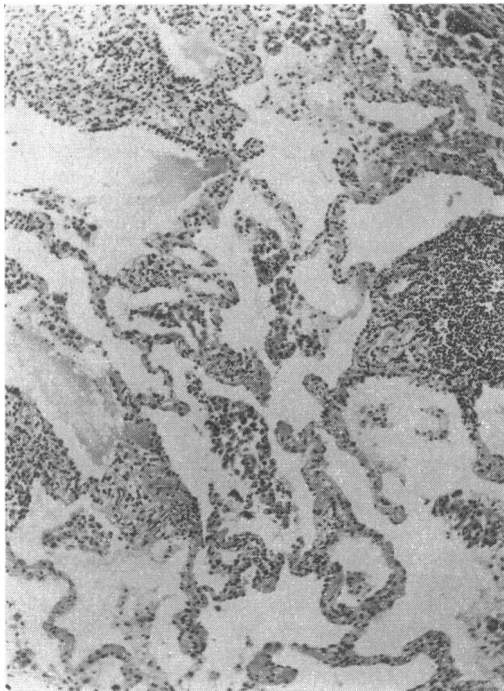


Fig 11 Case 3 *Histology of lung biopsy, showing cellular and fibrous thickening of alveolar walls, with some aggregates of lymphocytes. H & E. $\times 72$*

Radiographically, the lungs now showed mottling throughout the right and in the lower two-thirds of the left lung, with fine 'honeycombing', mainly at the bases (Fig 10). The DAT was positive at a titre of more than 1:64. The nodule from the elbow was removed and showed the histological structure of a rheumatoid nodule. A small left thoracotomy showed moderately severe fibrous and fibrinous pleural adhesions. The lung felt indurated and as if it contained nodules up to 3 mm in diameter. A biopsy specimen was removed from the lower lobe and showed great cellular and fibrous thickening of alveolar walls, most of the cells being lymphocytes and plasma cells, with some aggregations of lymphocytes; some alveoli contained large mononuclear cells; in places the fibrosis had become confluent, replacing normal lung architecture, and causing the palpable nodules (Figs 11 and 12).

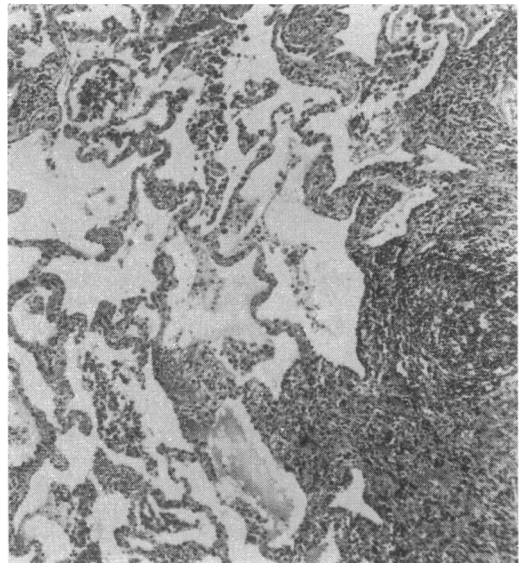


Fig 12 Case 3 *The same, showing on the right-hand side the edge of a nodule of confluent fibrosis. H & E. $\times 60$*

In spite of corticosteroid treatment, both lung and joint changes were very slowly progressive; the patient survives, much disabled by dyspnoea, and now with evidence of right ventricular failure, nearly ten years after the lung biopsy.

The other two patients in whom histological evidence was obtained, at necropsy in both, were also men, aged 57 and 54 at the time of death. In both, the lung changes were then in a stage of severe fibrotic honeycombing; radiologically they had been observed to evolve from a fine mottled pattern to honeycombing over periods of 4½ and 5 years. One had severe clubbing throughout the period of observation and the other developed it under observation. One had large subcutaneous nodules, suffered an episode of mesenteric

arteritis, and developed peripheral neuropathy; and in the other the joints and the lungs only were involved.

The other 11 patients, without histological evidence, all presented symptoms, clinical and radiographic signs, and a pattern of disordered function justifying a diagnosis of chronic fibrosing alveolitis. Of the whole series of 15, 11 were men and 4 women. This proportion of men may be unrepresentatively high; review of readily available published reports of diffuse lung fibrosis in patients with rheumatoid arthritis included 34 in men and 29 in women. The ages of my patients at the time of the first joint symptoms ranged from 22 to 63 years, with a mean of 52. In 10 cases the joint symptoms preceded the first evidence (symptomatic or radiological) of the lung changes by intervals ranging from 6 months to 11 years; in one, the joint and lung changes became evident at the same time; in 2 (including Case 3 above) the lung changes were radiologically evident two years and one year before the joint symptoms appeared; and in 2 it was not possible to date the onset of the lung changes. In all cases, the lung changes have followed a very indolent course; and, like fibrosing alveolitis of the chronic mural type in patients without rheumatoid arthritis, have shown little or no response to corticosteroid treatment.

In published reports of the histological findings in the lung at biopsy or necropsy in patients with rheumatoid arthritis and pulmonary fibrosis (Brannan *et al.* 1964, Cruickshank 1959, Cudkowicz *et al.* 1961, Dixon & Ball 1957, Edge & Rickards 1957, Ellman & Ball 1948, Flatley 1959, Gresham & Kellaway 1958, Katz & Auerbach 1951, Locke 1963, Ognibene 1960, Price & Skelton 1956, Ramirez-R & Campbell 1966, Rubin 1955, Rubin *et al.* 1967) the most constant findings are thickening of alveolar walls by cellular infiltration, principally by lymphocytes, plasma cells, histiocytes and fibroblasts, and by fibrosis, and the presence of large mononuclear cells, classified variously as macrophages, alveolar phagocytes, or alveolar lining cells, in the alveolar spaces. In some instances, the condition had progressed to macroscopic honeycombing. In some, hyperplasia of lymphoid tissue was noted. The pattern therefore conformed, as in my cases, to that of fibrosing alveolitis of the mural type. Additional features, observed in a few cases only, were thickening of walls of arterioles, and involvement of bronchioles. In most, there was no feature of the histology suggestive of the structure of a rheumatoid nodule, and nothing to distinguish it from that of the mural type of fibrosing alveolitis occurring in patients without arthritis. In a small number of cases, however, this sort of lung change was

accompanied by rheumatoid nodules in the lung or pleura (Cruickshank 1959 – Case 2, Gresham & Kellaway 1958 – Case 2, Rubin *et al.* 1967 – Case 1, Ramirez-R & Campbell 1966 – Case 2) or both pleuropulmonary nodules and pleural effusion (Cudkowicz *et al.* 1961, Flatley 1959). I have recently seen an ex-coalminer who had been known to have Caplan's syndrome for eleven years when, concurrently with an exacerbation of rheumatoid arthritis, the characteristic clinical, radiological and functional evidences of fibrosing alveolitis appeared, and proceeded to 'honeycombing' at the bases of the lungs.

Relationship of Fibrosing Alveolitis to Rheumatoid Arthritis

The problems posed by the concurrence of rheumatoid arthritis and fibrosing alveolitis, like many others in clinical medicine, have both logical and factual components. Until we have clearly defined each of them, we cannot say what is meant, in factual terms, by the statement that these two diseases are related. To anyone who clings to the naïve notion that in formulating the concept of a disease we have identified a cause of illness, this discussion will seem superfluous; the only question for him will be one of causal relationship. But analysis of the concept 'a disease' shows that it cannot be regarded in this simple way (Scadding 1967). A disease may be defined as 'the sum of the abnormal phenomena displayed by a group of living organisms in association with a common characteristic or set of characteristics by which they differ from the norm for their species in such a way as to place them at a biological disadvantage'. An individual disease is defined by the common characteristic which distinguishes the group of organisms (patients, in human medicine) upon the study of which its description is based. The common characteristic may be of several disparate types: among these the more frequently used are recognizable complexes of clinical symptoms and signs (syndromes), macroscopic or microscopic structural changes, disorders of function, and causative agents.

The basis of definition of 'fibrosing alveolitis' has already been discussed. It is morbid-anatomical; the clinician in making this diagnosis is forecasting, on the basis of information available to him, what the pathologist will find if the occasion arises. The nearest approach to a definition of rheumatoid arthritis that I can find is the 'diagnostic criteria' recommended by the American Rheumatism Association (Ropes *et al.* 1959) or modifications of them (Kellgren 1962). We may note that diagnostic criteria are logically distinct from defining characteristics (Scadding

1967). Only for a disease defined on a clinical-descriptive or syndromal basis will the defining characteristics necessarily be included in, and constitute the major part or even the whole of the diagnostic criteria. It is evident, therefore, that at present, rheumatoid arthritis is defined on a syndromal basis. It is true that the 11 main criteria of the ARA include 2 histological ones (changes in synovial membrane or nodules) and one serological, but these constitute possible, but not essential, parts of a complex of symptoms and signs.

The ARA criteria are to be regarded as offering an 'operational' definition whose chief purpose is to ensure that different observers refer to comparable cases when they use the same words. Evidently, these words should not be allowed to convey aetiological implications. Criteria of diminishing grades of stringency are provided for 'classical', 'definite', 'probable', and 'possible' rheumatoid arthritis; these must not be taken to be more than a means of indicating various grades of resemblance to an 'ideal' clinical picture. Unfortunately, they can all too easily be taken to imply varying degrees of confidence that a hypothetical specific agent or factor or set of factors is causing the observed symptoms and signs. The hypothesis that rheumatoid arthritis is aetiologicaly specific, and will eventually be definable on an aetiological basis, may of course be true; but it has not yet been proved to be so. It is almost irresistibly implied by the term 'rheumatoid disease'. Since the discovery that a variety of non-articular lesions may be observed in patients with rheumatoid arthritis this term has been used by some observers to include both articular and non-articular changes. But words must not be allowed insensibly to imply unproved hypotheses. In my view, 'rheumatoid disease' would be tolerable only if it were clearly and universally understood in a strictly descriptive sense, and defined in some such terms as 'the sum of the abnormal phenomena displayed by patients with the syndrome of rheumatoid arthritis, and thought to be related in some way to that syndrome'. But I doubt whether in this very broad sense the term has any useful application, and consider that the observed phenomena can be better expressed and discussed by accepting an operational definition of rheumatoid arthritis in clinical-descriptive terms, and describing the visceral changes occasionally found in patients with this syndrome in the most appropriate and precise terms (which will usually be morbid-anatomical). For each type of visceral change the evidence suggesting an association with rheumatoid arthritis and the possible nature of any association which is established can then be discussed.

We have therefore to decide whether the association between rheumatoid arthritis, defined on a clinical-descriptive or syndromal basis, and fibrosing alveolitis, defined on a morbid-anatomical basis, is more than a chance concurrence. On the whole, rheumatologists have tended to doubt whether there is any specific relationship, largely because of most of those who have surveyed large numbers of cases of rheumatoid arthritis have found an extremely low proportion with lung changes. Aronoff *et al.* (1955) in a comparative study concluded that various 'non-specific' pulmonary lesions appeared to be rather more frequent in the rheumatoid patients than in the control series, but no one particular lesion was outstanding. Short *et al.* (1957) compared 293 patients with rheumatoid arthritis with an equal number of controls, and found 'no clinical or roentgenographic evidence of pulmonary lesions as systemic manifestations of rheumatoid arthritis'. Horler & Thompson (1959) reported that of 180 patients with rheumatoid arthritis one had 'honeycomb lung' and one pleural effusion and patchy lung fibrosis. Talbott & Calkins (1964) surveyed necropsy records and compared 37 with an established diagnosis of rheumatoid arthritis with a control group constituted by selecting for each subject studied the next of the same sex and age-group in the necropsy records. They found rather more pleural changes but no difference in the proportions showing various forms of lung change. Patterson *et al.* (1965) did an uncontrolled radiological survey of 702 patients with rheumatoid arthritis, and found 9 with unexplained pulmonary fibrosis. Stack & Grant (1965) compared chest radiographs of 177 rheumatoid arthritis patients with those of a similar number attending a neurological clinic: 4 arthritic patients and 2 neurological patients had bilateral diffuse shadowing. Verhaeghe *et al.* (1967) similarly compared 180 rheumatoid arthritis patients with 180 matched controls; 8 arthritic patients had unexplained pulmonary fibrosis and 2 'reticulo-nodular' shadows, as compared with 3 and none respectively of the control group.

Those whose principal interest is in pulmonary disease have tended, on the other hand, to suspect a relationship between pulmonary fibrosis and rheumatoid arthritis: for in several large series of cases of 'diffuse interstitial pulmonary fibrosis' of undetermined cause, a relatively high proportion have occurred in patients with rheumatoid arthritis. I now have personal records of 104 patients of this sort: 15, about one-seventh, also had rheumatoid arthritis. Doctor & Snider (1962) in a review of published cases of 'diffuse interstitial pulmonary fibrosis' found that about 20% had had arthritis. It seems likely that this differ-

ence of viewpoint has arisen because this group of patients represents the intersection of a large set 'rheumatoid arthritis' with a much smaller set 'diffuse fibrosing alveolitis'.

What relationships could exist between a disease defined on a syndromal basis and a disease defined on a morbid-anatomical basis? And which of these possibilities could be considered in relation to rheumatoid arthritis and fibrosing alveolitis?

(1) If they occur together with sufficient frequency, the anatomical change might be accepted as part of the syndrome; but this evidently does not apply in the present context. Moreover, both are occasionally associated with certain changes of obscure cause in other organs, and these associations differ for the two diseases. In patients under my care with fibrosing alveolitis, but without rheumatoid arthritis, I have observed Sjögren's syndrome, Hashimoto's thyroiditis, polymyositis, ulcerative colitis and chronic interlobular hepatitis (Turner-Warwick 1968). Of these, only Sjögren's syndrome and possibly Hashimoto's thyroiditis (Buchanan *et al.* 1961) are generally regarded as associated with notable frequency with rheumatoid arthritis; and certain changes in other organs, such as scleritis, digital arteritis (Bywaters & Scott 1963) and peripheral neuropathy (Pallis & Scott 1965) have not been reported in patients with fibrosing alveolitis without rheumatoid arthritis.

(2) The presence of one might predispose to the effects of the unidentified cause of the other. This is not a satisfactory explanation, since the temporal relation of the joint and lung changes varies: although the lung changes have generally been detected after the joint changes, they may become evident at the same time, or even precede the joint changes, as in 2 of my cases and in those reported by Price & Skelton (1956) and Lee & Brain (1962).

(3) Even though they are infrequently associated, two diseases may be aetiologicaly related. It may be doubted whether, at the time when lupus vulgaris and phthisis were definable only on a clinical-descriptive basis, statistical studies would have suggested that these two diseases are associated through a common aetiological agent. The demonstration of their relationship depended upon the recognition, first of common elements in morbid histology, and finally of a common causative agent. Indeed, Virchow opposed the idea that lupus was 'scrófulous' and it was not until Friedländer in 1873 studied its histology that it was accepted as tuberculous (Webb 1936). Nevertheless, in relation to fibrosing alveolitis and rheumatoid arthritis, the fact that both diseases occur much more frequently without

than with the other, and that they have few common features beyond their occasional concurrence makes an identity of causal factors improbable.

(4) There remains for consideration the possibility that both diseases are multifactorial in causation, and that they share one or more common pathogenetic factors.

It has been suggested that rheumatoid factor might contribute to the pathogenesis of pulmonary fibrosis, by forming complexes with γ -globulin which might be deposited in pulmonary capillaries (Tomasi *et al.* 1962). Tests for rheumatoid factors in the blood serum are frequently positive in patients with fibrosing alveolitis but without arthritis (Franklin *et al.* 1959, Tomasi *et al.* 1962, Mackay & Ritchie 1965, Stretton & Leeming 1964, Turner-Warwick & Doniach 1965). But the positive results are generally at low titre, and found in only a minority of cases; e.g. 11 of 34 investigated by Turner-Warwick & Doniach. It must be remembered that positive tests for rheumatoid factor are found in a small proportion of persons without overt disease or suffering from diseases other than rheumatoid arthritis; Ball & Lawrence (1961) found sheep cell agglutination tests positive at a titre of 1:32 or more in proportions of a general population increasing with age from very low levels in young adults to 10–15% in those over the age of 65. Moreover, when fibrosing alveolitis occurs in association with rheumatoid arthritis, the titres of tests for rheumatoid factor tend to be in the range to be expected for the activity of the rheumatoid arthritis; and Tomasi *et al.* (1962) found that, among patients with rheumatoid arthritis, those with radiological evidence of lung changes had exceptionally high titres. Thus there is little evidence to support the suggestion that rheumatoid factor may be the link between fibrosing alveolitis and rheumatoid arthritis.

Thus, if there is indeed a pathogenetic factor common to rheumatoid arthritis and fibrosing alveolitis, it has yet to be demonstrated. In spite of this, I think that such a common factor is the most likely explanation of the occasional association of these two diseases.

To summarize, intrapulmonary nodules, both of the Caplan type, and in patients without pneumoconiosis, having a histological structure similar to that of subcutaneous rheumatoid nodules, occur almost exclusively in patients with the clinical syndrome of rheumatoid arthritis; they probably have considerable overlap of causal factors with rheumatoid arthritis.

Pleural effusions in patients with rheumatoid arthritis may be associated with pleural or sub-

pleural 'rheumatoid' nodules, and may have an unusually low glucose content. Pleural effusions during life and pleural adhesions at necropsy are significantly frequent in patients with rheumatoid arthritis. A relationship through common factors in pathogenesis is likely.

Fibrosing alveolitis of mural type occurs only rarely in patients with rheumatoid arthritis; but among patients with this sort of lung disease a proportion high enough to suggest more than a chance association also have rheumatoid arthritis. Although it may be that this occasional association is due to these two diseases of unknown aetiology sharing a factor or factors in multifactorial causation, no such factor has as yet been identified. Clarity of communication demands that, in the present state of knowledge, these cases should be referred to in a way that conveys no implication about their relationship, beyond their concurrence in the same patient.

REFERENCES

- Aronoff A, Bywaters E G L & Fearnley G R (1955) *Brit. med. J.* ii, 228
- Baggenstoss A H & Rosenberg E F (1943) *Arch. Path.* 35, 503
- Ball J & Lawrence J S (1961) *Ann. rheum. Dis.* 20, 235
- Bennett G A, Zeller J W & Bauer W (1940) *Arch. Path.* 30, 70
- Berger H W & Seckler S G (1966) *Ann. Intern. Med.* 64, 1291
- Bevans M, Nadell J, Demartini F & Ragan C (1954) *Amer. J. Med.* 16, 197
- Braunan H M, Good C A, Divertie M B & Baggenstoss A H (1964) *J. Amer. med. Ass.* 189, 914
- Brunk J R, Drash E C & Swineford O jr (1966) *Amer. J. med. Sci.* 251, 545
- Buchanan W W, Crooks J, Alexander W D, Koutras D A, Wayne E J & Gray K G (1961) *Lancet* i, 245
- Burrows F G O (1967) *Brit. J. Radiol.* 40, 256
- Bywaters E G L & Scott J T (1963) *J. chron. Dis.* 16, 905
- Campbell I A (1958) *Thorax* 13, 177
- Caplan A (1953) *Thorax* 8, 29
- Caplan A, Cowen E D H & Gough J (1958) *Thorax* 13, 181
- Caplan A, Payne R B & Withey J L (1962) *Thorax* 17, 205
- Carr D T & McGuckin W F (1968) *Amer. Rev. resp. Dis.* 97, 302
- Carr D T & Mayne J G (1962) *Amer. Rev. resp. Dis.* 85, 345
- Carr D T & Power M H (1960) *Dis. Chest* 37, 321
- Christie G S (1954) *Aust. Ann. Med.* 3, 49
- Collins D H (1937) *J. Path. Bact.* 45, 97
- Cruickshank B (1959) *Brit. J. Dis. Chest* 53, 226
- Cudkowicz L, Madoff I M & Abelmann W H (1961) *Brit. J. Dis. Chest* 55, 35
- Davies D (1966) *Thorax* 21, 230
- Dixon A St J & Ball J (1957) *Ann. rheum. Dis.* 16, 241
- Doctor L & Snider G L (1962) *Amer. Rev. resp. Dis.* 85, 413
- Dodson W H & Hollingsworth J W (1966) *New Engl. J. Med.* 275, 1337
- Dumas L W, Gregory R L & Ozer F L (1963) *Brit. med. J.* i, 383
- Edge J R & Rickards A G (1957) *Thorax* 12, 352
- Ellman P (1947) *Proc. roy. Soc. Med.* 40, 332
- (1956) *Postgrad. med. J.* 32, 370
- Ellman P & Ball R E (1948) *Brit. med. J.* ii, 816
- Ellman P & Cudkowicz L (1954) *Thorax* 9, 46
- Ellman P, Cudkowicz L & Elwood J S (1954) *J. clin. Path.* 7, 239
- Ferguson G C (1966) *Thorax* 21, 577
- Fingerman D L & Andrus F C (1943) *Ann. rheum. Dis.* 3, 168
- Flatley F J (1959) *New Engl. J. Med.* 261, 1105
- Franklin E C, Zucker F D & McEwen C (1959) *A.I.R. Arch. interamer. Rheum. (Rio de J.)* 2, 250
- Gough J, Rivers D & Seal R M E (1955) *Thorax* 10, 9
- Gresham G A & Kellaway T D (1958) *Ann. rheum. Dis.* 17, 286
- Gruenwald P (1948) *Arch. Path.* 46, 59
- Hayes D S & Posner E (1960) *Tubercle (Lond.)* 41, 143
- Horler A R & Thompson M (1959) *Ann. intern. Med.* 51, 1179
- Katz H L & Auerbach O (1951) *Dis. Chest* 20, 366
- Kellgren J H (1962) *Bull. rheum. Dis.* 13, 291
- Kellgren J H, Lawrence J S & Aitken-Swan J (1953) *Ann. rheum. Dis.* 12, 5
- Lee F I & Brain A T (1962) *Lancet* ii, 693
- Lee P R, Sox H C, North F S & Wood G A (1959) *Arch. intern. Med.* 104, 634
- Liebow A A, Steer A & Billingsley J G (1965) *Amer. J. Med.* 39, 369
- Locke G B (1963) *Clin. Radiol.* 14, 43
- Mackay I R & Ritchie B (1965) *Thorax* 20, 200
- Maher J A (1954) *Arch. Path.* 58, 354
- Mattingley S (1964) *Ann. phys. Med.* 7, 185
- Miail W E, Caplan A, Cochrane A L, Kilpatrick G S & Oldham P D (1953) *Brit. med. J.* ii, 1231
- Morgan W K & Wolfel D A (1966) *Amer. J. Roentgenol.* 98, 334
- Noonan C D, Taylor F B jr & Englemann E F (1963) *Arthr. and Rheum.* 6, 232
- Ognibene A J (1960) *Arch. intern. Med.* 105, 762
- Pallis C A & Scott J T (1965) *Brit. med. J.* i, 1141
- Panettiers F, Chandler B F & Libcke J H (1968) *Amer. Rev. resp. Dis.* 97, 89
- Patterson C D, Harville W E & Pierce J A (1965) *Ann. intern. Med.* 62, 685
- Portner M M & Gracie W A jr (1966) *New Engl. J. Med.* 275, 697
- Posner E (1960) *Brit. J. industr. Med.* 17, 109
- Price T M L & Skelton M D (1956) *Thorax* 11, 234
- Ramirez-R J & Campbell G D (1966) *Dis. Chest* 50, 544
- Rickards A G & Barrett G M (1958) *Thorax* 13, 185
- Robertson J L & Brinkman G L (1961) *Amer. J. Med.* 31, 483
- Ropes M W & Bauer W (1953) *Synovial Fluid Changes in Joint Disease*. Cambridge, Mass
- Ropes M W, Bennett G A, Cobb S, Jacox R & Jessar R A (1959) *Arthr. and Rheum.* 2, 16
- Ropes M W, Muller A F & Bauer W (1960) *Arthr. and Rheum.* 3, 496
- Rubin E H (1955) *Amer. J. Med.* 19, 569
- Rubin E H, Gordon M & Thelmo W L (1967) *Amer. J. Med.* 42, 567
- Scadding J G (1964) *Brit. med. J.* ii, 686, 941
- (1967) *Lancet* ii, 877
- Scadding J G & Hinson K F W (1967) *Thorax* 22, 291
- Short C L, Bauer W & Reynolds W E (1957) *Rheumatoid Arthritis*. Cambridge, Mass
- Sieniewicz D J, Martin J R, Moore S & Miller A (1962) *J. Canad. Ass. Radiol.* 13, 73
- Sinclair R J G & Cruickshank B (1956) *Quart. J. Med.* 25, 313
- Stack B H & Grant I W B (1965) *Brit. J. Dis. Chest* 59, 202
- Stengel B F, Watson R R & Darling R J (1966) *J. Amer. med. Ass.* 198, 1263
- Stretton T B & Leeming J T (1964) *Thorax* 19, 79
- Talbott J A & Calkins E (1964) *J. Amer. med. Ass.* 189, 911
- Telleson W G (1961) *Thorax* 16, 372
- Tomasi T B jr, Fudenberg H H & Finby N (1962) *Amer. J. Med.* 33, 243
- Turner-Warwick M (1968) *Quart. J. Med.* 37, 133
- Turner-Warwick M & Doniach D (1965) *Brit. med. J.* i, 886
- Verhaeghe A, Taquet A, Voisin C, Lemaitre G, Lebeurre R, Delcambre B & Defouillouy A (1967) *Lille med.* 12, 165
- Walker W C (1967) *Quart. J. Med.* 36, 239
- Walker W C & Wright V (1967) *Ann. rheum. Dis.* 26, 467
- Ward R (1961) *Lancet* ii, 1336
- Webb G B (1936) *Tuberculosis*. Clío Medica, New York; p 87
- Yates D A H (1963) *Ann. phys. Med.* 7, 105