

apparent invasion of the blood. One was a septi-cæmia with no apparent meningeal involvement. The first two responded to treatment with terramycin and with massive penicillin plus streptomycin. Neither penicillin nor tetracycline was effective in the septi-cæmia which complicated or was complicated by an obstructive jaundice of unknown etiology.

The authors wish to thank Dr. J. C. O'Brien and Dr. H. I. MacGregor for their assistance with these cases; and Professor E. G. D. Murray for helpful information.

REFERENCES

1. MURRAY, E. G. D., WEBB, R. A. AND SWANN, M. B. R.: *J. Path. & Bact.*, **29**: 407, 1926.
2. MURRAY, E. G. D.: *Canad. M. A. J.*, **72**: 99, 1955.
3. NYFELDT, A.: *Compt. rend. Soc. de biol.*, **101**: 590, 1929.
4. GIRARD, K. F. AND MURRAY, E. G. D.: *Am. J. M. Sc.*, **221**: 343, 1951.
5. MURRAY, E. G. D.: Personal communication.
6. KAPLAN, M. M.: *New England J. Med.*, **232**: 755, 1945.
7. BINDER, M. A., et al.: *Ann. Int. Med.*, **38**: 1315, 1953.
8. STOOT, D. W.: To be published.
9. ALLIN, A. E. AND KEMPER, D.: *Canad. J. Pub. Health*, **45**: 27, 1954.
10. JOHNSTON, W. H., et al.: *Canad. M. A. J.*, **73**: 402, 1955.
11. ROY, T. E.: Personal communication.
12. LINE, F. G. AND CHERRY, W. B.: *J. A. M. A.*, **148**: 366, 1925.
13. FINEGOLD, S. M., et al.: *A. M. A. Arch. Int. Med.*, **93**: 515, 1954.
14. WILLIAMS, R. AND HORUNG, J.: *Am. J. Clin. Path.*, **24**: 962, 1954.

SEPTICÆMIA OF THE NEWBORN DUE TO LISTERIA MONOCYTOGENES*

W. H. JOHNSTON, M.D.,
S. A. MORTON, M.B., M.R.C.P., D.C.H.,
M. H. WONG, M.B., Ch.B.(Edin.), and
T. E. ROY, M.D., Toronto

LISTERIA MONOCYTOGENES occurs in man and in many other animal species. The microorganism was first isolated and studied in 1924 by Murray, Webb, and Swann¹ from an epizootic affecting their laboratory rabbits. The organism found by Hülphers² in 1911 and called *Bacterium hepatis* was probably *L. monocytogenes*. It was first isolated from a human subject in 1929 by Nyfeldt,³ who found it in the blood stream of a 17-year-old boy with infectious mononucleosis. Listeriosis has been reviewed by Kaplan,⁴ Girard and Murray,⁵ and Murray.^{6, 7}

Natural infections with *L. monocytogenes* have been reported in many species of wild and domestic mammals and birds from many parts

of the world including Canada, but the incidence of such infections appears to be low. Listeriosis in Canadian lemmings has been reviewed recently by Barrales.⁸ The disease in animals often takes the form of a generalized infection associated with multiple small foci of necrosis, particularly in the liver, but a common manifestation of the natural disease in ruminants is an encephalitis or a meningitis. The microorganism has been found in the genital tract of guinea-pigs, rabbits, horses, and cattle, and may cause metritis and abortion. Conjunctivo-keratitis, myocarditis, and other atypical forms have also been reported. A most interesting characteristic is the monocytosis which occurs in rabbits 48 to 72 hours after the injection of the microorganism or of a lipid extract of the microorganism. This phenomenon has suggested a relationship between *L. monocytogenes* and infectious mononucleosis, a suggestion which has not received wide support.

Infections in human subjects occur sporadically and appear to be infrequent. Kaplan, in 1945, collected the reports of 23 definite and 13 probable cases of human listeriosis from all parts of the world. Fourteen of these isolations were from cases of infectious mononucleosis; the remaining 22 cases were diagnosed as meningitis. Most of the patients were adults. Only three reported by Burn⁹ in 1936, were under one year of age; these had meningitis. The mortality was high (79%) in the cases of meningitis. The epidemiology of the disease remains obscure. From these earlier reports it would appear that the disease occurs mostly in adults and older children and that the usual manifestation in man is a meningitis. However, Potel and others¹⁰⁻¹² have reported from Germany an unusually large number of infections (over 15) which occurred in infants and sucklings and from which *L. monocytogenes* was isolated. These patients suffered from an acute septicæmic disease, fatal in a large number of cases, which the authors called "granulomatosis infantiseptica." It was characterized by miliary granulomata with necrosis, found particularly in the liver, spleen, suprarenals, lungs, lymph nodes, and brain. A similar series of 10 fatal cases observed in 1951 and 1952 in Prague has been reported by Patocka and Benda.¹³

Listeriosis in human subjects had not been reported in Canada before 1951 when Stoot¹⁴ isolated *L. monocytogenes* from a premature infant who died in Toronto 45 hours after birth. Allin and Kemper¹⁵ later found it to be the cause

*From the Department of Bacteriology, the Department of Pathology and the Research Institute, The Hospital for Sick Children, Toronto.

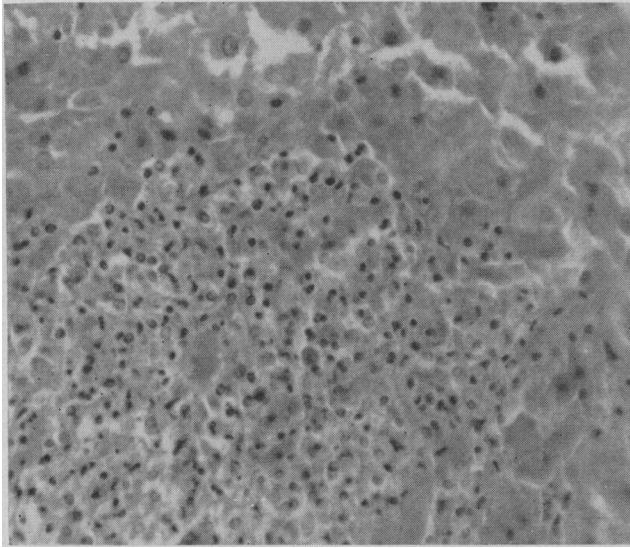


Fig. 1.—Small necrotic abscess in liver.

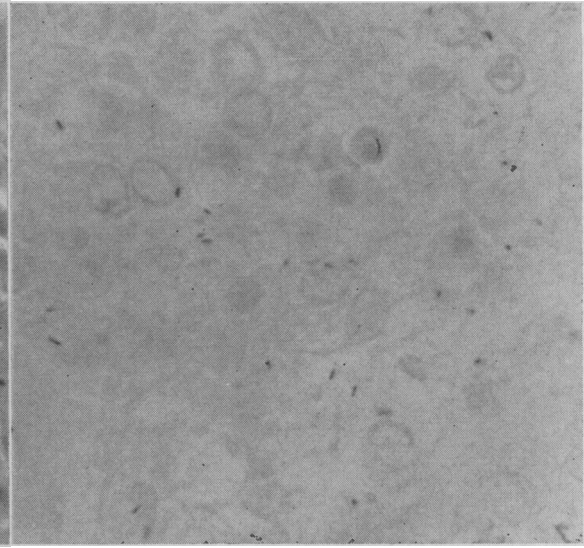


Fig. 2.—Gram-positive bacilli in liver lesion.

of a fatal meningitis in an adult in Port Arthur. Two cases have been found more recently in Montreal,¹⁶ two in Halifax,¹⁷ and one other in an adult in Toronto.¹⁸

CASE 1

Baby M. was born by precipitate delivery at the 36th week of a normal pregnancy. The infant was small, weighing 4 lb. 11 oz. (2,100 g.) Her immediate condition at birth was good, but on the first day of life she had two brief cyanotic attacks. On the morning of the second day she was found to have impaired vigour, moderate jaundice, and skin hæmorrhages. On admission to the Hospital for Sick Children at 36 hours of age the baby was moribund, with subnormal temperature, deep jaundice, numerous petechiæ on the extremities, slight enlargement of the liver, abdominal distension, and sclerema. Cultures of blood and cerebrospinal fluid grew *L. monocytogenes*. Stained films of the cerebrospinal fluid showed polymorphonuclear cells but no microorganisms. The baby was treated with parenteral sulphadiazine, penicillin and streptomycin, but died seven hours after admission.

At autopsy all the organs appeared normal except the liver, which was uniformly enlarged and firm. It weighed 103 g., compared with a normal weight of 88 g. for an infant of this size. The surface and substance were studded with submiliary greyish-white nodules which were not raised or palpable. Both lobes appeared equally affected.

Microscopical examination showed many small areas of hepatic necrosis with little inflammatory reaction (Fig. 1). These had no relationship to any part of the liver lobule. Many Gram-positive, short, slightly beaded rods were seen in these lesions (Fig. 2). There were similar foci in the spleen, the adrenal medulla, thymus, bone marrow, and the submucosa of the bladder. Sections of the brain showed the presence of an acute meningitis with a polymorphonuclear reaction. No focal accumulations of mononuclear cells were found. The myocardium was normal.

There was no history of febrile or other illness in the mother before delivery or post partum. She had been employed as a laboratory technician in Toronto but did not handle experimental animals. There were no household pets. In view of the early onset of septicæmia in the infant following delivery, it was thought that the mother might have harboured the microorganism and

infected the child. Vaginal cultures were taken which grew *L. monocytogenes*. The mother did not return for further examinations.

CASE 2

Baby P. died at the age of 3 hours. The pregnancy was normal, but the mother had a slight head cold for one week before delivery and was feverish for 20 hours before the onset of labour at about the 35th week. Labour and delivery lasted for six hours; the membranes did not rupture prematurely. The amniotic fluid was reported as being "murky" but not foul-smelling. The baby was cyanotic and flaccid at birth, and her face was covered with petechiæ. She was transferred immediately to the Hospital for Sick Children but died within two hours of admission.

Autopsy was undertaken. The infant was slightly premature, weighing 5 lb. 4 oz. (2,400 g.) and the body was covered with small petechiæ. The liver was enlarged (160 g. as compared with a normal weight of 105 g. for an infant of this size) but otherwise grossly normal. The lungs were moderately collapsed but without evidence of hæmorrhage or consolidation. The blood vessels over the brain were congested but there was no obvious meningitis. The post-mortem blood culture grew *L. monocytogenes*, as did cultures from the lung tissue.

Histological sections of the lungs showed a bronchitis and bronchiolitis with a radiating bronchopneumonia. The pulmonary alveoli were filled with amniotic debris and there was early hyaline membrane formation. Many small abscesses with a mononuclear cell response were seen in the adrenal gland (Fig. 3). There was pus on the surface of the gastric mucosa with a slight inflammatory reaction in the mucous membrane (Fig. 4). Gram-positive bacilli were found in the adrenal abscesses, in the pus covering the gastric mucosa, and diffusely throughout the lungs. The liver, brain, and remaining organs were normal.

Because of her febrile illness the mother was treated with penicillin and streptomycin for three days after delivery. Her temperature subsided rapidly and the post-partum period was uneventful. Cultures of blood, nasopharynx and vagina were taken on the second post-partum day and after the start of antibiotic therapy. The throat and blood cultures were negative, but the vaginal culture grew *L. monocytogenes*. Two weeks after delivery further vaginal cultures were negative. At this latter time a blood smear was normal and a heterophil antibody test (Paul-Bunnell) was negative, but the mother's serum agglutinated suspensions of *L. mono-*

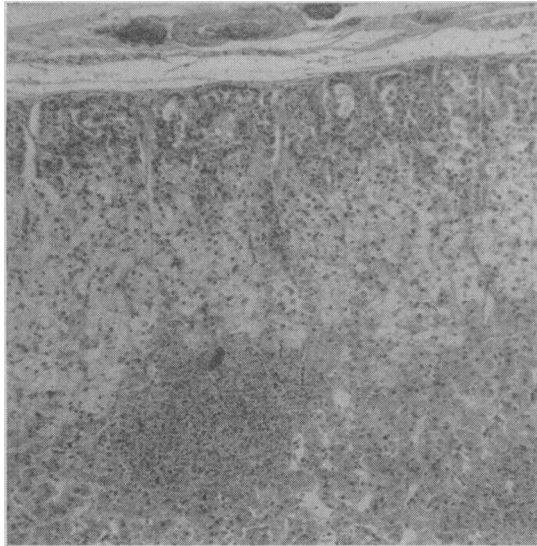


Fig. 3.—Small abscess in adrenal.

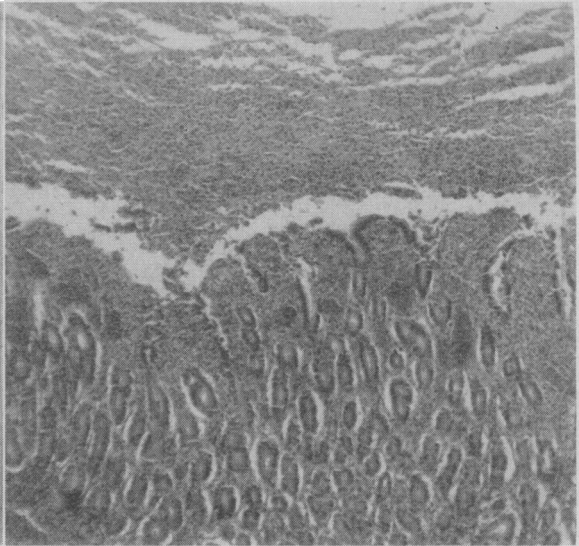


Fig. 4.—Section of gastric mucosa showing layer of pus on the surface.

cytogenes to a serum dilution of 1:1,024. A notable feature of the agglutination tests was the presence of a marked pro-zone extending up to serum dilutions of 1:128.

The source of the infection in this second mother also remained obscure. There were no household pets or obvious contacts with animals. The families in both cases lived in Toronto but were unknown to each other. Deliveries of the two mothers took place in different hospitals with a seven-month interval between them. Moreover, the strains of microorganism associated with the first case were of serological Type 4 while those from the second were Type 1.*

BACTERIOLOGY

All strains of microorganisms associated with these two cases had the same morphological and cultural characters. All were small Gram-positive rods resembling diphtheroids and showing some V-formations and palisading. They were motile, this being more marked in young broth cultures grown at room temperature than at 37° C. Motility often showed a "tumbling" characteristic. Spores were not formed.

Growth occurred readily on all ordinary media under aerobic conditions. The colonies on sheep's blood agar at 24 hours were small, regular, circular, convex, smooth, moist, slightly opaque and greyish. A narrow zone of beta hæmolysis appeared in 24 to 48 hours. A flocculent, easily

dispersible growth developed in plain nutrient broth.

The microorganisms produced acid but no gas in 24 hours at 37° C. in bromcresol-purple peptone media containing glucose, maltose, salicin, or rhamnose. Lactose was acidified slowly. Acid was not produced from sucrose, dulcitol, xylose, arabinose, or inositol. Nitrates were not reduced. Neither indol nor hydrogen sulphide was produced. The catalase test was positive.

A rabbit was injected intravenously with 0.5 ml. of an 18-hour broth culture of the strain isolated from the cerebrospinal fluid in Case 1. The animal survived, but a definite monocytosis was evident on the 3rd and 4th days, as shown in Table I.

The antibiotic sensitivities of the strains were tested by the three-disk technique (Difco) on blood agar. All strains were sensitive to aureomycin, bacitracin, chloramphenicol, erythromycin, neomycin, terramycin, and tetracycline. They were moderately sensitive to streptomycin, slightly sensitive to penicillin, and resistant to polymyxin B.

COMMENT

The occurrence of two cases of listeriosis in newborn infants in the Hospital for Sick Children within the period of one year is most unusual in view of the fact that the disease had not been recognized in Canada before 1951. One might wonder whether such cases have been misdiagnosed in the past. While the microorganism might easily be disregarded as a contaminating diph-

*Serological typing was kindly done for us by Professor E. G. D. Murray.

TABLE I.

MONOCYTE RESPONSE IN RABBIT TO <i>Listeria Monocytogenes</i> (0.5 ML. OF 18-HOUR CULTURE INTRAVENOUSLY)							
	White cell count (c.mm.)	Differential (%)					Absolute No. of Monocytes
		Neutrophils	Eosinophils	Basophils	Lymphocytes	Monocytes	
Before injection.....	7,500	23	1	3	69	4	300
After 24 hours.....	6,600	32	0	0	66	2	130
After 3 days.....	17,000	30	2	1	39	28	4,760
After 4 days.....	9,800	28	0	4	54	14	1,370
After 5 days.....	6,000	38	2	2	48	10	600

theroid if motility tests are not done, it is likely that attention would be directed to any case of meningitis in which a similar diphtheroid was found in both the blood and cerebrospinal fluid. Moreover, the characteristic small foci of necrosis in the liver and other organs had not been observed previously in histological material from autopsies on newborn infants at this hospital. Misdiagnosis, therefore, seems unlikely.

A noteworthy feature of the European cases of listeriosis in infants, of Stoot's case, and of both our cases is the recovery of *L. monocytogenes* from the vagina of the mother. The observations of the European workers led them to believe that infection of the infant took place *in utero* and was not the result of cross-infection within nurseries. The mothers in these cases occasionally showed clinical evidence of mild infection at the time of parturition, and this often led to premature birth. These views are supported by our observations. One might note that both our infants were small and somewhat premature.

The infection of newborn infants might be acquired ante-partum through the placenta or amniotic fluid, or intra-partum from the birth canal. No definite conclusions as to the mode of infection can be drawn from our first case. The mother had no signs of infection, the illness of the child developed only on the first day of life, and the age of the lesions could not be adequately assessed histologically. In our second case, however, the mother appeared to have had an active *Listeria* infection at the time of delivery as shown by the fever, the isolation of the micro-organism from the genital tract, and the high agglutinating titre of her serum two weeks later. The premature infant was extremely ill at birth following a labour of short duration without premature rupture of the membranes, and died at 3 hours of age with well-developed histological lesions in the tissues. Moreover, the distribution of the lesions in the lungs and the presence of

the *Listeria*-containing pus on the surface of the stomach mucosa suggest that the infection was acquired by aspiration and swallowing of infected amniotic fluid. Cultures of the mother's blood before labour and antibiotic therapy, cytological and cultural examination of the amniotic fluid, and gross and histological examination of the placenta, might have yielded still more significant information in these cases.

SUMMARY

1. Two cases of listeriosis in newborn premature infants have been described.
2. The infection in one case was acquired from the mother either *in utero* or during delivery.
3. The other case became infected *in utero* before the onset of labour.

We wish to thank the following for permission to publish details of these cases: Dr. H. W. Bain, Dr. W. G. Dobson, Dr. W. L. Donohue, Dr. S. F. Goodchild, Dr. H. W. Johnston, and Dr. C. E. Snelling. We are grateful to Miss J. Marion Johnson for technical assistance, and to Dr. D. H. Bowden for help in examining the histological preparations.

REFERENCES

1. MURRAY, E. G. D., WEBB, R. A. AND SWANN, M. B. R.: *J. Path. & Bact.*, **29**: 407, 1926.
2. HÜLPHERS, G. B.: *Svensk. veterinærtidskr.*, **16**: 265, 1911.
3. NYFELDT, A.: *Compt. rend. Soc. de biol.*, **101**: 590, 1929.
4. KAPLAN, M. M.: *New England J. Med.*, **232**: 755, 1945.
5. GIRARD, K. F. AND MURRAY, E. G. D.: *Am. J. M. Sc.*, **221**: 343, 1951.
6. MURRAY, E. G. D.: *Tr. Royal Soc. Canada*, Vol. 47, Series 3, Sect. 5, p. 15, June, 1953.
7. Idem: *Canad. M. A. J.*, **72**: 99, 1955.
8. BARRALES, D.: *Canad. J. Pub. Health*, **44**: 180, 1953.
9. BURN, C. G.: *Am. J. Path.*, **12**: 341, 1936.
10. REISS, H. J., PÖTEL, J. AND KREBS, A.: *Klin. Wchnschr.*, **29**: 29, 1951.
11. PÖTEL, J.: *Zentralbl. Bakt. I. Abt. Orig.*, **156**: 490, 1951.
12. SEELIGER, H.: *Deutsche Med. Wchnschr.*, **77**: 583, 1952.
13. PATOCKA AND BENDA: *Ceskoslov. Hyg. Epidemiol., Mikrobiol.*, **2**: 325, 1953.
14. STOOT, D. W.: To be published.
15. ALLIN, A. E. AND KEMPER, D.: *Canad. J. Pub. Health*, **45**: 27, 1954.
16. MURRAY, E. G. D.: Personal communication.
17. REED, R. W.: Personal communication.
18. GREY, P. H.: Personal communication.