

# MCF10AT: A Model for the Evolution of Cancer from Proliferative Breast Disease

Peter J. Dawson,\* Sandra R. Wolman,<sup>†</sup>  
Larry Tait,<sup>‡</sup> Gloria H. Heppner,<sup>‡</sup> and  
Fred R. Miller<sup>‡</sup>

From the Department of Pathology and Laboratory  
Medicine, University of South Florida and James A. Haley  
V. A. Hospital,\* Tampa, Florida; Oncor, Inc.,<sup>†</sup> Gaithersburg,  
Maryland; and Breast Cancer Program,<sup>‡</sup> Barbara Ann  
Karmanos Cancer Institute, Detroit, Michigan

**A human cell line (MCF10A) originated from spontaneous immortalization of breast epithelial cells obtained from a patient with fibrocystic disease. MCF10A cells do not survive in vivo in immunodeficient mice. However, T24 c-Ha-ras oncogene-transfected MCF10A cells (MCF10AT) form small nodules in nude/beige mice that persist for at least 1 year and sporadically progress to carcinomas. By reestablishing cells in tissue culture from one of the carcinomas, a cell line designated MCF10AT1 was derived that forms simple ducts when transplanted in Matrigel into immunodeficient mice. With time in vivo, the epithelium becomes proliferative and a cribriform pattern develops within the xenografts. A significant number progress to lesions resembling atypical hyperplasia and carcinoma in situ in women, and ~25% progress to invasive carcinomas with various types of differentiation including glandular, squamous, and undifferentiated. Cells have been established in culture from lesions representing successive transplant generations. With each generation, cells are somewhat more likely to progress to high risk lesions resembling human proliferative breast disease. Although the incidence of invasive carcinoma remained fairly constant at 20 to 25%, the frequency of nodules showing proliferative breast disease rose from 23% in the first transplant generation to 56% in the fourth transplant generation. (Am J Pathol 1996, 148:313-319)**

The human cell line MCF10A originated from spontaneous immortalization of non-malignant breast epithelium.<sup>1</sup> It acquired the ability for xenograft growth after mutated T24 *H-ras* transfection. The original transplants into nude/beige mice generated ducts lined by simple or hyperplastic epithelium and occasionally squamous, glandular, or undifferentiated carcinomas.<sup>2</sup> Serial passage of the *H-ras* oncogene-transfected cells (MCF10AT, formerly designated MCF10AneoT<sup>2</sup>) produces lesions in immunodeficient mice that demonstrate a complex of morphological types and grades that recapitulates the morphological characteristics of human proliferative breast disease as well as, in a minority of mice, *in situ* and invasive cancer. Although there is considerable variation among experiments and individual animal hosts, there is, overall, an evolutionary morphological sequence from hyperplasia to invasive carcinoma, which mirrors that seen in the development of human breast cancer.

Cells from cultures of MCF10AT and variants cultured from xenograft lesions are suspended in Matrigel (Collaborative Research, Bedford, MA) and inoculated into nude or nude/beige immunodeficient mice. MCF10AT cells initially form small ducts lined by a single layer of epithelium in a matrix lacking connective tissue and poor in vasculature. Although myoepithelial cells are observed, they are inconspicuous. Subsequently there is extensive epithelial proliferation resembling that seen in proliferative breast disease of women. However, the histological lesions do not correspond perfectly to those identified in human breast, and the criteria for defining stages of proliferative breast disease in humans have been modified slightly. We have developed a grading system (Table 1) to approximate those that have

---

Supported by National Institutes of Health grant CA28366 (FRM), NIH core grant CA22453 to the Michigan Cancer Foundation/Meyer L. Prentiss Comprehensive Cancer Center of Metropolitan Detroit, and a grant from the Elsa U. Pardee Foundation (GHH).

Accepted for publication September 21, 1995.

Address reprint requests to Dr. Fred Miller at Breast Cancer Program, Karmanos Cancer Institute-Meyer L. Prentiss Center, 110 E. Warren Ave., Detroit, MI 48201.

Table 1. Criteria for Grading of Proliferative Breast Lesions

Grade	Classification	Description
0	Simple epithelium	Small ducts Single layer of luminal epithelium* No nuclear enlargement No nucleoli or mitoses
1	Mild hyperplasia	Small ducts Two or more layers of epithelial cells* No significant bridging Variable nuclear contours
2	Moderate hyperplasia	Mildly distended ducts Four or more layers of epithelial cells* Irregular papillary proliferation Bridging by non-uniform cells Irregularly shaped lumens No solidly filled spaces Indistinct cell boundaries Variable nuclear contours Bland chromatin, small nucleoli
3	Atypical hyperplasia	Grossly distended ducts Regular micropapillary configuration Marked cellular proliferation often forming luminal mass Some regularity (roundness) of spaces Some loss of polarity Cells become monotonous Tendency to clear cytoplasm with distinct borders Enlarged, nonround hyperchromatic nuclei Small nucleoli, occasional mitoses
4	Carcinoma <i>in situ</i>	Distended ducts filled with uniform cells Rigid intraluminal bridges forming round spaces Occasional central necrosis Distinct cell boundaries Uniform round, hyperchromatic, enlarged nuclei Prominent nucleoli, frequent mitoses
5	Invasive carcinoma	Glandular, squamous, or undifferentiated

\*Because of the inconspicuous nature of the myoepithelial cells in many of the specimens, they were not considered as a layer.

evolved in recent years for evaluation of surgical specimens.<sup>3-5</sup> With this set of criteria, we have classified the experimental lesions in each of four sequential transplant generations. Our purpose is to chart the frequency, rate of development, and morphological sequence, and ultimately to examine the relevance of this model to proliferative breast disease and cancer in the human.

## Materials and Methods

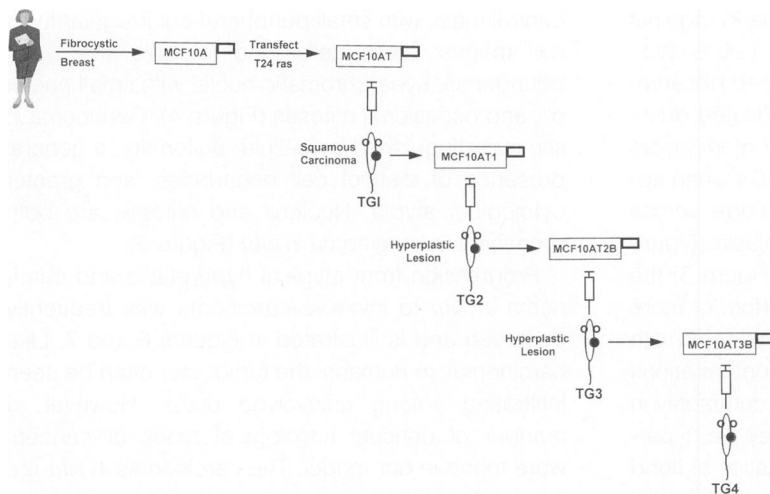
### Transplantation

The MCF10A cells were transfected with T24 *ras*<sup>6</sup> and the resulting MCF10AT cells were xenografted into nude or nude/beige mice (Life Sciences, St. Petersburg, FL) to form transplant generation 1 lesions. Results from three separate experiments with these cells were pooled for the analysis reported here (results from all three were similar). The first

(previously reported<sup>2</sup>) utilized MCF10AT cells after 1960 days in culture injected subcutaneously into male nude/beige mice (12 xenografts). The second and third experiments utilized cells after 2067 days in culture injected subcutaneously into female nude/beige or nude mice, respectively. Inocula consisted of  $1 \times 10^7$  cells in 0.1 ml of Matrigel.

MCF10AT1 cells were derived from a 100-day first transplant generation lesion (squamous carcinoma) as previously described,<sup>2</sup> grown in culture and xenografted to form the second transplant generation. Two experiments were pooled in which MCF10AT1 cells, after 19 days in culture, were injected subcutaneously into eight male nude mice or, after 60 days in culture, into 24 female nude/beige mice.

MCF10AT2B cells were derived from a 218-day second transplant generation lesion classified as grade 3, atypical hyperplasia, grown in culture and xenografted to form a third transplant generation. In a single experiment these cells, after 18 days in



**Figure 1.** The derivation of the MCF10ATn lines is depicted. The MCF10A cells were transfected with T24 ras, and the resulting MCF10AT cells were xenografted into nude/beige mice. MCF10AT1 cells were derived from a carcinoma, grown in culture, and xenografted again. MCF10AT2B cells were derived from a hyperplastic lesion, grown in culture, and again xenografted. MCF10AT3B cells were derived from a resulting hyperplastic lesion and grown in culture.

culture, were injected subcutaneously into 15 female nude/beige mice.

MCF10AT3B cells were derived from a 94-day third transplant generation lesion classified as grade 2, moderate hyperplasia, grown in culture and xenografted to form the fourth transplant generation. Three experiments in female nude/beige mice were pooled for analysis (cells injected after 33 days, 63 days, or 87 days in culture), all with the modification that  $1 \times 10^7$  cells were inoculated in 0.2 ml of Matrigel. In one experiment, some female mice were implanted subcutaneously with a tamoxifen-impregnated 60-day slow release pellet (5 mg tamoxifen/pellet designed to attain blood levels of 3 to 4 ng/ml; Innovative Research of America, Toledo, OH) 7 weeks after xenografting. This short-term treatment with Tamoxifen in mice not supplemented with estradiol had no apparent effect on persistence and progression of the lesions and, thus, data were pooled.

After subcutaneous inoculation, animals were checked for palpable lesions at weekly intervals. Although a few animals were killed relatively soon after inoculation, in general mice were maintained until signs of ill health developed to provide maximum opportunity for progression. Thus, most lesions were observed for several months. When the host animal was sacrificed and the lesion resected, a portion was fixed and blocked for histological examination and in some cases the remainder was minced and returned to growth in culture (periods of intervening culture are necessary to expand the cell populations for study and further transplant). Cells from culture were used to reconfirm the human origins and original patient source by DNA fingerprinting.<sup>2</sup> The cells have retained through the fourth transplant generation the human chromosome pattern and rearrangements observed in the original

cultures and transplants with little or no modification.<sup>1,7</sup> The lineages of the cells described in this report are diagrammed in Figure 1.

### Recovery of Cells from Lesions

As previously described in detail,<sup>2</sup> portions of the lesions were dissociated with collagenase. Epithelial clumps were periodically harvested and the enzyme mixture replenished over a 72-hour period. Clumps, which were "organoid" in appearance, were pooled to obtain monolayer outgrowths. Fibroblasts were removed from primary cultures by brief rinses with trypsin and EDTA. Cultures were maintained as described previously.<sup>1</sup>

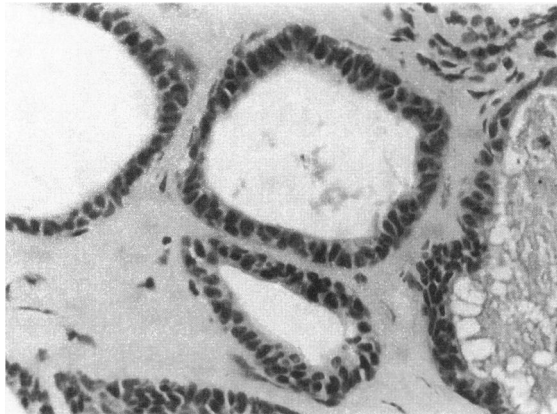
### Grading of Lesions

Using the criteria listed in Table 1, each lesion was graded according to the most advanced (deviant from normal) morphological pattern observed within it. The categories (0 = simple epithelium, 1 = mild hyperplasia, 2 = moderate hyperplasia, 3 = atypical hyperplasia, 4 = carcinoma *in situ*, 5 = invasive carcinoma) are intended to correspond as closely as possible to those that describe stages of human proliferative breast disease at the same level.<sup>2-5</sup>

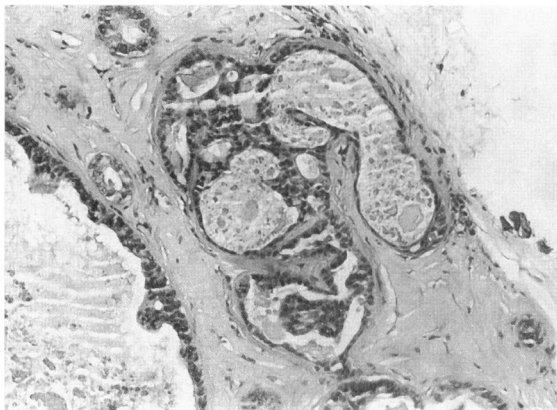### Results

Small ductules or acini developed within 3 weeks of inoculation in Matrigel. With time, the lesions sporadically progressed through sequential steps of proliferative breast disease. The ducts were lined by luminal epithelial cells, although both early and relatively advanced stages contained cells that by location, morphology, and staining with monoclonal

antibody 1A4 (Dako, Glostrup, Denmark) against smooth muscle  $\alpha$ -actin (F. R. Miller, L. Tait, S. Wolman, P. J. Dawson, K. Galea, unpublished observations) resemble myoepithelium. Mildly dilated ducts with minimal proliferation of cells (two or more layers of epithelium excluding myoepithelial cells when apparent) with little or no tendency to bridge across spaces are recognized as mild hyperplasia (Figure 2), whereas in moderate hyperplasia (Figure 3) the ducts are dilated with heaped-up cells (four or more layers), which create heterogeneous spaces with slit-like lumina peripherally. Papillary configurations are observed for both grades but more commonly in grade 2 lesions. The epithelial cells may be hyperchromatic and pleomorphic. Characteristics of florid hyperplasia and atypical hyperplasia are described as components of grade 3; they often include a large



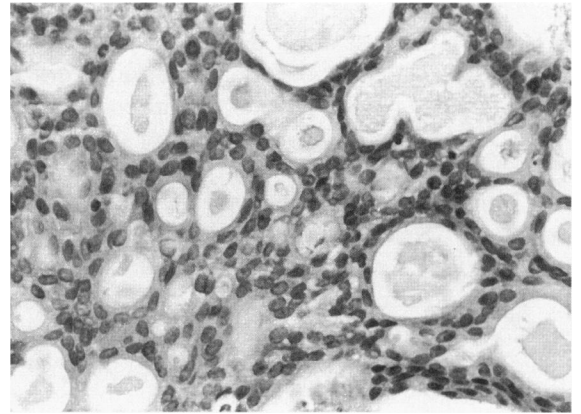
**Figure 2.** A grade 1 lesion depicting mild hyperplasia. The small ducts are lined by one or two layers of small epithelial cells with scant cytoplasm and small variable nuclei. This lesion was removed from a nude/beige mouse 288 days after injecting MCF10AT1 cells. (H&E, original magnification  $\times 400$ ).



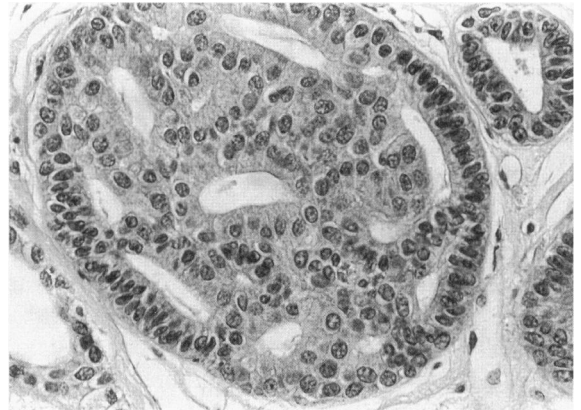**Figure 3.** A grade 2 lesion with a large cystic space lined by several layers of cells with enlarged irregular nuclei. The smaller cysts show papillary projections and irregularly formed spaces. The nuclei are similarly enlarged and irregular. This lesion was removed from a nude/beige mouse 407 days after injecting MCF10AT3B cells. (H&E, original magnification  $\times 160$ ).

central mass with small peripheral but irregular luminal spaces; some cells tend to have sharp cell boundaries, hyperchromatic nuclei with small nucleoli, and occasional mitoses (Figure 4). Carcinoma *in situ* is distinguished by cellular uniformity, a general presence of distinct cell boundaries, and greater cytological atypia. Nucleoli and mitoses are both prominent in carcinoma *in situ* (Figure 5).

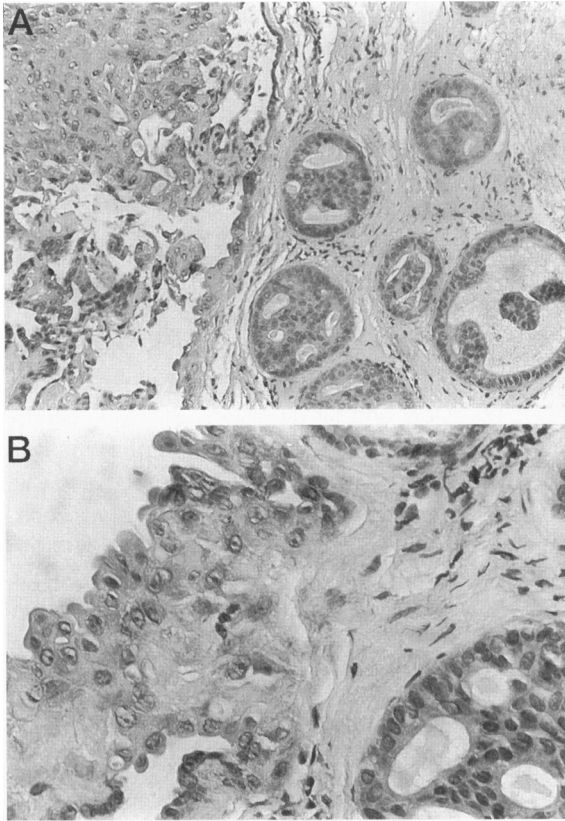
Progression from atypical hyperplasia and carcinoma *in situ* to invasive carcinoma was frequently observed and is illustrated in Figures 6 and 7. Like carcinomas in humans, the tumor can often be seen infiltrating among uninvolved ducts. However, a number of unusual histological types of cancers were found in our model. The carcinomas *in situ* are nearly all of the non-comedo type. Squamous cancer, mucin-secreting adenocarcinomas, and a pecu-



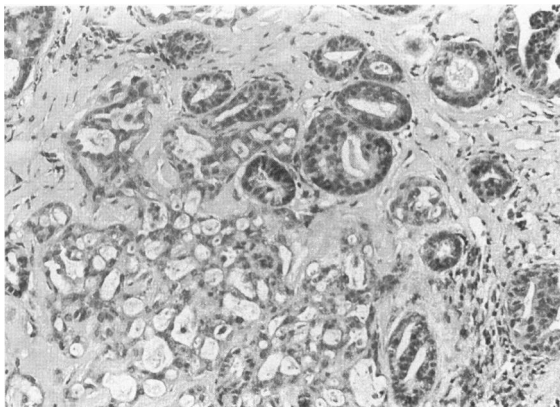
**Figure 4.** A grade 3 lesion in which the epithelial cells and nuclei are only mildly enlarged. The cribriform spaces are variable in size and shape, and the epithelial cells surrounding them are elongated and stream around them. This lesion was removed from a nude/beige mouse 490 days after injecting MCF10AT3B cells. (H&E, original magnification  $\times 400$ ).



**Figure 5.** A grade 4 lesion in which an extended duct is filled with rather uniform cells with relatively abundant cytoplasm and sharp cell boundaries. Although not completely round, many of the spaces have a somewhat rigid appearance. This lesion was removed from a nude/beige mouse 116 days after injecting MCF10AT3B cells. (H&E, original magnification  $\times 400$ ).



**Figure 6.** This lesion was removed from a nude/beige mouse 196 days after injecting MCF10AT3B cells. (A) An area of large cell carcinoma occupying a dilated ductal space. Note the change in the ductal lining from benign to malignant. Adjacent to the carcinoma are several small cysts showing atypical hyperplasia bordering on carcinoma *in situ*. (H&E, original magnification  $\times 160$ ). (B) Higher magnification of edge of the intraductal carcinoma that is beginning to invade the stroma. Note adjacent benign epithelium and early focus of atypical intraductal hyperplasia (H&E, original magnification  $\times 400$ ).



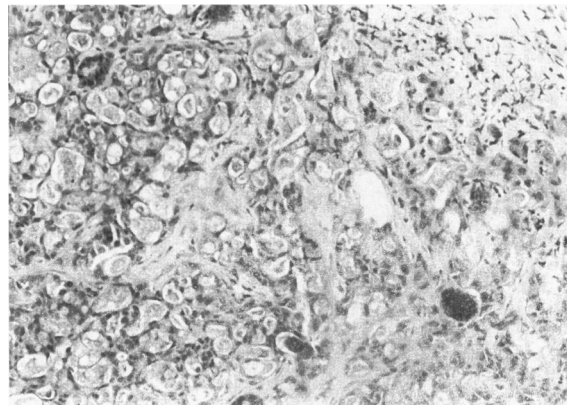
**Figure 7.** Mucin-secreting adenocarcinoma infiltrating among glands that show features of moderate hyperplasia (H&E, original magnification  $\times 160$ ). This lesion was removed from a nude/beige mouse 116 days after injecting MCF10AT3B cells.

liar type of tumor comprising areas of mucin-secreting adenocarcinoma with areas of squamous differentiation (Figure 8) are common in the model. We have not observed metastases.

The kinetics of progression with time is depicted for the fourth transplant generation in Figure 9. The sporadic nature of progression is clear; although cancer may be detected in relatively early lesions (day 72), lesions of more than 300 days may still consist of simple ducts. The results for four passages in nude/beige mice are summarized by Figure 10. Several points emerge. There was, with each succeeding passage, an increase in the percentage of mice developing proliferative lesions, although the number of carcinomas developing remained between 20 and 25%. The first passage was remarkable for the absence of atypical hyperplasia or carcinoma *in situ*. In subsequent passages, atypical hyperplasia was found in  $\sim 20\%$  of lesions. The comparatively infrequent observation of carcinoma *in situ* may be explained in part by our insistence on rigorous histological criteria for this diagnosis and the fact that our grading system was applied to the most advanced area so that foci of carcinoma *in situ* accompanied by invasive carcinoma were classified as the latter. The overall incidence of highly proliferative lesions (grade 3 and above) increased significantly ( $P = 0.0116$  by Fisher's exact test) from 23% for transplant generation 1 (5 of 23 for MCF10AT) to 56% for transplant generation 4 (33 of 59 for MCF10AT3B).

## Discussion

The significance of hyperplasia and atypical hyperplasia in relation to breast cancer relates to morphological contiguity of these lesions and to the relative risk to those patients in whom the lesions are present. The associated increased risk of the development of breast cancer in women with atypical hyperplasia has been



**Figure 8.** Invasive adenocarcinoma displaying an unusual histological pattern consisting of small irregular glands filled with mucin and small groups of polygonal cells with squamous features. This lesion was removed from a nude/beige mouse 72 days after injecting MCF10AT3B cells. (H&E, original magnification  $\times 160$ ).

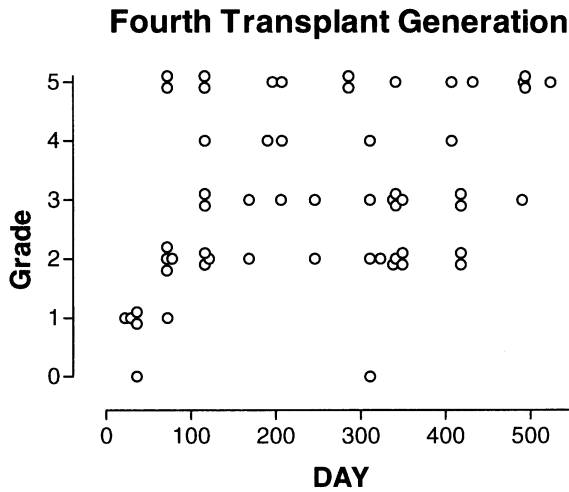


Figure 9. Kinetics of progression of MCF10AT3B in nude/beige mice is illustrated by plotting the grades of individual lesions removed from mice at the indicated days post implantation. Note the apparent random nature of progression.

established from numerous studies that have been reviewed and subjected to meta-analysis by Ma and Boyd.<sup>8</sup> This sequence is reproduced by our model, in which all stages are reproduced, although their incidence differs from that reported in humans. There are several important factors likely to be responsible for this variance. Environmental and hormonal influences are dissimilar. For example, the Ma and Boyd<sup>8</sup> analysis revealed a clear association with menopausal status. There is also an important selection factor in women who undergo breast biopsy. Selection is obviously influenced by the presence or absence of a mass, the patient's history and family history, and by mammographic findings. The latter rely heavily on the presence of calcification, particularly of the type associated with comedo intraductal carcinoma, a lesion significantly underrepresented in our model. Finally, although alteration or loss of *ras* may be associated with an aggres-

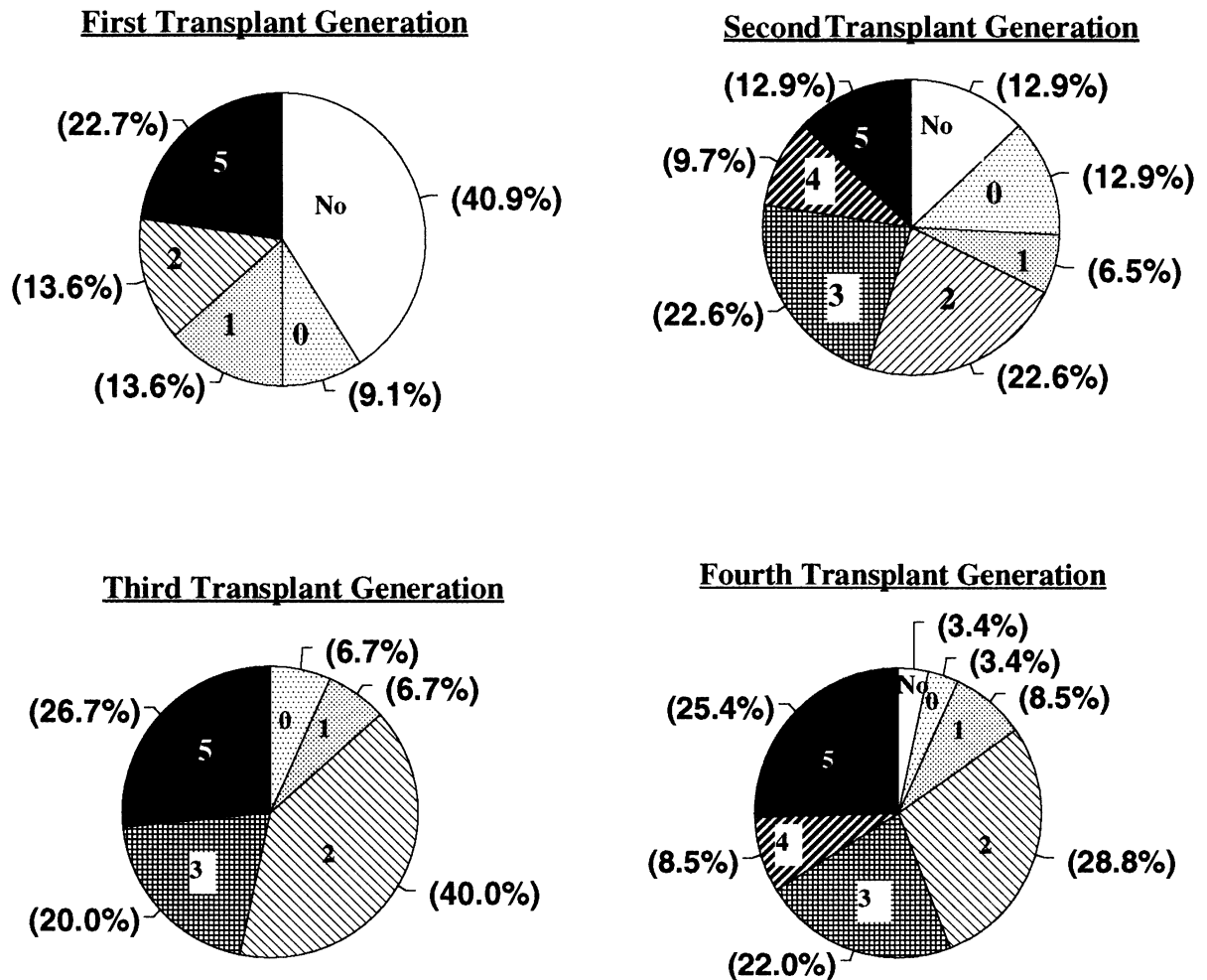


Figure 10. Distribution frequency of different grades of progression for each transplant generation. MCF10AT cells were injected to produce transplant generation 1 (22 xenografts analyzed); MCF10AT1 cells were injected to produce transplant generation 2 (31 xenografts analyzed); MCF10AT2B cells were injected to produce transplant generation 3 (15 xenografts analyzed); and MCF10AT3B cells were injected to produce transplant generation 4 (59 xenografts analyzed). Numbers in segments indicate grade of lesion (No: no persistent epithelial lesion detected).

sive phenotype<sup>9,10</sup> and overexpression of normal *ras* is common in human breast cancer,<sup>11</sup> it should be remembered that MCF10AT cells and lesions contain the activated *Ha-ras* oncogene, which is not highly characteristic of either female or male human breast carcinoma<sup>12</sup> (P. J. Dawson et al, unpublished observations). Thus, the unusual morphology observed in some of the tumors (squamous, mucin-secreting) may be the result of the activated *ras*.

In conclusion, we emphasize that our model is *not* a transplantable breast cancer line; rather, it is clear from the glandular histology of the premalignant lesions and from the variability of tumor morphology that the transplant is maintained by a multipotent cell. The stem cell nature of the cells is also evident in the simplest glandular architecture seen *in vivo*, which is composed of both epithelial and myoepithelial cells. Further, these cells, most probably subsequent to genetic alterations, are capable of reproducing the pathology of proliferative breast disease and ultimately progressing to cancer. Thus, the MCF10AT model provides a setting in which the steps in the conversion of the breast ductal epithelial cell to a malignant cell can be studied.

## References

1. Soule HD, Maloney TM, Wolman SR, Peterson WD, Brenz R, McGrath CM, Russo J, Pauley RJ, Jones RF, Brooks SC: Isolation and characterization of a spontaneously immortalized human breast epithelial cell line, MCF-10. *Cancer Res* 1990, 50:6075–6086
2. Miller FR, Soule HD, Tait L, Pauley RJ, Wolman SR, Dawson PJ, Heppner GH: Xenograft model of progressive human proliferative breast disease. *J Natl Cancer Inst* 1993, 85:1725–1732
3. Page DL, Dupont WD, Rogers LW, Rados MS: Atypical hyperplastic lesions of the breast: a long-term follow-up study. *Cancer* 1985, 55:2698–2708
4. Page DL, Anderson TJ: *Diagnostic Histopathology of the Breast*. Edinburgh, UK, Churchill Livingstone, 1987, pp 120–145
5. Tavassoli FA, Norris HJ: A comparison of the results of long-term follow-up for atypical intraductal hyperplasia and intraductal hyperplasia of the breast. *Cancer* 1990, 65:518–529
6. Basolo F, Elliott J, Tait L, Chen XQ, Maloney T, Russo IH, Pauley R, Momiki S, Caamano J, Klein-Szanto AJP, Koszalka M, Russo J: Transformation of human breast epithelial cells by *c-Ha-ras* oncogene. *Mol Carcinog* 1991, 4:25–35
7. Wolman SR, Mohamed AN, Heppner GH, Soule HD: Chromosomal markers of immortalization in human breast epithelium. *Genes Chromosomes & Cancer* 1994, 10:59–65
8. Ma L, Boyd NF: Atypical hyperplasia and breast cancer risk: a critique. *Cancer Causes & Control* 1992, 3:517–525
9. Theillet C, Lidereau R, Escot C, Hutzell P, Brunet M, Gest J, Schlom J, Callahan R: Loss of a *c-H-ras-1* allele and aggressive human primary breast carcinomas. *Cancer Res* 1986, 46:4776–4781
10. Garcia I, Dietrich P, Aapro M, Vauthier G, Vadas L, Engel E: Genetic alterations in human breast carcinomas. *Cancer Res* 1989, 49:6675–6679, 1989
11. Bos JL: The *ras* gene family, and human carcinogenesis. *Mutat Res* 1988, 195:255–268
12. Rochlitz CF, Scott GK, Dodson JM, Liu E, Dollbaum C, Smith HS, Benz CC: Incidence of activating *ras* oncogene mutations associated with primary metastatic human breast cancer. *Cancer Res* 1989, 49:357–360