

Short Communication

Kaposi's Sarcoma-Associated Herpesvirus in Non-AIDS-Related Lymphomas Occurring in Body Cavities

Ethel Cesarman,* Roland G. Nador,*
Katsuyuki Aozasa,† Georges Delsol,‡
Jonathan W. Said,§ and Daniel M. Knowles*

From the Department of Pathology, The New York Hospital-Cornell Medical Center, New York, New York; the Department of Pathology,† Osaka University, Osaka, Japan; the Laboratoire d'Anatomie et Cytologie Pathologiques,‡ Hôpitaux de Toulouse, Toulouse, France; and the Division of Anatomic Pathology,§ Department of Pathology and Laboratory Medicine, Cedars-Sinai Medical Center, Los Angeles, California*

DNA sequences belonging to the recently discovered Kaposi's sarcoma-associated herpesvirus (KSHV), now provisionally designated human herpesvirus 8, have been previously identified in an uncommonly occurring subset of AIDS-related lymphomas, referred to as body-cavity-based lymphomas (BCBLs), which present as lymphomatous effusions. Pyothorax-associated lymphomas (PALs) are non-Hodgkin's lymphomas that arise in the pleural cavity after long-standing pleural inflammation resulting from therapeutic artificial pneumothorax or from tuberculous pleuritis. Although PALs present as solid tumor masses, they are otherwise similar to BCBLs in that they also are B cell lymphomas, usually exhibit immunoblastic morphology, and contain Epstein-Barr virus. We investigated whether KSHV sequences are present in 2 BCBLs in patients without AIDS and in 12 Japanese and 2 French PALs. The 2 BCBLs were positive for KSHV sequences, whereas all 14 PALs were KSHV negative. This finding strongly suggests that BCBLs and PALs are distinct clinicopathological entities and further strengthens the association between the presence of KSHV and an

effusion phenotype. Based on these findings, we propose replacing the term body-cavity-based lymphoma with the term primary effusion lymphoma, which describes these non-Hodgkin's lymphomas more accurately and avoids confusion with other lymphomas that may occur in the body cavities, such as the PALs. (Am J Pathol 1996, 149:53-57)

DNA fragments belonging to a previously unidentified human herpesvirus have been found in more than 90% of Kaposi's sarcoma (KS) lesions in patients with and without the acquired immunodeficiency syndrome (AIDS).¹⁻⁷ These KS-associated herpesvirus (KSHV) DNA sequences also have been identified in some non-Hodgkin's lymphomas.¹ Notably, most of the KSHV-containing lymphomas have been body-cavity-based lymphomas (BCBLs) occurring in human immunodeficiency virus (HIV)-positive individuals.^{8,9} Besides the presence of KSHV, these BCBLs possess certain unusual clinical, immunophenotypic, and molecular genetic characteristics that suggest they represent a distinct clinicopathological entity.¹⁰⁻¹² They grow exclusively or mainly in the pleural, pericardial, and peritoneal cavities as lymphomatous effusions, usually with no identifiable tumor mass, throughout their clinical course and frequently exhibit indeterminate immunophenotypes but B cell genotypes with clonal immunoglobulin gene rearrangements. Furthermore, unlike many AIDS-related B cell non-Hodgkin's lymphomas, AIDS-related BCBLs nearly always contain Epstein-

Accepted for publication February 29, 1996.

Address reprint requests to Dr. Ethel Cesarman, The New York Hospital-Cornell Medical Center, Department of Pathology, 525 East 68th Street, New York, NY 10021.

Table 1. *Clinical and Pathological Features of Non-AIDS-Related Lymphomas Occurring in Body Cavities*

Case	Category	Origin	Age (years)	Sex	Duration of pyothorax (years)	Histology	Immunophenotype	Viral sequences		Ref.
								EBV*	KSHV	
1	PAL	Japan	67	M	30	IB	B	+	-	17
2	PAL	Japan	57	M	Unknown	IB	Null	+	-	17
3	PAL	Japan	57	M	Unknown	IB	B	+	-	17
4	PAL	Japan	58	M	34	IB	B	+	-	17
5	PAL	Japan	65	M	44	IB	B	+	-	17
6	PAL	Japan	56	M	37	IB	Null	+	-	17
7	PAL	Japan	60	M	35	LC	B	+	-	17
8	PAL	Japan	68	M	41	LC	B	+	-	17
9	PAL	Japan	76	M	46	IB	B	+	-	17
10	PAL	Japan	57	M	33	IB	B	+	-	17
11-CL [†]	PAL	Japan	76	M	46	IB	B	+	-	
12-CL	PAL	Japan	57	M	40	IB	B	+	-	
13	PAL	France	59	M	Unknown	LC	B	+	-	
14-CL	PAL	France	68	M	31	LC	B	+	-	18
15	BCBL	USA	78	M	NA	IB	Null	-	+	19
16	BCBL	USA	85	M	NA	IB	B [‡]	+	+	22

CL, cell line; IB, diffuse large cell-immunoblastic; LC, diffuse large cell; NA, not applicable; +, positive; -, negative.

*The presence of EBV was determined by PCR, *in situ* hybridization for EBEB sequences, and/or LMP-1 antigen expression.

[†]Cell line derived from case 9.

[‡]Expression of surface immunoglobulin but no other B-cell-associated antigens.

Barr virus (EBV) and consistently lack *c-myc* gene rearrangements.^{8,10}

Other non-Hodgkin's lymphomas arise in the body cavities. These include rare cases of non-AIDS-related BCBLs and the so-called pyothorax-associated lymphomas (PALs).^{13,14} The PALs are rare neoplasms associated with long-standing pyothorax resulting from artificial pneumothorax for the treatment of pulmonary tuberculosis or tuberculous pleuritis. These lymphomas have been identified most often in Japan, with more than 50 cases reported in the literature, in comparison with a single series of 3 cases reported from a Western country, France.¹⁵ The reason for this geographic distribution remains unclear, although it has been suggested that artificial pneumothorax has been used more frequently as a therapeutic modality in Japan than in the West. Although PALs appear as a tumor mass in or near the pleura, rather than as a lymphomatous effusion, they are reminiscent of the BCBLs in that they are similarly EBV-containing high grade B cell tumors with immunoblastic morphology occurring in the pleural cavity.¹⁶ Because of these similarities, we decided to analyze cases of PAL, as well as BCBLs occurring in non-AIDS patients, for the presence of KSHV sequences.

Materials and Methods

Pathological Samples

Fourteen PALs, including ten paraffin-embedded tissue specimens from Japan,¹⁷ two cell lines from

Japan, one tissue specimen from France, and one cell line from France,¹⁸ were investigated. One of the cell lines from Japan (case 11), was obtained from case 9. Histological sections of the PALs were reviewed to confirm the diagnosis of malignant lymphoma. The clinical, histological, immunohistochemical, and EBV analysis of the Japanese PALs has been previously reported¹⁷ and includes polymerase chain reaction (PCR) for the EBV *BamHI-W* region and EBNA-2 as well as *in situ* hybridization for the *BamHI-W* fragment and immunostaining for LMP-1. The two previously unpublished Japanese cell lines were characterized using the same methods. The cases from France were immunophenotyped on both frozen and paraffin sections (case 14) or only on paraffin sections (case 13). The analysis of case 14 has been previously reported.¹⁸ Case 13 was found to be positive for CD20 (L26, Dako, Santa Barbara, CA) and negative for CD3 (polyclonal CD3, Dako). Two cases of BCBL in HIV-negative individuals were also analyzed for the presence of KSHV sequences. One of these BCBLs presented as a lymphomatous effusion in the pleural cavity (case 15), whereas the second case presented as an abdominal effusion (case 16). The clinical, morphological, immunophenotypic, and molecular features of both of these cases have been previously reported.²² Case 15 is the only KSHV-positive, EBV-negative BCBL we had identified to this date. The characteristics of all of these patients and the pathological features of the specimens studied are summarized in Table 1.

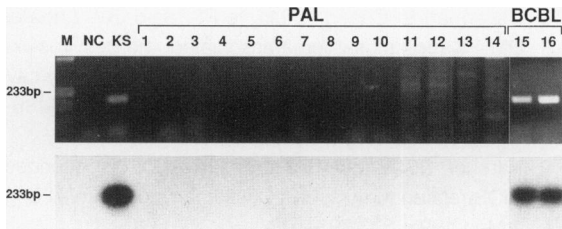


Figure 1. PCR amplification for KSHV DNA sequences in non-AIDS-related lymphomas occurring in body cavities. The upper panel shows the ethidium-bromide-stained agarose gel of the amplification products of DNA from a negative control (NC; HL60 cell line), a positive control (KS), PALs (PAL 1 through 14), and BCBLs (BCBL 15 and 16). A molecular weight marker (M) is in the first lane. A band of 233 bp indicating the presence of KSHV sequences is only identified in the positive control and in the two cases of BCBL. The lower panel shows specific hybridization of the PCR products to an internal oligonucleotide probe end-labeled with ^{32}P after transfer to nitrocellulose filters.

PCR and Hybridization Analysis

DNA was extracted from these tissues and tested by PCR for EBV using EBER primers and p53 exon 6 to confirm the integrity of the DNA and the lack of PCR inhibitors using previously reported primers and methods.^{20,21} The presence of KSHV sequences was examined by PCR using primers KS330₂₃₃F and KS330₂₃₃R, which amplify a 233-bp fragment as previously reported.¹

Results

Sixteen non-AIDS lymphomas presenting in body cavities were investigated. These included fourteen cases of PAL and two lymphomatous effusions from HIV-negative patients. The main features of these cases are summarized in Table 1. We found all of the cases, except one of the lymphomatous effusions, to be positive for EBV sequences. This was determined by PCR, *in situ* hybridization for EBER sequences, and/or LMP-1 antigen expression.^{17-19,22}

The search for the presence of KSHV sequences revealed that, whereas the 2 BCBL cases showed a distinct 233-bp band similar to the KS tissue used as a positive control, none of the 14 cases of PAL displayed an amplification product. This finding was confirmed by transfer and hybridization of the gels to a ^{32}P -end-labeled internal oligonucleotide probe (Figure 1). Ability of the DNA to amplify in all of the cases was confirmed by PCR for P53 (not shown) and EBV, previously reported for cases 1 to 10,¹⁷ and shown for cases 11 to 16 in Figure 2.

Discussion

We analyzed 16 malignant lymphomas presenting in body cavities in HIV-negative individuals for the

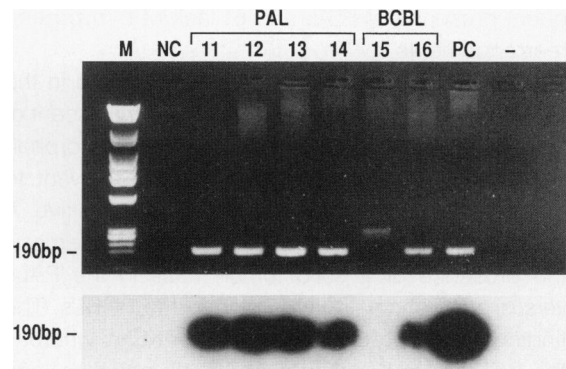


Figure 2. PCR amplification for EBV DNA sequences using EBER primers in representative cases of non-AIDS-related lymphomas occurring in body cavities. The upper panel shows the ethidium-bromide-stained agarose gel of the amplification products of DNA from a negative control (NC; HL60 cell line), PALs (PAL 11 through 14), and BCBLs (BCBL 15 and 16), a positive control (PC; UH-1 lymphoblastoid cell line), and the reaction carried out in the absence of DNA (-). A molecular weight marker (M) is in the first lane. A band of 190 bp indicating the presence of EBV sequences is identified in the positive control and in all of the PALs and one of the two BCBL cases. Case 15 has been previously shown to be negative for EBV DNA sequences by a variety of methods.¹⁹ The lower panel shows specific hybridization of the PCR products to an internal oligonucleotide probe end-labeled with ^{32}P after transfer to nitrocellulose filters.

presence of KSHV sequences. We found that all of those cases that were solid tumor masses, corresponding to the PALs, were negative for these sequences. In sharp contrast, the two cases presenting as lymphomatous effusions contained KSHV DNA sequences.

These sequences have been identified in a total of 18 AIDS-related BCBLs presenting as lymphomatous effusions.^{8,22-24} However, these sequences are not present in every lymphomatous effusion we have seen to date. For example, they are absent from those AIDS-related lymphomatous effusions that resemble Burkitt's and Burkitt's-like lymphomas morphologically and molecularly, ie, are composed of relatively small round cells with cytoplasmic vacuoles and have *c-myc* oncogene rearrangements.²² They also appear to be absent from lymphomatous effusions that are secondary to a contiguous tumor mass, eg, from cases of Burkitt's lymphoma or large cell lymphoma occurring in the mediastinum or peritoneal cavity having an accompanying effusion with neoplastic cells (unpublished observation). Thus, the presence of KSHV sequences seems to be confined to a very specific and distinct subset of tumors, in our experience characterized by 1) the presence of a lymphomatous effusion in the absence of a contiguous tumor mass, 2) high grade morphology with features bridging those of immunoblastic and anaplastic large cell lymphoma, 3) frequent indeterminate immunophenotype, 4) B cell genotype, 5) fre-

quent presence of EBV, and 6) lack of *c-myc* gene rearrangements.

As the PALs are B cell lymphomas based in the pleural cavity and have other features reminiscent of the AIDS-BCBLs, such as immunoblastic morphology and the presence of EBV, it was relevant to determine whether they were also KSHV positive. A major difference between these two neoplasms is the presence of a solid tumor mass in the PALs versus a lymphomatous effusion in the BCBLs. The finding that the PALs are negative for KSHV whereas the BCBLs are positive, even in HIV-negative individuals, strongly supports the notion that KSHV is related to the effusion phenotype in the BCBLs. Thus, the presence of KSHV among non-AIDS lymphoid neoplasms also remains confined to a highly specific subset of cases, ie, those primary lymphomatous effusions that we have referred to as BCBLs. Based on the findings presented here, we propose referring to these cases as primary effusion lymphomas rather than BCBLs, as this term describes these non-Hodgkin's lymphomas more accurately and avoids confusion with other lymphomas that may occur in the body cavities, such as the PALs.

References

1. Chang Y, Cesarman E, Pessin MS, Lee F, Culpepper J, Knowles DM, Moore PS: Identification of herpesvirus-like DNA sequences in AIDS-associated Kaposi's sarcoma. *Science* 1994, 266:1865-1869
2. Dupin N, Grandadam M, Calvez V, Gorin I, Aubin JT, Havard S, Lamy F, Leibowitch M, Huraux JM, Escande JP, Augut H: Herpesvirus-like DNA sequences in patients with Mediterranean Kaposi's sarcoma. *Lancet* 1995, 345:761-762
3. Moore PS, Chang Y: Detection of herpesvirus-like DNA sequences in Kaposi's sarcoma lesions from persons with and without HIV infection. *N Engl J Med* 1995, 332:1181-1185
4. Ambroziak JA, Blackburn DJ, Herndier BG, Glogau RG, Gullett JH, McDonald AR, Lennette ET, Levy JA: Herpes-like sequences in HIV-infected and uninfected Kaposi's sarcoma patients. *Science* 1995, 268:582-583
5. Boshoff C, Whitby D, Hatzionnou T, Fisher C, van der Walt J, Hatzakis A, Weiss R, Schulz T: Kaposi's sarcoma-associated herpesvirus in HIV-negative Kaposi's sarcoma. *Lancet* 1995, 345:1043-1044
6. Huang YQ, Li JJ, Kaplan MH, Poiesz B, Katabira E, Zhang WC, Feiner D, Friedman-Kien AE: Human herpesvirus-like nucleic acid in various forms of Kaposi's sarcoma. *Lancet* 1995, 345:759-761
7. Schalling M, Ekman M, Kaaya EE, Linde A, Biberfeld P: A role for a new herpes virus (KSHV) in different forms of Kaposi's sarcoma. *Nat Med* 1995, 1:707-708
8. Cesarman E, Chang Y, Moore PS, Said JW, Knowles DM: Kaposi's sarcoma-associated herpesvirus-like DNA sequences are present in AIDS-related body cavity based lymphomas. *N Engl J Med* 1995, 332:1186-1191
9. Karcher DS, Alkan S: Herpes-like DNA sequences, AIDS-related tumors, and Castleman's disease. *N Engl J Med* 1995, 333:797-798
10. Knowles DM, Inghirami G, Ubriaco A, Dalla-Favera R: Molecular genetic analysis of three AIDS-associated neoplasms of uncertain lineage demonstrates their B-cell derivation and the possible pathogenetic role of the Epstein-Barr virus. *Blood* 1989, 73:792-799
11. Walts AE, Shintaku IP, Said JW: Diagnosis of malignant lymphoma in effusions from patients with AIDS by gene rearrangement. *Am J Clin Pathol* 1990, 94:170-175
12. Green I, Espiritu E, Ladanyi M, Chaponda R, Wiecek R, Gallo L, Feiner H: Primary lymphomatous effusions in AIDS: a morphological, immunophenotypic, and molecular study. *Mod Pathol* 1995, 8:39-45
13. Iuchi K, Ichimiya A, Akashi A, Mizuta T, Lee YE, Tada H, Mori T, Sawamura K, Lee YS, Furuse K, Yamamoto S, Aozasa K: Non-Hodgkin's lymphoma of the pleural cavity developing from long-standing pyothorax. *Cancer* 1987, 60:1771-1775
14. Iuchi K, Aozasa K, Yamamoto S, Mori T, Tajima K, Minato K, Mukai K, Komatsu H, Tagaki T, Kobashi Y, Yamabe H, Shimoyama M: Non-Hodgkin's lymphoma of the pleural cavity developing from long-standing pyothorax: summary of clinical and pathological findings in thirty-seven cases. *Jpn J Clin Oncol* 1989, 19:249-257
15. Martin A, Capron F, Liguory-Brunaud M-D, De Frejacques C, Pluot M, Diebold J: Epstein-Barr virus-associated primary malignant lymphomas of the pleural cavity occurring in longstanding pleural chronic inflammation. *Hum Pathol* 1994, 25:1314-1318
16. Fukayama M, Ibuka T, Hayashi Y, Ooba T, Koike M, Mizutano S: Epstein-Barr virus in pyothorax-associated pleural lymphoma. *Am J Pathol* 1993, 143:1044-1049
17. Ohsawa M, Tomita Y, Kanno H, Iuchi K, Kawabata Y, Nakajima Y, Komatsu H, Mukai K, Shimoyama M, Aozasa K: Role of Epstein-Barr virus in pleural lymphomagenesis. *Mod Pathol* 1995, 8:848-853
18. al Saati T, Delecluze HJ, Chittal S, Brousset P, Magaud JP, Dastugue N, Cohen-Knafo E, Laurent G, Rubin B, Delsol G: A novel human lymphoma cell line (Deglis) with dual B/T phenotype and gene rearrangements and containing Epstein-Barr virus genomes. *Blood* 1992, 80:209-216
19. Nador RG, Cesarman E, Knowles DM, Said JW: Herpes-like DNA sequences in a body-cavity-based lymphoma in an HIV-negative patient. *N Engl J Med* 1995, 333:943
20. Frank D, Cesarman E, Liu YF, Michler RE, Knowles DM: Post-transplantation lymphoproliferative disorders frequently contain type A and not type B Epstein-Barr virus. *Blood* 1995, 85:1396-1403

21. Gaidano G, Ballerini P, Gong JZ, Inghirami G, Neri A, Newcomb EW, Magrath IT, Knowles DM, Dalla-Favera R: p53 mutations in human lymphoid malignancies: association with Burkitt lymphoma and chronic lymphocytic leukemia. *Proc Natl Acad Sci USA* 1991, 88:5423-5417
22. Nador RG, Cesarman E, Chadburn A, Dawson DB, Ansari MQ, Said J, Knowles DM: Primary effusion lymphoma: a distinct clinicopathologic entity associated with the Kaposi's sarcoma-associated herpesvirus. *Blood* (in press)
23. Karcher D, Dawkins F, Garret CT, Schulof RS: Body cavity-based non-Hodgkin's lymphoma (NHL) in HIV-infected patients: B-cell lymphoma with unusual clinical, immunophenotypic, and genotypic features. *Lab Invest* 1992, 66:80
24. Ansari MQ, Dawson DB, Nador RG, Rutherford C, Schneider NR, Latimer MJ, Picker L, Knowles DM, McKenna RW: Primary body-cavity-based AIDS-related lymphomas. *Am J Clin Pathol* 1996, 105:221-229