

Autoantibodies to Myeloperoxidase Aggravate Mild Anti-Glomerular-Basement-Membrane-Mediated Glomerular Injury in the Rat

Peter Heeringa,* Elisabeth Brouwer,*
Pieter A. Klok,[†] Minke G. Huitema,*
Jaap van den Born,[‡] Jan J. Weening,[§] and
Cees G. M. Kallenberg*

From the Departments of Clinical Immunology* and Pathology,[†] University Hospital Groningen, Groningen, the Department of Nephrology,[‡] Nijmegen, and the Department of Pathology,[§] Academic Medical Center, Amsterdam, The Netherlands

Autoantibodies to myeloperoxidase (MPO) are present in sera from patients with various forms of vasculitis-associated glomerulonephritis. Evidence for a pathogenic role of anti-MPO antibodies has been provided mainly by in vitro studies. We studied the pathogenic role of autoantibodies to MPO in a rat model of mild immune-mediated glomerular injury. Brown Norway rats were immunized with human MPO in complete Freund's adjuvant or with complete Freund's adjuvant alone. At 2 weeks after immunization, rats had developed antibodies to human and rat MPO as detected by indirect immunofluorescence, enzyme-linked immunosorbent assay, and immunoprecipitation. At this time point, rats were intravenously injected with a subnephritogenic dose of 150 µg of rabbit anti-rat GBM. Rats were sacrificed at 4 hours, 24 hours, 4 days, and 10 days after antibody administration. Control immunized rats developed mild glomerulonephritis characterized by slight proteinuria at day 10 (14.8 ± 8.1 mg/24 hours) and moderate intraglomerular accumulation of ED1⁺ macrophages. Crescent formation, tuft necrosis, and tubular atrophy were not observed in those rats. In contrast, rats immunized with MPO developed severe glomerulonephritis characterized by the early occurrence of severe hematuria, marked proteinuria at day 10 (76.2 ± 18.2 mg/24 hours), and massive glomerular deposition of fibrin. Complement and rat IgG were present in insuda-

tive lesions, but no linear pattern along the glomerular capillary wall was observed. By light microscopy, severe glomerular lesions were found at day 10 consisting of crescent formation and fibrinoid necrosis of capillary loops. In the interstitium, tubular necrosis and atrophy and marked interstitial mononuclear infiltration were found. In conclusion, autoantibodies to MPO severely aggravate subclinical anti-GBM disease demonstrating their in vivo pathogenic potential. (Am J Pathol 1996, 149:1695-1706)

Necrotizing crescentic glomerulonephritis (NCGN) associated with anti-neutrophil cytoplasmic antibodies (ANCA) is a rapidly progressive glomerular disease characterized by segmental fibrinoid necrosis of the glomerular capillary wall, marked infiltration of neutrophils and mononuclear cells, and paucity of IgG deposits.^{1,2} Autoantibodies in ANCA-associated NCGN are directed against either proteinase 3 or myeloperoxidase (MPO), both myeloid lysosomal enzymes.³⁻⁶ Interestingly, ANCA have also been detected in 30 to 40% of patients with anti-glomerular basement membrane (anti-GBM) disease.⁷⁻⁹ In some of these patients, clinical and pathological data suggest associated systemic vasculitis.⁷ The strong association between pauci-immune NCGN and ANCA suggests that ANCA play a pathogenic role in this disease. Evidence supporting this hypothesis has been provided mainly by *in vitro* studies. These studies have shown that ANCA can activate tumor-necrosis-factor- α -primed neutrophils leading to the production of reactive oxygen species and cytokines and the release of lysosomal enzymes.¹⁰⁻¹³ Furthermore, it has been demonstrated that ANCA can promote the adhesion of neutrophils

Supported by grant C91.1178 from the Dutch Kidney Foundation.

Accepted for publication July 15, 1996.

Address reprint requests to Dr. P. Heeringa, Department of Clinical Immunology, University Hospital Groningen, Hanzeplein 1, 9713 EZ Groningen, The Netherlands.

to monolayers of cultured endothelial cells and that primed neutrophils in the presence of ANCAs induce lysis of endothelial cells.¹⁴⁻¹⁷ So far, the *in vivo* relevance of these phenomena is not clear.

In a recent study, we hypothesized that NCGN may develop after focal degranulation and production of H₂O₂ by activated polymorphonuclear leukocytes (PMNs) in the presence of anti-MPO antibodies.¹⁸ This hypothesis was tested by perfusion of a human lysosomal enzyme extract and H₂O₂ into the kidney of Brown Norway rats previously immunized with human (h)MPO.¹⁹ These rats were found to develop a proliferative NCGN closely resembling human NCGN. The relevance of this animal model for human disease is, however, hampered by its use of heterologous MPO and the necessity to perfuse the kidneys. In the present study, we evaluated whether a MPO-directed autoimmune response in Brown Norway rats is able to aggravate subclinical anti-GBM disease. These studies would provide more evidence for the pathogenic potential of anti-MPO antibodies in this and perhaps other types of immune-mediated renal diseases.

Materials and Methods

Animals

All experiments were performed in conventionally housed, 3-month-old Brown Norway rats (Harlan, Bilthoven, The Netherlands). Animals were fed *ad libitum* with standard chow (Hope Farms, Woerden, The Netherlands).

Isolation of Human Myeloperoxidase

hMPO was isolated as described before.¹⁸ Briefly, isolated human PMNs were dissolved in cetylmethyl ammonium chloride (Sigma Chemical Co., St. Louis, MO) and sonicated. The extract was absorbed to a concanavalin A Sepharose gel (Pharmacia, Uppsala, Sweden) and eluted with methyl- α -mannoside (Sigma). The eluate was further purified on a Sephadex G100 gel (Pharmacia). The final hMPO preparation had an optical density (OD) 428/280 ratio of 0.85, measured as the ratio between the OD at 428 nm (showing a specific spectral band for MPO) and the OD obtained at 280 nm. The preparation was not contaminated with proteinase 3, elastase, or lactoferrin as estimated by antigen-specific enzyme-linked immunosorbent assay (ELISA), and analysis by gel electrophoresis showed specific bands for hMPO (at 15, 38, and 58 kd; data not shown).

Isolation of Rat Myeloperoxidase

Rat MPO was purified from peritoneal exudate cells (PECs). These PEC suspensions were obtained from the peritoneal cavity of Brown Norway rats 16 hours after an intraperitoneal injection of 7 ml of saline with 10% proteose peptone (Difco, Detroit, MI) and 0.8% heart infusion broth. Cell suspensions were harvested by washing the peritoneal cavity with phosphate-buffered saline (PBS) and contained more than 90% PMNs as judged by morphological criteria. Rat MPO was purified from the PEC suspension as described for hMPO.

Immunization

Brown Norway rats were immunized with hMPO in complete Freund's adjuvant supplemented with 5 mg/ml H37RA (Difco). Rats received 10 μ g of hMPO or control solution (sodium acetate buffer) without hMPO subcutaneously in 0.2 ml at two sites near the base of the tail.

Detection of Anti-Human MPO and Anti-Rat MPO Antibodies by ELISA

Microtiter plates (Greiner, Kremsmunster, Austria) were coated for 2 hours at 37°C with hMPO or rat MPO at a protein concentration of 2 μ g/ml in 0.1 mol/L carbonate buffer, pH 9.6. Plates were incubated with rat serum, diluted in 0.05 mol/L Tris/HCl, 0.05% Tween-20, 1% normal goat serum, 2% bovine serum albumin, and 0.3 mol/L NaCl, pH 8.0, starting at a dilution of 1:100 for hMPO and 1:25 for rat MPO. Antibody binding was detected with alkaline-phosphatase-labeled goat anti-rat Ig (Cappel Laboratories, West Chester, PA) followed by *p*-nitrophenyl phosphate disodium as a substrate. The plates were read at 405 nm, and a standard curve was prepared from a reference serum. Antibody titers were computed from the linearized titration curve of the reference serum. The antibody titer of the reference serum was set at 100 U.

Detection of Anti-Human MPO and Anti-Rat MPO Antibodies by Immunofluorescence

Antibodies to hMPO and rat MPO were detected by indirect immunofluorescence on ethanol-fixed human granulocytes or cytospin preparations of rat PECs. Rat plasma was diluted 1:10, and fluorescein isothiocyanate (FITC)-labeled rabbit anti-rat IgG (Cappel) was used to detect bound antibodies.

Detection of Anti-Rat MPO Antibodies by Immunoprecipitation

PECs were obtained as described above. A crude extract was prepared by nitrogen cavitation and ureum extraction in the presence of protease inhibitors. Nuclei and membrane fragments were discarded by centrifugation. The antigens were labeled with ^{125}I by the iodogen method and diluted in PBS containing 4% bovine serum albumin, 1% Triton X-100, 0.5% sodium dodecyl sulfate, and 0.5 mol/L NaCl (immunoprecipitation buffer). Antibody-bound antigen complexes were precipitated with protein A CL-4B (Pharmacia), 5 mg per plasma sample, washed with immunoprecipitation buffer, PBS, and 10 mmol/L Tris/HCl, pH 6.8, and centrifuged through a sucrose gradient. The samples were boiled for 1 minute in β -mercaptoethanol/SDS and run on a 12.5% SDS-polyacrylamide gel. After electrophoresis, gels were vacuum dried and exposed to a Kodak XAR5 film.

Induction of Anti-GBM Nephritis

Antiserum against rat GBM was raised in rabbits as follows. Rat glomeruli were purified from renal cortex tissue by a sieving technique.²⁰ Subsequently, GBMs were isolated from the glomeruli by the detergent method.²¹ Rabbits were immunized with 1 mg of rat GBM in complete Freund's adjuvant by multiple subcutaneous injections and boosted at 1-month intervals with 1 mg of rat GBM in incomplete Freund's adjuvant. Antibody titers were controlled by immunofluorescence. IgG was purified from serum by ammonium sulfate precipitation followed by protein A Sepharose affinity chromatography. At 2 weeks after immunization with hMPO, rats received a subnephritogenic dose of 150 μg of anti-GBM antibodies intravenously in 1 ml of PBS. Radiolabel experiments showed that equal amounts of rabbit IgG bound in the kidney of MPO-immunized and control immunized rats ($2.9 \pm 0.6 \mu\text{g/g}$ of kidney ($n = 3$) versus $3.0 \pm 0.4 \mu\text{g/g}$ of kidney ($n = 3$)). For estimation of proteinuria and hematuria, urine was collected in metabolic cages during 24 hours after the anti-GBM injection and before the day of sacrifice at 4 and 10 days. The protein content was measured with the biuret method. Hematuria was evaluated with the Sangur test (Boehringer Mannheim, Mannheim, Germany) and graded according to the following scale: 0, absent; 1, mild; 2, intermediate; 3, severe. When maximal hematuria was found, urine samples were diluted 10 times in physiological saline and tested again. The resultant score was then multiplied by 10.

Finally, a hematuria score was calculated for each experimental group at each time point by the sum of the individual scores of the rats divided by the number of rats.

Histopathology

At the times indicated, kidneys were perfused with PBS at 4°C to remove the blood. Tissue samples from the left and right kidney were obtained and prepared for light microscopy, immunofluorescence, and immunohistochemistry. For light microscopy, renal tissue was fixed in 2% paraformaldehyde/PBS and embedded in glycomethacrylate (Technovit 8100 solution, Kulzer, Wehrheim, Germany) as described.²² The 2- μm sections were cut and stained with periodic acid-Schiff and periodic acid silver methamine. The percentage of crescentic glomeruli was estimated by examination of 50 glomeruli on periodic acid-Schiff-stained plastic sections and counting the number of crescentic glomeruli. For immunofluorescence, tissue samples were snap frozen in isopentane. The 4- μm sections were fixed in acetone and then preincubated with normal serum from the same species as the conjugate. Detection of rabbit IgG, rat IgG, complement, and fibrin was tested by immunofluorescence using FITC-labeled F(ab)₂ goat anti-rabbit IgG, F(ab)₂ goat anti-rat IgG, FITC-labeled F(ab)₂ goat anti-rat C3, and goat anti-rat fibrinogen (all from Cappel). As a conjugate, FITC-labeled F(ab)₂ rabbit anti-goat was used (Cappel). The amount of rabbit IgG, rat IgG, and complement was scored on a semiquantitative scale as follows: 0, absent; 1, weak; 2, mild; 3, intermediate; 4, strong. Fibrin deposition was evaluated by scoring the extent of fibrin depositions in 50 glomeruli per rat according to the following scale: 0, absent; 1, less than 25%; 2, between 25 and 50%; 3, between 50 and 75%, and 4, between 75 and 100% of the total glomerular area. The fibrin score per rat was expressed as the sum of the individual glomerular scores.

PMNs, monocytes, and T cells were detected by an immunoperoxidase staining using the monoclonal antibodies His48 (PMNs²³), ED1 (monocytes; Serotec, Oxford, UK), and R73 (T cells²⁴), followed by peroxidase-labeled rabbit anti-mouse (Dakopatts, Glostrup, Denmark) and aminoethylcarbimazole as a substrate. Endogenous peroxidase activity was blocked with 0.05% H₂O₂ in PBS. Sections were counterstained with hematoxylin. Glomerular infiltrates were estimated by scoring the number of His48-, ED1-, and R73-positive cells within 50 glomeruli and dividing the total by 50. Interstitial infil-

trates were quantified on a semiquantitative scale: 0, absent; 1, minimal; 2, mild; 3, moderate; 4, severe.

Glomerular Presence of Rat MPO

The presence of rat MPO was studied on plastic-embedded sections for optimal morphological detail. Dried 2- μ m sections were fixed with acetone-buffered formalin (9%) according to Pryzwansky to prevent artifactual shifting of highly cationic MPO.^{25,26} To study the possible extracellular localization of rat MPO we applied double-labeling immunofluorescence using CD11b as a leukocyte marker. For this purpose, sections were preincubated with 10% goat serum, followed by a mixture of mouse anti-rat CD11b (OX 42) and biotinylated rabbit anti-rat MPO for 2 hours at 37°C. This was followed by incubation with a mixture of tetraethylrhodamine-isothiocyanate-labeled goat anti-mouse IgG (Southern Biotechnology Associates, Birmingham, AL) and FITC-labeled streptavidin (Dakopatts) supplemented with 1% normal rat serum. Sections were mounted in Citifluor (Fenwall Laboratories, London, UK). Controls included the omission of biotinylated rabbit anti-rat MPO or OX 42 or both and incubating biotinylated rabbit anti-rat MPO or OX 42 with the second step used for the other antibody in the double staining.

Statistical Analysis

Values were expressed as mean \pm SD and were analyzed for statistical differences by the two-tailed Mann-Whitney *U* test. Probability values of <0.05 were considered significant.

Experimental Design

Two experimental groups were formed. In the first group, hMPO-immunized rats received an injection of a subnephritogenic dose of rabbit anti-rat GBM. Rats were sacrificed at 4 hours ($n = 3$), 24 hours ($n = 4$), 4 days ($n = 5$), and 10 days ($n = 5$). In the second group, control immunized rats received an injection of a subnephritogenic dose of rabbit anti-rat GBM. Rats were sacrificed at 4 hours ($n = 4$), 24 hours ($n = 5$), 4 days ($n = 4$), and 10 days ($n = 4$).

Results

Immune Response to Human and Rat MPO

Brown Norway rats immunized with hMPO developed antibodies reacting with human and rat MPO as detected by indirect immunofluorescence (Figure

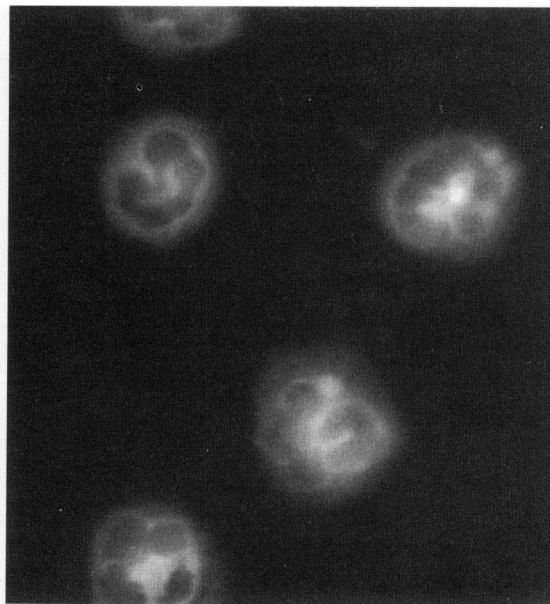


Figure 1. Indirect immunofluorescence on ethanol-fixed rat PMNs with sera from Brown Norway rats immunized with human MPO. Magnification, $\times 450$.

1) and ELISA (Figure 2). The antibodies specifically precipitated rat MPO from a crude extract prepared from rat PECs (Figure 3). The same bands were precipitated by a polyclonal antibody raised against purified rat MPO that, in addition, recognizes smaller MPO fragments. Sera from control immunized rats were negative in all tests.

Urine Analysis

Control immunized rats receiving rabbit anti-GBM antibodies developed moderate hematuria 10 days after injection (Figure 4). At earlier time points, only intermediate hematuria was found in some rats, the majority being negative. In contrast, intermediate to severe hematuria developed in hMPO-immunized animals starting at 24 hours after the anti-GBM antibody administration. Hematuria increased in severity during the time period of the experiment (Figure 4). Urine samples from rats at day 10 still showed maximal hematuria after 10-fold dilution in physiological saline, illustrating the extent of hematuria. In addition, low-grade proteinuria was detectable 4 days after anti-GBM antibody administration in both groups and had increased at day 10 with a significantly higher degree of proteinuria in hMPO-immunized rats as compared with control rats (76.2 ± 18.2 mg/24 hours *versus* 14.8 ± 8.1 mg/24 hours; Figure 5).

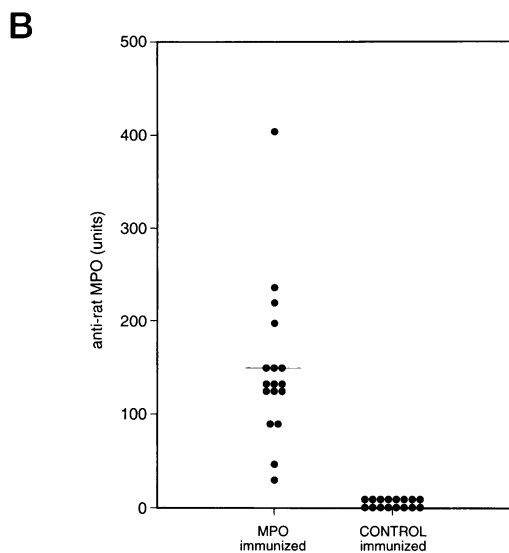
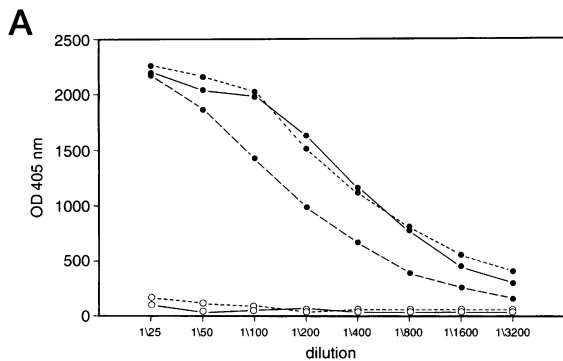


Figure 2. Reactivity of sera from human MPO or control immunized Brown Norway rats with purified rat MPO as detected by ELISA. **A:** Dilution curves of hMPO-immunized rats or control immunized rats. **B:** Anti-rat MPO titers expressed in arbitrary units relative to a reference serum.

Histopathology

Macroscopic Appearance of Kidneys

The macroscopic appearance of kidneys from control immunized rats showed no abnormalities except for occasional petechiae 10 days after the administration of anti-GBM antibodies (Figure 6). However, kidneys from hMPO-immunized animals showed some petechiae at 4 hours and widespread petechiae at 24 hours and 4 and 10 days. In addition, kidneys at 10 days were swollen and had a pale appearance (Figure 6).

Light Microscopy

In hMPO-immunized rats, a moderate influx of PMNs was found at 4 hours. At 24 hours, a local influx of PMNs and monocytes was observed in the glomeruli of hMPO-immunized rats. In addition, in some glo-

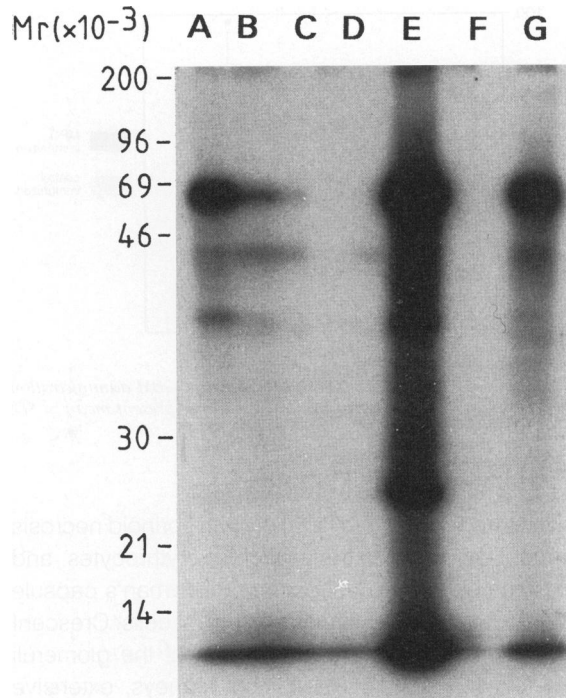


Figure 3. Immunoprecipitation studies with a crude extract from rat PEC cells. Brown Norway rats with hMPO precipitated the characteristic MPO bands at 58 and 38 kd (lanes A, B, and G). Control immunized rats did not precipitate any proteins (lanes C and D). A polyclonal rabbit anti-rat MPO also precipitated the 58- and 38-kd band but, in addition, also recognized smaller bands (lane E). Normal rabbit serum did not precipitate any proteins (lane F).

meruli capillaries showed thrombosis with hemostasis and swelling of endothelial cells (Figure 7A). These changes were less conspicuous in the control immunized rats. At 4 days, the rats from the hMPO-immunized group showed increased numbers of intracapillary cells, mostly macrophages with endothelial and mesangial proliferation and segmental proliferation of epithelial cells in Bowman's space. At 10 days, the hMPO-immunized rats showed exten-

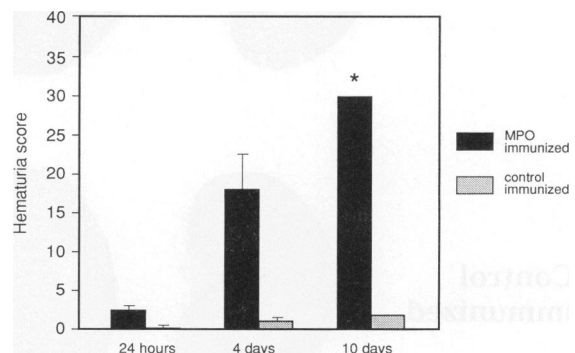


Figure 4. Occurrence and severity of hematuria after anti-GBM administration in control and hMPO-immunized rats. Results represent the mean hematuria score at each time point. *Urine samples from hMPO-immunized rats at day 10 after anti-GBM administration diluted 10 times in physiological saline still showed maximal hematuria.

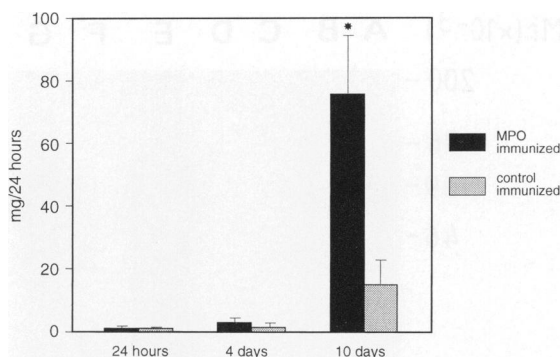


Figure 5. Development of proteinuria after anti-GBM administration in control and hMPO-immunized rats. Results represent mean \pm SD. * $P < 0.02$.

sive extracapillary proliferation with fibrinoid necrosis of capillary walls, extravasation of erythrocytes, and in some glomeruli destruction of Bowman's capsule with formation of multinucleated giant cells. Crescent formation was found in 24 to 60% of the glomeruli (mean, 41.2%; $n = 5$). In most kidneys, extensive interstitial inflammatory changes were observed at this time (Figure 7, D–F). At 10 days after anti-GBM IgG administration, the kidneys of control immunized rats showed only mild intracapillary proliferation as shown in Figure 7B. Severe lesions, such as the development of crescents, the occurrence of interstitial infiltrates and tubular atrophy, and necrosis were not observed.

Immunophenotyping

Phenotypic analysis of intraglomerular inflammatory cells in control immunized rats showed a slight influx of PMNs (1.3 ± 0.3 per glomerulus) at 4 hours after anti-GBM administration (see Table 2). At later time points, the predominant infiltrating cells were ED1⁺ macrophages, which peaked at day 4. No intraglomerular T cells were found at any time (Table 1). In addition, interstitial macrophages were only occasionally found at day 10 (Table 1). Rats immunized with hMPO also showed an influx of PMNs (1.9 ± 0.4 per glomerulus) at 4 hours and ED1⁺ macrophages at 24 hours and 4 and 10 days after anti-GBM administration (Table 1). The total number of infiltrating inflammatory cells was generally higher compared with control immunized rats. Occasionally, some T cells were observed at day 10 (Table 1). In addition, at 10 days, large numbers of inflammatory cells accumulated in the interstitium mainly consisting of ED1⁺ macrophages (Table 1).

Immunofluorescence

Immunofluorescence studies showed strong linear deposition of rabbit IgG along the glomerular capillary wall at all time points in both experimental groups (Figure 8 and Table 2). Complement C3 was only weakly present whereas no linear deposition of rat IgG was found along the capillary walls of either

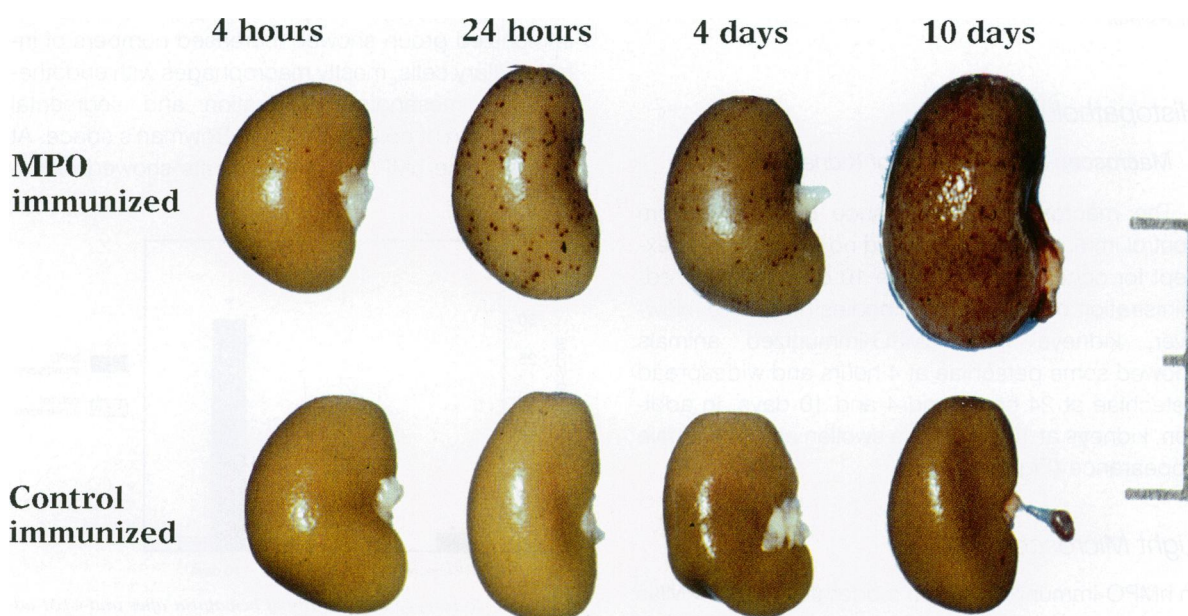


Figure 6. Macroscopic appearance of kidneys from control or hMPO-immunized Brown Norway rats 4 hours, 24 hours, 4 days, and 10 days after administration of a subnephritogenic dose of anti-GBM antibodies. Widespread petechiae are seen in kidneys from hMPO-immunized rats at 24 hours and 4 and 10 days. In addition, kidneys at 10 days after anti-GBM administration appear swollen. Bar, 2 cm.

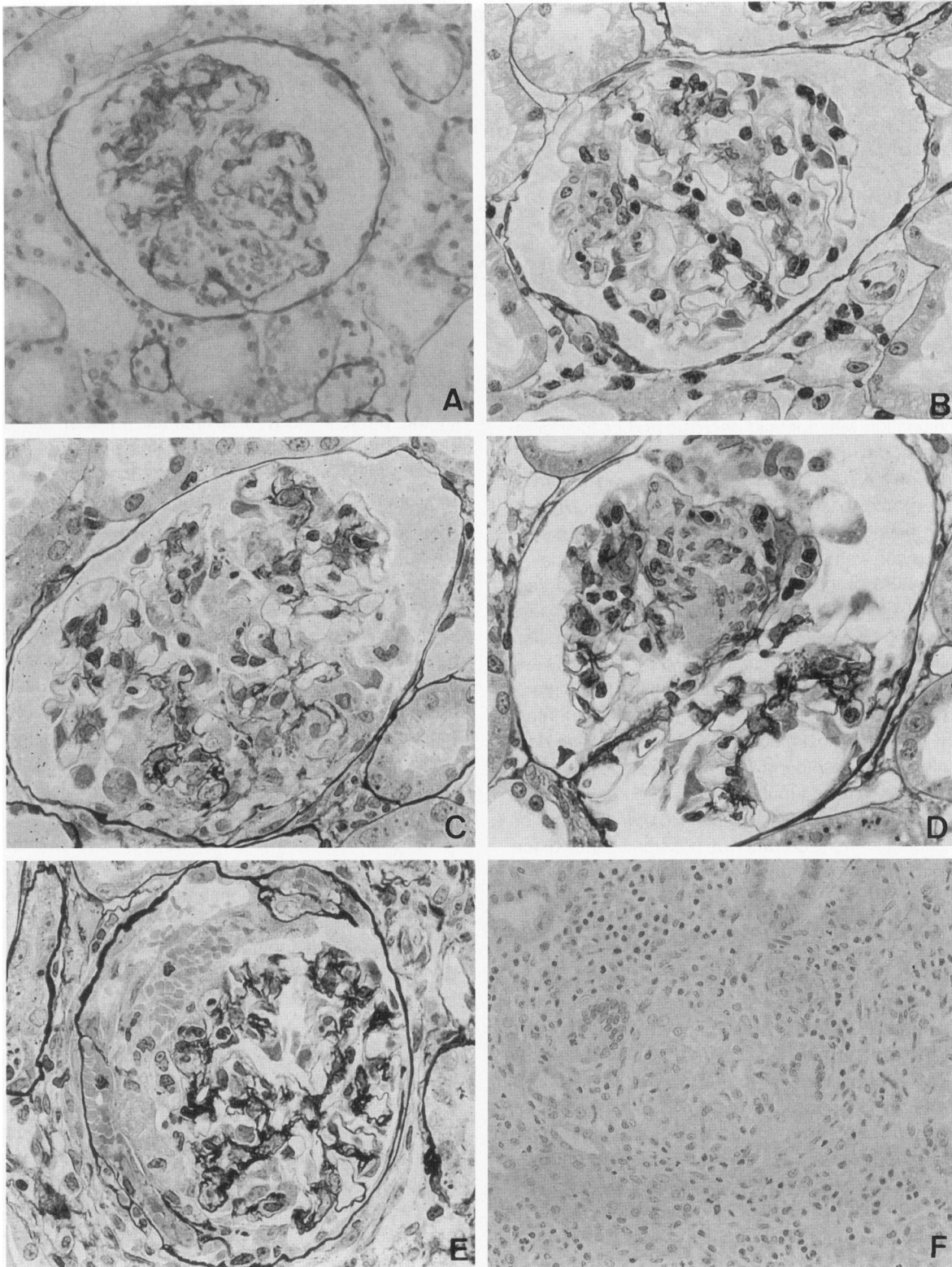


Figure 7. Light microscopy. **A:** Light micrograph showing a glomerulus at 24 hours after injection of anti-GBM IgG in a MPO-immunized rat showing deposition of fibrin and stasis of erythrocytes. Methenamine silver, magnification, $\times 250$. **B:** Light micrograph showing a glomerulus at 10 days after injection of anti-GBM IgG in a control immunized rat. Local intracapillary accumulation of macrophages is observed. Methenamine silver, $\times 360$. **C to F:** Light micrographs showing glomeruli at 10 days after injection of anti-GBM IgG in MPO-immunized rats. Intra- and extracapillary proliferation, crescent formation, extravasation of erythrocytes into Bowman's space, multinucleated giant cells, and extensive interstitial inflammation can be seen. Methenamine silver (**C to E**) and periodic acid-Schiff (**F**); magnification, $\times 360$.

Table 1. *Intraglomerular and Interstitial Presence of Macrophages, PMNs, and T Cells*

Infiltrating cells	Groups	Intraglomerular cells				Interstitial cells			
		4 hours	24 hours	4 days	10 days	4 hours	24 hours	4 days	10 days
PMNs	I	1.9 ± 0.4	1.4 ± 0.4	0.78 ± 0.1	1.2 ± 0.2	0	0	0.8 ± 0.4	2.2 ± 0.4
	II	1.3 ± 0.3	1.0 ± 0.3	0.72 ± 0.3	0.7 ± 0.1	0	0	0	0.3 ± 0.2
Monocytes	I	1.1 ± 0.1	2.7 ± 0.7	7.0 ± 1.6	6.9 ± 1.5*	0	0	1.4 ± 0.2	3.2 ± 0.2
	II	0.7 ± 0.1	2.5 ± 1.3	6.0 ± 2.7	3.7 ± 0.5	0	0	0.3 ± 0.3	0.5 ± 0.3
T cells	I	0	0	0	0.2 ± 0.1	0	0	0	0.5 ± 0.3
	II	0	0	0	0	0	0	0	0

In group I, rats were immunized with hMPO. In group II were control immunized rats. The number of intraglomerular PMNs, monocytes, and T cells was estimated by counting positive cells in 50 glomeruli and dividing the total by 50. Numbers represent mean ± SD. Labeled interstitial cells were scored on a semiquantitative scale: 0, absent; 1, minimal; 2, mild; 3, moderate; 4, severe. Results represent mean scores ± SEM.

**P* < 0.05.

group at any time (Figure 8). However, complement and rat IgG were detected in Bowman's space in conjunction with fibrinoid necrosis and cellular crescents at day 10 in hMPO-immunized rats (Figure 8). Until day 4, deposition of fibrin showed a similar pattern and extent in both groups. No deposition of fibrin was found at 4 hours whereas weak diffuse deposition was seen at 24 hours (Figure 9). At day 4, 30 to 50% of the glomeruli showed focal and segmental glomerular deposition of fibrin. At 10 days after anti-GBM administration, a significant difference in glomerular fibrin score was found between both experimental groups (Figure 9). In hMPO-immunized rats, fibrin deposition had increased in intensity, involving most glomeruli. At this time, fibrin deposition was also found in Bowman's space, within crescents, and in tubular lumens (Figures 8 and 9). In contrast, the pattern and extent of fibrin deposition in control immunized rats was not significantly different from that found at day 4 (Figure 9).

Glomerular Presence of Rat MPO

Staining for rat MPO showed strong intracellular staining of infiltrating leukocytes at 4 and 24 hours after anti-GBM administration in both groups (Figure 10A). In addition, extracellular granular staining of rat MPO was observed (Figure 10, B and C), although not all rat-MPO-positive cells were accompanied by extracellular staining. No apparent difference in the amount of extracellular staining was noted between hMPO-immunized and control immunized rats. At 4 and 10 days after anti-GBM administration, only weak staining for rat MPO was found in both groups.

Discussion

In the present study, rats immunized with hMPO developed antibodies to hMPO that cross-reacted with rat MPO. When, subsequently, these rats were challenged with a subnephritogenic dose of rabbit anti-rat GBM antibodies, severe glomerulonephritis developed. Clinically, the glomerulonephritis was characterized by the early onset of severe hematuria and exacerbation of proteinuria while histopathologically crescent formation, tuft necrosis, and tubulointerstitial nephritis were observed. In contrast, control immunized rats receiving the same amount of rabbit anti-rat GBM antibodies showed only mild glomerulonephritis. These results demonstrate a pathogenic role of the anti-rat MPO autoantibodies in the development of crescentic glomerulonephritis in this experimental model.

Several other *in vivo* observations have pointed toward a pathogenic role for ANCAs. Anti-MPO antibodies have been demonstrated in sera from mercury-chloride-treated Brown Norway rats and in a mouse strain with spontaneous NCGN developed by genetic selection from lupus prone MRL mice.²⁶⁻³⁰ Interestingly, in both models, vasculitis has been observed. However, the immune response to MPO is part of a polyclonal B-cell stimulation in both models, which makes the specific pathophysiological role of anti-MPO antibodies in the induction of vasculitis difficult to interpret. The studies presented here are based on the hypothesis that focal neutrophil activation by circulating autoantibodies to MPO leads to the development of anti-MPO-associated crescentic glomerulonephritis. As has been reported previ-

Figure 8. *Localization of rabbit IgG, rat IgG, complement, and fibrin by immunofluorescence. A and B: Linear staining along the glomerular capillary wall of rabbit IgG 24 hours after anti-GBM administration in control (A) and hMPO-immunized (B) rats. C: Absence of linear deposition of rat IgG in glomeruli from a hMPO-immunized rat 10 days after anti-GBM administration. D: Strong staining of complement along Bowman's capsule in a hMPO-immunized rat 10 days after anti-GBM administration. E: Moderate fibrin deposition in glomeruli from a control immunized rat 10 days after anti-GBM administration. F: Massive glomerular fibrin deposition in a hMPO-immunized rat 10 days after anti-GBM administration. Magnification, ×250 (A and B) and ×360 (C to F).*

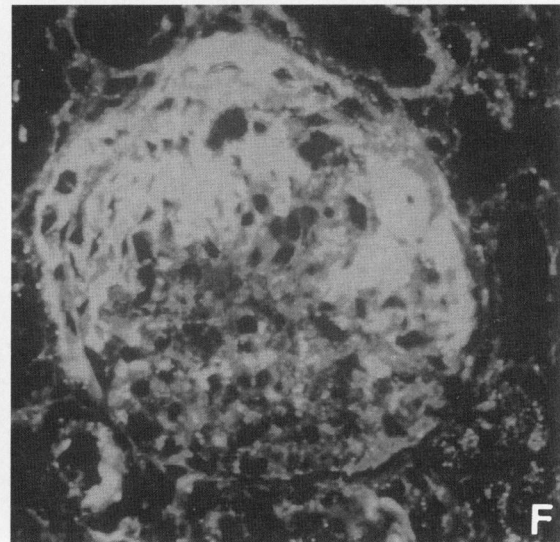
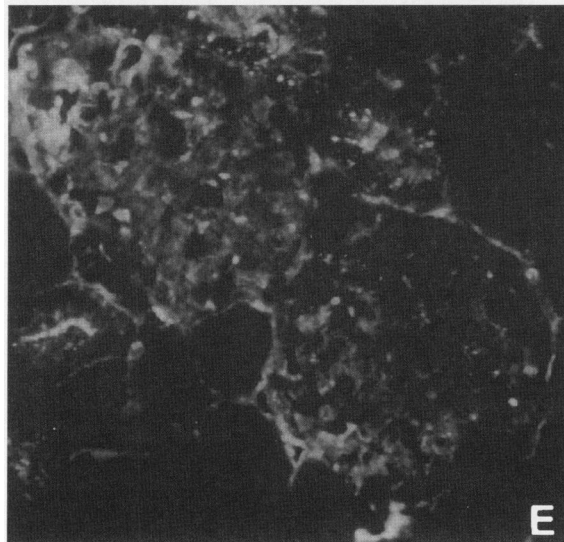
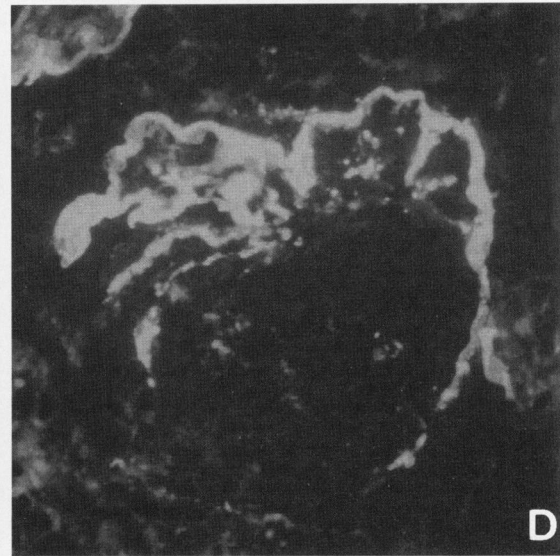
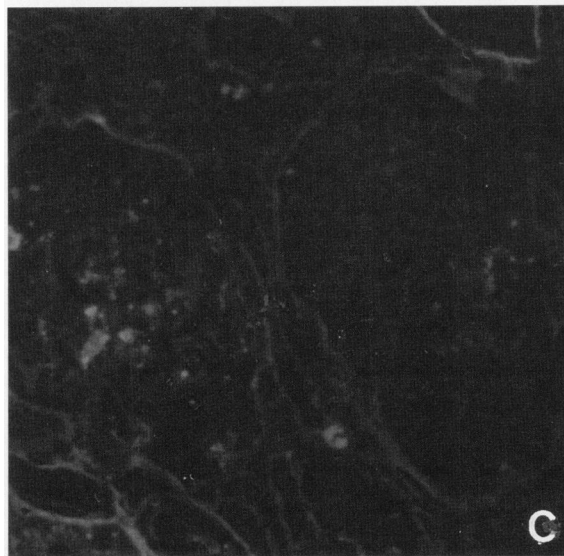
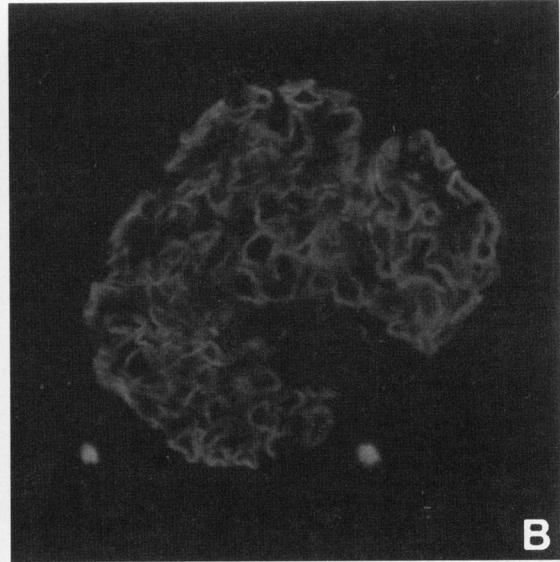
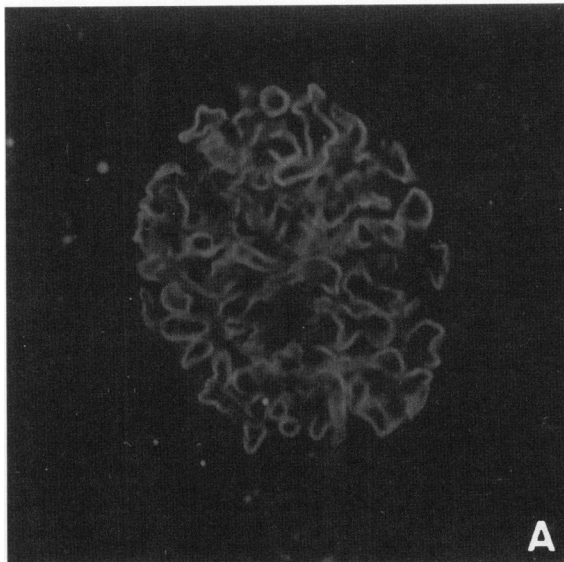


Table 2. *Intraglomerular Presence of Rabbit IgG, rat IgG, and Complement*

Groups	Rabbit IgG				Rat IgG				Complement			
	4 hours	24 hours	4 days	10 days	4 hours	24 hours	4 days	10 days	4 hours	24 hours	4 days	10 days
I	4	4	4	3.6 ± 0.2	0	0	1.6 ± 0.4	1.8 ± 0.4	0.5 ± 0.3	0.5 ± 0.3	1.6 ± 0.2	2.4 ± 0.3
II	4	4	4	4	0	0	1.5 ± 0.3	1.3 ± 0.3	0.3 ± 0.3	0.5 ± 0.3	1.0 ± 0.5	1.5 ± 0.3

In group I, rats were immunized with hMPO. In group II were control immunized rats. The presence of rabbit IgG, rat IgG, and complement was scored on a semiquantitative scale: 0, absent; 1, weak; 2, mild; 3, intermediate; 4, strong. Results represent mean scores ± SEM.

ously, the development of anti-MPO antibodies after immunization is in itself not sufficient to induce any lesions.^{18,31} In addition, *in vitro* studies have shown that ANCA stimulate human PMNs to produce reactive oxygen metabolites and enhance degranulation only after cytokine priming of PMNs.¹⁰ In our model, the induction of a mild anti-GBM nephritis possibly served as the priming process. Administration of a subnephritogenic dose of anti-GBM results in a mild PMN influx and complement activation.³² In the presence of MPO autoantibodies, this may result in the development of severe NCGN. The exact mechanisms by which the autoantibodies to MPO aggravate mild anti-GBM nephritis are not clear, but several possibilities may be considered.

First, *in vitro* studies have shown that anti-GBM/GBM immune complexes as well as anti-MPO antibodies can induce MPO release from PMNs, and both mechanisms may be relevant in the model presented here.^{10,33} Indeed, rat MPO was found in an extracellular localization in glomerular capillary structures. MPO is a highly cationic enzyme that, upon exocytosis or degranulation, will bind to negatively charged structures such as the GBM or endothelial cells. Active MPO reacts with H₂O₂ and halides to form reactive oxygen metabolites that induce acute glomerular injury.³⁴⁻³⁶ Once MPO is released

from the cell, MPO/anti-MPO complexes may form, leading to prolonged presence of the active enzyme and more extensive morphological damage.

Second, the development of focal MPO/anti-MPO immune complexes may also enhance the influx of inflammatory cells resulting in an increased production of reactive oxygen radicals and release of pro-

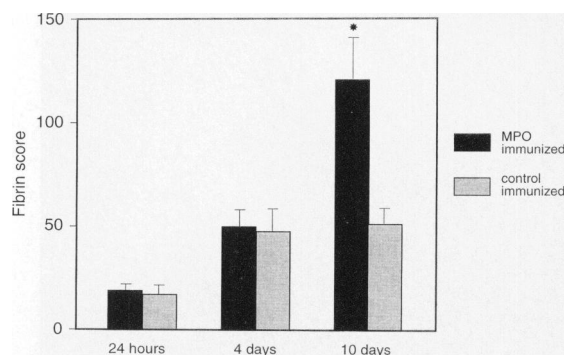


Figure 9. *Glomerular fibrin deposition at 24 hours and 4 and 10 days after anti-GBM administration in control and hMPO-immunized rats. Fibrin deposition was scored semiquantitatively according to the following scale: 0, absent; 1, less than 25%; 2, between 25 and 50%; 3, between 50 and 75%; and 4, between 75 and 100% of the total glomerular area. Results are expressed as mean score ± SD. *P < 0.02.*

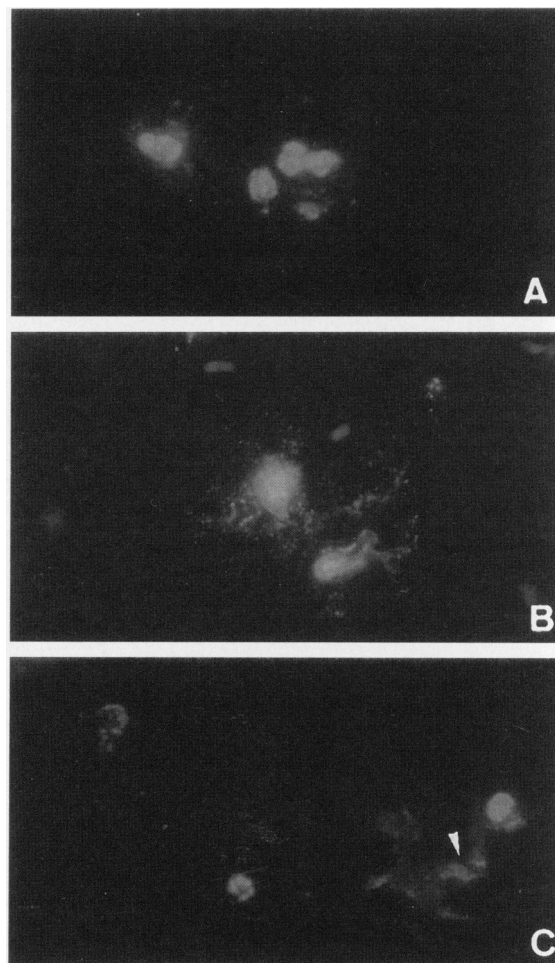


Figure 10. *Localization of rat MPO in glomeruli from hMPO-immunized rats 24 hours after anti-GBM administration by indirect immunofluorescence. A: Intracellular localization of rat MPO. B: Intracellular staining accompanied by extracellular granular staining of rat MPO. C: Extracellular staining of rat MPO (arrow). Magnification, ×360.*

teolytic enzymes. However, it should be stressed that we found no abnormal quantities of rat IgG in the glomeruli. The role of focal immune complex formation in anti-MPO-associated NCGN was also tested by Brouwer et al.¹⁸ They developed an animal model in which a human neutrophil lysosomal extract consisting of MPO and trace amounts of proteinase 3 and elastase and H₂O₂ were perfused into the kidney of Brown Norway rats previously immunized with hMPO. These rats developed a NCGN characterized by intra- and extracapillary proliferation, ruptured Bowman's capsule, periglomerular granulomatous inflammation, and formation of giant cells while IgG and C3 were scanty or absent. This model therefore closely resembles the human disease of ANCA-associated NCGN, although some controversy exists on the pauci-immune character of this model.³¹ In line with these observations are the data of Kobayashi et al,³⁷ who described exacerbation of anti-GBM disease in the rat by heterologous anti-rat MPO antibodies. They showed that the administration of rabbit anti-rat MPO together with anti-GBM antibodies increases fibrin accumulation and the number of infiltrating PMNs 3 and 15 hours after injection, although neither crescent formation or tuft necrosis was seen. In addition, deposition of rat MPO along the GBM was found, and anti-MPO antibodies could be eluted from the kidney. These results suggest that focal MPO/anti-MPO immune complex formation is responsible for the aggravation of the anti-GBM nephritis. However, this model is based on heterologous anti-MPO antibodies and therefore cannot be regarded as a genuine autoimmune model for ANCA-associated glomerulonephritis.

Third, recent studies have shown that anti-MPO antibodies enhance cytokine production by PMNs.^{13,38} Cytokines, like tumor necrosis factor- α and interleukin-1, aggravate mild anti-GBM nephritis when administered systemically.^{38,39} In addition, it was shown that, in patients with active Wegener's disease as well as in sepsis patients, monocytes express MPO on their cell surface, and it has been reported that ANCAs induce monocyte chemoattractant protein-1 production by monocytes.^{40,41} Therefore, increased cytokine production by monocytes and PMNs due to interaction with anti-MPO antibodies could be an alternative mechanism in our model and should be studied further.

In conclusion, these studies demonstrate that autoantibodies to MPO markedly aggravate mild anti-GBM disease and suggest that ANCAs may be a pathogenic factor in rendering mild glomerular injury into clinically overt disease.

References

1. Beirne GJ, Wagnild JP, Zimmerman SW, Macken PD, Burkholder PM: Idiopathic crescentic glomerulonephritis. *Medicine* 1977, 76:349-381
2. Couser WG: Rapidly progressive glomerulonephritis: classification, pathogenetic mechanisms, and therapy. *Am J Kidney Dis* 1988, 11:449-464
3. Falk RJ, Jennette JC: Anti-neutrophil cytoplasmic autoantibodies with specificity for myeloperoxidase in patients with systemic vasculitis and idiopathic necrotizing and crescentic glomerulonephritis. *N Engl J Med* 1988, 318:1651-1657
4. Goldschmeding R, van der Schoot CE, ten Bokkel-Huinink D, Hack CE, van den Ende CE, Kallenberg CGM, von dem Borne AEGK: Wegener's granulomatosis autoantibodies identify a novel diisopropylfluorophosphate-binding protein in the lysosomes of normal human neutrophils. *J Clin Invest* 1989, 84:1577-1587
5. Niles JL, McCluskey RT, Ahmad MF, Arnaot MA: Wegener's autoantigen is a novel neutrophil serine protease. *Blood* 1989, 74:1888-1893
6. Cohen Tervaert JW, Goldschmeding R, Elema JD, van der Giessen M, Huitema MG, van der Hem GK, The TH, von dem Borne AEGK, Kallenberg CGM: Autoantibodies against myeloid lysosomal enzymes in crescentic glomerulonephritis. *Kidney Int* 1990, 37:799-806
7. Jayne DW, Marshall PD, Jones SJ, Lockwood CM: Autoantibodies to GBM and neutrophil cytoplasm in rapidly progressive glomerulonephritis. *Kidney Int* 1990, 37:965-970
8. O'Donoghue DJ, Short CD, Brenchley PEC, Lawler W, Balardie FW: Sequential development of systemic vasculitis with anti-neutrophil cytoplasmic antibodies complicating anti-glomerular basement membrane disease. *Clin Nephrol* 1989, 32:251-255
9. Bosch X, Mirapeix E, Font J, Borrelas X, Rodriguez R, Lopesoto A, Ingelmo M, Revert L: Prognostic implication of anti-neutrophil cytoplasmic autoantibodies with myeloperoxidase specificity in anti-glomerular basement membrane disease. *Clin Nephrol* 1991, 36:107-113
10. Falk RJ, Terrell RS, Charles LA, Jennette JC: Anti-neutrophil cytoplasmic autoantibodies induce neutrophils to degranulate and produce oxygen radicals *in vitro*. *Proc Natl Acad Sci USA* 1990, 87:4115-4119
11. Mulder AHL, Heeringa P, Brouwer E, Limburg PC, Kallenberg CGM: Activation of granulocytes by anti-neutrophil cytoplasmic antibodies (ANCA): a Fc γ RIII-dependent process. *Clin Exp Immunol* 1994, 78:270-278
12. Porges AJ, Redecha PB, Kimberley WT, Csernok E, Gross WL, Kimberley RP: Anti-neutrophil cytoplasmic antibodies engage and activate human neutrophils via Fc γ RIIa. *J Immunol* 1994, 153:1271-1280
13. Brooks CJ, Adu D, Savage COS: ANCA stimulate neutrophils to produce IL-1 β . *Clin Exp Immunol* 1995, 101:39
14. Vargunam M, Adu D, Taylor CM, Michael J, Richards N,

- Neuberger J, Thompson RA: Endothelium myeloperoxidase-antimyeloperoxidase interaction in vasculitis. *Nephrol Dial Transplant* 1995, 7:1077-1081
15. Ewert BH, Jennette JC, Falk RJ: Anti-myeloperoxidase antibodies stimulate neutrophils to damage human endothelial cells. *Kidney Int* 1992, 41:375-383
 16. Savage CO, Pottinger BE, Gaskin G, Pusey CD, Pearson JD: Autoantibodies developing to myeloperoxidase and proteinase 3 in systemic vasculitis stimulate neutrophil cytotoxicity towards cultured endothelial cells. *Am J Pathol* 1992, 141:335-342
 17. Ballieux BEPB, Hiemstra PS, Klar-Mohamad N, Hagen EC, van Es LA, van der Woude FJ, Daha MR: Detachment and cytolysis of human endothelial cells by proteinase 3. *Eur J Immunol* 1994, 24:3211-3215
 18. Brouwer E, Huitema MG, Klok PA, de Weerd H, Cohen Tervaert JW, Weening JJ, Kallenberg CGM: Anti-myeloperoxidase associated proliferative glomerulonephritis: an animal model. *J Exp Med* 1993, 177:905-914
 19. Brouwer E, Weening JJ, Klok PA, Huitema MG, Cohen Tervaert JW, Kallenberg CGM: Induction of a humoral and cellular (auto) immune response to human and rat myeloperoxidase in Brown-Norway, Lewis, and Wistar Kyoto rat strains. *Adv Exp Med Biol* 1993, 336:139-142
 20. Meezan E, Hjelle JT, Brendel K, Carlson EC: A simple, versatile, nondisruptive method for the isolation of morphologically and chemically pure basement membranes from several tissues. *Life Sci* 1975, 17:1721-1732
 21. Langeveld JPM, Veerkamp JH, Duyf CPM, Monnens LAH: Chemical characterization of glomerular and tubular basement membranes of men of different age. *Kidney Int* 1981, 20:104-114
 22. van Goor H, van der Horst MLC, Fidler V, Grond J: Glomerular macrophage modulation affects mesangial expansion in the rat after renal ablation. *Lab Invest* 1992, 66:564-571
 23. Kampinga J, Aspinoll R: Thymocyte differentiation and thymic microenvironment development in the fetal rat thymus: an immunological approach. *Thymus Update*, vol 3. Edited by M Kendall, M Ritter. London, Harwood Academic Publishers, 1990, p 149
 24. Hunig T, Wallny HJ, Hartley JK, Lawetzky A, Tiefenthaler G: A monoclonal antibody to a constant determinant of the rat T cell antigen receptor that induces T cell activation. *J Exp Med* 1989, 169:73-86
 25. Pryzwanski KB, Martin LE, Spitznagel JK: Immunocytochemical localization of myeloperoxidase, lactoferrin, lysozyme and neutral proteases in human monocytes and neutrophilic granulocytes. *J Reticuloendothel Soc* 1978, 24:295-310
 26. Brouwer E, Huitema MG, Mulder AHL, Heeringa P, van Goor H, Cohen Tervaert JW, Kallenberg CGM: Neutrophil activation *in vitro* and *in vivo* in Wegener's granulomatosis. *Kidney Int* 1994, 45:1120-1131
 27. Kinjoh K, Kyogoku M, Good RA: Genetic selection for crescent formation yields mouse strain with rapidly progressive glomerulonephritis and small vessel vasculitis. *Proc Natl Acad Sci USA* 1993, 90:3413-3417
 28. Kettritz R, Yang JJ, Kinjoh K, Jennette JC, Falk RJ: Animal models in ANCA-vasculitis. *Clin Exp Immunol* 1995, 101:12-15
 29. Esnault VLM, Mathieson PW, Thiru S, Oliveira DB, Lockwood CM: Autoantibodies to myeloperoxidase in brown Norway rats treated with mercuric chloride. *Lab Invest* 1992, 67:114-120
 30. Mathieson PW, Thiru S, Oliveira DB: Mercuric chloride-treated brown Norway rats develop widespread tissue injury including necrotizing vasculitis. *Lab Invest* 1992, 67:121-129
 31. Yang JJ, Jennette JC, Falk RJ: Immune complex glomerulonephritis is induced in rats immunized with heterologous myeloperoxidase. *Clin Exp Immunol* 1994, 97:466-473
 32. Wilson CW: Nephritogenic antibody mechanisms involving antigens within the glomerulus. *Immunol Rev* 1981, 55:258-297
 33. Vissers MC, Wiggins R, Fantone JC: Comparative ability of human monocytes and neutrophils to degrade glomerular basement membrane *in vitro*. *Lab Invest* 1989, 60:831-838
 34. Johnson RJ, Couser WG, Chi EY, Adler S, Klebanoff SJ: New mechanism for glomerular injury myeloperoxidase-hydrogen peroxide-halide system. *J Clin Invest* 1987, 79:1379-1387
 35. Johnson RJ, Guggenheim SJ, Klebanoff SJ, Ochi RF, Wass A, Baker P, Schulze M, Couser WG: Morphological correlates of glomerular oxidant injury induced by the myeloperoxidase-hydrogen peroxide system of neutrophils. *Lab Invest* 1988, 5:294-301
 36. Rehan A, Johnson KJ, Kunkel RG, Wiggins RC: Role of oxygen radicals in phorbol myristate acetate-induced glomerular injury. *Kidney Int* 1985, 27:503-511
 37. Kobayashi K, Shibata T, Sugisaki S: Aggravation of rat nephrotoxic serum nephritis by anti-myeloperoxidase antibodies. *Kidney Int* 1995, 47:454-463
 38. Myers CR, O'Donoghue DJ, Brenchley PEC: ANCA stimulates PMN cytokine production. *J Am Soc Nephrol* 1995, 6:844
 39. Tomosugi NL, Cashman SJ, Hay H, Pusey CD, Evans DJ, Shaw A, Rees AJ: Modulation of antibody-mediated glomerular injury *in vivo* by bacterial lipopolysaccharide, tumor necrosis factor, and IL-1. *J Immunol* 1989, 142:3083-3090
 40. Muller Kobold AC, Mesander G, Kallenberg CGM, Cohen Tervaert JW: Activated circulating neutrophils in relation to disease activity in ANCA-associated vasculitis. *Nephrol Dial Transplant* 1996, 11:1690 (Abstract)
 41. Casselman BL, Kilgore KS, Miller BF, Warren JS: Antibodies to neutrophil cytoplasmic antigens induce monocyte chemoattractant protein-1 secretion from human monocytes. *J Lab Clin Med* 1995, 126:495-502