

The interplay between *Helicobacter pylori*, gastro-oesophageal reflux disease, and intestinal metaplasia

P Malfertheiner, U Peitz

Gut 2005;54(Suppl 1):i13-i20. doi: 10.1136/gut.2004.041533

Helicobacter pylori infection and gastro-oesophageal reflux disease (GERD) account for most upper gastrointestinal pathologies with a wide spectrum of clinical manifestations. The interplay of both conditions is complex, in part intriguing, and has become a matter of debate because of conflicting results. The cardia is an area where both *H pylori* and abnormal GERD exert their damaging potential, inducing inflammation and its consequences, such as intestinal metaplasia. While the role of intestinal metaplasia within columnar lined epithelium (Barrett's oesophagus) in the context of GERD is well established as a risk for neoplasia development, the role of intestinal metaplasia at the cardia in the context of *H pylori* infection is unclear. A particular challenge is the distinction of intestinal metaplasia as a consequence of GERD or *H pylori* if both conditions are concomitant. Available data on this issue, including follow up of a small patient series, are presented, but more studies are required to shed light on this issue because they will help to identify those patients that need surveillance.

well as their interpretation, are conflicting and contribute to keep the interplay of GERD and *H pylori* an intriguing one.⁸⁻¹⁰

There is an area, the cardia, where both the abnormal gastro-oesophageal reflux and *H pylori* may potentially exert their damage independently. However, they may be concomitant and interfere with each other. The result of *H pylori* infection and GERD at the cardia is an inflammatory reaction. In a subset of patients the inflammation may progress and lead to intestinal metaplasia.

In the following we will report on the complexity of the relationship between *H pylori* and GERD; the independent pathway of *H pylori* in the induction of inflammation and intestinal metaplasia, with special focus on the cardia; and the abnormalities of the oesophago-gastric junction (OGJ) in association with GERD. Further aspects are the characterisation of the intestinal metaplasia and the question of whether a distinction of intestinal metaplasia types will be attributed to either *H pylori* or GERD, and, finally, the fate of intestinal metaplasia during follow up.

THE H PYLORI-GERD RELATIONSHIP

The vast majority of pathologies in the oesophagus, stomach, and duodenum are related to either *H pylori* infection or GERD. Both conditions affect a large proportion of the population and they may occur either independently or concomitantly. The question of whether the two conditions are mutually exclusive, synergistic, or simply independent is an issue that was raised several years ago and is a matter of ongoing debate.¹⁰⁻¹¹ *H pylori* has a profound impact on the gastric mucosa and to a lesser extent on gastric physiology (gastrin, somatostatin, and acid secretion), whereas GERD is the result of an increased oesophageal exposure to gastric acid.¹²⁻¹⁴ Gastric acid secretion, therefore, is the key factor in the relationship between *H pylori* and GERD. In patients who develop chronic atrophic gastritis as a consequence of *H pylori* infection, gastric acid is suppressed and so acid would no longer appear to be produced in a critical amount for the induction of GERD.¹⁵⁻¹⁶ Retrospectively analysed data in a large patient group suggest that even a corpus predominant gastritis would exert a protective effect against GERD development.¹⁷

Current epidemiological trends indicate an inverse relationship in the Western world between the rising incidence of gastro-oesophageal reflux disease (GERD) and the decreasing incidence of duodenal ulcer disease as the classical clinical expression of *Helicobacter pylori* infection as well as of *H pylori* infection in general.¹⁻³ There is still uncertainty whether epidemiological data reflect a real increase of the incidence and prevalence of GERD, or whether merely a higher awareness and more attention is paid by endoscopists in the detection of erosive oesophagitis.⁴ There is no doubt, however, that the incidence of Barrett's carcinoma, which is the most serious consequence of GERD, has shown the steepest increase of all gastrointestinal tumours during past decades.⁵

A sum of additional aspects, including the lower prevalence of *H pylori* (around 10%) in patients with GERD, the increase of GERD following *H pylori* eradication, and the association that certain gastritis patterns (that is, atrophic corpus gastritis) would be rather inconceivable with GERD, have led to the widespread opinion that *H pylori* exerts a protective effect on the oesophagus and may prevent the development of GERD as well as its complications.^{1-6,7} However, the generation and sources of data, as

See end of article for authors' affiliations

Correspondence to:
P Malfertheiner,
Department of
Gastroenterology,
Hepatology, and Infectious
Diseases, Otto-von-
Guericke University,
Leipziger Str. 44, 39120
Magdeburg, Germany;
peter.malfertheiner@
medizin.uni-magdeburg.
de

Abbreviations: GERD, gastro-oesophageal reflux disease; PPI, proton pump inhibitor; NERD, non-erosive reflux disease; ERD, erosive reflux disease; CLE, columnar lined oesophagus; SCJ, squamo-columnar junction; OGJ, oesophago-gastric junction; CK, cytokeratin

In most patients, especially in the Western world, *H pylori* induces an antrum predominant gastritis^{18–20} and in this condition gastric acid secretion is rather increased,¹² which is also reflected in the different association of antrum predominant gastritis with duodenal ulcer and pangastritis with gastric ulcer.²¹ Antrum predominant gastritis is also the usual phenotype in GERD patients infected with *H pylori*.^{22–23}

Studies from Japan in patients with atrophic gastritis reported increased acid production following *H pylori* eradication and induction of GERD in a subset of patients.^{24–25} These patients were, however, predisposed because of a pre-existing impaired anti-reflux barrier.^{24–25} On the contrary, studies from Europe found that *H pylori* eradication did not lead to alterations in the duodenogastro-oesophageal reflux pattern²⁶ and the *H pylori* status in patients with GERD did not impact on the degree of oesophageal acid exposure.^{22–27} From these pathophysiological considerations the risk for GERD development following eradication seems to be low and is, if at all, restricted to patients with atrophic gastritis in whom acid secretion recovers and meets with the premise of an abnormal gastro-oesophageal reflux barrier.

A strong argument for the protective role of *H pylori* against GERD came from epidemiological studies. A lower prevalence of *H pylori* infection in patients affected by GERD in the magnitude of 5–10% when compared with a control population has been reported by most authors.^{6–8–10}

The protective potential of *H pylori* has further been emphasised in studies that discovered more virulent strains to be less prevalent or even absent in severe forms of GERD. Cag A carrying strains were suspected to protect from Barrett's adenocarcinoma.^{28–30} These early observations, however, were not confirmed in a large US population.³¹ By extending the analysis beyond Cag A to other *H pylori* virulence factors (vacAs1, iceA1), some authors report a decreased prevalence of these factors in patients with GERD or with more severe forms of GERD,^{32–33} while others did not.³⁴

The strongest argument for *H pylori* as a protective factor in GERD came from clinical trials. A higher incidence of erosive GERD following successful eradication in patients with duodenal ulcer disease had been reported^{7–35} but was recently rebutted by the analysis of large clinical trials conducted in patients with duodenal ulcer and gastric ulcer, in whom no increase of GERD following eradication has been documented.^{36–37}

The only advantage, with respect to the *H pylori* status, was the finding of a slightly (clinically irrelevant) increased healing of erosive oesophagitis with proton pump inhibitor (PPI) treatment. Healing of GERD with PPI treatment is marginally influenced by the *H pylori* status in severe forms due to a slightly increased efficacy of acid suppressants.³⁸

In conclusion, we appreciate the clinical reality that there is a large population of patients with GERD and concomitant *H pylori* infection. There is inconclusive evidence that more severe forms of GERD have a lower prevalence of *H pylori* infection or are infected with less virulent strains. From all current debates concerning the clinical management of *H pylori* infection in patients with GERD, eradication treatment is recommended in those who require long term PPI.³⁹ In most recent studies relapses of GERD are not more frequent in those treated for *H pylori* infection.^{40–42} However, in a further study, healing failure was more frequent in patients with *H pylori* eradication. Relapses in those patients with GERD on low dose PPI maintenance have also been reported to be more frequent following *H pylori* eradication.²³ Both PPI doses for initial healing (omeprazole 20 mg) and for maintenance (omeprazole 10 mg) do not correspond to current PPI standard dosing requirements.

H PYLORI CARDITIS AND INTESTINAL METAPLASIA

Early studies on *H pylori* have all concentrated on the pattern and degree of inflammation and mucosal damage in the gastric antrum, corpus, and fundus, but left out the cardia area. In 1994 Genta *et al*⁴³ in a careful investigation of the cardia drew attention to the fact that *H pylori* was present at this site in almost all patients in whom the infection was detected in the gastric antrum and body. Moreover, the degree of inflammation in the cardia was correlated with the degree of inflammation in the antrum and not with that in the corpus.^{44–45}

Subsequent studies confirmed the presence of *H pylori* in the cardia in almost all patients carrying the infection in the distal stomach, but in contrast to the original observation with a lower colonisation density and lesser degree of inflammation compared with the gastric antrum.^{44–46–49} In particular, patients with GERD had a reduced density of *H pylori* at the cardia.⁴² This has been suggested to be a consequence of the down regulation of *H pylori* growth by the lower pH in this site compared with the pre-pyloric antrum. This hypothesis is supported by the observation that a high acidity pocket is created in the upper fundic zone following the ingestion of a meal.⁵⁰

A progression of gastritis occurs over time in around 20% with development of intestinal metaplasia. The presence of intestinal metaplasia in the cardia occurs in parallel with the intestinal metaplasia in the antrum and is more prevalent than in the corpus.^{51–52} The prevalence of intestinal metaplasia in the cardia in association with *H pylori* infection is reported from many studies to be highly variable and ranges 5–40%.^{47–48–51–55}

Intestinal metaplasia as a consequence of *H pylori* positive gastritis appears usually after many years of persisting gastritis. Intestinal metaplasia is more frequent in older subjects (positive correlation with age) and is usually associated with atrophic gastritis.⁵⁶

Currently the hypothesis favoured is that a genetic predisposition is more relevant to the development of intestinal metaplasia than specific strains of *H pylori*.⁵⁷ The presence of intestinal metaplasia in association with atrophic changes in the gastric mucosa constitutes an increased risk for the development of gastric cancer.^{57–58} This is particularly true for the condition of a corpus predominant gastritis or pangastritis and relates to distal gastric cancer. It is presently not clear whether intestinal metaplasia at the cardia in association with *H pylori* represents a pre-neoplastic condition as well. A reversibility of intestinal metaplasia is unlikely to occur; however, data are conflicting. More important is the question of whether intestinal metaplasia, and what type, may progress to cancer.⁵⁷

In summary, *H pylori* leads to chronic inflammation of various degrees that involves the gastric mucosa from the most distal gastric (pre-pyloric) region up to the cardia. The topographical pattern of chronic gastritis is variable and ranges from an antrum predominant gastritis to a corpus predominant gastritis or even atrophic pangastritis. The cardia is usually involved in all cases infected with *H pylori*. Around 20% of the *H pylori* infected subjects in Western populations develop intestinal metaplasia. It is noteworthy that the intestinal metaplasia develops at a much higher frequency in the antrum than in the corpus region, and the prevalence of intestinal metaplasia in the cardia parallels the prevalence in the antrum.⁵¹

Once intestinal metaplasia is established, *H pylori* is no longer capable of colonising this epithelium. However, because intestinal metaplasia is often a focal process, *H pylori* may survive on the gastric epithelium in the neighbourhood of intestinal metaplasia.

Table 1 Subjects with v those without intestinal metaplasia in the gastric cardia with regard to clinical and histological characteristics (patients with Barrett's oesophagus (CLE plus intestinal metaplasia) are excluded as far as presented data allowed for such adjustment)

Author	Patients	Definition of normal OGJ	Number and location of cardia biopsies	Total number of patients	Number of patients with normal OGJ	Number of patients with intestinal metaplasia	GERD symptoms	Erosive oesophagitis	Hernie	<i>H pylori</i>	Intestinal metaplasia antrum	Correlation with age
Spechler ⁷⁷	Patients for elective endoscopy	<2 cm of columnar epithelium in distal oesophagus	Two from columnar epithelium at SCJ	142	142	26 (18.0%)	no	yes†	nd	nd	nd	no
Johnson ⁶⁹	Consecutive patients for endoscopy	<2 cm of columnar epithelium in distal oesophagus	Two just distal to SCJ	170	?	16 (9.4%)	yes	no	nd	nd	nd	no
Öberg ⁷⁴	Consecutive patients	SCJ at the proximal extent of the gastric rugal folds, no evidence of columnar lined oesophagus	Minimum five from OGJ	334	246	29 (11.7%)	nd	yes	yes	no	no	nd
Nandurkar ⁷³	Consecutive patients, CLE <3 cm included	Short segment Barrett's included (<3 cm)	Two immediately distal to Z-line	158	?	46 (29.1%)	no	no	nd	no	nd	yes
Trudgill ⁷⁸	Randomly selected	By exclusion: Barrett's oesophagus defined as >3 cm between SCJ and proximal margin of gastric folds	Three immediately below the SCJ, and three at 2 cm from the gastric flare	120	120	21 (18.0%)	no	no	no	no	yes	yes
Hackelsberger ⁵¹	Consecutive patients	Location of SCJ within 2 cm above OGJ with straight appearance of SCJ, no irregularity, no tongues or islands of columnar epithelium.	Two immediately below the SCJ	423	315	42 (13.0%)	no	no	nd	yes	yes	yes
El-Sera ⁸⁰	Consecutive patients	By exclusion of Barrett's oesophagus: defined as any length of columnar mucosa above the OGJ plus intestinal metaplasia	Two within 1–2 cm distal to the OGJ*	302	166	50 (30.0%)	no	no	nd	no	yes	yes
Voutilainen ⁵²	Consecutive dyspeptic patients	By exclusion: Barrett's oesophagus defined as incomplete intestinal metaplasia detected in the oesophagus	Two OGJ, that is proximal end of gastric folds	1058	1058	235 (22.0%)	no	yes	no	yes	yes	yes
Hirota ⁴⁸	Patients for endoscopy	Devoid of any tongues of pink columnar lined epithelium above the endoscopically defined OGJ	Two immediately distal to the Z-line	889	795	47 (5.9%)	no	no	no	yes	nd	yes
Peck-Radosavljevic ⁷⁵	Consecutive patients	OGJ without endoscopic lesion, no tongues of columnar epithelium	Two just below the SCJ, and two directly from the OGJ	200	186	22 (11.8%)	no	no	nd	no	yes	yes
Goldstein ⁴⁸	Consecutive patients	SCJ within 2 cm of mucosa proximal the uppermost gastric fold	One straddling the SCJ, one from within 1 cm below the SCJ	150	150	40 (37.3%)	nd	(yes)	yes	yes	yes	yes
Carton ⁴⁵	Consecutive patients for endoscopy	Not given, n=63 had short segment columnar lining in oesophagus	Four immediately distal to the Z-line	200	126	34 (17%)‡	yes	yes	nd	no	no	no
El-Zimaity ⁶²	65 Selected patients, 71 controls	By exclusion: short segment Barrett's oesophagus	Two within 0.5 cm of the Z-line or OGJ	136	123	21 (15.4%)	no	no	nd	yes	yes	nd
Pieramico ⁷⁶	122 Consecutive GERD patients, 49 controls	By exclusion: any length of columnar appearing mucosa in tubular oesophagus lining with histological presence of intestinal metaplasia	Two within 1 cm below the SCJ*	171	171	32 (19.0%)	no	no	nd	yes	nd	nd
Ormsby ⁷⁴	Consecutive autopsies	SCJ located immediately distal to the proximal gastric folds, 18 cases with Barrett's excluded	Entire OGJ sectioned	223	205	22 (10.7%)	nd	nd	nd	**	yes	no
Wolf ⁷⁹	Consecutive patients	Group 1, columnar lining 0–1 cm	Two immediately distal to the SCJ, and two from 2 cm distal to the OGJ	658	511	77 (15.1%)	no§	no§	no§	yes§	yes§	yes§

Table 1 Continued

Author	Patients	Definition of normal OGJ	Number and location of cardia biopsies	Total number of patients	Number of patients with normal OGJ	Number of patients with intestinal metaplasia	GERD symptoms	Erosive oesophagitis	Hernia	<i>H pylori</i>	Intestinal metaplasia antrum	Correlation with age
Morini ⁷²	Consecutive patients with dyspeptic or reflux symptoms	Not given, nd on Barrett's cases	Two within 2 cm below a normal looking SCJ*	133		18 (13.5%)	no	no	no	yes	yes	nd
Dincer ⁶⁶	All patients undergoing upper endoscopy	No columnar epithelium proximal to the OGJ, EGJ proximal heads of gastric folds	One from columnar side of the SCJ, one from 2 cm distal to the OGJ*	60	59	6 (10.0%)	no	no	nd	inverse	no	yes
Goldblum ⁴⁷	108 GERD, 70 Barrett's, 60 controls	SCJ Same level as OGJ, 70 cases with Barrett's excluded	Two immediately below or a least within 5 mm of the OGJ	238	168	13 (7.7%)	inverse	nd	nd	yes	yes	nd
Law ⁷⁰	Consecutive patients	Most proximal margin of the gastric folds, only cases with cardia type mucosa were analysed (n=100)	Two antegradely at SCJ, two retrogradely immediately below the SCJ	145	136 (100)	34 (34%)	no	no	no	no	nd	yes
Oksanen ⁵⁵	Consecutive outpatients (<45 years)	No classic Barrett's oesophagus, SCJ normally located; but: n=4 tongues of columnar mucosa <5 mm, n=36 tiny tongues	One to two or more at the SCJ or within 5 mm from the SCJ	168	168	11 (6.5%)	no	no	no	no	no	?

*Studies with location of cardia biopsies that rather may be assigned to the gastric fundic mucosa. †Only for histological signs of oesophagitis. ‡1.5% Normal OGJ, 24% short segment. §Not differentiated with regard to length of columnar lining. **,yes†† for chronic gastritis. CLE, columnar lined oesophagus; GERD, gastro-oesophageal reflux disease; OGJ oesophago-gastric junction; SCJ squamocolumnar junction; IM intestinal metaplasia; nd no data.

GERD AND INTESTINAL METAPLASIA

GERD is associated with a wide spectrum of endoscopic and histopathological changes. From the endoscopic perspective, GERD presents as non-erosive reflux disease (NERD), erosive reflux disease (ERD), or as columnar lined oesophagus (CLE). A recent validated classification distinguishes between NERD and ERD of different severity degrees.³⁹ Histologically, CLE may contain three different types of mucosa: specialised intestinal metaplasia, cardiac type mucosa, or oxyntic mucosa.⁶⁰ Where the term Barrett's oesophagus has formerly been used for any CLE irrespective of histology, there is now general acceptance that Barrett's oesophagus designates CLE containing specialised intestinal metaplasia.⁶¹ Although the determinants of the multifactorial aetiology of Barrett's oesophagus are not completely elucidated, gastro-oesophageal reflux is agreed upon as a necessary condition and as the most important causal factor. With the appropriate consideration of pitfalls such as hiatal hernia and erosive inflammatory lesions, the length of CLE segments is considered as short if <3 cm and long if >3 cm.

The importance of Barrett's oesophagus lies in its risk for adenocarcinoma of the oesophagus. This risk is increased from 10- to 30-fold. A recent meta-analysis calculated an incidence of 0.5% per patient-year.⁶²

Barrett's oesophagus is detected in approximately 8% of patients with GERD and is more frequently associated with ERD of any degree than with NERD.⁶³ Of note, CLE is also accidentally detected in around 6% of patients who undergo upper gastrointestinal endoscopy for reasons other than GERD related symptoms.⁶⁴

As CLE may contain gastric type epithelium, it is not surprising that CLE may be colonised by *H pylori*. The rate of colonisation in patients with an infected stomach varies considerably among different studies, ranging 0–90%.⁶ When considering the different types of epithelium within CLE, it becomes clear that only gastric type metaplasia, not specialised intestinal metaplasia, can be colonised by the bacterium. It is unknown whether such colonisation may increase the risk of carcinoma within CLE.

H PYLORI AND/OR GERD AT THE ORIGIN OF INTESTINAL METAPLASIA AT THE CARDIA

In recent years several investigators have directed their attention to the detection of intestinal metaplasia at the gastro-oesophageal junction, in particular at the squamo-columnar junction (SCJ) in patients without any endoscopic abnormality such as long or short segment CLE. An important finding in these patients with an endoscopically normal cardia is that histological examinations of biopsies taken at or below the SCJ reveal a prevalence of intestinal metaplasia 6–37% with a mean of 15.9% (see table 1 and fig 1).^{47 48 51 52 54 55 65–79}

The risk of intestinal metaplasia detected at the cardia with an endoscopically normal OGJ for adenocarcinoma is presently unknown. It may be close to the high risk of Barrett's oesophagus 10- to 30-fold,⁶² or to the much lower risk of intestinal metaplasia in the stomach, which amounts to a factor of two to threefold.⁵⁸ As long as longitudinal data on this topic are scarce, the estimation of the risk is essentially based on extrapolations from clinical, endoscopic, and histological associations with intestinal metaplasia at the cardia.

All full paper publications with sufficient data on such associations, listed on Medline (search terms: intestinal metaplasia and cardia), are included in table 1. Some studies addressed such associations as a primary aim. In other papers, the analysis of subgroups allowed for an association, quasi as a secondary aim. Although not intending a formal meta-analysis, for the purpose of this table, we excluded as

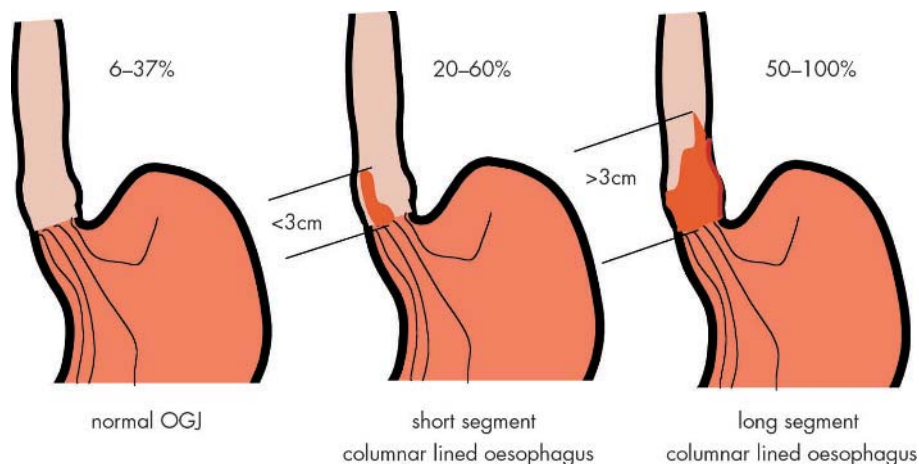


Figure 1 Prevalence of intestinal metaplasia dependent on endoscopic appearance of oesophagogastric junction.

far as possible those cases with Barrett's oesophagus, that is, CLE histologically exhibiting specialised intestinal metaplasia. In some publications, the study design excluded Barrett's oesophagus. In other studies, including patients with Barrett's oesophagus, we adjusted the prevalence of intestinal metaplasia by confining it to patients with a normal OGJ if the presentation of the data allowed for such data adjustment. This is the reason why the number of patients with a normal OGJ is smaller than the total number of patients in some of the studies. The prevalence of intestinal metaplasia in the general population is uncertain as all study samples represent patients with a clinical indication for endoscopy. One study investigated not endoscopies, but deceased patients selected for autopsy.⁷⁴

The association of intestinal metaplasia is less frequent with GERD manifestations than the correlation to *H pylori* infection and intestinal metaplasia in the gastric antrum. Why this discrepancy? The main reason for it is the difference at the biopsy site. Almost all studies showing an association of intestinal metaplasia with GERD manifestations included cases with a maximum of 2 cm columnar lining in the lower oesophagus. Therefore, these studies in part investigated patients who would be classified nowadays as short segment Barrett's oesophagus rather than intestinal metaplasia at the normal OGJ.^{69 73 77 81} The authors of all these studies report the patient characteristics independent of length of columnar lining and also independent of any endoscopic irregularities of the Z-line. In contrast, the vast majority of studies that excluded patients with any columnar lining in the lower oesophagus or patients with short segment Barrett's oesophagus did not confirm an association with GERD manifestations.

In some studies reporting associations of cardia intestinal metaplasia with intestinal metaplasia in the distal stomach and with *H pylori* infection, the so called cardia biopsies were taken at 1–2 cm below the OGJ or below the SCJ. As these studies do not report whether cardia intestinal metaplasia occurred on the grounds of cardiac type mucosa or fundic type mucosa, the biopsies have to be assigned to fundic mucosa rather than cardia mucosa.^{66 72 76 81}

However, the majority of studies of an association of cardia intestinal metaplasia with intestinal metaplasia in the distal stomach and of *H pylori* infection targeted the biopsies precisely to the OGJ, defined as the proximal end of the gastric folds. Biopsies have been reported to contain squamous as well as columnar epithelium. Four studies even focused only on biopsies containing cardiac type mucosa.^{54 67 70 81} Biopsies taken according to these criteria

Table 2 Differentiation of intestinal metaplasia by mucin histochemistry

Characteristic mucins	Complete type		Incomplete type
	Type 1, neutral mucins	Type 2, acid sialomucins	Type 3, acid sulphomucins
Mucin histochemistry			
Alcian blue and periodic acid-Schiff (PAS)	magenta	Blue	Blue
Alcian blue and high iron diamine		Blue	Brown-black
Alcian blue and Gomori's Aldehyde Fuchsin		Blue	Purple

These staining characteristics regard the columnar cells, not the goblet cells, which stain blue with Alcian blue.

will more reliably stem from the gastric cardia than biopsies obtained from 1–2 cm below the OGJ, and allow a more precise allocation of intestinal metaplasia to the cardia.

The evidence from these studies is that intestinal metaplasia at the endoscopically normal OGJ is associated with intestinal metaplasia in the distal stomach and a consequence of *H pylori* infection, and less likely a consequence of an abnormal acid reflux (GERD).

Some of the studies in table 1 and further studies also address the comparison between patients with intestinal metaplasia at the cardia and patients with Barrett's oesophagus. These studies confirm that intestinal metaplasia at the cardia is more closely associated with intestinal metaplasia in the distal stomach and with *H pylori* infection than is intestinal metaplasia in Barrett segments. Reflux manifestation like symptoms, reflux oesophagitis, and abnormal reflux function tests (manometry and pH-metry) were found to be more frequent and/or more severe in patients with Barrett's oesophagus than in those with intestinal metaplasia at the cardia.^{51 71 82–86}

Both types of comparisons, cardia intestinal metaplasia *v* histologically normal OGJ and cardia intestinal metaplasia *v* Barrett's oesophagus, support the association of intestinal metaplasia at the cardia with intestinal metaplasia in the distal stomach and with *H pylori* infection rather than with GERD. Notwithstanding this, unresolved issues continue to elude the origin and prognosis of intestinal metaplasia at the endoscopically normal OGJ. The association of cardia intestinal metaplasia with intestinal metaplasia in the distal

Table 3

Author	Patients	Therapeutic intervention	Median follow up (years)	Number of biopsies	Persistence of intestinal metaplasia (%)	Development of dysplasia
De Meester ¹⁰⁰	F	Fundoplication	2.1	6	5 (33%)	Regression of initial dysplasia in oesophage
Goldstein ⁴⁸	85	No data	2.4	2	6 (7%)	None
Morales ¹⁰⁸	28	No data	2.5	2-4*	19 (68%)	1 (1.4%/year)
Sharma ¹⁰¹	34	No data	2	4	†	1 (1.5%/year)
Peitz‡	19	<i>H pylori</i> eradication, partly PPI	2.5	3	8 (42%)	None

*Targeted by methylene blue. †100% because intestinal metaplasia at follow up was inclusion criteria.
‡Unpublished.

stomach was often stronger than that with *H pylori* infection. Furthermore, age was frequently correlated with intestinal metaplasia. These observations show that the most important cause for intestinal metaplasia at the cardia is not only *H pylori* infection and a number of other aetiological factors are important, such as smoking, environmental and genetic factors, and duodenogastric reflux. Two studies have revealed a link between abnormal duodenal gastric (biliary) reflux and intestinal metaplasia at the cardia.^{87 88}

The challenge in the individual case remains whether intestinal metaplasia at the cardia is the expression of an abnormal gastric reflux condition or is due to *H pylori* in those cases in which both conditions coexist.

Several histochemical and immunohistochemical methods have been proposed for the assignment of intestinal metaplasia at the cardia to either Barrett's oesophagus or gastric intestinal metaplasia. The most promising approaches are mucin staining and immunohistochemistry with antibodies against cytokeratin (CK) and colonic antigens.

The histochemical differentiation of mucins into three subtypes was first described in order to differentiate intestinal metaplasia in the stomach and to establish distinctive risk profiles of different types of intestinal metaplasia for gastric carcinoma.⁸⁹ The staining characteristic of the three subtypes are listed in table 2. In the stomach, intestinal metaplasia is mainly of type I. Type I is also designated complete type because it represents similar features as intestinal epithelium, including absorptive functions with a brush border. Type II and III lack such features and are therefore called incomplete. These types are more closely correlated with gastric adenocarcinoma than type I.⁸⁹ Such mucin typing of intestinal metaplasia has also been applied to intestinal metaplasia at the OGJ. Barrett's mucosa is to more than 90% the types II or III.⁹⁰⁻⁹² Intestinal metaplasia at the cardia, however, exhibits the incomplete type in only around 50%. Our own data support that mucin sub-typing may serve as an additional indicator for Barrett's oesophagus *v* gastric intestinal metaplasia.⁹²

Regarding CKs, Ormsby *et al*⁹³ observed three distinct patterns of CK7 and CK20: Barrett type characterised by strong diffuse CK7 and superficial CK20 immunostaining; gastric type with complete intestinal metaplasia characterised by absence of CK7 and strong diffuse CK20 staining; and gastric type with incomplete intestinal metaplasia showing weak patchy CK7 staining and moderate patchy CK20 staining. The reasonably good correlation with clinical and endoscopic characteristics of such systematic staining has been confirmed by Coulevard *et al*,⁹⁴ Wallner *et al*,⁸⁶ Jovanovic *et al*,⁹⁵ and Glickman *et al*,⁹⁶ whereas Mohammed *et al*⁹⁷ and El-Zimaity and Graham⁹⁸ did not find the CK pattern sufficiently helpful for differentiation. There are no data yet on the relevance of CK pattern for the prognosis regarding potential development towards neoplasia.

Another promising candidate for differentiation of intestinal metaplasia is Das1, an antibody shown to react specifically with colonic epithelial cells. In two studies, this antibody showed a significantly higher rate of positive immunohistochemistry in biopsies from Barrett's mucosa or cardia intestinal metaplasia than in biopsies from gastric antrum containing intestinal metaplasia.^{96 99}

THE FATE OF INTESTINAL METAPLASIA AT THE CARDIA

The real nature of cardia intestinal metaplasia and its variant endoscopic and histological appearances will not be disclosed until sufficient longitudinal study data are available. The development of Barrett's oesophagus starts at or close to the OGJ. Hence, intestinal metaplasia at the cardia may represent the beginning of Barrett's oesophagus. It is well known that the extent of Barrett's oesophagus develops rapidly and then remains rather stable for many years.¹⁰⁰ Therefore, those cases with cardia intestinal metaplasia that represent the beginning of Barrett's oesophagus would be identified during follow up examinations.

The few currently available longitudinal studies¹⁰¹⁻¹⁰³ on the fate of cardia intestinal metaplasia describe a decreased prevalence of intestinal metaplasia at the cardia during follow up. The current data are listed in table 3. However, there are also data on intestinal metaplasia being only detected at a repeat endoscopy in cases with an endoscopically suspicious OGJ.¹⁰⁴

Several explanations may account for such diverging results. One is therapeutic intervention. In one of the studies reporting a decreased prevalence of intestinal metaplasia at follow up, patients are examined after fundoplication. In our study, all patients with *H pylori* infection received eradication therapy and subsequently PPI treatment on demand. Other studies did not provide data on treatment during the interval until follow up.

Never the less, the rather low rate of persistence of intestinal metaplasia in the cardia, around 50%, is a surprising result. The available data, however, are too scarce to state that intestinal metaplasia at the cardia is really reversible. It still has to be excluded that disappearance of cardia intestinal metaplasia is not just a biopsy sampling error as intestinal metaplasia is known to be distributed in a patchy and mosaic pattern.^{105 106} Such distribution is known for both gastric intestinal metaplasia as well as specialised intestinal metaplasia in the oesophagus.

The issue of sampling error also applies to studies reporting an increase in the prevalence of intestinal metaplasia. There are no follow up data in patients with an endoscopically as well as histologically normal OGJ. Jones *et al*¹⁰⁴ reported on cases with endoscopically suspected Barrett's oesophagus, but not confirmed by histology. Such a condition can also be defined as CLE without intestinal metaplasia. A repeat

endoscopy in these patients revealed intestinal metaplasia in 23% of the cases, which may be explained by sampling error rather than by the short term development of intestinal metaplasia. Furthermore, there is evidence that the experience of the endoscopist leads to a higher detection rate of intestinal metaplasia.¹⁰⁷⁻¹⁰⁸

The occurrence of dysplasia (nowadays designated as intraepithelial neoplasia) within cardia intestinal metaplasia has been reported only by one group in one patient after a median follow up interval of approximately 2 years.¹⁰²⁻¹⁰⁹ Certainly, the number of patients observed as yet is too small to draw any conclusions. But by extrapolating data derived from cross sectional studies, we may conclude that the risk for neoplasia is lower than for Barrett's oesophagus.⁶⁸ Whether it is as low as the risk of gastric intestinal metaplasia to be associated with gastric cancer (two to threefold⁵⁸) needs to be determined.

Authors' affiliations

P Malfertheiner, U Peitz, Department of Gastroenterology, Hepatology, and Infectious Diseases, Otto-von-Guericke University, Germany

REFERENCES

- Blaser MJ. Hypothesis: the changing relationships of *Helicobacter pylori* and humans: implications for health and disease. *J Infect Dis* 1999;**179**:1523-30.
- Bardhan KD, Royston C, Nayyar M, et al. Reflux rising! A disease in evolution. *Gastroenterology* 2004;**118**(Suppl 2pt1):A478.
- El Serag HB, Sonnenberg A. Opposing time trends of peptic ulcer and reflux disease. *Gut* 1998;**43**:327-33.
- Prach AT, MacDonald TA, Hopwood DA, et al. Increasing incidence of Barrett's oesophagus: education, enthusiasm, or epidemiology? *Lancet* 1997;**350**:933.
- Devesa SS, Blot WJ, Fraumeni JFJ. Changing patterns in the incidence of esophageal and gastric carcinoma in the United States. *Cancer* 1998;**83**:2049-53.
- O'Connor HJ. *Helicobacter pylori* and gastro-oesophageal reflux disease: clinical implications and management [Review]. *Aliment Pharmacol Ther* 1999;**13**:117-27.
- Labenz J, Blum AL, Bayerdorffer E, et al. Curing *Helicobacter pylori* infection in patients with duodenal ulcer may provoke reflux esophagitis. *Gastroenterology* 1997;**112**:1442-7.
- Malfertheiner P, Gerards C. *Helicobacter pylori* infection and gastro-oesophageal reflux disease: coincidence or association? *Baillieres Best Pract Res Clin Gastroenterol* 2000;**14**:731-41.
- Xia HH, Talley NJ. *Helicobacter pylori* infection, reflux esophagitis, and atrophic gastritis: an unexplored triangle. *Am J Gastroenterol* 1998;**93**:394-400.
- Sharma P, Vakil N. *Helicobacter pylori* and reflux disease [Review]. *Aliment Pharmacol Ther* 2003;**17**:297-305.
- Labenz J, Malfertheiner P. *Helicobacter pylori* in gastro-oesophageal reflux disease: causal agent, independent or protective factor? *Gut* 1997;**41**:277-80.
- Calam J, Gibbons A, Healey ZV, et al. How does *Helicobacter pylori* cause mucosal damage? Its effect on acid and gastrin physiology. *Gastroenterology* 1997;**113**(Suppl):S43-9.
- el Omar EM, Oien K, El Nujumi A, et al. *Helicobacter pylori* infection and chronic gastric acid hyposecretion. *Gastroenterology* 1997;**113**:15-24.
- Gillen D, el Omar EM, Wirz AA, et al. The acid response to gastrin distinguishes duodenal ulcer patients from *Helicobacter pylori*-infected healthy subjects. *Gastroenterology* 1998;**114**:50-7.
- Koike T, Ohara S, Sekine H, et al. *Helicobacter pylori* infection prevents erosive reflux oesophagitis by decreasing gastric acid secretion. *Gut* 2001;**49**:330-4.
- Yamaji Y, Mitsuhashi T, Ikuma H, et al. Inverse background of *Helicobacter pylori* antibody and pepsinogen in reflux oesophagitis compared with gastric cancer: analysis of 5732 Japanese subjects. *Gut* 2001;**49**:335-40.
- El Serag HB, Sonnenberg A, Jamal MM, et al. Corpus gastritis is protective against reflux oesophagitis. *Gut* 1999;**45**:181-5.
- Genta RM, Graham DY. Comparison of biopsy sites for the histopathologic diagnosis of *Helicobacter pylori*: a topographic study of *H pylori* density and distribution. *Gastrointest Endosc* 1994;**40**:342-5.
- Khulusi S, Mendall MA, Patel P, et al. *Helicobacter pylori* infection density and gastric inflammation in duodenal ulcer and non-ulcer subjects. *Gut* 1995;**37**:319-24.
- Robert ME, Weinstein WM. *Helicobacter pylori*-associated gastric pathology. *Gastroenterol Clin North Am* 1993;**22**:59-72.
- Schultz V, Hackelsberger A, Gunther T, et al. Differing patterns of *Helicobacter pylori* gastritis in patients with duodenal, prepyloric, and gastric ulcer disease. *Scand J Gastroenterol* 1998;**33**:137-42.
- Zentilin P, Iritano E, Vignale C, et al. *Helicobacter pylori* infection is not involved in the pathogenesis of either erosive or non-erosive gastro-oesophageal reflux disease. *Aliment Pharmacol Ther* 2003;**17**:1057-64.
- Wu JC, Chan FK, Ching JY, et al. Effect of *Helicobacter pylori* eradication on treatment of gastro-oesophageal reflux disease: a double blind, placebo controlled, randomised trial. *Gut* 2004;**53**:174-9.
- Haruma K, Mihara M, Okamoto E, et al. Eradication of *Helicobacter pylori* increases gastric acidity in patients with atrophic gastritis of the corpus: evaluation of 24-h pH monitoring. *Aliment Pharmacol Ther* 1999;**13**:155-62.
- Koike T, Ohara S, Sekine H, et al. Increased gastric acid secretion after *Helicobacter pylori* eradication may be a factor for developing reflux esophagitis. *Aliment Pharmacol Ther* 2001;**15**:813-20.
- Manifold DK, Anggiansah A, Rowe I, et al. Gastro-oesophageal reflux and duodenogastric reflux before and after eradication in *Helicobacter pylori* gastritis. *Eur J Gastroenterol Hepatol* 2001;**13**:535-9.
- Peters FT, Kuipers EJ, Ganesh S, et al. The influence of *Helicobacter pylori* on oesophageal acid exposure in GERD during acid suppressive therapy. *Aliment Pharmacol Ther* 1999;**13**:921-6.
- Chow WH, Blaser MJ, Blot WJ, et al. An inverse relation between *cagA* strains of *Helicobacter pylori* infection and risk of esophageal and gastric cardia adenocarcinoma. *Cancer Res* 1998;**58**:588-90.
- Vaezi MF, Falk GW, Peek RM, et al. *CagA*-positive strains of *Helicobacter pylori* may protect against Barrett's esophagus. *Am J Gastroenterol* 2000;**95**:2206-11.
- Vicari JJ, Peek RM, Falk GW, et al. The seroprevalence of *cagA*-positive *Helicobacter pylori* strains in the spectrum of gastroesophageal reflux disease. *Gastroenterology* 1998;**115**:50-7.
- Wu AH, Crabtree JE, Bernstein L, et al. Role of *Helicobacter pylori CagA* strains and risk of adenocarcinoma of the stomach and esophagus. *Int J Cancer* 2003;**103**:815-21.
- Arents NL, van Zwet AA, Thijs JC, et al. The importance of *vacA*, *cagA*, and *iceA* genotypes of *Helicobacter pylori* infection in peptic ulcer disease and gastroesophageal reflux disease. *Am J Gastroenterol* 2001;**96**:2603-8.
- Fallone CA, Barkun AN, Gotke MU, et al. Association of *Helicobacter pylori* genotype with gastroesophageal reflux disease and other upper gastrointestinal diseases. *Am J Gastroenterol* 2000;**95**:659-69.
- Leodolter A, Wolle K, Peitz U, et al. *Helicobacter pylori* genotypes and expression of gastritis in erosive gastro-oesophageal reflux disease. *Scand J Gastroenterol* 2003;**38**:498-502.
- Fallone CA, Barkun AN, Friedman G, et al. Is *Helicobacter pylori* eradication associated with gastroesophageal reflux disease? *Am J Gastroenterol* 2000;**95**:914-20.
- Laine L, Sugg J. Effect of *Helicobacter pylori* eradication on development of erosive esophagitis and gastroesophageal reflux disease symptoms: a post hoc analysis of eight double blind prospective studies. *Am J Gastroenterol* 2002;**97**:2992-7.
- Malfertheiner P, Dent J, Zeijl L, et al. Impact of *Helicobacter pylori* eradication on heartburn in patients with gastric or duodenal ulcer disease—results from a randomized trial programme. *Aliment Pharmacol Ther* 2002;**16**:1431-42.
- Holtmann G, Cain C, Malfertheiner P. Gastric *Helicobacter pylori* infection accelerates healing of reflux esophagitis during treatment with the proton pump inhibitor pantoprazole. *Gastroenterology* 1999;**117**:11-6.
- Malfertheiner P, Megraud F, OMorain C, et al. Current concepts in the management of *Helicobacter pylori* infection—The Maastricht 2-2000 Consensus report. *Aliment Pharmacol Ther* 2002;**16**:167-80.
- Moayyedi P, Bardhan C, Young L, et al. *Helicobacter pylori* eradication does not exacerbate reflux symptoms in gastroesophageal reflux disease. *Gastroenterology* 2001;**121**:1120-6.
- Schwizer W, Thumshirn M, Dent J, et al. *Helicobacter pylori* and symptomatic relapse of gastro-oesophageal reflux disease: a randomised controlled trial. *Lancet* 2001;**357**:1738-42.
- Kuipers EJ, Nelis GF, Klinkenberg-Knol EC, et al. Cure of *Helicobacter pylori* infection in patients with reflux oesophagitis treated with long term omeprazole reverses gastritis without exacerbation of reflux disease: results of a randomised controlled trial. *Gut* 2004;**53**:12-20.
- Genta RM, Huberman RM, Graham DY. The gastric cardia in *Helicobacter pylori* infection. *Hum Pathol* 1994;**25**:915-9.
- Hackelsberger A, Gunther T, Schultze V, et al. Prevalence and pattern of *Helicobacter pylori* gastritis in the gastric cardia. *Am J Gastroenterol* 1997;**92**:2220-4.
- Voutilainen M, Farkkila M, Mecklin JP, et al. Chronic inflammation at the gastroesophageal junction (carditis) appears to be a specific finding related to *Helicobacter pylori* infection and gastroesophageal reflux disease. The Central Finland Endoscopy Study Group. *Am J Gastroenterol* 1999;**94**:3175-80.
- Chen YY, Antonioli DA, Spechler SJ, et al. Gastroesophageal reflux disease versus *Helicobacter pylori* infection as the cause of gastric carditis. *Mod Pathol* 1998;**11**:950-6.
- Goldblum JR, Richter JE, Vaezi M, et al. *Helicobacter pylori* infection, not gastroesophageal reflux, is the major cause of inflammation and intestinal metaplasia of gastric cardiac mucosa. *Am J Gastroenterol* 2002;**97**:302-11.
- Goldstein NS, Karim R. Gastric cardia inflammation and intestinal metaplasia: associations with reflux esophagitis and *Helicobacter pylori*. *Mod Pathol* 1999;**12**:1017-24.
- Wieczorek TJ, Wang HH, Antonioli DA, et al. Pathologic features of reflux and *Helicobacter pylori*-associated carditis: a comparative study. *Am J Surg Pathol* 2003;**27**:960-8.

- 50 Fletcher J, Wirz A, Young J, *et al*. Unbuffered highly acidic gastric juice exists at the gastroesophageal junction after a meal. *Gastroenterology* 2001;**121**:775–83.
- 51 Hackelsberger A, Gunther T, Schultze V, *et al*. Intestinal metaplasia at the gastro-oesophageal junction: Helicobacter pylori gastritis or gastro-oesophageal reflux disease? *Gut* 1998;**43**:17–21.
- 52 Vuolilainen M, Farkkila M, Juhola M, *et al*. Complete and incomplete intestinal metaplasia at the oesophagogastric junction: prevalences and associations with endoscopic erosive oesophagitis and gastritis. *Gut* 1999;**45**:644–8.
- 53 Hackelsberger A, Schultze V, Gunther T, *et al*. The prevalence of Helicobacter pylori gastritis in patients with reflux oesophagitis: a case-control study. *Eur J Gastroenterol Hepatol* 1998;**10**:465–8.
- 54 Oberg S, Peters JH, DeMeester TR, *et al*. Inflammation and specialized intestinal metaplasia of cardiac mucosa is a manifestation of gastroesophageal reflux disease. *Ann Surg* 1997;**226**:522–30.
- 55 Oksanen A, Sipponen P, Karttunen R, *et al*. Inflammation and intestinal metaplasia at the squamocolumnar junction in young patients with or without Helicobacter pylori infection. *Gut* 2003;**52**:194–8.
- 56 Dixon MF. Histological responses to Helicobacter pylori infection: gastritis, atrophy and preneoplasia. *Baillieres Clin Gastroenterol* 1995;**9**:467–86.
- 57 Dixon MF. Prospects for intervention in gastric carcinogenesis: reversibility of gastric atrophy and intestinal metaplasia. *Gut* 2001;**49**:2–4.
- 58 Meining A, Kiel G, Stolte M. Changes in Helicobacter pylori-induced gastritis in the antrum and corpus during and after 12 months of treatment with ranitidine and lansoprazole in patients with duodenal ulcer disease. *Aliment Pharmacol Ther* 1998;**12**:735–40.
- 59 Lundell LR, Dent J, Bennett JR, *et al*. Endoscopic assessment of oesophagitis: clinical and functional correlates and further validation of the Los Angeles classification. *Gut* 1999;**45**:172–80.
- 60 Chandrasoma PT, Der R, Dalton P, *et al*. Distribution and significance of epithelial types in columnar-lined esophagus. *Am J Surg Pathol* 2001;**25**:1188–93.
- 61 Sampliner RE, Camargo L, Fass R. Impact of esophageal acid exposure on the endoscopic reversal of Barrett's esophagus. *Am J Gastroenterol* 2002;**97**:270–2.
- 62 Shaheen NJ, Crosby MA, Bozynski EM, *et al*. Is there publication bias in the reporting of cancer risk in Barrett's esophagus? *Gastroenterology* 2000;**119**:333–8.
- 63 Malfetheriner P, Lind T, Willich S, *et al*. Prognostic influence of Barrett's esophagus and of H Pylori infection on healing of erosive GERD and symptom resolution in non-erosive GERD. *Gut* 2005;**54**(Suppl 1):i27–32.
- 64 Sharma P, Sidorenko EI. Are screening and surveillance for Barrett's esophagus really worthwhile? *Gut* 2005;**54**(Suppl 1):i27–32.
- 65 Carton E, Mulligan ED, Keeling PW, *et al*. Specialized intestinal metaplasia: analysis of prevalence, risk factors and association with gastro-oesophageal reflux disease. *Br J Surg* 2000;**87**:362–73.
- 66 Dincer D, Besisik F, Sahin E, *et al*. Intestinal metaplasia of the gastric cardia: a study from Turkey. *Hepatogastroenterology* 2002;**49**:1153–6.
- 67 El Zimaity HM, Verghese VJ, Ramchatesingh J, *et al*. The gastric cardia in gastro-oesophageal disease. *J Clin Pathol* 2000;**53**:619–25.
- 68 Hirota WK, Loughney TM, Lazas DJ, *et al*. Specialized intestinal metaplasia, dysplasia, and cancer of the esophagus and esophagogastric junction: prevalence and clinical data. *Gastroenterology* 1999;**116**:277–85.
- 69 Johnston MH, Hammond AS, Laskin W, *et al*. The prevalence and clinical characteristics of short segments of specialized intestinal metaplasia in the distal esophagus on routine endoscopy. *Am J Gastroenterol* 1996;**91**:1507–11.
- 70 Law S, Lam KY, Chu KM, *et al*. Specialized intestinal metaplasia and carditis at the gastroesophageal junction in Chinese patients undergoing endoscopy. *Am J Gastroenterol* 2002;**97**:1924–9.
- 71 Morales TG, Bhattacharyya A, Johnson C, *et al*. Is Barrett's esophagus associated with intestinal metaplasia of the gastric cardia? *Am J Gastroenterol* 1997;**92**:1818–22.
- 72 Morini S, Zullo A, Hassan C, *et al*. Gastric cardia inflammation: role of Helicobacter pylori infection and symptoms of gastroesophageal reflux disease. *Am J Gastroenterol* 2001;**96**:2337–40.
- 73 Nandurkar S, Talley NJ, Martin CJ, *et al*. Short segment Barrett's esophagus: prevalence, diagnosis and associations. *Gut* 1997;**40**:710–5.
- 74 Ormsby AH, Kilgore SP, Goldblum JR, *et al*. The location and frequency of intestinal metaplasia at the esophagogastric junction in 223 consecutive autopsies: implications for patient treatment and preventive strategies in Barrett's esophagus. *Mod Pathol* 2000;**13**:614–20.
- 75 Peck-Radosavljevic M, Puspok A, Potzi R, *et al*. Histological findings after routine biopsy at the gastro-oesophageal junction. *Eur J Gastroenterol Hepatol* 1999;**11**:1265–70.
- 76 Pieramico O, Zanetti MV. Relationship between intestinal metaplasia of the gastro-oesophageal junction, Helicobacter pylori infection and gastro-oesophageal reflux disease: a prospective study. *Dig Liver Dis* 2000;**32**:567–72.
- 77 Spechler SJ, Zeroogian JM, Antonioli DA, *et al*. Prevalence of metaplasia at the gastro-oesophageal junction. *Lancet* 1994;**344**:1533–6.
- 78 Trudgill NJ, Suvarna SK, Kapur KC, *et al*. Intestinal metaplasia at the squamocolumnar junction in patients attending for diagnostic gastroscopy. *Gut* 1997;**41**:585–9.
- 79 Wolf C, Seldenrijk CA, Timmer R, *et al*. Epidemiological, clinical, and histological characteristics of intestinal metaplasia at the oesophagogastric junction compared to short segments of columnar-lined oesophagus. *Eur J Gastroenterol Hepatol* 2001;**13**:113–20.
- 80 El Serag HB, Sonnenberg A, Jamal MM, *et al*. Characteristics of intestinal metaplasia in the gastric cardia. *Am J Gastroenterol* 1999;**94**:622–7.
- 81 Carton E, Caldwell MT, McDonald G, *et al*. Specialized intestinal metaplasia in patients with gastro-oesophageal reflux disease. *Br J Surg* 2000;**87**:116–21.
- 82 Chalasani N, Wo JM, Hunter JG, *et al*. Significance of intestinal metaplasia in different areas of esophagus including esophagogastric junction. *Dig Dis Sci* 1997;**42**:603–7.
- 83 Csendes A, Smok G, Flores N, *et al*. Comparison of clinical, endoscopic and functional findings in patients with intestinal metaplasia at the cardia, carditis and short-segment columnar epithelium of the distal esophagus with and without intestinal metaplasia. *Dis Esophagus* 2000;**13**:61–8.
- 84 Pereira AD, Suspiro A, Chaves P, *et al*. Short segments of Barrett's epithelium and intestinal metaplasia in normal appearing oesophagogastric junctions: the same or two different entities? *Gut* 1998;**42**:659–62.
- 85 Vuolilainen M, Farkkila M, Mecklin JP, *et al*. Classical Barrett esophagus contrasted with Barrett-type epithelium at normal-appearing esophagogastric junction. Central Finland Endoscopy Study Group. *Scand J Gastroenterol* 2000;**35**:2–9.
- 86 Wallner B, Sylvan A, Janunger KG, *et al*. Immunohistochemical markers for Barrett's esophagus and associations to esophageal Z-line appearance. *Scand J Gastroenterol* 2001;**36**:910–5.
- 87 Dixon MF, Mapstone NP, Neville PM, *et al*. Bile reflux gastritis and intestinal metaplasia at the cardia. *Gut* 2002;**51**:351–5.
- 88 Oberg S, Peters JH, DeMeester TR, *et al*. Determinants of intestinal metaplasia within the columnar-lined esophagus. *Arch Surg* 2000;**135**:651–5.
- 89 Jass JR, Filipe MI. The mucin profiles of normal gastric mucosa, intestinal metaplasia and its variants and gastric carcinoma. *Histochem J* 1981;**13**:931–9.
- 90 van Sandick JW, van Lanschot JB, van Felius L, *et al*. Intestinal metaplasia of the esophagus or esophagogastric junction: evidence of distinct clinical, pathologic, and histochemical staining features. *Am J Clin Pathol* 2002;**117**:117–25.
- 91 Byrne JP, Bhatnagar S, Hamid B, *et al*. Comparative study of intestinal metaplasia and mucin staining at the cardia and esophagogastric junction in 225 symptomatic patients presenting for diagnostic open-access gastroscopy. *Am J Gastroenterol* 1999;**94**:98–103.
- 92 Gunther T, Hackelsberger A, Malfetheriner P, *et al*. Is typing of metaplasia at the squamocolumnar junction revealing its aetiology? *Virchows Arch* 2000;**436**:6–11.
- 93 Ormsby AH, Goldblum JR, Rice TW, *et al*. The utility of cytokeratin subsets in distinguishing Barrett's-related oesophageal adenocarcinoma from gastric adenocarcinoma. *Histopathology* 2001;**38**:307–11.
- 94 Couvelard A, Cauvin JM, Goldfain D, *et al*. Cytokeratin immunoreactivity of intestinal metaplasia at normal oesophagogastric junction indicates its aetiology. *Gut* 2001;**49**:761–6.
- 95 Jovanovic I, Tzardi M, Mouzas IA, *et al*. Changing pattern of cytokeratin 7 and 20 expression from normal epithelium to intestinal metaplasia of the gastric mucosa and gastroesophageal junction. *Histol Histopathol* 2002;**17**:445–54.
- 96 Glickman JN, Wang H, Das KM, *et al*. Phenotype of Barrett's esophagus and intestinal metaplasia of the distal esophagus and gastroesophageal junction: an immunohistochemical study of cytokeratins 7 and 20, Das-1 and 45 M1. *Am J Surg Pathol* 2001;**25**:87–94.
- 97 Mohammed IA, Streutker CJ, Riddell RH. Utilization of cytokeratins 7 and 20 does not differentiate between Barrett's esophagus and gastric cardiac intestinal metaplasia. *Mod Pathol* 2002;**15**:611–6.
- 98 El Zimaity HM, Graham DY. Cytokeratin subsets for distinguishing Barrett's esophagus from intestinal metaplasia in the cardia using endoscopic biopsy specimens. *Am J Gastroenterol* 2001;**96**:1378–82.
- 99 DeMeester SR, Wickramasinghe KS, Lord RV, *et al*. Cytokeratin and DAS-1 immunostaining reveal similarities among cardiac mucosa, CIM, and Barrett's esophagus. *Am J Gastroenterol* 2002;**97**:2514–23.
- 100 Falk GW. Barrett's esophagus. *Gastroenterology* 2002;**122**:1569–91.
- 101 DeMeester SR, Campos GM, DeMeester TR, *et al*. The impact of an antireflux procedure on intestinal metaplasia of the cardia. *Ann Surg* 1998;**228**:547–56.
- 102 Sharma P, Weston AP, Morales T, *et al*. Relative risk of dysplasia for patients with intestinal metaplasia in the distal oesophagus and in the gastric cardia. *Gut* 2000;**46**:9–13.
- 103 Goldstein NS. Gastric cardia intestinal metaplasia: biopsy follow-up of 85 patients. *Mod Pathol* 2000;**13**:1072–9.
- 104 Jones TF, Sharma P, Daaboul B, *et al*. Yield of intestinal metaplasia in patients with suspected short-segment Barrett's esophagus (SSBE) on repeat endoscopy. *Dig Dis Sci* 2002;**47**:2108–11.
- 105 Eloubeidi MA, Provenzale D. Does this patient have Barrett's esophagus? The utility of predicting Barrett's esophagus at the index endoscopy. *Am J Gastroenterol* 1999;**94**:937–43.
- 106 Fitzgerald RC, Abdalla S, Onwuegbusi BA, *et al*. Inflammatory gradient in Barrett's oesophagus: implications for disease complications. *Gut* 2002;**51**:316–22.
- 107 Oberg S, Johansson J, Wenner J, *et al*. Endoscopic surveillance of columnar-lined esophagus: frequency of intestinal metaplasia detection and impact of antireflux surgery. *Ann Surg* 2001;**234**:619–26.
- 108 Padda S, Ramirez FC. Accuracy in the diagnosis of short-segment Barrett's esophagus: the role of endoscopic experience. *Gastrointest Endosc* 2001;**54**:605–8.
- 109 Morales TG, Camargo E, Bhattacharyya A, *et al*. Long-term follow-up of intestinal metaplasia of the gastric cardia. *Am J Gastroenterol* 2000;**95**:1677–80.