

(Rowlands, 1959). A satisfactory method of measuring the rate of flow is urgently required for the investigation of the common clinical problem of simple diarrhoea. The most welcome advance in this field, however, would be the development of techniques which do not require intubation, and a step has already been taken in this direction. An ingenious method has been described which depends on the use of a small radio transmitter contained in a pill which is easily swallowed and transmits information about pressure, temperature, and hydrogen ion concentration during its passage through the alimentary tract (Mackay and Jacobson, 1958).

REFERENCES

- BENSON, J. A., *et al.* (1957) *New Engl. J. Med.*, **256**, 335.
- BERES, P., WENGER, J., and KIRSNER, J. B. (1957) *Gastroenterology*, **32**, 1.
- BLANKENHORN, D. H., HIRSCH, J., and AHRENS, E. H. (1955) *Proc. Soc. exp. Biol., N.Y.*, **88**, 356.
- BLOMSTRAND, R. (1958) Abstracts of Scientific Presentations, World Congress of Gastroenterology. Washington; p. 19.
- BORGSTRÖM, B., DAHLQVIST, A., LUNDH, G., and SJÖVALL, J. (1957) *J. clin. Invest.*, **36**, 1521.
- CALLENDER, S. T. E. (1958) *Lancet*, *ii*, 257.
- CHANARIN, I., ANDERSON, B. B., and MOLLIN, D. L. (1958) *Brit. J. Haemat.*, **4**, 156.
- COMFORT, M. W., WOLLAEGER, E. E., TAYLOR, A. B., and POWER, M. H. (1953) *Gastroenterology*, **23**, 155.
- COOKE, W. T. (1958) *Brit. med. J.*, *ii*, 261.
- , and FRENCH, J. M. (1958) In: *Modern Trends in Gastroenterology*. Ed.: F. Avery Jones. London; p. 218.
- , THOMAS, G., MANGALL, D., and CROSS, H. (1953) *Clin. Sci.*, **12**, 223.
- CUMMINS, A. J., and ALMY, T. P. (1953) *Gastroenterology*, **23**, 179.
- DUFFY, B. J., and TURNER, D. A. (1958) *Ann. intern. Med.*, **48**, 1.
- GIRDWOOD, R. H. (1953) *Lancet*, *ii*, 53.
- GROSSMAN, M. I., and JORDAN, P. H. (1958) *Gastroenterology*, **34**, 892.
- HIRSCH, J., AHRENS, E. H., and BLANKENHORN, D. H. (1956) *Gastroenterology*, **31**, 274.
- KAMER, J. H. van de, HUIJINK, H. ten B., and WEYERS, H. A. (1949) *J. biol. Chem.*, **177**, 347.
- LEGERTON, C. W., TEXTER, E. C., and RUFFIN, J. M. (1953) *Gastroenterology*, **23**, 477.
- LUNDH, G. (1958) *Acta. chir. scand.*, Suppl. 231.
- MCINTYRE, P. A., SACHS, M. V., KREVANS, J. R., and CONLEY, C. L. (1956), *Arch. intern. Med.*, **98**, 541.
- MACKAY, R. S., and JACOBSON, B. (1958) *Electronics*, **31**, 51.
- McKENNA, R. D., BOURNE, R. H., and MATZKO, A. (1957) *Gastroenterology*, **32**, 17.
- MOLLIN, D. L., BOOTH, C. C., and BAKER, S. J. (1957) *Brit. J. Haemat.*, **3**, 412.
- REEMTSMA, K., MALM, J. R., and BARKER, H. G. (1957) *Surgery*, **42**, 22.
- ROSS, C. A. C., *et al.* (1955) *Lancet*, *i*, 1087.
- ROWLANDS, E. N. (1959) In: *Symposium on Quantitative Methods in Human Pharmacology and Therapeutics*, 24th and 25th March, 1958. Ed.: D. R. Laurence. London. In press.
- RUFFIN, J. M., *et al.* (1958) *Gastroenterology*, **34**, 484.

Histopathology of the Small Intestine

By B. C. MORSON, M.A., D.M.

St. Mark's Hospital, London

THE small intestine, excluding the duodenum, is about 20–25 feet long. The proximal two-fifths is called the jejunum and the distal three-fifths constitutes the ileum. It tends to become narrower throughout its course, but there are also microscopical differences between the jejunum and ileum which will be referred to later.

In its general microscopic structure the small intestine consists of two muscle layers, an inner circular and an outer longitudinal, lined by a mucous membrane and covered externally by visceral peritoneum. The mucous membrane or mucosa is separated from the muscle layers or muscularis externa by a layer of loose connective tissue known as the submucosa. Likewise the peritoneum and muscularis externa are separated by the serosa, also composed of loose connective tissue. In the normal small intestine the mucosa and the peritoneum are freely mobile over the muscularis externa.

The small intestinal mucosa consists of an epithelial membrane and a supporting framework of fine connective tissue known as the lamina propria. These rest on the muscularis mucosæ. The latter consists of smooth muscle fibres together with some elastic tissue. Some of the muscle fibres are longitudinal, others are circular. The muscularis mucosæ is important in the maintenance of the normal mucosal pattern. The submucosa and serosa consist of loose connective tissue and elastic fibres containing the main blood and lymphatic supply to the intestinal wall. In particular, the submucosa contains numerous large veins. Meissner's plexus of post-ganglionic sympathetic nerves together with ganglia is found in the submucosa. Auerbach's plexus of ganglia and preganglionic parasympathetic nerves is found between the two layers of the muscularis externa. The visceral peritoneum covering the small intestine is composed of a thin layer of pavement epithelium supported by a layer of fibrous tissue which contains a well-developed elastic lamina (Fig. 1). Hence the elasticity of the peritoneum.

The small intestine presents an enormous absorptive surface, not only because of its great length, but because the mucous membrane is thrown into crescentic circular folds or plicæ circulares. These are most prominent in the upper jejunum (Fig. 2), gradually becoming smaller towards the lower ileum where they disappear. The absorptive surface is also increased by the intestinal villi, which are most developed in the jejunum, again becoming fewer and shorter towards the lower ileum. There are

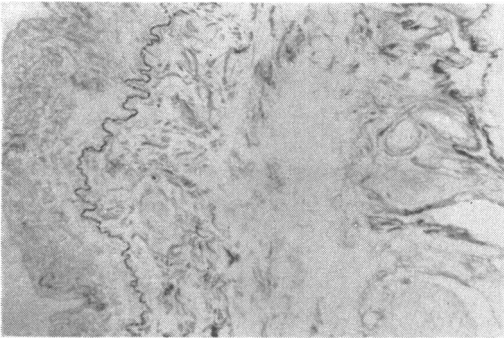


FIG. 1.—Peritoneum showing the wavy elastic lamina stained black by Weigert's method. $\times 125$

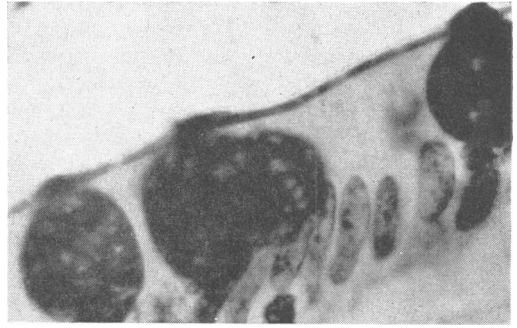


FIG. 3.—Small intestinal epithelium. Simple columnar cells and goblet cells are present. Note the brush border. PAS. $\times 315$.

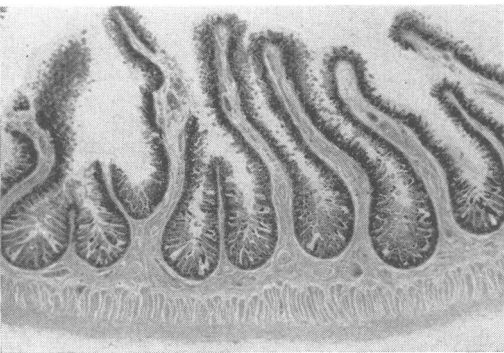


FIG. 2.—Normal jejunum. H. and E. $\times 2$.

anatomical reasons, then, to support the view that the absorptive and secretory power per foot is greater in the jejunum than the ileum. The presence of the plicæ circulares appears to depend on the tone of the smooth muscle fibres of the muscularis mucosæ and on the state of the submucosa. In the normal small intestine dilatation will cause the plicæ to disappear, and contraction to emphasize their presence. But contraction and dilatation are only possible in the presence of a normal elastic submucosa. If the latter is affected by fibrosis, the muscularis mucosæ will be immobilized, leading to atrophy of the plicæ.

The surface cells of the small intestine which cover the intestinal villi are of two types (Fig. 3). Firstly, there are simple columnar cells which are non-secretory and primarily absorptive in function. Between these simple columnar cells may be seen goblet cells, in varying stages of mucus secretion. The simple columnar epithelial cells have a brush border which is really composed of enormous numbers of microvilli which further increase the absorptive capacity of the epithelial membrane: these are only found in small intestinal epithelium. They are absent from the normal stomach mucosa and from

large intestinal mucosa which is entirely composed of mucus-secreting or goblet cells. Their absence from the colon links up with the relatively greater absorptive power of the small intestine.

The mucus-secreting or goblet cells of the small and large intestine are stained red by mucicarmine. The normal gastric mucosa will not stain with mucicarmine, which suggests that gastric and intestinal mucus differ in their chemical structure.

The experiments by Florey (1958) at Oxford suggest that the functions of mucus are mainly physical, being concerned with lubrication and the protection of the delicate intestinal mucous membrane from damage by solid matter. This is illustrated by the examination of surgical specimens of intestine from patients who have been prepared pre-operatively with non-absorbable sulphonamide. Not infrequently these contain the disintegrating tablets of sulphonamide wrapped up in a neat parcel of mucus.

The deep part of the small intestinal mucosa contains the intestinal glands or crypts of Lieberkühn. These are also lined by simple columnar and goblet cells, except at the base of the crypts where two types of cell of great interest are found. These are the Kulchitsky cells and the Paneth cells.

The Kulchitsky cell has, in recent years, achieved considerable notoriety because of the discovery of the clinical syndrome associated with carcinoid tumours. The cells are found mostly near the base of the crypts of Lieberkühn, although some may be seen nearer the surface of the epithelium. They are low columnar or triangular in shape, with nuclei which are rather larger and clearer than those of the neighbouring cells. The cytoplasm contains granules which are always infranuclear in contrast to the neighbouring Paneth cells in which the granules

are supranuclear. We now know that the granules in the Kulchitsky cells contain 5-hydroxytryptamine and that this substance is secreted into the blood stream. In other words, the Kulchitsky cell is an endocrine cell, and this might explain the basal position of the cytoplasmic granules. The Kulchitsky cells are found throughout the gastro-intestinal tract, but are most common in the duodenum and small intestine. There seems to be no difference in their frequency in the jejunum and ileum.

The granules in Kulchitsky cells and carcinoid tumours may be stained brick red by a diazo dye, the Brentamine fast Red B Salt. They are also strongly eosinophilic in hæmatoxylin and eosin preparations and have the property of reducing ammoniacal silver to metallic silver—in other words they are argentaffin. Hence the term argentaffinoma.

It has been noticed that there is hypertrophy of smooth muscle in the neighbourhood of carcinoid tumours and the suggestion has been made that this is due to the local effect of 5-hydroxytryptamine secretion. However, it is my experience that local hypertrophy of smooth muscle is common in the neighbourhood of diseased intestine, including carcinoma and endometriosis. It is probable that this is a work hypertrophy following interruption of the normal muscular contractions of the intestine by diseased tissue. More evidence must be obtained before the theory can be accepted that the hypertrophy of muscle in the neighbourhood of carcinoid tumours is due to the local action of serotonin.

We know something of the histology and function of the Kulchitsky cell. The other special cell found at the base of the crypts of Lieberkühn remains a complete mystery. This is the Paneth cell.

The Paneth cell (Fig. 4) was first described by Schwalbe in 1872, but the first accurate description was given by the German physician Dr. Paneth in 1888. It is remarkable that we have almost nothing to add to-day to Dr. Paneth's original description of this cell and we are still ignorant of its function.

Paneth cells are found only in the small intestine. They are absent from the normal stomach, although they may be present in areas of intestinal metaplasia. An occasional Paneth cell can be found in the cæcum, but they are absent from the rest of the large intestine. The cells are found only at the base of the crypts of Lieberkühn. Most crypts have at least one cell and often two or three.

Paneth cells contain numerous, rather coarse granules which are supranuclear in position. They are strongly eosinophilic in hæmatoxylin and eosin preparations. A more specific staining

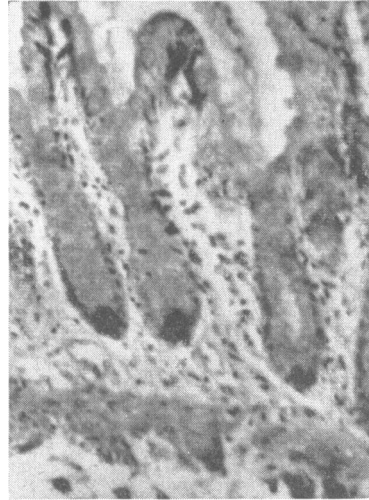


FIG. 4.—Small intestinal mucosa. Paneth cells at the base of the crypts of Lieberkühn. Phosphotungstic acid, hæmatoxylin and mucicarmine. $\times 105$.

technique has been described by Kerr and Lendrum (1936) in which the granules are stained blue-black by phosphotungstic acid hæmatoxylin. The supranuclear position of the Paneth cell granules suggests that they are extruded into the lumen of the crypts of Lieberkühn. However, free granules are not seen in the lumen, although a close study of the periphery of the cell strongly suggests that they are excreted in this direction.

The chemical nature and function of Paneth cell granules is not known. There is no sound evidence for the theory that they are precursors of goblet cells. An increase or decrease in their number and position has not been described in any disease; and unlike the neighbouring Kulchitsky cells, tumours of Paneth cells have never been reported. Our ignorance of this common cell is profound, and is a challenge to future research.

Nodules of lymphoid tissue are present in the lamina propria throughout the small intestine. The smaller are entirely confined to the lamina propria, but larger ones bulge through the muscularis mucosæ into the submucosa. These small nodules are found with greatest frequency in the lower ileum. In addition, the lower ileum contains considerably larger nodules of lymphoid tissue in the mucosa known as Peyer's patches.

Lymphoid tissue plays an important part in the pathogenesis of diseases of the small intestine. It provides a focus of infection for a number of inflammatory conditions. Typhoid and tuberculosis are well-known examples of this—the ulcers being found with greater frequency in the

lower ileum where there is most lymphoid tissue. Likewise, the ileocaecal type of intussusception in infants is possibly due to hyperplasia of the lymphoid tissue in the terminal ileum. There is evidence, too, that Crohn's disease begins in the lymphoid tissue of the small intestine. In the first place Crohn's disease is most common in the terminal ileum. Secondly, the histological appearances are those of a disease of lymphatic tissue. The three main histological features in Crohn's disease are: overgrowth of lymphoid tissue with a characteristic distribution in the submucosa; the formation of fissures which appear to begin in the lymphatic nodules of the mucosa and gradually extend through the intestinal wall; and last, the presence of non-caseating giant cell systems in at least 60% of cases. These resemble the giant cell systems of sarcoid rather than tuberculosis.

It is well known that ectopic epithelium of gastric or pancreatic type may be found in the intestine, particularly within a Meckel's diverticulum. In my experience epithelium of the type found in the pyloric glands of the stomach is not infrequently present in pathological material from the ileum (Fig. 5). Whether this is due to metaplasia or is a congenital abnormality is not clear, although the latter seems the more likely.

It has been stated that the polyps in small intestinal polyposis or the Peutz-Jeghers syndrome may show histological evidence of malignant change, although there has been no report of a patient with this disease dying from primary small intestinal carcinoma. A recent report from the Mayo Clinic (Bartholomew *et al.*, 1957) suggests that these polyps are not neoplasms in the generally accepted sense of the word, but are more in the nature of a congenital abnormality or hamartoma. The histological evidence for

this is that the polyps are not composed of one predominant type of proliferating cell. On the contrary all the epithelial cells of the intestinal mucosa, including the simple columnar cells, the goblet cells, and the Paneth cells are represented in the same relationship to one another as they are in the normal mucosa. Furthermore, the stroma consists of bands of smooth muscle fibres, which are related to the epithelial elements of the polyp in the same way as to the normal mucous membrane. If the polyp of the Peutz-Jeghers syndrome is not a neoplasm, but a hamartoma, then it follows that it is not a pre-cancerous condition.

In the wall of the small intestine there is found another cell in which there has recently been a revival of interest. This is the mast cell (Fig. 6), originally described by Ehrlich in 1877. It is a wandering, connective tissue cell filled with granules which stain purple with toluidine blue. These cells have a characteristic distribution in the wall of the small intestine. Most of them are found among the loose connective tissue of the submucosa and serosa in close relationship to the blood vessels. A few may be found in the deeper parts of the lamina propria, close to the muscularis mucosæ, but they are absent from the rest of the mucous membrane. The inner or circular part of the muscularis externa normally contains very few mast cells, but a fair number can usually be found among the fibres of the longitudinal muscle.

It is believed that mast cells secrete heparin (Jorpes, 1946). More recently Riley (1953) and Riley and West (1953, 1955) have shown that they also secrete histamine and the histamine value of a tissue is in proportion to its mast cell content. Certain animals, such as dogs and cattle, develop tumours composed of mast cells and these have a very high histamine

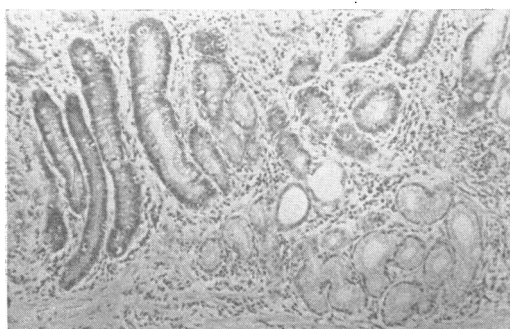


FIG. 5.—Small intestinal mucosa showing chronic inflammatory changes and tubules of pyloric type on the right of the photograph. H. and E. $\times 105$.

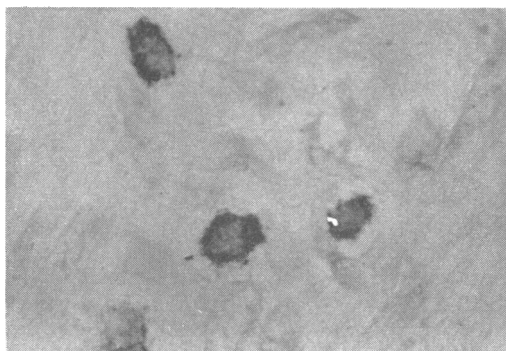


FIG. 6.—Mast cells filled with granules lying in the muscle layers of the small intestine. Toluidine blue. $\times 315$.

content. The injection of histamine causes contraction of smooth muscle and it is tempting to suggest that these cells may be concerned with intestinal motility.

In this paper I have attempted to give an account of the microscopic structure of the normal small intestine together with some remarks on how these appearances may be affected by disease. The large gaps in our knowledge are partly due to the relative inaccessibility of the small intestine to clinical investigation and partly to the fact that pathologists have in the past only had post-mortem material available for study. This is notorious for giving erroneous histological impressions as autolysis of the mucosa occurs very rapidly after death. However, the increasing amount of surgical material available together with the introduction of small intestinal biopsy leads one to hope that the large gaps in our knowledge of small intestinal pathology may be narrowed in future years.

Acknowledgments.—I would like to thank Mr. Norman Mackie for the photomicrographs and Mr. Lloyd Soodeen for technical assistance.

REFERENCES

- BARTHOLOMEW, L. G., DAHLIN, D. G., and WAUGH, J. M. (1957) *Proc. Mayo Clin.*, **32**, 675.
 EHRLICH, P. (1877) *Arch. mikr. Anat.*, **13**, 263.
 FLOREY, H. W. (1958) *General Pathology*. 2nd ed. London.
 JORPES, J. E. (1946) *Heparin in the Treatment of Thrombosis*. 2nd ed. London.
 KERR, A. B., and LENDRUM, A. C. (1936) *Brit. J. Surg.*, **23**, 615.
 PANETH, J. (1888) *Arch. mikr. Anat.*, **31**, 113.
 RILEY, J. F. (1953) *J. Path. Bact.*, **65**, 471.
 —, and WEST, G. B. (1953) *J. Physiol.*, **120**, 528.
 —, — (1955) *J. Path. Bact.*, **69**, 269.
 SCHWALBE, G. (1872) *Arch. mikr. Anat.*, **8**, 92.

Small Intestinal Biopsy: Diagnostic and Research Value

By MARGOT SHINER,¹ M.R.C.S., L.R.C.P., D.C.H.

*Department of Gastroenterology,
 Central Middlesex Hospital, London*

214 peroral small intestinal biopsies were obtained from 193 patients during the past three years and the method employed (Shiner, 1956) has proved safe and reliable. The tube

¹In receipt of a grant from the Medical Research Council.

devised for this purpose (Fig. 1) is a modification of Wood's gastric biopsy tube (Wood *et al.*, 1949) and operates on a similar principle, whereby a knuckle of mucosa is sucked into the aperture at the head-end of the instrument to be cut off by a cylindrical knife within the headpiece which is operated at the tail-end of the instrument. Progress of the headpiece is followed fluoroscopically and biopsy specimens are taken either from the duodenum or upper 12 inches (30 cm.) of jejunum. A recent modification of the headpiece (Fig. 2) by shortening the vertical and horizontal dimensions, together with a longer and more flexible tube, will enable us to biopsy more distal parts of the small intestine.

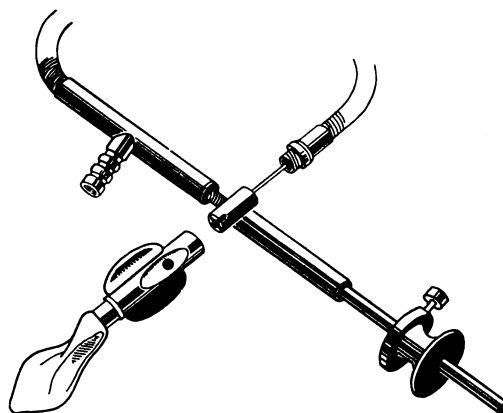


FIG. 1.—Jejunal biopsy tube—original headpiece.

The method thus described can be used as an out-patient procedure, and takes from half to three hours to accomplish. No special preparation of the patient is necessary other than fasting for at least three hours prior to intubation. In special gastroenterological clinics it may be used routinely. Complications so far encountered consisted of melæna of only moderate amount, not requiring blood transfusion, in 3 of the 193 patients biopsied.

Several mucosal specimens are obtained from the small intestine and gastric mucosa can be biopsied at the same time. These specimens vary from 3–10 mm. in length and include full

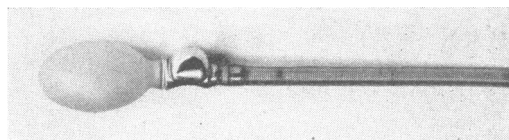


FIG. 2.—Jejunal biopsy tube—modified headpiece.