

Apoptosis Mediates the Decrease in Cellularity during the Transition between Granulation Tissue and Scar

Alexis Desmoulière,*† Mireille Redard,*
Ian Darby,*‡ and Giulio Gabbiani*

From the Department of Pathology,* University of Geneva, Geneva, Switzerland; the Pasteur Institut[†], Lyon, France; and the Wound Foundation of Australia, Department of Surgery,[‡] Heidelberg Repatriation Hospital, Heidelberg West, Victoria, Australia

Granulation tissue formation and contraction is an important step of second intention wound healing. Granulation tissue develops from the connective tissue surrounding the damaged or missing area and its cellular components are mainly small vessel and inflammatory cells as well as fibroblasts and myofibroblasts. As the wound closes and evolves into a scar, there is an important decrease in cellularity; in particular myofibroblasts disappear. The question arises as to which process is responsible for this cellular loss. During a previous investigation on the expression of α -smooth muscle actin in myofibroblasts (Darby I, Skalli O, Gabbiani G, Lab Invest, 1990, 63:21–29), we have observed that in late phases of wound healing, many myofibroblasts show changes compatible with apoptosis and suggested that this type of cell death could be responsible for the disappearance of myofibroblasts. We have now tested this hypothesis by means of morphometry at the electron microscopic level and by *in situ* end labeling of fragmented DNA. Our results indicate that the number of myofibroblastic and vascular cells undergoing apoptosis increases as the wound closes and support the assumption that this is the mechanism of granulation tissue evolution into a scar. The regulation of apoptotic phenomena during wound healing may be important in scar establishment and development of pathological scarring. (Am J Pathol 1995, 146:56–66)

In higher vertebrates, the repair of an open wound (or of an irreversible parenchymal lesion such as myo-

cardial cell death) terminates (with the exception of some fetal situations¹) with the establishment of a permanent scar consisting mainly of extracellular matrix components such as collagen, fibroblasts, and small vessels.^{2,3} The scar evolves from granulation tissue that is comparatively rich in cells. Granulation tissue fibroblasts and small vessel cells derive from similar pre-existing cells in the subcutaneous tissue.⁴ During granulation tissue formation, many fibroblasts acquire morphological and biochemical features of contractile cells;⁵ they have been named myofibroblasts and are considered responsible for granulation tissue contraction⁶ (for review see reference 4). As the wound becomes epithelialized and the scar forms, there is a striking decrease in cellularity, including disappearance of typical myofibroblasts.⁷ The question arises as to what process is responsible for myofibroblast and small vessel cell disappearance. Apoptosis is a form of cell death that has several distinctive features.^{8–10} It is thought to involve the expression of an endogenous endonuclease that cleaves DNA.^{11–15} Typical morphological changes are observed during this process, including condensation and fragmentation of the nucleus and modifications of cytoplasmic organelles.^{9,10} Apoptotic cells are removed through phagocytosis either by macrophages or by neighboring cells. Apoptosis has been described in various physiological and pathological conditions.^{16–20} During a previous investigation on the expression of α -smooth muscle (α -SM) actin in myofibroblasts,⁷ we have observed that in late phases of wound healing many of these cells show signs of apoptosis and suggested that this type of cell death could be responsible for the disappearance of myofibroblasts. In the present study, we have tested this hypothesis by *in situ* end labeling of fragmented

Supported by the Swiss National Science Foundation (Grant 31-30796.91).

Accepted for publication September 16, 1994.

Address reprint requests to Dr. G. Gabbiani, Department of Pathology, University of Geneva, University Medical Center, 1 rue Michel-Servet, 1211 Geneva 4, Switzerland.

DNA^{21,22} and by means of electron microscopy and morphometric analysis. Our results show that the number of apoptotic cells sharply increases as the wound closes, suggesting that apoptosis is the mechanism responsible for the evolution of granulation tissue into a scar.

Materials and Methods

Experimental Procedures

A total of 65 8-week-old female Wistar rats were used in this study. On day 0, rats were anesthetized with an intraperitoneal injection of pentobarbital sodium solution (Nembutal, Abbott Laboratories, North Chicago, IL) and a 2 × 2-cm skin wound was made on the mid-dorsal surface. Granulation tissue samples were collected for DNA cleavage detection, electron microscopy, and immunogold electron microscopy at 2, 4, 6, 7, 8, 10, 12, 16, 20, 25, 30, 35, and 60 days after wounding from animals sacrificed by cervical dislocation after pentobarbital anesthesia (n = 5 per group).

In Situ End Labeling (ISEL) of Fragmented DNA

The characteristic strand breaks seen in the apoptotic process can be detected by a modification of the nick translation procedure, which allows *in situ* DNA labeling of active sites of transcription.²³⁻²⁵ This method relies on the use of a DNA polymerase that acts on the naturally occurring strand breaks seen during apoptosis, allowing the incorporation of a nonisotopically labeled nucleotide.²²

Normal skin and granulation tissue after 2, 4, 6, 7, 8, 10, 12, 16, 20, 25, 30, and 60 days were tested for ISEL of fragmented DNA. Briefly, tissues were fixed in buffered 4% formaldehyde and embedded in paraffin. After deparaffinization and rehydration, tissue sections (4 μ thick) were digested by incubation with 5 μg/ml proteinase K (Life Technologies, Basel, Switzerland) for 15 minutes at room temperature to enable the enzymatic incorporation of nucleotides. Sections were rinsed and incubated in buffer containing 0.01 mmol/L dATP, dCTP, and dGTP (Promega Corp., Madison, WI), 0.01 mmol/L biotin-16-dUTP (Boehringer Mannheim, Rotkreuz, Switzerland) and 8 U/ml *Escherichia coli* DNA polymerase I (Klenow) large fragment (BioConcept, Allschwill, Switzerland). Positive controls consisted of sections previously treated with DNase I to introduce DNA breaks in all nuclei.

After blocking endogenous peroxidase by immersion in distilled water containing 2% H₂O₂, sections were washed, incubated with horseradish peroxidase-conjugated streptavidin (DAKO A/S, Glostrup, Denmark), developed in diaminobenzidine-H₂O₂, and counterstained with hematoxylin. To control the procedure, rat and human large intestine and involuting rat prostate (2 days after castration), known to contain apoptotic cells, were analyzed similarly to experimental specimens.

Electron Microscopy and Morphometry

Tissue samples taken from skin wounds were cut into 1-mm cubes and fixed for 5 hours at room temperature in 2% glutaraldehyde (Merck, Darmstadt, Germany) in 0.1 mol/L cacodylate buffer. They were stained *en bloc* in uranyl maleate for 1 hour, postfixed in osmium tetroxide, dehydrated through graded ethanols, and embedded in Epon 812 (Fluka Chemie, Buchs, Switzerland). Thin sections were cut with a diamond knife, collected on copper grids, and double stained with uranyl acetate and lead citrate before examination in a Philips 400 electron microscope.

For morphometric analysis, thin sections were cut from four blocks chosen at random from each animal in each group. Grids were photographed at a magnification ×1100 with 35-mm positive reversal film (Kodak, Rochester, NY). Fields were randomized by systematically taking the same corner of each window in the grid. Positives of these films were projected onto a test system of points consisting of 168 points on 84 2-cm lines.²⁶ Data were stored and analyzed by using the StepOne morphometry program.²⁷ Total cellularity of the granulation tissue was measured by counting the points falling on any cellular structures; this result is expressed as the mean number of points falling on cells per field. Relative volumes of apoptotic fibroblasts to fibroblasts (Va/Vf) and apoptotic fibroblasts to all cells (Va/Vc) were calculated by counting points that fell on apoptotic fibroblasts, on normal fibroblasts, and on other cell types. Statistical analyses were performed outside the StepOne program. Mean ± SE was calculated for each group and Student's *t*-test was used to evaluate significance of differences between two groups.

Immunogold Electron Microscopy

Samples from wounds were cut into 1-mm cubes and fixed for 5 hours at room temperature in 0.1 mol/L phosphate buffer containing 2% paraformaldehyde

(Merck) and 0.5% glutaraldehyde (Merck). After fixation, tissues were rinsed overnight in 0.1 mol/L phosphate buffer. Dehydration was carried out through graded ethanols in a low temperature embedding device (LTE 020, Balzers Union, Liechtenstein). The final dehydration step in 100% ethanol and the subsequent infiltration with resin were performed at -35 C . Tissue was embedded in Lowicryl K4M resin (Chemische Werke Lowi, Waldkraiburg, Germany) and polymerized for 24 hours in UV light at -35 C and an additional 48 hours in UV light at room temperature. Thin sections were cut with a diamond knife and collected onto formvar-coated nickel grids onto which a thin layer of carbon had been evaporated. All steps were carried out in a solution consisting of 0.1 mol/L phosphate buffer, 0.8% bovine serum albumin, and 0.1% gelatin. Grids were preincubated in this solution containing 5% normal goat serum. The primary antibody was a monoclonal antibody (anti- α -SM-1) specific for α -SM actin²⁸ diluted 1:10 in buffer containing 1% normal goat serum. Grids were incubated in primary antibody for 2 hours, then washed three times for 10 minutes in buffer. The secondary antibody was a goat anti-mouse IgG conjugated to 1-nm gold particles (Aurion, Wageningen, The Netherlands). This antibody was diluted 1:100 in buffer containing 1% normal goat serum. Incubation in the secondary antibody was for 2 hours. Grids were then washed in buffer three times for 15 minutes, in phosphate-buffered saline three times for 5 minutes, and finally rinsed in distilled water. Silver enhancement of the gold staining was performed by the method of Danscher²⁹ for 15 minutes or by the Aurion R-GENT system (Aurion) for 5 minutes. Sections were counterstained for 7 minutes in uranyl acetate and 1 minute in lead citrate before examination.

Results

ISEL of Fragmented DNA

After DNase treatment, all cells were labeled in rat and human large intestine, in involuting rat prostate, and in rat normal skin.

As described previously,²¹ apoptotic cells were detected at the tips of the villi in rat and human large intestine (Figure 1a). The staining was typically confined to clusters of neighboring apical cells whereas other areas of the mucosa remained unstained. In in-

voluting rat prostate, apoptosis was easily recognized in the epithelial lining of prostate acini; 2 days after castration, the fractions of apoptotic cells labeled by ISEL of fragmented DNA (Figure 1b) and those evaluated by morphological criteria were similar.²²

In normal rat skin, no apoptotic cells were generally noted (Figure 1c). However, few cells present in the uppermost layer of the stratified epithelium were sometimes labeled by ISEL of fragmented DNA. Apoptotic cells were observed frequently between the lower third and the upper two-thirds of the hair follicle. The exact nature of these labeled cells remains to be defined.

During the first days after wounding, many inflammatory cells in the scab appeared apoptotic. Starting from 7 days after wounding, the scab was no longer apparent. In our model,⁷ the wound is practically closed by 15 days.

In the wall of newly formed vessels in granulation tissue, isolated apoptotic cells appeared at 8 days and a maximum of labeled cells was observed between 16 and 25 days (Table 1). Apoptotic changes were seen in both pericytes and endothelial cells.

Positive apoptotic staining in myofibroblasts appeared, albeit exceptionally, at 12 days when α -SM actin expression was maximal (Figure 1 and Table 1). The frequency of apoptotic myofibroblasts and vascular cells measured as a percentage of labeled cells increased greatly by 16 days with a maximum at 20 days (Table 1 and Figure 1e, f). We then observed a progressive decrease of labeled cells (Figure 1g, h) and at 60 days, labeled cells were absent (Table 1).

Electron Microscopy and Morphometry

In granulation tissue after 2, 4, 6, 8, and 12 days, apoptotic cells were only exceptionally present. In 12-day-old and 16-day-old granulation tissue, typical myofibroblasts containing prominent microfilament bundles with dense bodies were observed. Apoptotic cells became evident at 16, 20, 25, 30, and 35 days. The main criteria used for the definition of apoptotic cells were margination and condensation of chromatin, enlargement of endoplasmic reticulum cisternae, and convoluted cell surface. In 16-day-old granulation tissue early morphological changes associated with apoptosis such as margination of chromatin and dilatation of endoplasmic reticulum cisternae were

Figure 1. Identification of apoptotic cells in rat tissues by ISEL of fragmented DNA. **a:** Large intestine. Apoptotic cells are detected at the tip of a villus. **b:** Prostate 2 days after castration. Several apoptotic bodies are scattered within the epithelium. **c:** Normal skin. No apoptotic cells are detected. **d:** 12-day-old wound tissue. **e:** 16-day-old wound tissue. **f:** 20-day-old wound tissue. **g:** 25-day-old wound tissue. **h:** 30-day-old wound tissue. At 12 days, when α -SM actin expression is maximal, there is no positive staining for apoptotic cells, after which the number of labeled cells increases with a maximum at 20 days (f) and decreases thereafter. Magnification, $\times 1000$.

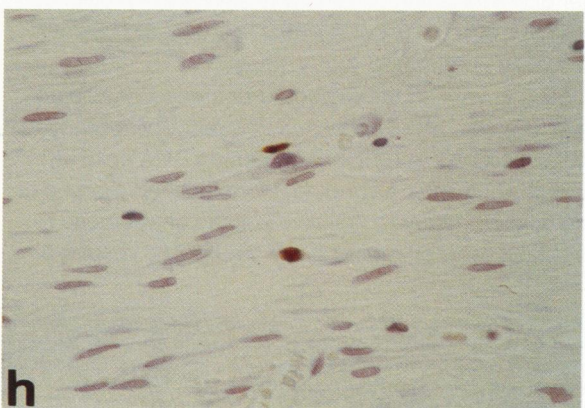
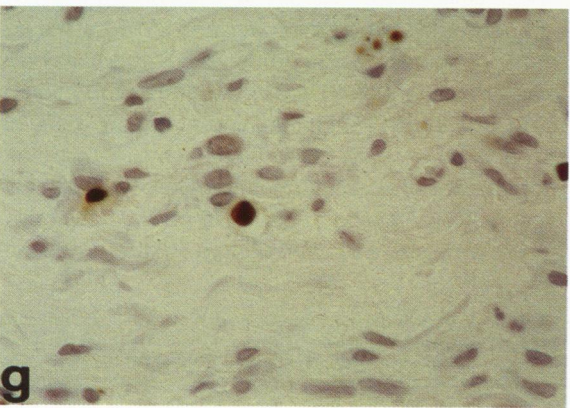
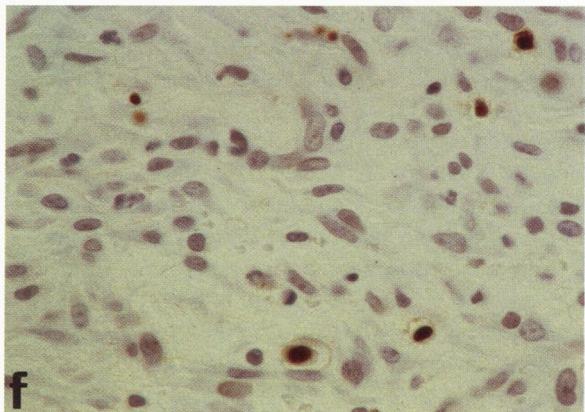
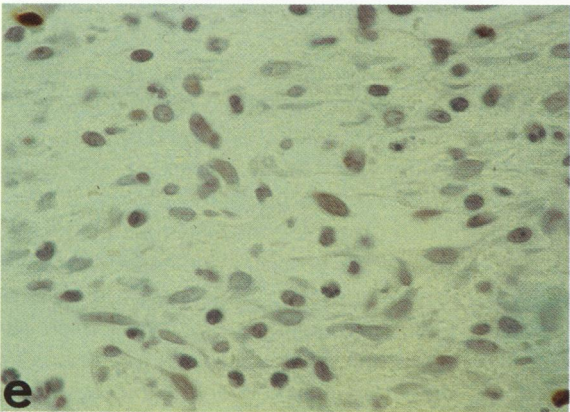
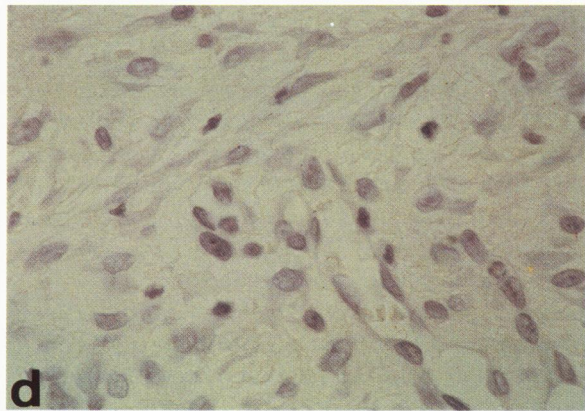
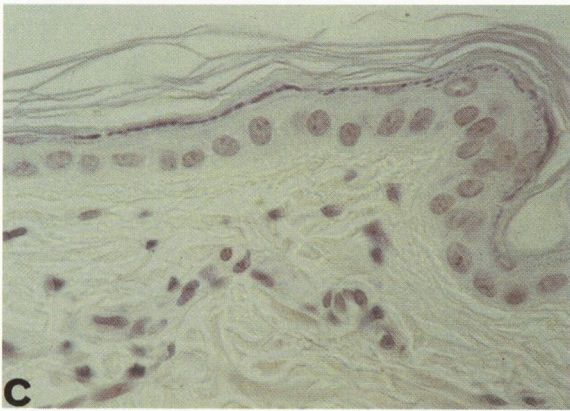
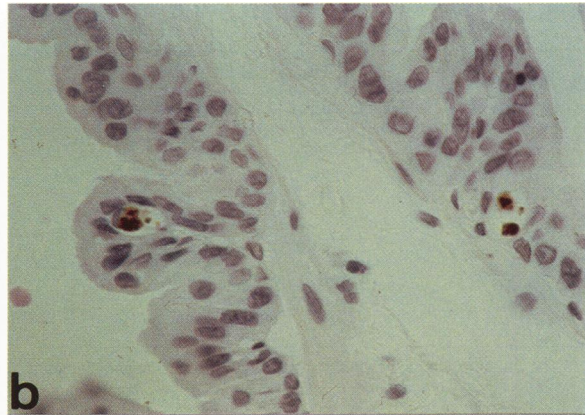
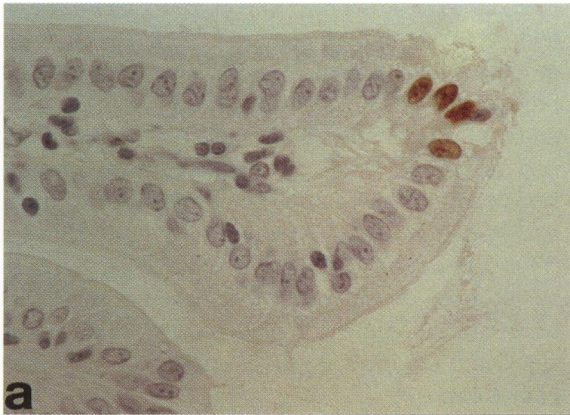

Table 1. Evaluation of Cells Showing ISEL of Fragmented DNA*

Days after wounding	Granulation tissue	
	Fibroblasts	Vascular cells
7	-	-
8	-	+/-
10	-	+/-
12	+/-	+
16	++	++
20	+++	++
25	++	++
30	+/-	+
60	-	-

* The staining with ISEL method was observed blindly and independently by two researchers and classified as: -, no staining; +/-, staining in less than 3% of cells; +, staining in 3 to 6% of cells; ++, staining in 6 to 9% of cells; +++, staining in 9 to 12% of cells.

observed. These changes became more evident 20 and 25 days after wounding (Figure 2a, b) and were accompanied by signs of later steps of apoptotic death such as chromatin condensation and formation of nuclear fragments surrounded or not by a double membrane (Figure 2c). Progressive degeneration of cytoplasmic organelles, such as mitochondria, with a concentric (onion skin) pattern of membrane organization were observed (Figure 2c). Macrophages containing phagolysosomes were seen near fibroblastic apoptotic cells, suggesting that this is the major route of removal of apoptotic bodies (Figure 2d). In addition, capillaries with endothelial cells undergoing apoptosis (Figure 3a) and sometimes containing platelet thrombi (Figure 3b) were observed.

Morphometric analysis of granulation tissue was done at 12, 20, 25, 35, and 60 days after wounding. It showed a significant reduction in tissue cellularity compared with the cellularity at 12 days, as indicated by a decrease in the number of points that fall on cells. At 12 days 46.8 ± 2.58 points per field fell on cellular structures, whereas at 20 days this figure was 32.38 ± 5.9 ; at 25 days, 27.58 ± 1.4 ; at 35 days, 25.12 ± 1.6 ; and at 60 days, 20.07 ± 2.5 (see Figure 4a). The number of points falling on cells was significantly lower at 20 ($P < 0.02$), 25 ($P < 0.01$), 35 ($P < 0.01$), and 60 days ($P < 0.01$) compared with 12 days.

Having verified the expected decrease in cellularity and in view of the increased frequency of apoptotic cells observed by ISEL of fragmented DNA at 16, 20, and 25 days after wounding, we examined morphometrically whether the relative volume of apoptotic fibroblasts was changing accordingly. The results of

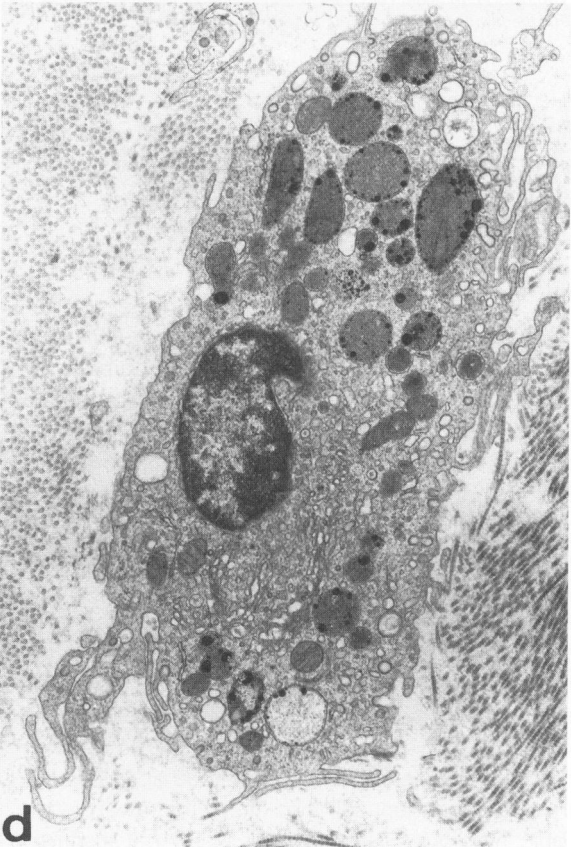
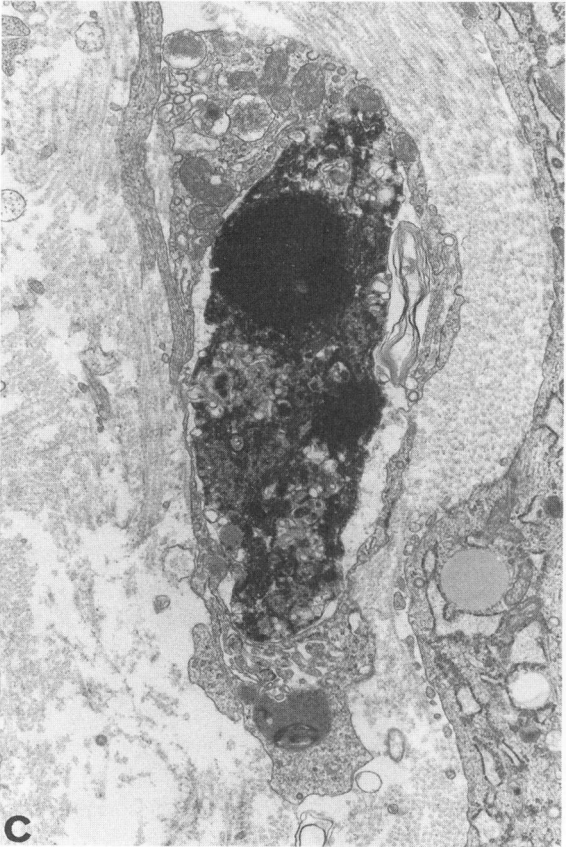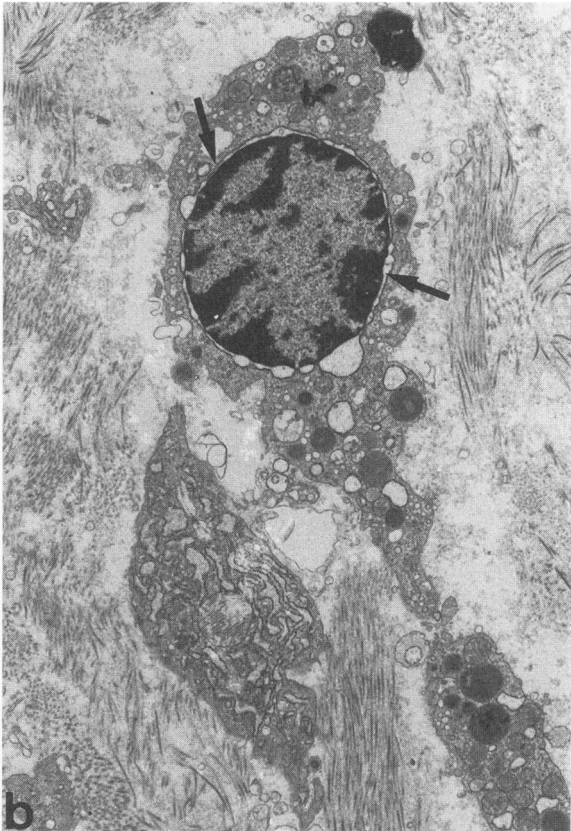
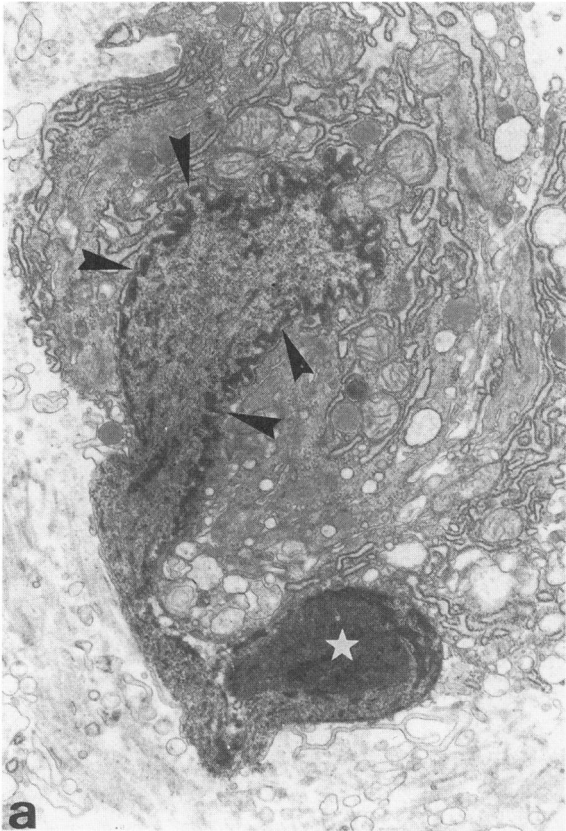
morphometry are shown in Figure 4b and c. Va/Vf (Figure 4b) showed an increase from $0.115 \pm 0.115\%$ at 12 days to $4.93 \pm 0.67\%$ at 20 days. At 25 days the proportion was $5.9 \pm 1.11\%$; at 35 days, $1.36 \pm 0.5\%$; and at 60 days, $0.92 \pm 0.1\%$. Statistical analyses carried out for each time point showed that there was a significant difference between 12-day wound tissue and 20-day ($P < 0.01$), 25-day ($P < 0.01$), and 35-day ($P < 0.1$) wound tissues. The small difference observed between 20 and 25 days was not significant ($P < 0.2$), although the diminution after 25 days was significant (25 days versus 35 days, $P < 0.01$; see Figure 4b).

Morphometry was also used to measure Va/Vc to give an indication of its frequency regardless of the tissue cell composition (Figure 4c). Once again at 12 days the volume of apoptotic cells present in the tissue was very small. There was a significant increase at 20 days ($P < 0.01$) and at 25 days ($P < 0.05$) compared with 12-day tissue. At 35 days the volume of apoptotic fibroblasts in the tissue was still significantly different from that at 12 days ($P < 0.05$). However, there was no significant difference between 20 and 35 days or 25 and 35 days.

Immunogold Electron Microscopy

The time course of α -SM actin appearance in wound fibroblasts has been reported in detail elsewhere.⁷ Twelve days after wounding, a large proportion of fibroblasts in the wound tissue expressed α -SM actin. These cells showed the typical morphology of myofibroblasts with prominent microfilament bundles in the cytoplasm. This positivity decreased with time and at 20 and 25 days, only a few positive cells remained.⁷ Fibroblastic cells displaying both microfilament bundles containing α -SM actin and apoptotic features were frequently observed (Figure 5a-c). These cells showed various degrees of degenerative changes and clear staining with anti- α SM-1 at the periphery (Figure 5a). The proportion of apoptotic cells was always higher compared with the proportion of cells showing α -SM actin staining, suggesting that the expression of α -SM actin decreases slightly before appearance of apoptotic features. Cells with phagolysosomes containing α -SM-actin-positive microfilaments were also observed (Figure 5d). Pericytes with

Figure 2. Transmission electron micrographs showing different features of apoptotic fibroblasts (a, b, c) and a macrophage (d) with numerous phagolysosomes 20 and 25 days after wounding. In fibroblasts undergoing apoptosis, early (arrowheads) and more advanced (arrows) degrees of chromatin condensation are visible (a and b); cytoplasmic vacuoles and convoluted cell surface are also present. Note that in (a) the nucleus appears in part extruded from the cytoplasm (*). In (c) the chromatin is highly condensed and the nuclear membrane has disappeared. Magnification, $\times 10,000$ (a), $\times 4800$ (b), $\times 9300$ (c), $\times 9000$ (d).



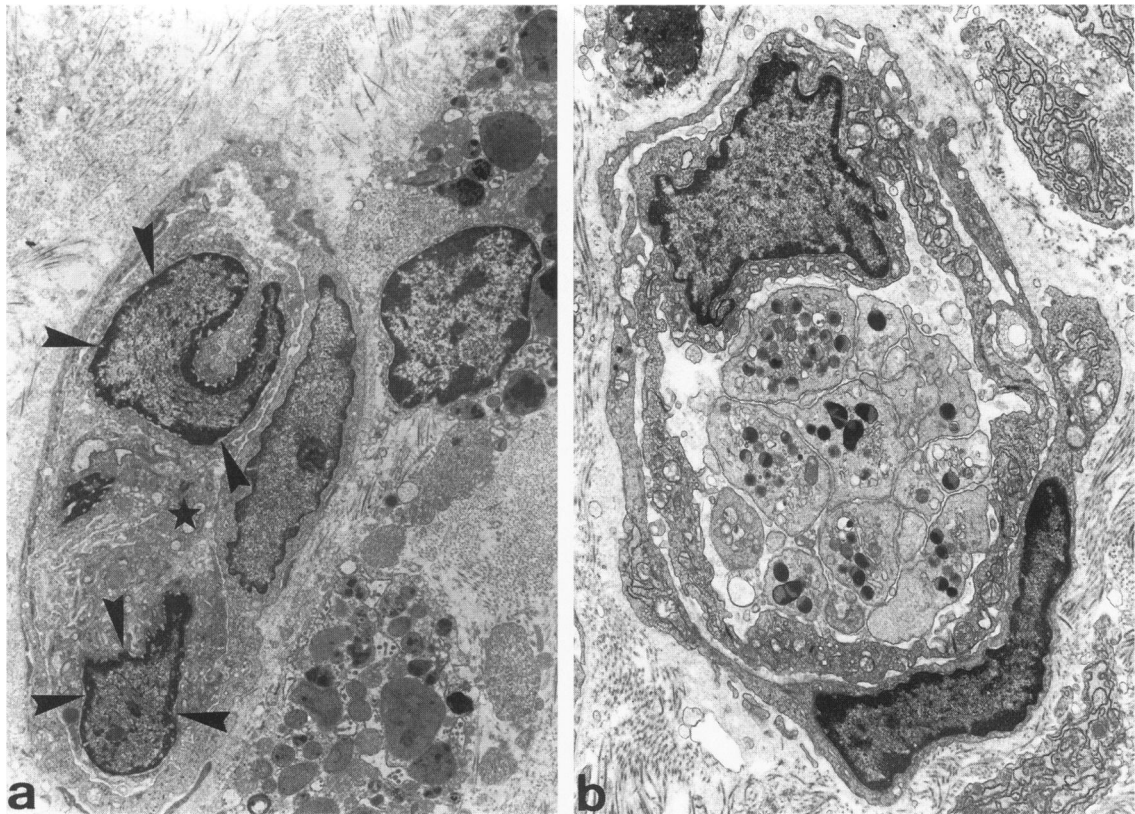


Figure 3. Transmission electron micrographs showing damaged small vessels of granulation tissue 20 days after wounding. In (a) the small vessel (*) contains endothelial cells with initial apoptotic changes, such as chromatin condensation (arrowheads); in (b) a platelet thrombus is present within the lumen. Magnification, $\times 3900$ (a), $\times 5800$ (b).

both apoptotic features and α -SM actin expression as well as apoptotic endothelial cells were also observed.

Discussion

It is well established that the evolution of granulation tissue into scar tissue implies a massive decrease in cellularity, notably involving the disappearance of fibroblasts, endothelial cells, and pericytes.^{2,3} When granulation tissue cells are not eliminated, there is development of pathological scarring, ie, hypertrophic scar and keloid, which are distinct clinical^{30,31} and pathological^{32,33} entities, both characterized by a high degree of cellularity. Our results suggest that the reduction in cell number observed under our experimental conditions is achieved to a great extent through apoptosis. Whether apoptosis, or perhaps the lack of apoptosis, plays a role in the establishment of hypertrophic scar and keloid remains to be explored. Previous studies have detected apoptosis in hormone-dependent cell lines after withdrawal of the trophic hormone. These studies used gel electro-

phoresis to evaluate DNA degradation into characteristic fragments.²⁰ In these studies DNA degradation was detectable probably due to the high proportion (up to 50%) of cells dying synchronously. We were unable to consistently detect DNA degradation by electrophoresis on agarose gels (data not shown) probably due to the relatively small proportion of dead or dying cells at any one time. Indeed we have found a maximum of approximately 12% of apoptotic cells at any one time by means of both ISEL of fragmented DNA and morphometric analysis of electron micrographs. However, the techniques we have used have the advantage of precisely localizing apoptotic cells. Typical features of apoptosis, ie, condensation of chromatin at the nuclear periphery, can be observed without activation of endonuclease.³⁴ Different markers of fibroblastic cell death have been described in the literature.^{35,36} It has been suggested that clusterin (TRPM-2, SGP-2) is a marker of apoptotic cells;³⁷ however, in additional experiments, we have detected clusterin expression only in hair follicles (data not shown). We think, as suggested by others,³⁸⁻⁴⁰ that clusterin is not exclusively a marker

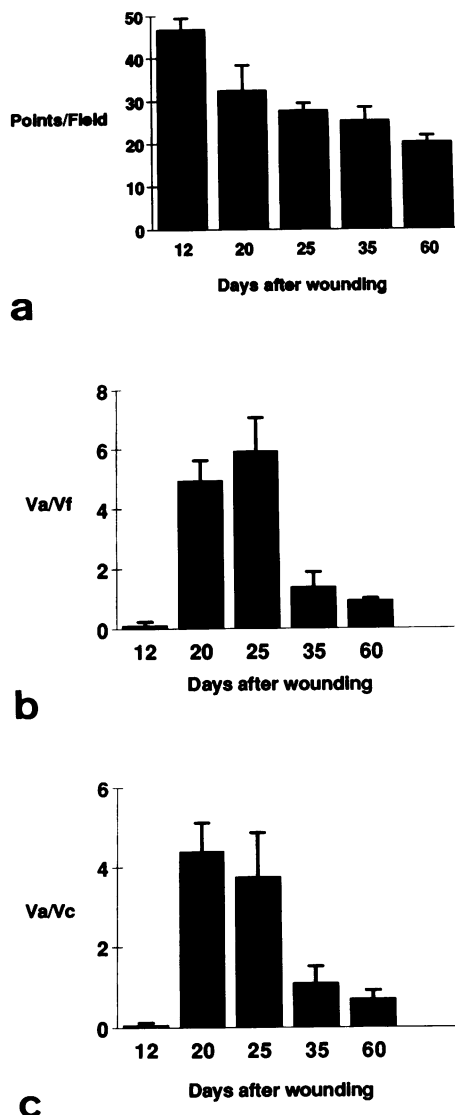


Figure 4. Morphometric evaluation of fibroblast apoptotic changes. **a:** Tissue cellularity at different times after wounding. Columns represent the mean \pm SE of the number of points per field that fell on cells. **b:** Va/Vf at various times after wounding. There is a significant increase in the proportion of apoptotic fibroblasts at 20 and 25 days after wounding. **c:** Va/Vc at various times after wounding. An increase in the proportion of apoptotic cells in the wound at 20 and 25 days is evident.

of cell death. Furthermore, French et al⁴¹ have recently shown that the expression of clusterin may be associated with cell survival within tissues regressing as a consequence of programmed cell death.

Our data indicate that apoptosis of granulation tissue cells takes place essentially after wound closure and affects target cells consecutively rather than producing a single wave of cell disappearance. This observation is in line with the gradual resorption of granulation tissue after wound closure and with the observation that dead cells are digested by macro-

phages and surrounding cells. It is well known that covering granulation tissue with a thick skin transplant or flap (including subcutaneous tissue) results in a rapid (approximately 48 hours) resorption.⁴² It would be of interest to determine whether this result is obtained through a rapid and massive apoptosis of granulation tissue cells.

During the healing of an open wound, fibroblasts gradually acquire the expression of α -SM actin,⁷ a well accepted marker of SM cell differentiation.⁴³ These modified fibroblasts or myofibroblasts are likely to be involved in wound contraction and disappear when the wound is closed.^{7,44} Our results show that they disappear through apoptosis and suggest that under normal conditions the process of myofibroblast differentiation ends with the death of these cells. Thus, myofibroblasts could be considered terminally differentiated cells.

Cell death and particularly apoptosis plays a key role in the control of normal and pathological tissue growth.⁴⁵⁻⁴⁷ Recently, Polunovsky et al⁴⁸ have studied the role of mesenchymal cell death in lung remodeling after acute injury. During elimination of intra-alveolar granulation tissue, the mode of endothelial cell death is apoptosis. The mechanism of fibroblast death is not only morphologically distinct from necrosis but also different from typical apoptosis.

The question that remains to be answered is what the stimulus is that leads to apoptosis during wound healing. Recently, gene products regulating cell death have been identified.⁴⁹⁻⁵⁴ In fibroblasts, the c-Myc protein⁵⁵ and interleukin-1 β -converting enzyme, the mammalian homologue of the *Caenorhabditis elegans* cell death gene *ced-3*,⁵⁶ have been shown to induce apoptosis. In turn, it has been shown that Bcl-2 is capable of blocking apoptosis (for review, see reference 57); however, fibroblasts lack Bcl-2 expression as assessed by antibody staining (58 and unpublished observation). A possible mechanism for apoptosis induction could be via direct action and/or withdrawal of cytokines or growth factors.^{34,59-61} Several factors have been shown to increase the rate of wound healing, including platelet-derived growth factor,⁶² transforming growth factor- β ,^{63,64} transforming growth factor- α ,⁶⁵ and tumor necrosis factor⁶⁶ (for review see reference 67). These factors may be present in the normally healing wound, released by platelets and inflammatory cells. It is probable that as the wound resolves, there is a decrease in the levels of these factors. A possible explanation for the death of at least a subpopulation of myofibroblasts and vascular cells would be that these are growth factor dependent. Alternatively, factors selectively causing the death of fibroblastic and vas-

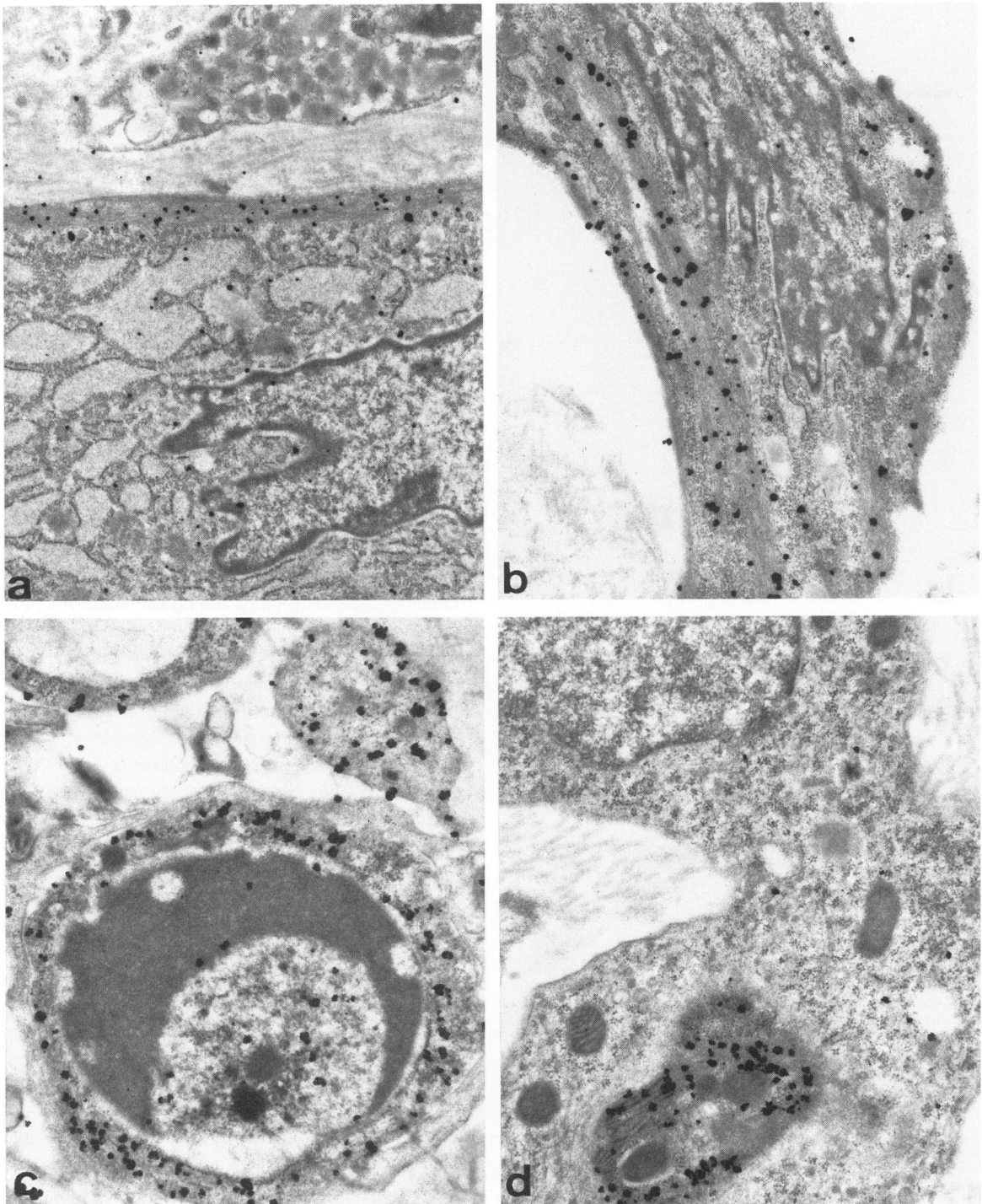


Figure 5. Immunogold electron microscopy with anti- α SM-1 on granulation tissue cells 20 and 25 days after wounding. Myofibroblasts positive for α -SM actin show dilated cisternae of rough endoplasmic reticulum (a) and various degrees of chromatin condensation (b, c). A phagocytic cell with an inclusion containing α -SM-actin-positive material is illustrated in d. Magnification, $\times 14,300$ (a, b), $\times 18,700$ (c), $\times 17,000$ (d).

cular cells could be liberated after epithelialization has been completed. Additional work is necessary to identify these hypothetical factors, but it appears that apoptosis is the mechanism through which vascular and fibroblastic cells are gradually eliminated from a

normally healing granulation tissue. Studies along these lines will be useful for the understanding of normal and pathological wound healing and possibly for modifying the evolution of keloid and hypertrophic scar.

Acknowledgments

We thank Mr. P. Henchoz for excellent technical assistance, Mr. K. Grandchamp for help in statistical analysis, Mr. E. Denkinger and Mr. J. C. Rumbeli for photographic work and Mrs. G. Gillioz for typing the manuscript.

References

1. Adzick NS, Longaker MT: Scarless fetal wound healing: therapeutic implications. *Ann Surg* 1992, 215:3-7
2. Martinez-Hernandez A: Repair, regeneration, and fibrosis. Pathology. Edited by E Rubin and JL Farber. Philadelphia, JB Lippincott, 1988, pp 66-95
3. Cotran RS, Kumar V, Robbins SL: Robbins Pathologic Basis of Disease. Philadelphia, WB Saunders, 1989, pp 39-86
4. Schürch W, Seemayer TA, Gabbiani G: Myofibroblast. *Histology for Pathologists*. Edited by SS Sternberg. New York, Raven Press, 1992, pp 109-144
5. Gabbiani G, Ryan GB, Majno G: Presence of modified fibroblasts in granulation tissue and their possible role in wound contraction. *Experientia* 1971, 27:549-550
6. Grinnell F: Fibroblasts, myofibroblasts, and wound contraction. *J Cell Biol* 1994, 124:401-404
7. Darby I, Skalli O, Gabbiani G: α -Smooth muscle actin is transiently expressed by myofibroblasts during experimental wound healing. *Lab Invest* 1990, 63:21-29
8. Kerr JFR, Wyllie AH, Currie AR: Apoptosis: a basic biological phenomenon with wide-ranging implications in tissue kinetics. *Br J Cancer* 1972, 26:239-257
9. Wyllie AH, Kerr JFR, Currie AR: Cell death: the significance of apoptosis. *Int Rev Cytol* 1980, 68:251-306
10. Searle J, Kerr JFR, Bishop CJ: Necrosis and apoptosis: distinct modes of cell death with fundamentally different significance. *Pathol Annu* 1982, 17(part 2):229-259
11. Wyllie AH: Glucocorticoid-induced thymocyte apoptosis is associated with endogenous endonuclease activation. *Nature* 1980, 284:555-556
12. Duke RC, Chervenak R, Cohen JJ: Endogenous endonuclease-induced DNA fragmentation: an early event in cell-mediated cytotoxicity. *Proc Natl Acad Sci USA* 1983, 80:6361-6365
13. Arends MJ, Morris RG, Wyllie AH: Apoptosis: the role of the endonuclease. *Am J Pathol* 1990, 136:593-608
14. Peitsch MC, Polzar B, Stephan H, Crompton T, MacDonald HR, Mannherz HG, Tschopp J: Characterization of the endogenous deoxyribonuclease involved in nuclear DNA degradation during apoptosis (programmed cell death). *EMBO J* 1993, 12:371-377
15. Peitsch MC, Mannherz HG, Tschopp J: The apoptosis endonucleases: cleaning up after cell death? *Trends Cell Biol* 1994, 4:37-41
16. Don MM, Ablett G, Bishop CJ, Bundesen PG, Donald KJ, Searle J, Kerr JFR: Death of cells by apoptosis following attachment of specifically allergized lymphocytes *in vitro*. *Aust J Exp Biol Med Sci* 1977, 55:407-417
17. Russell JH, Masakowski V, Rucinsky T, Phillips G: Mechanisms of immune lysis. III. Characterization of the nature and kinetics of the cytotoxic T lymphocyte-induced nuclear lesion in the target. *J Immunol* 1982, 128:2087-2094
18. Duvall E, Wyllie AH: Death and the cell. *Immunol Today* 1986, 7:115-119
19. Yamada T, Ohyama H: Radiation-induced interphase death of rat thymocytes is internally programmed (apoptosis). *Int J Radiat Biol* 1988, 53:65-75
20. Rotello RJ, Hocker MB, Gerschenson LE: Biochemical evidence for programmed cell death in rabbit uterine epithelium. *Am J Pathol* 1989, 134:491-495
21. Gravielli Y, Sherman Y, Ben-Sasson SA: Identification of programmed cell death *in situ* via specific labeling of nuclear DNA fragmentation. *J Cell Biol* 1992, 119:493-501
22. Wijsman JH, Jonker RR, Keijzer R, Van de Velde CJH, Cornelisse CJ, Van Dierendonck JH: A new method to detect apoptosis in paraffin sections: *in situ* end-labeling of fragmented DNA. *J Histochem Cytochem* 1993, 41:7-12
23. Adolph S, Hameister H: *In situ* nick translation of metaphase chromosomes with biotin-labelled d-UTP. *Hum Genet* 1985, 69:117-121
24. Murer-Orlando ML, Peterson AC: *In situ* nick translation of human and mouse chromosomes detected with biotinylated nucleotide. *Exp Cell Res* 1985, 157:322-334
25. Ansari B, Coates PJ, Greenstein BD, Hall PA: *In situ* end-labelling detects DNA strand breaks in apoptosis and other physiological and pathological states. *J Pathol* 1993, 170:1-8
26. Weibel ER: *Practical Methods for Biological Morphometry*. New York, Academic Press, 1979
27. Humbert D, Cruz-Orive LM, Weibel ER, Gehr P, Burri PH, Hoppeler H: STEPone - an interactive program for manual stereology. *Acta Stereol* 1990, 9:111-124
28. Skalli O, Ropraz P, Trzeciak A, Benzionana G, Gillesen D, Gabbiani G: A monoclonal antibody against α -smooth muscle actin: a new probe for smooth muscle differentiation. *J Cell Biol* 1986, 103:2787-2796
29. Danscher G: Localization of gold in biological tissue: a photochemical method for both light and electron microscopy. *Histochemistry* 1981, 71:81-88
30. Kischer CW, Shetlar MR, Chvapil M: Hypertrophic scars and keloids: a review and new concept concerning their origin. *Scand Electron Microsc* 1982, 4:1699-1713
31. Rockwell WB, Cohen IK, Ehrlich HP: Keloids and hypertrophic scars: a comprehensive review. *Plast Reconstr Surg* 1989, 84:827-837
32. Blackburn WR, Cosman C: Histologic basis of keloid and hypertrophic scar differentiation. *Arch Pathol* 1966, 82:65-71
33. Ehrlich HP, Desmoulière A, Diegelmann RF, Cohen IK, Compton CC, Garner WL, Kapanci Y, Gabbiani G: Morphological and immunochemical differences between keloid and hypertrophic scar. *Am J Pathol* 1994, 145:105-113
34. Oberhammer F, Bursh W, Tiefenbacher R, Fröschl G,

- Pavelka M, Purchio T, Schulte-Hermann R: Apoptosis is induced by transforming growth factor- β 1 within 5 hours in regressing liver without significant fragmentation of the DNA. *Hepatology* 1993, 18:1238-1246
35. Bayreuther K, Francz PI, Rodemann HP: Fibroblasts in normal and pathological terminal differentiation, aging, apoptosis and transformation. *Arch Gerontol Geriatr* 1992, Suppl 3:47-74
36. Hébert L, Pandey S, Wang E: Commitment to cell death is signaled by the appearance of a terminin protein of 30 kDa. *Exp Cell Res* 1994, 210:10-18
37. Buttyan R, Olsson CA, Pintar J, Chang C, Bandyk M, Ng PY, Sawczuk IS: Induction of the *TRPM-2* gene in cells undergoing programmed death. *Mol Cell Biol* 1989, 9:3473-3481
38. Jenne DE, Tschopp J: Clusterin: the intriguing guises of a widely expressed glycoprotein. *Trends Biochem Sci* 1992, 17:154-159
39. Fritz IB, Murphy B: Clusterin: insights into a multifunctional protein. *Trends Endocrinol Metab* 1993, 4:41-45
40. Rosenberg ME, Dvergsten J, Correa-Rotter R: Clusterin: an enigmatic protein recruited by diverse stimuli. *J Lab Clin Med* 1993, 121:205-214
41. French LE, Wohlwend A, Sappino AP, Tschopp J, Schifferli JA: Human clusterin gene expression is confined to surviving cells during *in vitro* programmed cell death. *J Clin Invest* 1994, 93:877-884
42. Rudolph R: Inhibition of myofibroblasts by skin grafts. *Plast Reconstr Surg* 1979, 63:473-480
43. Gabbiani G, Schmid E, Winter S, Chaponnier C, de Chastonay C, Vandekerckhove J, Weber K, Franke WW: Vascular smooth muscle cells differ from other smooth muscle cells: predominance of vimentin filaments and a specific α -type actin. *Proc Natl Acad Sci USA* 1981, 78:298-302
44. Clark RAF: Regulation of fibroplasia in cutaneous wound repair. *Am J Med Sci* 1993, 306:42-48
45. Bursch W, Oberhammer F, Schulte-Hermann R: Cell death by apoptosis and its protective role against disease. *Trends Pharmacol Sci* 1992, 13:245-251
46. Cohen JJ: Apoptosis: the physiologic pathway of cell death. *Hosp Prac* 1993, 15:35-43
47. Kerr JFR: Apoptosis: its significance in cancer and cancer therapy. *Cancer* 1994, 73:2013-2026
48. Polunovsky VA, Chen B, Henke C, Snover D, Wendt C, Ingbar DH, Bitterman PB: Role of mesenchymal cell death in lung remodeling after injury. *J Clin Invest* 1993, 92:388-397
49. Evans VG: Multiple pathways to apoptosis. *Cell Biol Int* 1993, 17:461-476
50. Lee S, Christakos S, Small MB: Apoptosis and signal transduction: clues to a molecular mechanism. *Current Opin Cell Biol* 1993, 5:286-291
51. Schwartzman RA, Cidlowski JA: Apoptosis. The biochemistry and molecular biology of programmed cell death. *Endocr Rev* 1993, 14:13-151
52. White E: Death-defying acts: a meeting review on apoptosis. *Genes Dev* 1993, 7:2277-2284
53. Williams GT, Smith CA: Molecular regulation of apoptosis: genetic controls on cell death. *Cell* 1993, 74:777-779
54. Martin SJ, Green DR, Cotter TG: Dicing with death: dissecting the components of the apoptosis machinery. *Trends Biochem Sci* 1994, 19:26-30
55. Evan GI, Wyllie AH, Gilbert CS, Littlewood TD, Land H, Brooks M, Waters CM, Penn LZ, Hancock DC: Induction of apoptosis in fibroblasts by c-Myc protein. *Cell* 1992, 69:119-128
56. Miura M, Zhu H, Rotello R, Hartweg EA, Yuan J: Induction of apoptosis in fibroblasts by IL-1 β -converting enzyme, a mammalian homolog of the *C. elegans* cell death gene *ced-3*. *Cell* 1993, 75:653-660
57. Reed JC: Bcl-2 and the regulation of programmed cell death. *J Cell Biol* 1994, 124:1-6
58. Hockenbery DM, Zutter M, Hickey W, Nahm M, Korsmeyer SJ: BCL2 protein is topographically restricted in tissues characterized by apoptotic cell death. *Proc Natl Acad Sci USA* 1991, 88:6961-6965
59. Laster SM, Wood JG, Gooding LR: Tumor necrosis factor can induce both apoptic and necrotic forms of cell lysis. *J Immunol* 1988, 141:2629-2634
60. Robaye B, Mosselmans R, Fiers W, Dumont JE, Garland P: Tumor necrosis factor induces apoptosis (programmed cell death) in normal endothelial cells *in vitro*. *Am J Pathol* 1991, 138:447-453
61. Moulton BC: Transforming growth factor- β stimulates endometrial stromal apoptosis *in vitro*. *Endocrinology* 1994, 134:1055-1060
62. Pierce GF, Mustoe TA, Senior RM, Reed J, Griffin GL, Thomason A, Deuel TF: *In vivo* incisional wound healing augmented by platelet-derived growth factor and recombinant c-sis gene homodimeric proteins. *J Exp Med* 1988, 167:974-987
63. Mustoe TA, Pierce GF, Thomason A, Gramates P, Sporn MB, Deuel TF: Accelerated healing of incisional wounds in rats induced by transforming growth factor- β . *Science* 1987, 237:1333-1336
64. Beck LS, DeGuzman L, Lee WP, Xu Y, Siegel MW, Amento EP: One systemic administration of transforming growth factor- β 1 reverses age- or glucocorticoid-impaired wound healing. *J Clin Invest* 1993, 92:2841-2849
65. Schultz GS, White M, Mitchell R, Brown G, Lynch J, Twardzik DR, Todaro GJ: Epithelial wound healing enhanced by transforming growth factor- α and vaccinia growth factor. *Science* 1987, 235:350-352
66. Mooney DP, O'Reilly M, Gamelli RL: Tumor necrosis factor and wound healing. *Ann Surg* 1990, 211:124-129
67. Martin P, Hopkinson-Wooley J, McCluskey J: Growth factors and cutaneous wound repair. *Prog Growth Factor Res* 1992, 4:25-44