

# Histogenesis of the Human Adrenal Medulla

## An Evaluation of the Ontogeny of Chromaffin and Nonchromaffin Lineages

Mark J. Cooper,\* Grover M. Hutchins,†  
and Mark A. Israel\*

From the Molecular Genetics Section,\* Pediatric Branch,  
National Cancer Institute, National Institutes of Health,  
Bethesda, and the Department of Pathology,† The Johns  
Hopkins Medical Institutions, Baltimore, Maryland

*The authors previously evaluated the expression of a panel of chromaffin-related genes during histogenesis of the human adrenal medulla. In these studies, chromaffin and nonchromaffin adrenal neuroblasts were identified. To better characterize these nonchromaffin neuroblasts, the authors evaluated two additional markers: HNK-1, an antibody recognizing the migratory neural crest cell; and S-100, a protein expressed by sustentacular cells of the adrenal medulla. HNK-1 immunoreactivity was found in both chromaffin and nonchromaffin cell types at different times during development, marking the nonchromaffin lineage during the second trimester of gestation as well as the chromaffin lineage in the neonatal period. In addition, S-100 expression was noted in some nonchromaffin neuroblasts, and sustentacular cells were first identified at approximately 28 weeks of gestational age. These data suggest a model of human adrenal medullary histogenesis that incorporates the chromaffin, ganglionic, and sustentacular lineages known to constitute the adult adrenal medulla. (Am J Pathol 1990, 137:605-615)*

The histogenesis of human organs from multipotent precursor cells undoubtedly requires complex and sensitively regulated control mechanisms that direct the differentiation of primitive cells along the different cellular lineages that constitute adult tissues. During organogenesis, progenitor cells from multiple lineages simultaneously proliferate and differentiate to generate the complex structural and functional organization that characterizes differentiated tissues. The adrenal medulla, a

neuroendocrine tissue that is enveloped by the mesodermally derived adrenal cortex,<sup>1</sup> provides a model system to evaluate the expression of genes that mark different cellular lineages during tissue development.

The adrenal medulla is composed of three different neural crest-derived lineages: chromaffin,<sup>2-4</sup> ganglionic,<sup>5-7</sup> and sustentacular.<sup>8</sup> Chromaffin cells constitute most of the adult adrenal medulla<sup>9</sup> and release catecholamines<sup>10,11</sup> and possibly neuropeptides<sup>10,12,13</sup> into the circulation. The adrenal medulla also contains a small number of ganglion cells interspersed among the chromaffin cells.<sup>5-7</sup> Ganglion cells can be identified by their large size, and electron micrographs of adrenal sections have identified neuronal processes associated with these cells.<sup>5</sup> The adult adrenal medulla also is composed of sustentacular cells,<sup>8</sup> Schwann-like cells that are closely associated with adrenal chromaffin cells. The adrenal medullary sustentacular cell is distinguished by its expression of the S-100 protein as well as its characteristic electron microscopic appearance.<sup>8</sup>

In previous studies, we have identified chromaffin and putative nonchromaffin precursor cells during development of the human adrenal medulla.<sup>14,15</sup> While evaluating the expression of chromaffin-related genes in a panel of fetal and neonatal adrenal glands, we delineated successive stages during the chromaffin maturation of adrenal neuroblasts by the sequential expression of tyrosine hydroxylase (TH), the rate-limiting enzyme in catecholamine biosynthesis<sup>16</sup>; chromogranin A (CGA), a major constituent of the neurosecretory granule<sup>9</sup>; pG2, an anonymous chromaffin-related gene that we previously cloned from a pheochromocytoma cDNA library<sup>17</sup>; and beta-2-microglobulin (B2M), the light chain component of the class I major histocompatibility complex.<sup>18</sup> In addition to adrenal chromaffin cells, a population of adrenal neuroblasts that did not express any of these markers was found in some adrenal specimens until 24 weeks of gestational age.

---

Accepted for publication April 19, 1990.

Address reprint requests to Mark J. Cooper, Division of Hematology/Oncology, University Hospitals of Cleveland, 2074 Abington Rd., Cleveland, OH 44106.

These marker-negative cells could be identified also by their distinctive cellular morphology. They had a small nucleus with condensed chromatin that contrasted sharply with the more open chromatin and larger nuclear size found in chromaffin cells.<sup>15</sup>

To further characterize these presumptive nonchromaffin adrenal medullary progenitor cells, we evaluated adrenal gland specimens over the course of development for the expression of S-100 protein and HNK-1 immunoreactivity. S-100 protein has previously been shown to be expressed by adrenal sustentacular cells.<sup>8</sup> We found it useful in marking development of the sustentacular lineage. Although most cells found in the adult adrenal medulla, including chromaffin cells, are immunoreactive with HNK-1,<sup>19</sup> this antibody has been shown previously to label primitive, migratory neural crest cells.<sup>20-23</sup> HNK-1 recognizes a variety of proteins, including neural cell adhesion molecule (N-CAM),<sup>24</sup> neuronal-glia cell adhesion molecule (Ng-CAM),<sup>25</sup> myelin-associated glycoprotein (MAG),<sup>26</sup> a protein found in adrenal medullary chromaffin granules,<sup>27</sup> and a cell-surface protein found on natural killer cells.<sup>28</sup> We found that HNK-1 marks the presumptive nonchromaffin adrenal neuroblast population, lending further support for their neural crest origin. The combination of S-100, HNK-1, TH, CGA, pG2, and B2M therefore can be used to delineate stages during the differentiation of adrenal neuroblasts and to identify branch points in this maturational program during histogenesis of the adrenal medulla.

## Materials and Methods

### Adrenal Glands

Paraffin-embedded blocks of 34 fetal and neonatal adrenal glands ranging in age from approximately 42 days postconception to 5 years after birth were evaluated by immunohistochemistry for the expression of CGA, HNK-1, and S-100. These research specimens were obtained from either the Central Laboratory of Embryology (Dr. Thomas H. Shepard, University of Washington, Seattle, WA) or from the Pathology Department of the Johns Hopkins Hospital (Dr. Grover M. Hutchins, Baltimore, MD). Paraffin-embedded blocks of adult adrenal glands were obtained from the Pathology Department of the East Carolina University School of Medicine (Dr. Richard P. Bolande, Greenville, NC). All tissue samples were fixed in 4% formaldehyde before being embedded in paraffin for immunohistochemical analysis.

### Immunohistochemistry

Five-micron sections of paraffin-embedded blocks of fetal, neonatal, and adult adrenal glands were evaluated for CGA, HNK-1, and S-100 immunoreactivity using an avidin-biotin complex immunoperoxidase-linked detection system (Vectastain ABC Immunoperoxidase Kit) according to the manufacturer's instructions (Vector Laboratories, Burlingame, CA). Primary antibodies included a mouse IgG<sub>1</sub> anti-human chromogranin A monoclonal antibody (clone LKH210) at a dilution of 10  $\mu$ g/ml (Boehringer Mannheim Biochemicals, Indianapolis, IN); HNK-1, a mouse IgM monoclonal antibody used at a dilution of 10  $\mu$ g/ml (Becton-Dickinson, Mountain View, CA); a rabbit anti-bovine brain S-100 antisera used at a dilution of 1:1500 (Accurate Chemicals, Westbury, NY); an IgG<sub>1</sub> mouse anti-leukocyte common antigen antibody used at a dilution of 1:20 (Dako Corp., Santa Barbara, CA); and a rabbit anti-human neuron-specific enolase antisera used at a dilution of 1:500 (Accurate Chemicals, Westbury, NY). Control antibodies included isotype matched mouse anti-mouse H2 antigen-specific monoclonal antibodies (provided by Dr. David Sachs, National Institutes of Health, Bethesda, MD) and purified rabbit immunoglobulin (Accurate Chemicals, Westbury, NY). Antibodies were incubated with sections overnight at room temperature. Diaminobenzidine (0.05%) was used as the chromogen (Sigma, St. Louis, MO). Sections were counterstained with hematoxylin and eosin (H&E) using standard techniques. Each experimental assay also included sections of adult adrenal glands, with adrenal medullary and cortical cells serving as positive and negative tissue controls, respectively. The staining intensity of adult adrenal medullary cells was essentially identical in each assay, and all fetal and neonatal adrenal glands were evaluated in two consecutive experiments to minimize variations in experimental conditions.

### Maturation Index

The expression of HNK-1 in chromaffin adrenal medullary cells was independently evaluated by two authors (MJC, GMH) using an index that takes into account staining intensity as well as the percentage of medullary cells scoring positively at a given signal intensity level. Maturation index =  $\sum (i) (n_i) / 3N$ , where  $i$  is the level of signal intensity;  $n_i$  is the number of cells with signal intensity  $i$ ; and  $N$  is the total number of cells counted (usually two to five high-power fields containing 100 to 200 cells). The level of signal intensity,  $i$ , was graded as 0 (no stain), 1 (minimal), 2 (moderate), and 3 (marked). An adrenal chromaffin medullary cell was recognized by the expression of CGA

and by its characteristic morphology, with a relatively large nucleus and open chromatin.

## Results

In previous studies we identified fetal adrenal medullary cells that did not express a panel of chromaffin-related markers, including TH, CGA, pG2, and B2M.<sup>14,15</sup> These marker-negative adrenal medullary cells morphologically resembled neuroblasts, and were easily distinguishable from the surrounding fetal adrenal cortical cells. The possibility that these cells could be of hematopoietic origin was investigated by examining adrenal sections for immunoreactivity to a monoclonal antibody that recognizes the anti-leukocyte common antigen. The absence of any staining by this antibody in these adrenal sections (data not shown) added further support to the possibility that these marker-negative cells were nonchromaffin adrenal neuroblasts. To better understand the developmental fate of these nonchromaffin adrenal neuroblasts, we evaluated human fetal and neonatal adrenal glands for immunoreactivity to the HNK-1 antibody. HNK-1 recognizes an oligosaccharide determinant found in a family of proteins that may be important in cell-cell recognition,<sup>29,30</sup> and detects primitive, migratory neural crest cells<sup>20-23</sup> as well as neural crest-derived cell types that have differentiated along the Schwann cell,<sup>25,26</sup> neuronal,<sup>24</sup> and chromaffin<sup>27</sup> lineages.

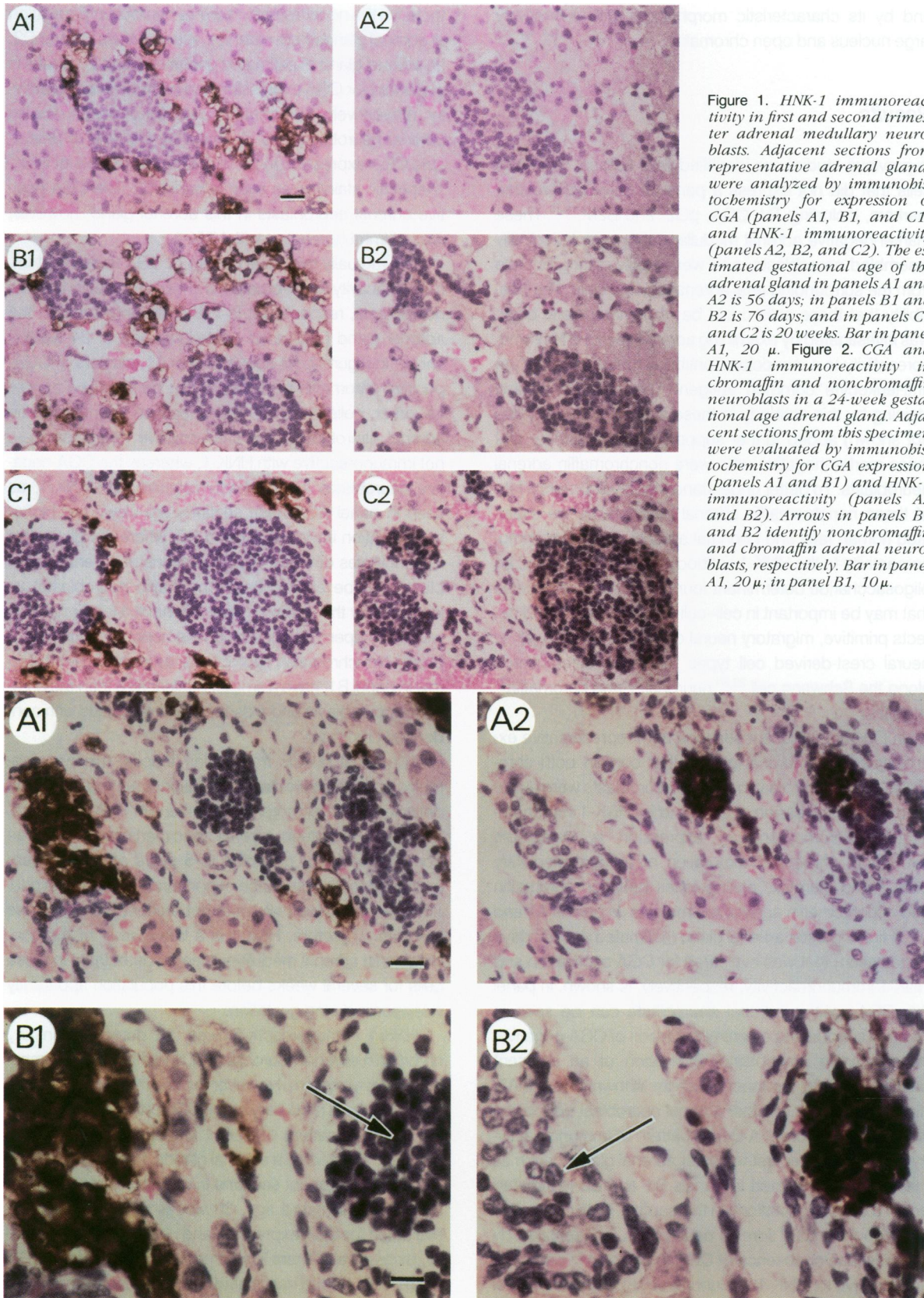
In Figure 1, adjacent sections from representative examples of fetal adrenal glands that contain both chromaffin and nonchromaffin adrenal neuroblasts were evaluated for the expression of CGA and for HNK-1 immunoreactivity. Chromogranin A expression is detectable throughout chromaffin maturation of adrenal medullary cells,<sup>15</sup> and therefore distinguishes between chromaffin and nonchromaffin adrenal neuroblasts. In panels A1 and A2, a first-trimester adrenal gland (estimated age, 57 days of gestation) that was evaluated for CGA expression and HNK-1 immunoreactivity, respectively, is shown. In panel A1, CGA-positive adrenal neuroblasts can be seen in clusters surrounding a central collection of CGA-negative, nonchromaffin neuroblasts. Evaluation of an adjacent section for HNK-1 immunoreactivity, shown in panel A2, did not indicate that either adrenal neuroblast population was immunoreactive. A similar pattern of immunoreactivity is found in other first-trimester adrenal glands, such as the example evaluated in panels B1 and B2 (estimated age, 76 days of gestation). In this sample, both chromaffin and nonchromaffin adrenal neuroblasts, as identified by the presence or absence of CGA expression in panel B1, are negative for HNK-1 immunoreactivity, as seen in panel B2. In contrast, HNK-1 immunoreactivity is exclusively de-

tected in the nonchromaffin adrenal neuroblast population of adrenal glands from older fetuses. In panels C1 and C2, an adrenal gland of estimated gestational age 20 weeks is evaluated for CGA expression and HNK-1 immunoreactivity, respectively. The central collection of nonchromaffin adrenal neuroblasts, as identified by the lack of detectable CGA expression in panel C1, has low levels of HNK-1-specific staining, as seen in panel C2. The CGA-positive adrenal neuroblasts in this adrenal gland, however, are not immunoreactive with HNK-1.

The mutually exclusive pattern of CGA and HNK-1 immunoreactivity in chromaffin and nonchromaffin adrenal neuroblasts, respectively, is further demonstrated in the adrenal gland (estimated gestational age of 24 weeks) shown in Figure 2. As seen in panel A1, clusters of CGA-positive chromaffin neuroblasts can be identified as well as other collections of CGA-negative, nonchromaffin adrenal neuroblasts. The CGA-positive neuroblasts are not immunoreactive with HNK-1, whereas the CGA-negative neuroblasts are markedly reactive with HNK-1, as seen in panel A2. These sections are viewed at higher magnification in panels B1 and B2, where the distinctive morphologies of these two populations of adrenal neuroblasts can be appreciated. Chromaffin neuroblasts, as identified by the arrow in panel B2, have a larger nucleus with more open chromatin than the nonchromaffin neuroblasts. Nonchromaffin neuroblasts, as identified by the arrow in panel B1, have a smaller nuclear size than the chromaffin neuroblasts and a darkly staining nucleus with condensed chromatin.

In adrenal glands from older fetuses, this nonchromaffin adrenal neuroblast population could no longer be detected by either morphologic criteria or HNK-1 immunoreactivity. Seventeen adrenal specimens ranging in age from 28 weeks of gestation to 5 years after birth were evaluated for the presence of nonchromaffin adrenal neuroblasts, and these cells were not present in any of these samples. Therefore, HNK-1 is a late marker of the nonchromaffin adrenal medullary lineage, detectable in these cells for several weeks before this population apparently disappears during gestation.

HNK-1 immunoreactivity was not detectable in any chromaffin adrenal neuroblasts during the first two trimesters of development. However, as this marker is detected in adult adrenal medullary chromaffin cells,<sup>19</sup> we evaluated the temporal pattern of HNK-1 immunoreactivity in third trimester and neonatal adrenal glands. In Figure 3, panels A1 and A2, adjacent sections from a third-trimester adrenal gland (estimated age, 30 weeks of gestation) were evaluated for CGA expression and HNK-1 immunoreactivity, respectively. There is a homogeneous pattern of CGA expression among nearly all identifiable adrenal medullary cells, as seen in panel A1. Rather than CGA-positive neu-



**Figure 1.** HNK-1 immunoreactivity in first and second trimester adrenal medullary neuroblasts. Adjacent sections from representative adrenal glands were analyzed by immunohistochemistry for expression of CGA (panels A1, B1, and C1) and HNK-1 immunoreactivity (panels A2, B2, and C2). The estimated gestational age of the adrenal gland in panels A1 and A2 is 56 days; in panels B1 and B2 is 76 days; and in panels C1 and C2 is 20 weeks. Bar in panel A1, 20  $\mu$ . **Figure 2.** CGA and HNK-1 immunoreactivity in chromaffin and nonchromaffin neuroblasts in a 24-week gestational age adrenal gland. Adjacent sections from this specimen were evaluated by immunohistochemistry for CGA expression (panels A1 and B1) and HNK-1 immunoreactivity (panels A2 and B2). Arrows in panels B1 and B2 identify nonchromaffin and chromaffin adrenal neuroblasts, respectively. Bar in panel A1, 20  $\mu$ ; in panel B1, 10  $\mu$ .

roblasts being distributed in individual groups or clusters, as seen in Figures 1 and 2, the chromaffin medullary cells in adrenal glands during the third trimester have coalesced to form the distinct, centrally placed medullary zone characteristic of the adult adrenal gland. No HNK-1 immunoreactivity is detectable in this third-trimester specimen, as seen in Figure 3, panel A2.

In contrast, HNK-1 immunoreactivity is detected in neonatal chromaffin cells. In Figure 3, an adrenal gland from a 4-week-old child was evaluated for CGA and HNK-1 immunoreactivity in panels B1 and B2, respectively. Nearly all identifiable medullary cells express CGA, and some of these chromaffin cells are moderately immunoreactive with HNK-1. A similar pattern of CGA expression and HNK-1 immunoreactivity was seen in the adrenal medullary cells of an adrenal gland from a 2-year-old child, in panels C1 and C2, respectively. The pattern of HNK-1 staining in an adult adrenal gland is more intense than that found in neonatal samples, resembling the staining pattern seen for CGA. A representative example of an adult adrenal gland evaluated for CGA expression and HNK-1 immunoreactivity is presented in panels D1 and D2, respectively. The maturation index for HNK-1 during development of the chromaffin adrenal medullary lineage is presented in Figure 4. Chromaffin adrenal medullary cells are not HNK-1 immunoreactive until the neonatal period. The level of immunoreactive staining in neonatal adrenal glands gradually increases, with the oldest non-adult specimen evaluated in this study, at 5 years after birth, having a maturation index of approximately 0.4. Subsequently, the time course of HNK-1 staining remains to be defined, although the maturation index for HNK-1 eventually reaches 1.0, the value characteristic of adult adrenal medullary cells.

To evaluate the sustentacular lineage during histogenesis of the adrenal medulla, we analyzed fetal and neonatal adrenal glands for expression of the S-100 protein, a marker previously established to be expressed by adrenal medullary satellite or sustentacular cells and not by adrenal chromaffin cells.<sup>8</sup> Two patterns of staining were recognized in first- and second-trimester fetal adrenal glands: S-100 positive spindle-shaped cells were associated with nerve tracks that were detected running through the adrenal gland by antisera recognizing neuron-specific enolase (data not shown) and S-100-positive cells were sometimes seen associated with collections of nonchromaffin neuroblasts. The former type of S-100-positive cell appears to be a Schwann cell associated with neurons that innervate the adrenal gland, and these cells probably are not precursors of the sustentacular lineage. The S-100-positive cells associated with nonchromaffin adrenal neuroblasts also were spindle shaped and were typically localized around the perimeter of these collections of cells

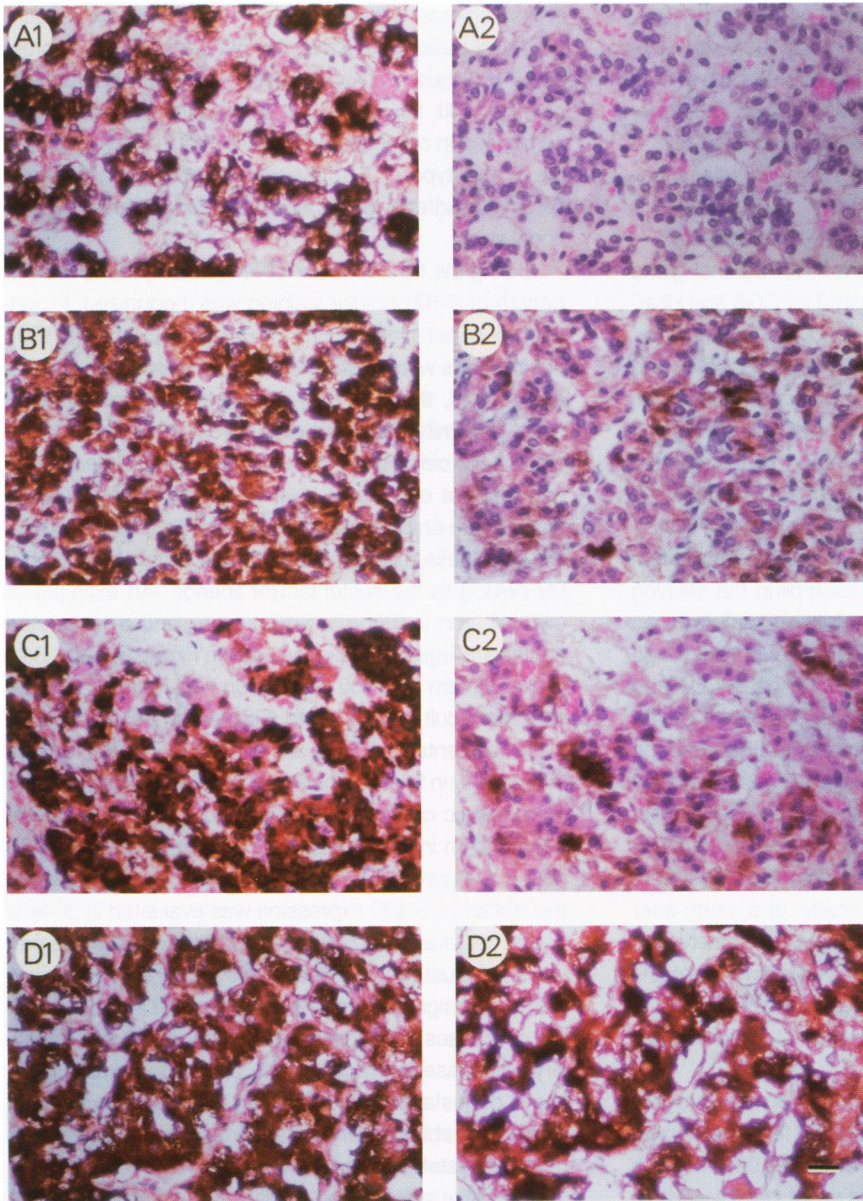
in first-trimester adrenal glands (data not shown). Later during gestation, however, the pattern of S-100 expression in these nonchromaffin adrenal neuroblasts changed. At this time, S-100-positive cells were observed within collections of nonchromaffin cells. An example of this type of S-100-positive cell is seen in Figure 5A, in an adrenal gland of 20 weeks estimated gestational age.

During the third trimester of fetal development, another pattern of S-100 cellular staining was recognized. In contrast to earlier times during development, when S-100-positive cells were associated with nonchromaffin adrenal neuroblasts, these S-100-positive cells were found in close proximity to surrounding chromaffin cells. Furthermore these cells have cellular processes that interdigitate between the chromaffin cells. Because these histologic features are characteristic of the adult adrenal sustentacular cell, these third-trimester S-100-positive cells probably belong to the sustentacular lineage. An example of this cell type is found in an adrenal gland of estimated gestational age 30 weeks, as seen in Figure 5, panel B. A similar pattern of S-100 expression was found in a representative adult adrenal gland (Figure 5, panel C).

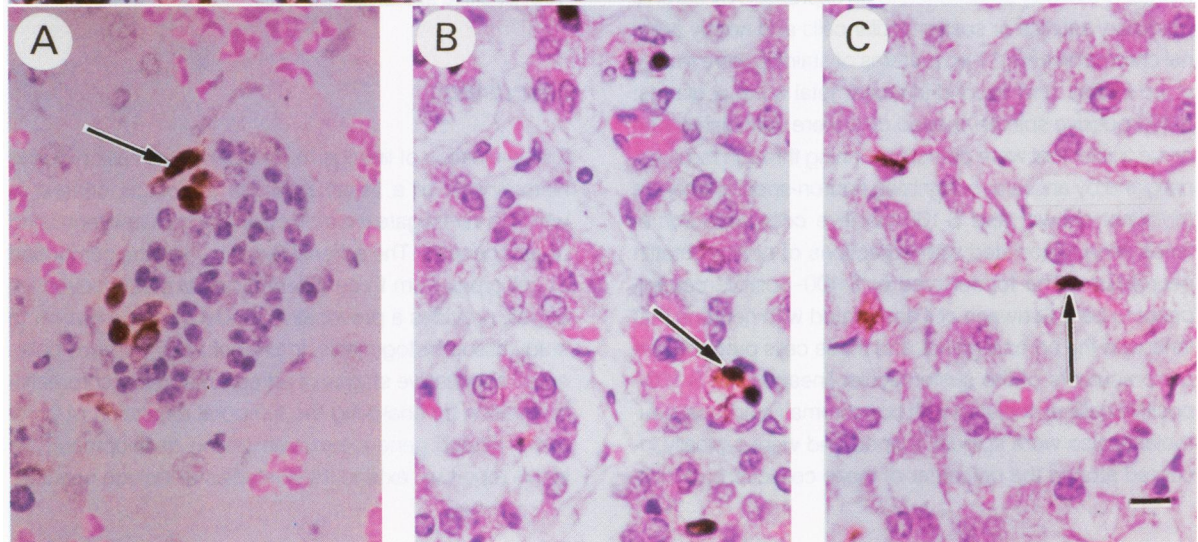
As sustentacular cells are difficult to identify by light microscopy in fetal and neonatal adrenal glands based on morphologic criteria alone, it was not possible to devise a maturation index to quantitate the expression of S-100 during maturation of the sustentacular lineage. Despite this limitation, S-100 expression was evaluated in 30 fetal and neonatal adrenal glands, including most of those previously evaluated for CGA and HNK-1. An S-100-positive cell was designated a sustentacular cell if it had spindle-like processes interdigitating between chromaffin medullary cells. Based on these criteria, all 14 fetal adrenal specimens of gestational age less than 28 weeks were devoid of recognizable sustentacular cells, whereas 16 specimens of gestational age 28 weeks and older contained S-100-positive sustentacular cells.

## Discussion

The evaluation of lineage-related gene expression during histogenesis of a tissue provides a biologic context in which to investigate the molecular mechanisms regulating organogenesis. The adrenal medulla, a tissue composed of cell types from three different neural crest-derived lineages, provides a provocative model system in which to study tissue histogenesis. In prior studies we have delineated successive stages of adrenal medullary chromaffin maturation by analyzing the temporal regulation of chromaffin-related gene expression during development.<sup>14,15</sup> In this report we extend these studies to include nonchro-



**Figure 3.** HNK-1 immunoreactivity in third trimester, neonatal, and adult adrenal medullary cells. Adjacent sections from representative adrenal glands were evaluated for CGA expression (panels A1, B1, C1, and D1) and HNK-1 immunoreactivity (panels A2, B2, C2, and D2). The estimated ages of the adrenal glands in panels A1 and A2 is 30 weeks; in panels B1 and B2 is 2 months after birth; and in panels C1 and C2 is 2 years after birth. In panels D1 and D2 an adult adrenal gland is shown. Bar in panel D2, 20  $\mu$ .



**Figure 5.** Expression of S-100 during histogenesis of the human adrenal medulla. Representative adrenal glands demonstrating the pattern of S-100 expression during development of the adrenal medulla are shown. A shows an adrenal gland of 20 weeks estimated gestational age. The arrow in this section points to an S-100-positive cell within an island of non-chromaffin adrenal neuroblasts. A collection of sustentacular cells in a field of adrenal medullary chromaffin cells is identified in an adrenal gland of 30 weeks estimated gestational age (B) and an adult adrenal gland (C). The arrows in these panels identify typical sustentacular cells with processes interdigitating between surrounding chromaffin cells. Bar in C, 10  $\mu$ .

maffin adrenal medullary lineages, describing each of the neural crest-derived cell types thought to give rise to the adult adrenal medulla.

Our data suggest a model of adrenal medullary histogenesis (Figure 6) that extends our earlier description of chromaffin cell maturation.<sup>15</sup> Clonal analyses of the descendants of primordial neural crest cells using *in vivo* labeling techniques<sup>31</sup> and *in vitro* cell cultures<sup>32,33</sup> have determined that primitive neural crest cells can give rise to cells that differentiate along multiple lineages. These multipotent neural crest stem cells may give rise to one or more classes of migratory neuroblasts that invade the fetal adrenal cortex to become adrenal medullary precursor cells. The chromaffin, sustentacular, and ganglionic adrenal medullary lineages may arise from a common adrenal medullary precursor cell. Alternatively, adrenal medullary precursor cells may have limited plasticity to differentiate along chromaffin and nonchromaffin lineages, consistent with the committed neuronal progenitors observed in *in vitro* cultures of quail neural crest.<sup>32</sup> Local environmental factors, possibly produced by the fetal adrenal cortex, then may initiate a program of cellular proliferation and differentiation along chromaffin and nonchromaffin lineages.<sup>3,34</sup>

We have shown previously that stages during maturation of the chromaffin lineage are delineated by the successive expression of TH, CGA, pG2, and B2M: TH and CGA are expressed early in the first trimester of development; pG2 is a mid-gestational marker expressed at high levels by 20 weeks of gestation; and B2M is a late marker of the adrenal medullary chromaffin lineage expressed at high levels soon after birth.<sup>14,15</sup> Our current study indicates that HNK-1 also marks the neonatal chromaffin cell, as shown in Figure 4, although the maturation index for this marker, unlike these other chromaffin-related genes, has not yet approached the adult value of 1.0 even at 5 years of age. The gradual onset of HNK-1 immunoreactivity is indicated by the open arrow in Figure 6.

In addition to chromaffin cells, the adult adrenal medulla is composed of a very small number (<1%) of ganglion cells<sup>5</sup> (unpublished data). We believe the ganglionic lineage arises from a nonchromaffin precursor cell. Early during development, nonchromaffin neuroblasts are not immunoreactive with HNK-1 (Figure 1, panels A2 and B2), and such a precursor cell is designated as a ganglionic progenitor cell in Figure 6. By 20 weeks of gestation, however, HNK-1 immunoreactivity is detectable in nonchromaffin neuroblasts (Figure 1, panel C2). Several weeks later these cells can no longer be recognized in fetal adrenal glands. HNK-1 is therefore a late marker of the nonchromaffin adrenal neuroblast population. We believe that these cells belong to the ganglionic lineage, as indicated in Figure 6, although it is also possible that some mem-

bers of the HNK-1-positive nonchromaffin population could give rise to nonganglionic adrenal medullary cell types. The reactivity of nonchromaffin adrenal neuroblasts with HNK-1 is of importance because it provides further evidence of a neural crest origin for this population of cells. Moreover, as many adult adrenal medullary ganglion cells are immunoreactive with HNK-1 (unpublished data), it is likely that nonchromaffin neuroblasts are precursors of the ganglionic lineage.

Adrenal medullary precursor cells also may give rise to the sustentacular lineage (Figure 6). The adult adrenal medullary sustentacular cell is characterized by a spindle-shaped cytoplasm, the expression of S-100, and the extension of cellular processes interdigitating between chromaffin cells. During histogenesis of the adrenal medulla, cells with these features were first detected in an adrenal gland from approximately 28 weeks of gestation (Figure 5, panel B), 22 to 23 weeks after migratory neural crest cells first invade the fetal adrenal cortex. Before this time, spindle-shaped cells expressing S-100 were seen in fetal adrenal sections, although most of these appeared to be Schwann cells closely associated with nerves innervating the adrenal gland. However, we have identified S-100-positive cells associated with the nonchromaffin adrenal neuroblast population in adrenal specimens from approximately 20 to 24 weeks of gestation (Figure 5, panel A). We believe these cells are likely to be sustentacular progenitor cells, although without additional markers of the sustentacular lineage we cannot be certain of the lineage to which these cells belong.

These findings suggest that nonchromaffin adrenal neuroblasts may include precursors of both sustentacular and ganglion cells, and that the ganglionic and sustentacular lineages may be more closely related to one another ontogenetically than either lineage is to the chromaffin medullary lineage. The developmental fate of these nonchromaffin neuroblasts, however, remains undefined. There are proportionately many fewer nonchromaffin parenchymal cells in the adult adrenal than in fetal adrenal glands of 20 to 24 weeks of gestational age. Moreover, nonchromaffin adrenal neuroblasts are not detectable in adrenal glands from fetuses older than 24 weeks of gestation. These data raise the possibility that many of these cells die during development. This outcome is consistent with the programmed developmental cell death observed in a variety of other systems, including the hermaphrodite-specific neurons of *Caenorhabditis elegans*,<sup>35</sup> and spinal and ganglionic neurons that have unsuccessfully innervated target tissues.<sup>36</sup> Moreover, neuronal cell death has been observed to occur in cultures of rat adrenal medullary cells in response to environmental manipulations.<sup>4</sup>

As sympathetic neural crest cells have the plasticity to differentiate along multiple lineages *in vitro*, it is also

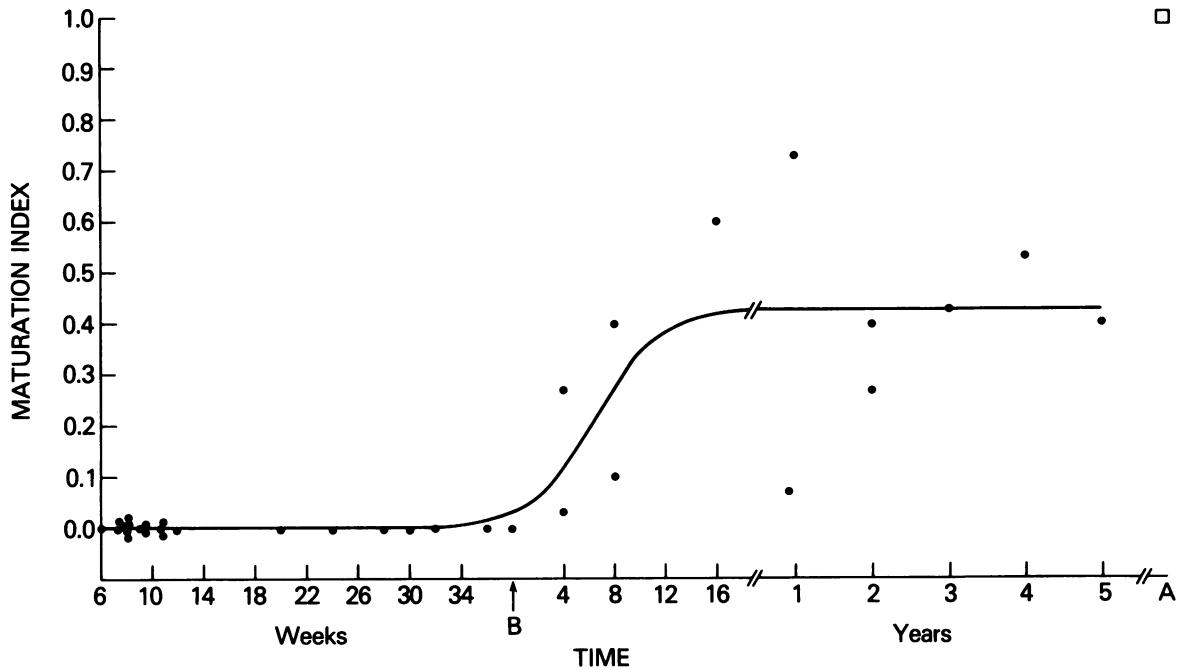


Figure 4. HNK-1 immunoreactivity in chromaffin neuroblasts during development of the human adrenal medulla. HNK-1 staining was evaluated in 34 adrenal specimens using a maturation index as defined in Methods. The abscissa indicates times during fetal development of the adrenal medulla, with a break in the axis after postnatal week 16 and after 5 years of age. The best-fit curve was determined by a nonlinear regression analysis using a sigmoid equation (correlation coefficient, 0.75). Chromaffin medullary cells in four adult adrenal glands each had a maturation index of 1.0 for HNK-1 staining, indicated by ( $\square$ ). B, birth; A, adult.

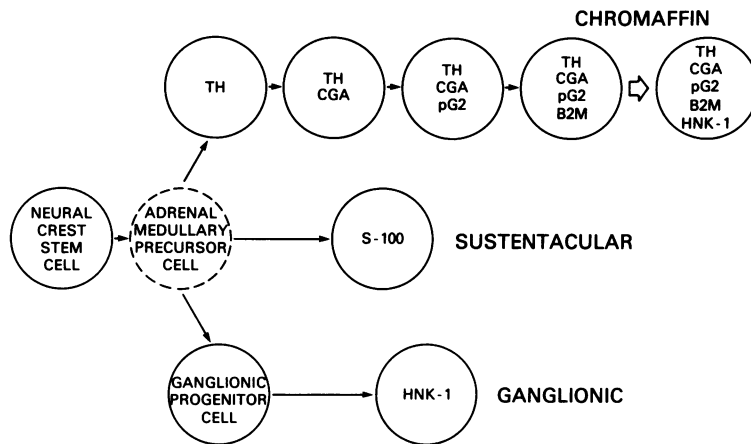
possible that some HNK-1-immunoreactive nonchromaffin neuroblasts may differentiate into chromaffin or sustentacular cells. In the presence of glucocorticoids, neonatal rat sympathetic cervical ganglia cells differentiate to cells with adrenal chromaffin characteristics, including the production of phenylethanolamine-N-methyltransferase, the synthesis of epinephrine, and the presence of large granular vesicles.<sup>34</sup> Dexamethasone also induces the transcription of several chromaffin-specific cDNAs in a human neuroblastoma cell line.<sup>17</sup> In contrast, when rat neonatal chromaffin adrenal medullary cells are cultured in the presence of nerve growth factor, these cells can differentiate into cells with neuronal features, including the presence of synapses, the loss of chromaffin granules, and the expression of neurofilament protein.<sup>3</sup> Nerve growth factor also induces the transcription of a neuron-specific cDNA in rat pheochromocytoma cells.<sup>6</sup> In addition, human neuroblastoma cells can be induced to express the S-100 protein in the presence of 5-bromo-2'-deoxyuridine, suggestive of differentiation along a Schwann cell lineage.<sup>37</sup> These findings suggest another possible explanation for the precipitous fall in the number of HNK-1-immunoreactive nonchromaffin neuroblasts after week 24 of gestation; namely, the differentiation of these cells along chromaffin or sustentacular pathways.

Subpopulations of human fetal adrenal neuroblasts with distinct morphologies have been previously re-

ported.<sup>38-40</sup> Coupland<sup>39</sup> conducted a morphologic evaluation of human adrenal medullary development and noted cell types, including pheochromoblasts and chromaffin cells, with different nuclear morphologies. In addition, primitive sympathetic cells were found within the fetal adrenal gland, and these cells were considered to be the multipotent precursor cell of both the adrenal chromaffin and ganglionic lineages. Primitive sympathetic cells were recognized within adrenal glands from fetuses up to the 150-mm stage, a size that corresponds to approximately 17 weeks of gestational age. These cells are probably the nonchromaffin adrenal medullary population seen in our study. Our model of adrenal medullary histogenesis extends these earlier observations, although our data suggest that adrenal medullary nonchromaffin neuroblasts may be committed to a nonchromaffin lineage(s) and do not give rise to chromaffin cells.

Expression of the S-100 protein has been examined previously in human fetal adrenal glands of approximately 20 weeks of gestational age.<sup>41</sup> This study reported several patterns of S-100 staining by fetal medullary cells. S-100-positive cells were identified around the perimeter and occasionally within the center of clusters of nonargyrophilic adrenal neuroblasts. Within clusters of chromaffin cells, identified by positive staining with Grimelius' silver impregnation method, S-100-positive cells were interpreted to be adrenal sustentacular cells. Our observations





by the expression of S-100 and may arise from a nonchromaffin adrenal neuroblast. The ganglionic lineage also may arise from such precursors. An early stage during maturation of this lineage is represented by the ganglionic progenitor cell, which is not immunoreactive with HNK-1. Later during development, this cell type becomes immunoreactive with HNK-1.

**Figure 6.** Model of adrenal medullary histogenesis. The neural crest stem cell represents a primordial, multipotent cell before neural crest migration. Descendants of these stem cells that invade the fetal adrenal cortex and give rise to the adrenal medulla are designated as adrenal medullary precursor cells. As the precise developmental potential of such precursor cells has not been defined, it is represented using a dashed line. Successive stages during maturation of chromaffin medullary cells are identified by the sequential expression of TH, CGA, pG2, and B2M, as previously described.<sup>14,15</sup> An additional stage in chromaffin maturation is identified by HNK-1 immunoreactivity, although the open arrow preceding the HNK-1-positive chromaffin cell signifies that the maturation index for this adrenal marker has not yet reached the adult value of 1.0 by 5 years of age. The sustentacular lineage is marked

parallel these patterns of S-100 expression in fetal adrenal glands at comparable gestational ages, although we did not observe sustentacular cells until approximately 28 weeks of gestational age.

Neuroblastoma, an embryonal tumor of the adrenal medulla, differentiates spontaneously along multiple cell lineages<sup>42</sup> and in response to a variety of exogenous agents in cell culture.<sup>37,43-45</sup> This tumor has also been reported to differentiate *in vivo*,<sup>46,47</sup> sometimes associated with spontaneous tumor regression.<sup>48,49</sup> Although many neuroblastoma tumors appear histologically to be composed of small, undifferentiated round cells,<sup>50</sup> resembling the histology of primitive neuroblasts found early during development of the adrenal medulla, other tumors have more differentiated features, resembling Schwann cells<sup>47</sup> and ganglion cells.<sup>46</sup> In addition, some neuroblastoma tumors express the chromaffin-related marker, CGA,<sup>51</sup> indicating differentiation along a neuroendocrine pathway. These findings suggest that neuroblastoma tumors can differentiate along several different lineages physiologic for precursor cells of the adrenal medulla. Moreover, as neuroblastoma is a tumor of early childhood, it is possible that some neuroblastoma tumors may arise during fetal development of the adrenal medulla, perhaps associated with a phenotypic differentiation arrest. An analysis of adrenal medullary lineage-related gene expression in neuroblastoma cell lines and tumors therefore may identify neuroblastomas that correspond to adrenal medullary precursor cells arrested at different stages of development. Also, because the biologic behavior of neuroblastomas may mimic the cellular characteristics of primitive neuroblasts, including the ability of primitive, migratory neural crest cells to traverse tissue barriers and invade adjacent structures, it is possible that a differentiation-based classification of neuroblastoma tumors may pro-

vide insight into biologic activities key in determining the pathologic behavior of individual tumors.

## References

1. Keene MF, Hewer EE: Observations on the development of the human suprarenal gland. *J Anat Physiol* 1927, 61:302-324
2. Le Douarin NM: The neural crest, *Developmental and Cell Biology Series*. Edited by PW Barlow, PB Green, CC Wylie. Cambridge, England, Cambridge University Press, 1984, pp 144-212
3. Doupe AJ, Landis SC, Patterson PH: Environmental influences in the development of neural crest derivatives: Glucocorticoids, growth factors, and chromaffin cell plasticity. *J Neurosci* 1985, 5:2119-2142
4. Anderson DJ, Axel R: A bipotential neuroendocrine precursor whose choice of cell fate is determined by NGF and glucocorticoids. *Cell* 1986, 47:1079-1090
5. Unsicker K: Fine structure and innervation of the avian adrenal gland. I. Fine structure of adrenal chromaffin cells and ganglion cells. *Z Zellforsch Mikrosk Anat* 1973, 145:389-416
6. Anderson DJ, Axel R: Molecular probes for the development and plasticity of neural crest derivatives. *Cell* 1985, 42:649-662
7. Trojanowski JQ, Walkenstein N, Lee VMY: Expression of neurofilament subunits in neurons of the central and peripheral nervous system: An immunohistochemical study with monoclonal antibodies. *J Neurosci* 1986, 6:650-660
8. Cocchia D, Michetti F: S-100 antigen in satellite cells of the adrenal medulla and the superior cervical ganglion of the rat. *Cell Tissue Res* 1981, 215:103-112
9. Lloyd RV, Wilson BS: Specific endocrine tissue marker defined by a monoclonal antibody. *Science* 1983, 222:628-630

10. Lundberg JM, Hamberger B, Schultzberg M, Hokfelt T, Granberg PO, Efendic S, Terenius L, Goldstein M, Luk R: Enkephalin- and somatostatin-like immunoreactivities in human adrenal medulla and pheochromocytoma. *Proc Natl Acad Sci USA* 1979, 76:4079-4083
11. Lloyd RV, Sisson JC, Shapiro B, Verhofstad AAJ: Immunohistochemical localization of epinephrine, norepinephrine, catecholamine-synthesizing enzymes, and chromogranin in neuroendocrine cells and tumors. *Am J Pathol* 1986, 125:45-54
12. Eiden LE, Giraud P, Hotchkiss A, Brownstein MJ: Enkephalins and VIP in human pheochromocytomas and bovine adrenal chromaffin cells. *Regulatory Peptides: From Molecular Biology to Function*. Edited by E Costa, M Trabucchi. New York, Raven Press, 1982, pp 387-395
13. Allen JM, Yeats JC, Causon R, Brown MJ, Bloom SR: Neuropeptide Y and its flanking peptide in human endocrine tumors and plasma. *J Clin Endocrinol Metab* 1987, 64:1199-1204
14. Cooper MJ, Hutchins GM, Mennie RJ, Israel MA: Beta-2-microglobulin expression in embryonal neuroblastoma reflects its developmental regulation. *Cancer Res* 1990, 50:3694-3700
15. Cooper MJ, Hutchins GM, Cohen PS, Helman LJ, Mennie RJ, Israel MA: Human neuroblastoma tumor cell lines correspond to the arrested differentiation of chromaffin adrenal medullary neuroblasts. *Cell Growth Differen* 1990, 1:149-159
16. Levitt M, Spector S, Sjderosma A, Udenfriend U: Elucidation of the rate-limiting step in norepinephrine biosynthesis in the perfused guinea-pig heart. *J Pharmacol Exp Ther* 1965, 148:1-8
17. Helman LJ, Thiele CJ, Linehan WM, Nelkin BD, Baylin SB, Israel MA: Molecular markers of neuroendocrine development and evidence of environmental regulation. *Proc Natl Acad Sci USA* 1987, 84:2336-2339
18. Cunningham BA: Structure and significance of B<sub>2</sub>-microglobulin. *Fed Proc* 1976, 35:1171-1176
19. Lipinski M, Braham K, Caillaud JM, Carlu C, Tursz R: HNK-1 antibody detects an antigen expressed on neuroectodermal cells. *J Exp Med* 1983, 158:1775-1780
20. Vincent M, Duband JL, Thiery JP: A cell surface determinant expressed early on migrating avian neural crest cells. *Dev Brain Res* 1983, 9:235-236
21. Tucker GC, Aoyama H, Lipinski M, Tursz T, Thiery JP: Identical reactivity of monoclonal antibodies HNK-1 and NC-1: conservation in vertebrates on cells derived from the neural primordium and on some leukocytes. *Cell Differ* 1984, 14:223-230
22. Rickmann M, Fawcett JW, Keynes RJ: The migration of neural crest cells and the growth of motor axons through the rostral half of the chick somite. *J Embryol Exp Morph* 1985, 90:437-455
23. Bronner-Fraser M: Analysis of the early stages of trunk neural crest migration in avian embryos using monoclonal antibody HNK-1. *Dev Biol* 1986, 115:44-55
24. Kruse J, Mailhammer R, Wernecke H, Faissner A, Sommer I, Goridis C, Schachner M: Neural cell adhesion molecules and myelin-associated glycoprotein share a common carbohydrate moiety recognized by monoclonal antibodies L2 and HNK-1. *Nature* 1984, 311:153-155
25. Tucker GC, Dellagi K, Schmitt C, Brouet JC, Thiery JP: Heterogeneity of human anti-MAG IgM as revealed by their reactivity on avian embryonic tissues. *Clin Exp Immunol* 1987, 67:352-361
26. McGarry RC, Helfand SL, Quarles RH, Roder JC: Recognition of myelin-associated glycoprotein by the monoclonal antibody HNK-1. *Nature* 1983, 306:376-378
27. Tischler AS, Mobtaker H, Mann K, Nunnemacher G, Jason WJ, Dayal Y, Delellis RA, Adelman L, Wolfe HJ: Anti-lymphocyte antibody leu-7 (HNK-1) recognizes a constituent of neuroendocrine granule matrix. *J Histochem Cytochem* 1986, 34:1213-1216
28. Abo T, Balch CM: A differentiation antigen on human NK and K cells identified by a monoclonal antibody (HNK-1). *J Immunol* 1981, 127:1024-1029
29. Chou KH, Ilyas AA, Evans JE, Quarles RH, Jungalwala FB: Structure of a glycolipid reacting with monoclonal IgM in neuropathy and with HNK-1. *Biochem Biophys Res Commun* 1985, 128:383-388
30. Kunemund V, Jungalwala FB, Fischer G, Chou DK, Keilhauer G, Schachner M: The L2/HNK-1 carbohydrate of neural cell adhesion molecules is involved in cell interactions. *J Cell Biol* 1988, 106:213-223
31. Bronner-Fraser M, Fraser SE: Cell lineage analysis reveals multipotency of some avian neural crest cells. *Nature* 1988, 335:161-164
32. Baroffio A, Dupin E, Le Douarin NM: Clone-forming ability and differentiation potential of migratory neural crest cells. *Proc Natl Acad Sci USA* 1988, 85:5325-5329
33. Maxwell GD, Forbes ME, Christie DS: Analysis of the development of cellular subsets present in the neural crest using cell sorting and cell culture. *Neuron* 1988, 1:557-568
34. Doupe AJ, Patterson PH, Landis SC: Small intensely fluorescent cells in culture: Role of glucocorticoids and growth factors in their development and interconversions with other neural crest derivatives. *J Neurosci* 1985, 5:2143-2160
35. Desai C, Garriga G, McIntire SL, Horvitz HR: A genetic pathway for the development of the *Caenorhabditis elegans* HSN motor neurons. *Nature* 1988, 336:638-646
36. Barde YA: Trophic factors and neuronal survival. *Neuron* 1989, 2:1525-1534
37. Tsunamoto K, Todo S, Imashuku S, Kato K: Induction of S100 protein by 5-bromo-2'-deoxyuridine in human neuroblastoma cell lines. *Cancer Res* 1988, 48:170-174
38. Crowder RE: The development of the adrenal gland in man, with special reference to the origin and ultimate location of cell types and evidence in favor of the "cell migration theory." *Carnegie Inst Contrib Embryol* 1957, 36:195-210
39. Coupland RE: *The Natural History of the Chromaffin Cell*. London, Longman, Green and Co., LTD., 1965, pp 47-76

40. Turkel SB, Itabashi HH: The natural history of neuroblastic cells in the fetal adrenal gland. *Am J Pathol* 1974, 76:225-244
41. Iwanaga T, Fujita T: Sustentacular cells in the fetal human adrenal medulla are immunoreactive with antibodies to brain S-100 protein. *Cell Tissue Res* 1984, 236:733-735
42. Ciccarone V, Spengler BA, Meyers MB, Biedler JL, Ross RA: Phenotypic diversification in human neuroblastoma cells: Expression of distinct neural crest lineages. *Cancer Res* 1989, 49:219-225.
43. Sidell N: Retinoic acid-induced growth inhibition and morphologic differentiation of human neuroblastoma cells in vitro. *J Natl Cancer Inst* 1982, 68:589-596
44. Reynolds CP, Maples J: Modulation of cell surface antigens accompanies morphological differentiation of human neuroblastoma cell lines. *Prog Clin Biol Res* 1986, 271:13-37
45. Tsokos M, Scarpa S, Ross R, Triche TJ: Differentiation of human neuroblastoma recapitulates neural crest development. Study of morphology, neurotransmitter enzymes, and extracellular matrix proteins. *Am J Pathol* 1987, 128:484-496
46. Fox F, Davidson J, Thomas LB: Maturation of sympathicoblastoma into ganglioneuroma. *Cancer* 1959, 12:108-116
47. Shimada H, Aoyama C, Chiba T, Newton WA: Prognostic subgroups for undifferentiated neuroblastoma: immunohistochemical study with anti-S-100 protein antibody. *Hum Pathol* 1985, 16:471-476
48. Evans AE, Gerson J, Schnauffer L: Spontaneous regression of neuroblastoma. *Natl Cancer Inst Monogr* 1976, 44:49-54
49. Evans AE, Chatten J, D'Angio GJ, Gerson J, Robinson J, Schnauffer L: A review of 17 IV-S neuroblastoma patients at the Children's Hospital of Philadelphia. *Cancer* 1980, 45:833-839
50. Triche TJ, Askin FB: Neuroblastoma and the differential diagnosis of small-, round-, blue-cell tumors. *Hum Pathol* 1983, 14:569-595
51. Cooper MJ, Helman LJ, Evans AE, Swamy S, O'Connor DT, Helson L, Israel MA: Chromogranin A expression in childhood peripheral neuroectodermal tumors. *Advances in Neuroblastoma Research 2*. Edited by AE Evans. New York, Alan R. Liss, 1988, pp 175-184

### **Acknowledgments**

The authors thank R. J. Mennie for excellent technical assistance and Dr. P. S. Cohen for many helpful discussions.