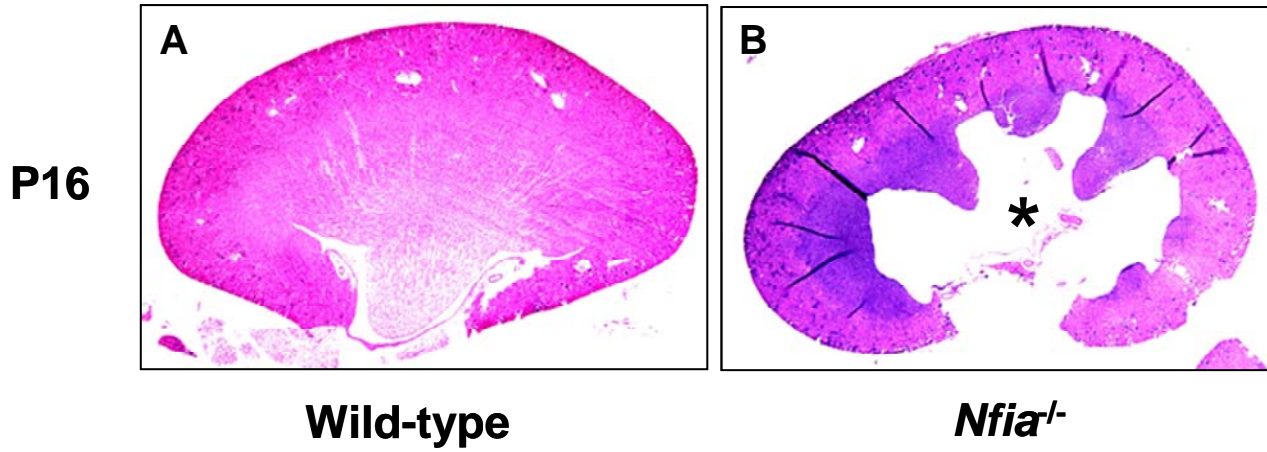


Figure S6. Hydronephrosis in P16 *Nfia*^{-/-} mutant



Severe hydronephrosis (* in B) is shown in a P16 *Nfia*^{-/-} mutant kidney, whereas the kidney in its wild-type littermate (A) is normal.