

Interstitial Nephritis Induced by Protein-Overload Proteinuria

Allison A. Eddy with the technical assistance of
Lorinda McCulloch, Jennifer Adams,
and Elaine Liu

From The Hospital for Sick Children, University of
Toronto, Toronto, Ontario, Canada

Experimental nephrotic syndrome induced by several immunologic and biochemical methods is associated with the development of tubulointerstitial nephritis (TIN). To investigate the hypothesis that severe sustained proteinuria plays a role in the pathogenesis of TIN, the renal interstitium in a model of protein-overload proteinuria was studied. After uninephrectomy, rats received daily injections of 1.0 g of bovine serum albumin (BSA) or saline (controls) until killing at 1, 2, 4, or 7 weeks. Sections of frozen renal cortex were stained with a panel of monoclonal antibodies reactive with subsets of rat lymphohemopoietic cells, and positive tubulointerstitial cells (TIC) were quantitated by epifluorescence microscopy. BSA rats developed proteinuria, with mean rat urinary albumin excretion rates at 1, 2, 3, and 6 weeks of 35.6 ± 21.8 , 97.2 ± 46.1 , 63.6 ± 40.8 , and 58.6 ± 24.4 mg/24 hours, respectively (controls, 0.17 ± 0.16 mg/24 hours). BSA was detectable in the plasma of experimental animals at all periods, with mean values of 26.8 ± 3.8 , 27.8 ± 2.7 , 20.3 ± 6.2 , and 7.0 ± 1.1 mg/ml (controls, 0.03 ± 0.04 mg/ml) at 1, 2, 4, and 7 weeks, respectively, whereas plasma anti-BSA antibodies were never detected. A significant mononuclear cell infiltrate was present in the interstitium of experimental animals at all periods. At 1 week, an influx of macrophages was evident that was identified by surface markers OX42 (75^+ /1000 TIC) ($P < 0.01$) and Ia (58^+ /1000 TIC) ($P < 0.01$). Macrophages dominated the infiltrate at all periods. By 2 weeks, a significant population of lymphocytes was also present that was identified by the surface marker OX19 (54^+ /1000 TIC) ($P < 0.01$). This early lymphocytic infiltrate was a mixed lesion of T helper and T cytotoxic cells. However, at 4 and 7 weeks, most lymphocytes expressed the OX8 cytotoxic T cell marker. The proximal tu-

bules of proteinuric rats expressed vimentin intermediate filaments, a marker of tubular epithelial cell regeneration after injury. In BSA rats, C3 and neoantigens of the membrane attack complex of complement without IgG were present along the luminal border of many tubular epithelial cells. The interstitial infiltrate was confirmed by light microscopy. By 4 weeks, focal areas of chronic interstitial disease were evident consisting of tubular atrophy and interstitial fibrosis. In a second study, one group of BSA-treated rats was depleted of circulating T lymphocytes by daily parenteral injections of monoclonal antibody OX19. Although this group of rats did not develop an interstitial influx of T cells, the macrophage infiltrate was not significantly different from that occurring in rats with an intact cellular immune system. A third study, designed to evaluate the effect of renal mass on the severity of TIN, compared the effect of BSA overload in uninephrectomized rats and 2-kidney rats. A strong positive correlation was observed between the intensity of TIN and the degree of proteinuria: $r = 0.89$ for OX42⁺ TI cells and $r = 0.77$ for OX19⁺ TI cells. In the final study, BSA-treated rats were compared with rats given daily injections of rat plasma enriched for rat albumin (0.7 g/day). Focal TIN was found in both animal groups. The results of this study suggest that proteinuria may play a direct role in the pathogenesis of tubulointerstitial injury that develops in association with chronic glomerulonephritis. Further studies are necessary to delineate specific afferent and efferent pathways. (Am J Pathol 1989, 135:719-733)

Chronic tubulointerstitial disease is the histologic hallmark of chronic and progressive renal injury and yet our understanding of its pathogenesis remains limited. In the ab-

This work was supported by grants from The Medical Research Council of Canada (MA9720) and The Kidney Foundation of Canada. Dr. Allison Eddy is a scholar of The Kidney Foundation of Canada.

Accepted for publication June 15, 1989.

Address reprint requests to Dr. Allison Eddy, The Hospital for Sick Children, Division of Nephrology, Rm. 5123, 555 University Avenue, Toronto, Ontario, Canada, M5G 1X8.

sence of known mediators such as tubular toxins and immune reactants, it is frequently suggested that the tubulointerstitial disease is ischemic in origin, secondary to the obliteration of peritubular capillaries ensuing from a sclerosed glomerulus.^{1,2} However, it is clear that severe tubulointerstitial damage may coexist with glomerular injury well before the development of glomerular sclerosis.^{3,4} The presence of interstitial pathology is functionally important. In chronic glomerulonephritis in humans the decline in the glomerular filtration rate usually correlates better with the interstitial than the glomerular morphologic changes.^{3,5-11}

Monoclonal antibodies reactive with subsets of lymphohemopoietic cells can be used as extremely sensitive probes to examine interstitial cellular events. The recent application of this method to the study of nephrotic syndrome induced in rats by the aminonucleoside of puromycin (PAN) demonstrated that acute interstitial nephritis was associated with the proteinuric phase.¹² The observed positive correlation between the degree of albuminuria and the intensity of the interstitial cell infiltrate in PAN-treated rats led us to speculate that a relationship might exist between severe proteinuria and some of the pathologic changes that occurred within the interstitium.

To further investigate the possible relationship between proteinuria and interstitial disease, the model of protein-overload proteinuria in young, uninephrectomized rats was selected for study. Rats given daily intraperitoneal injections of bovine serum albumin (BSA) developed proteinuria that began within the first 24 hours and was characterized by increased urinary excretion of rat proteins as well as of the injected heterologous albumin. Most studies of overload proteinuria focused on the acute events that occur within the glomerulus during proteinuria. However, morphologic changes were described in the tubules including proteinaceous casts in the distal tubules, and the proximal tubules may demonstrate degenerative changes, occasional mitotic figures, cytoplasmic swelling, the presence of hyaline droplets, and disruption of the brush border.¹³⁻¹⁹ Interstitial fibrosis has occasionally been reported as a late consequence of protein-overload proteinuria.^{20,21} Although the mechanism of proteinuria in this model is still controversial, immunologic factors are generally considered unimportant. In this study, we characterized the cellular events that occurred in the interstitium of the renal cortex during protein-overload proteinuria. Our results suggest that, under the appropriate conditions, proteinuria may contribute to tubulointerstitial inflammation.

Materials and Methods

Animals

Female Lewis rats weighing 100 to 125 g were purchased from Charles River Breeding Laboratories (Wilmington,

MA). Animals were fed standard rat chow *ad libitum* and given free access to water.

Experimental Design I: BSA-overload model

All animals underwent unilateral right nephrectomy 5 days before initiation of the study. Experimental rats received intraperitoneal injections of 1.0 g of bovine serum albumin (BSA) (Fraction V, No. A-4503, 96-99% albumin, Sigma Chemical Company, St. Louis, MO) given as 3 ml of a 33.3% albumin solution in saline. Albumin was given once daily for the first 4 weeks and 5 out of 7 days throughout weeks 4 to 7. Control animals received intraperitoneal injections of 0.9% saline on an identical schedule.

Animals were housed individually in metabolic cages, and timed collections of spontaneously voided urine were obtained at weeks 1, 2, 3, 4, and 6 for determination of urinary total protein and rat albumin excretion rates. Groups of rats (four experimental and two control animals) were killed after 1, 2, 4, and 7 weeks. Before killings, animals were anesthetized using inhalation of nitrous oxide, oxygen, and enflurane (Anaquest, Pointe Claire, Quebec, Canada). Plasma was obtained by exsanguination through the abdominal aorta.

Plasma Biochemistry

Plasma creatinine was measured using the Kodak Ektachem 700 method. Total serum protein was determined by dye dilution using the Bio-Rad protein assay (Bio-Rad Laboratories, Richmond, CA) with human plasma as the standard. Protein electrophoresis established the total protein content of the standard plasma. Plasma BSA was quantitated by radial immunodiffusion using a rabbit antiserum to bovine serum albumin (Cappel Scientific Division, Cooper Biomedical Inc., Malvern, PA) that was absorbed with normal rat plasma before use.

Plasma Anti-BSA Levels

Using the double gel diffusion method of Ouchterlony,²² samples of plasma obtained at killing were serially diluted and tested for the presence of antibodies against BSA. The BSA antigen (Fraction V, Sigma) was used at a concentration of 1.0 mg/ml. Commercially available rabbit anti-BSA antiserum (Cappel, Organon Teknika Corporation, West Chester, PA) was used as a positive control.

Urinary Protein Excretion

Rat urinary albumin was quantitated by radial immunodiffusion using a rabbit antiserum to rat albumin as previously described.¹² This antiserum does not cross react

with BSA. Total urinary protein was determined using the Bio-Rad protein assay.

Enumeration and Characterization of Tubulointerstitial Cells

When killed, animals were completely exsanguinated before kidney harvesting to minimize the number of circulating lymphohemopoietic cells remaining in the kidney. Pieces of renal cortex were snap-frozen in isopentane, precooled in liquid nitrogen, and stored at -70°C . Sections of renal cortical tissue ($3\ \mu\text{m}$) were stained with a panel of monoclonal antibodies reactive with subsets of rat lymphohemopoietic cells as previously described.^{12,23} In brief, using a three-step sequence, acetone-fixed sections were incubated with the predetermined working dilutions of one of the monoclonal antibodies, fluorescein-isothiocyanate (FITC)-conjugated goat anti-mouse IgG F(ab')₂ (Tago Inc., Burlingame, CA) and finally FITC-conjugated rabbit anti-goat IgG (Fab')₂ (Cooper Biomedical, Malvern PA). FITC-conjugated antisera were preabsorbed with rat plasma and shown to be nonreactive with control sections of rat kidneys. Coverslips were mounted using PBS-glycerol containing 0.1% p-phenylenediamine added to retard fluorescence quenching and the nuclear stain ethidium bromide ($1\ \mu\text{g}/\text{ml}$).

For each of the six monoclonal antibodies, 18 interstitial fields from each animal were selected for study using a Zeiss epifluorescence microscope and a $63\times$ lens. Initially, three spatially distinct regions were selected using phase contrast microscopy, by the random selection of a glomerulus within the top, middle, and lower third of the cortical tissue. A field was defined as the area within a $10\ \text{mm} \times 10\ \text{mm}$ eyepiece counting grid. The randomly selected glomeruli then served as the central field of each region, and a total of six adjacent fields were evaluated in each of the three areas. With the addition of epifluorescence microscopy, the cells in each field were counted twice. Initially, all positive tubulointerstitial (TI) cells were counted, identified by the green fluorescent membranes surrounding a red nucleus. Caution was taken to include only interstitial fluorescence clearly associated with a cell nucleus. Second, all TI cell nuclei within the field were identified and enumerated by the red nuclear staining of ethidium bromide. With the assistance of phase contrast microscopy, all cells within glomeruli and blood vessels were carefully excluded. An average of 1197 TI cells were evaluated for each monoclonal antibody ($N = 6$) in each animal studied ($N = 24$). Results were expressed as the number of positive cells per 1000 TI cells counted.

Monoclonal Antibodies

Six monoclonal antibodies were obtained from commercial sources (Sera Lab distributed through Dimension

Laboratories, Mississauga, Ontario, Canada). Monoclonal antibody OX42 was a gift of Dr. Alan Williams, MRC Cellular Immunology Unit, Oxford, England. The reactivity of each of these monoclonal antibodies is summarized in Table 1.²⁴⁻³⁶

Additional Immunofluorescence Studies

Sections of frozen renal tissue were stained by direct immunofluorescence for the presence of rat C3 and rat IgG using commercially available antisera (Cappel Laboratories). Tissue was stained for rat C5b-9 neoantigens using monoclonal antibody 2A1 (a gift of Dr. W. Couser, University of Washington, Seattle)³⁷ followed by FITC-conjugated goat anti-mouse IgG F(ab')₂. Renal deposition of BSA was assessed by indirect immunofluorescence using rabbit anti-BSA antiserum (Cappel Laboratories) followed by FITC-conjugated goat anti-rabbit IgG (Cappel Laboratories). The FITC-conjugated antiserum was extensively absorbed with normal rat plasma and BSA before use. The expression of vimentin intermediate filaments was used as an indicator of regenerating tubular epithelial cells as recently reported by Grone et al.³⁸ A murine monoclonal antibody against vimentin (BioGenex Laboratories, Dublin, CA) was used for indirect immunofluorescence staining of kidney sections as described above.

Light Microscopy

A piece of renal tissue was placed in Zenker's fixative and processed for routine light microscopy. Sections were stained with periodic acid Schiff and Masson's trichrome. Using a semiquantitative index, sections were assessed for the degree of acute interstitial disease in the renal cortex (tubulorrhesis, interstitial edema, interstitial mononuclear cells, and tubular dilation) and chronic injury (tubular atrophy, thickening of tubular basement membranes, and interstitial fibrosis). An overall acute and chronic activity score was assigned to each animal using the following criteria: 0, normal; 1+, less than 10% of the cortex; 2+, 10% to 25% of the cortex; 3+, 25% to 75% of the cortex; and 4+, more than 75% of the cortex.

Experimental Design II: Comparison of Rat Serum Albumin (RSA) with Bovine Serum Albumin (BSA) Overload Proteinuria

To overcome any potential immunologic response to heterologous albumin, an attempt was made to repeat experimental design I comparing the effects of RSA with those of BSA. Rat serum (1500 ml) was purchased from Charles River Laboratories, and a concentrate of rat-albumin en-

Table 1. Reactivity of Anti-Rat Monoclonal Antibodies

Antibody/reference	Lymphohemopoietic cells	Kidney
OX1 (RCLA) ^{24,25}	All marrow-derived leukocytes (rat leukocyte common antigen positive; analogous to human CD45 ⁺ cells)	Amorphous interstitial substance
OX19 ^{26,27}	All T lymphocytes (analogous to CD3 ⁺ cells)	NR
W3/25 ²⁸⁻³¹	T helper lymphocytes (analogous to CD4 ⁺ cells); some macrophages	Peritubular capillaries
OX22 ³⁶	B lymphocytes, subset of T helper cells (reacts with high molecular weight RCLA)	NR
OX8 ^{28-30,32,33}	T cytotoxic/suppressor cells (analogous to CD8 ⁺ cells); natural killer cells	NR
OX42 ³⁴	Macrophages and polymorphonuclear cells expressing the C3bi receptor (analogous to CD11 ⁺ cells)	NR
OX4 (anti-Ia) ³⁵	MHC class II (Ia) antigen-positive cells (B cells, activated macrophages)	Interstitial dendritic cells; small population resident mesangial cells; epithelial cells of proximal convoluted tubules

NR, nonreactive.

riched, sodium-depleted serum was prepared by the following procedure. The plasma was preconcentrated two-fold using an Amicon YM30 ultrafiltration membrane. Immunoglobulins were precipitated with 50% ammonium sulfate. The supernatant was dialyzed against sterile water, passed through a 0.2 micron filter, and lyophilized. This preparation was redissolved in sterile water. By protein electrophoresis, the albumin concentration was 142 g/l which represented 75% of the total protein content. The final sodium concentration was adjusted to 154 mmol/l. All rats were nephrectomized on day minus 5. Group I (N = 2) received a single daily intraperitoneal injection of 0.7 g rat albumin for 10 days. Group II (N = 4) was given 0.7 g bovine serum albumin (Fraction V, No. A-7906, 98% or 99% albumin, Sigma), and Group III controls (N = 4) were given 4.9 ml saline intraperitoneally once daily. Blood pressures were determined in awake animals by tail cuff on day 8. Urine collections were obtained over 24 hours on days 4 and 7. The animals were killed on day 11.

Experimental Design III: Effect of T Cell Depletion on BSA-Induced Interstitial Nephritis

To further evaluate the possibility that BSA triggered a T cell dependent hypersensitivity response resulting in the development of acute interstitial nephritis, one group of experimental animals was depleted of circulating T cells by intraperitoneal injections of monoclonal antibody OX19.^{39,40} The OX19-cell line was obtained from Dr. A. Like, University of Massachusetts Medical School, with the approval of Dr. A. F. Williams, University of Oxford. The monoclonal antibody was produced as culture supernatant, concentrated using an amicon YM30 membrane, precipitated with 50% ammonium sulfate, dialyzed against PBS, and filtered sterilized. Monoclonal antibody

OX19 is an IgG1 antibody. The antibody concentration was determined by the radial immunodiffusion technique of Mancini using a sheep anti-mouse IgG antiserum (Organon Technika) and commercially available murine gamma globulin (Organon Technika) to establish a standard curve. A pilot study established a dose of 0.3 mg intraperitoneally to be effective in completely eliminating circulating OX19⁺ blood cells. All animals underwent uninephrectomy on day minus 6. Group A (N = 5) received daily intraperitoneal injections of 1.0 g of BSA (Sigma Fraction V, No. A 4503); Group B (N = 5) was given daily BSA as above but also received OX19 monoclonal antibody (0.3 mg) given intraperitoneally beginning on day minus one, which then was given daily a few hours before BSA injection; Group C (N = 5) was saline-injected controls. Timed urine collections (24 hours) were obtained the day before killing. Animals were killed on day 10 by exsanguination as described above. Mononuclear cells were isolated from 3.0 ml of heparinized blood from each rat by Ficoll-Hypaque density gradient centrifugation. The total number of cells was counted using a hemocytometer chamber, and the number of OX19⁺ cells was determined by indirect-immunofluorescent staining as previously described.¹² The renal interstitial cell infiltrate was evaluated quantitatively for cells expressing surface markers OX19, OX8, OX42, and Ia.

Experimental Design IV: The Effect of Renal Mass on the Severity of Tubulointerstitial Nephritis

The experimental protocol described in Study I was used to compare the severity of tubulointerstitial nephritis in uninephrectomized rats with interstitial disease in rats with two native kidneys. Nephrectomies were performed on day minus 1 and the animals were killed on day 9. Urine collections (24 hours) were obtained on days 5 and 8.

Table 2. Mean Plasma Creatinine

Week	Protein overload (umol/L)	Control (umol/L)
1	44.3 ± 12.9	46.0 ± 2.8
2	49.0 ± 7.4*	38.3 ± 7.1
4	51.2 ± 4.5	47.6 ± 4.5
7	49.8 ± 1.7	52.5 ± 2.1

* $P < 0.05$.

Results are expressed as mean ± 1 SD for experimental (N = 4) and control (N = 2) animals and represent values for animals sacrificed at each of these time periods.

Group I (N = 5) was nephrectomized and received daily BSA; Group II (N = 4) had two native kidneys and received daily BSA; Group III (N = 3) was saline injected uninephrectomized controls, and Group IV (N = 3) was saline-injected controls with two native kidneys. The interstitial infiltrate was evaluated quantitatively for cells expressing surface markers OX19, OX42, and Ia.

Statistical Analysis

All results are expressed as the group mean ± 1 standard deviation. Results of the biochemical studies were compared using a two-tailed Student's *t*-test for independent means. Results of the tubulointerstitial cell studies were assessed using Bonferroni's *t*-test.⁴¹ A *P* value of less than 0.05 was considered significant.

Results

Study I: BSA-Induced Tubulointerstitial Disease

Biochemical Profile

The plasma creatinine levels of experimental animals did not differ significantly from control animals except at 2 weeks, the period of peak proteinuria (Table 2). BSA-treated animals were hyperproteinemic at 1, 2, and 4 but not at 7 weeks (Table 3). Significant levels of BSA were detected in the plasma of all experimental animals.

Table 3. Plasma Protein Profile

Week	Total protein (mg/ml)		Plasma BSA (mg/ml)	
	Protein-overload	Control	Protein-overload	Control
1	64.3 ± 3.5*	46.2 ± 4.0	26.8 ± 3.8*	0.03 ± 0.04
2	65.1 ± 3.3*	48.3 ± 3.3	27.8 ± 2.7*	0.08 ± 0.02
4	67.9 ± 4.7*	49.8 ± 4.1	20.3 ± 6.2*	0
7	65.3 ± 0.6	65.0 ± 3.7	7.0 ± 1.1*	0

* Results expressed as mean ± 1 SD; $P < 0.05$.

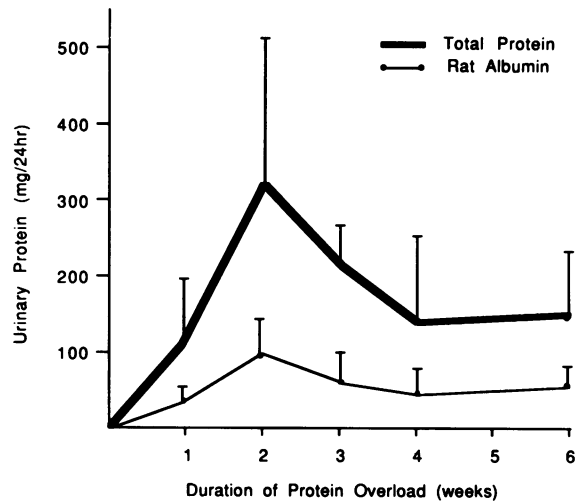


Figure 1. Urinary protein excretion rates in experimental rats with protein-overload proteinuria. The bold line represents total urinary protein. The value obtained for control animals (N = 24) was 2.1 ± 1.8 mg/24 hours (range, 0.1–8.7 mg/24 hours). The narrower line illustrates the urinary levels of rat albumin. Control animals (N = 24) excreted a mean of 0.17 ± 0.16 mg/24 hours (range, 0–0.68 mg/24 hours). All values are mean ± 1 standard deviation with an experimental sample size at 1, 2, 3, 4, and 6 weeks of 15, 11, 8, 8, and 4 experimental animals, respectively.

Plasma Anti-BSA Levels

No evidence of circulating anti-BSA antibodies could be found by double gel diffusion. By contrast, commercially purchased anti-BSA antiserum produced strong precipitation bands at all titers tested (1:1 to 1:32 dilutions of a 1 mg/ml solution)

Urinary Protein

Protein-overload animals developed significant proteinuria (Figure 1) reaching a peak mean at 2 weeks of 316 ± 198 mg/24 hours. Thereafter, the levels decreased to a plateau of 141 to 216 mg/24 hours. A significant proportion of the urinary protein was rat albumin. The mean percentage of rat albumin at 1, 2, 3, 4, and 6 weeks was 36%, 32%, 29%, 38%, and 43%, respectively.

Characterization of the Tubulointerstitial Cellular Infiltrate

Uninephrectomized rats receiving daily parenteral injections of BSA had evidence of interstitial nephritis when first examined at 7 days. This early lesion was characterized by an infiltration of macrophages identified by the presence of cell surface markers reactive with monoclonal antibodies OX42 and Ia (Figures 2 and 3). At all subsequent experimental periods, macrophages remained the dominant mononuclear cell populating the interstitium.

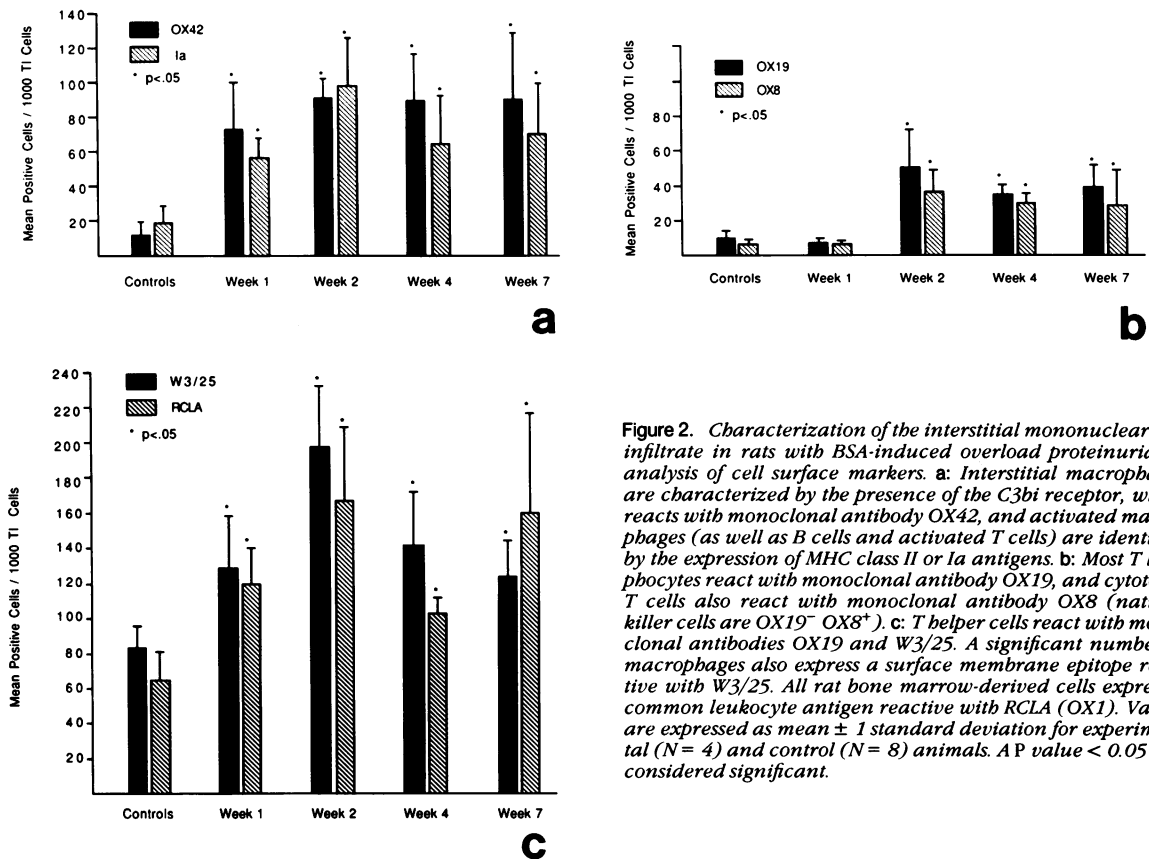


Figure 2. Characterization of the interstitial mononuclear cell infiltrate in rats with BSA-induced overload proteinuria by analysis of cell surface markers. **a:** Interstitial macrophages are characterized by the presence of the C3bi receptor, which reacts with monoclonal antibody OX42, and activated macrophages (as well as B cells and activated T cells) are identified by the expression of MHC class II or Ia antigens. **b:** Most T lymphocytes react with monoclonal antibody OX19, and cytotoxic T cells also react with monoclonal antibody OX8 (natural killer cells are OX19⁻ OX8⁺). **c:** T helper cells react with monoclonal antibodies OX19 and W3/25. A significant number of macrophages also express a surface membrane epitope reactive with W3/25. All rat bone marrow-derived cells express a common leukocyte antigen reactive with RCLA (OX1). Values are expressed as mean \pm 1 standard deviation for experimental (N = 4) and control (N = 8) animals. A P value < 0.05 was considered significant.

Significant numbers of lymphocytes first appeared at 2 weeks and appeared to represent a mixed infiltrate of T cytotoxic cells (31⁺/1000 TI cells) (Figures 2 and 3) and T helper cells. The latter cannot be absolutely quantitated due to the lack of a monoclonal antibody probe that is specific and sensitive for T helper cells. The difference between the net increase in OX19⁺ cells and OX8⁺ cells at 2 weeks suggests that the net increase in T helper cells was 13.5/1000 TI cells. The anti-T helper antibody, W3/25, cross reacts with peritubular capillaries and most macrophages. At 2 weeks, the net increase in W3/25⁺ cells minus the net increase in OX42⁺ cells (mainly macrophages) was 34.1/1000 TI cells. It can only be estimated that the absolute increase in T helper cells lies within this range of values. T lymphocytes persisted at 4 and 7 weeks and appeared to be primarily T cytotoxic cells. At 4 weeks, a mean of 37/1000 TI cells was reactive with OX19 ($P < 0.01$) and a mean of 32/1000 TI cells was reactive with OX8 ($P < 0.01$). At 7 weeks, a mean of 39/1000 TI cells was reactive with OX19 ($P < 0.01$) and a mean of 31/1000 TI cells was reactive with OX8 ($P = 0.025$). Studies using monoclonal antibody OX22 (not shown in Figures), which reacts with a subset of T helper cells, showed a small but significant increase in OX22⁺ T cells at weeks 1, 2, and 4. The group means \pm 1 standard deviation were controls, 0.4 ± 0.5 ; week 1, 3.0 ± 2.4 ;

week 2, 3.3 ± 2.2 ; week 4, 3.5 ± 1.9 ; and week 7, 5.0 ± 6.7 OX22⁺/1000 TI cells.

Cell counts for RCLA-reactive cells (all bone-marrow derived cells) are high in control animals (Figure 2c) due to the reactivity of RCLA with unidentified interstitial material, making this antibody a less sensitive cellular probe for studies of the renal interstitium.

A relationship was observed between the degree of proteinuria (maximum 24-hour urinary protein) and the intensity of the interstitial mononuclear cell infiltrate. By linear regression the correlation coefficients were all significant ($P < 0.05$); OX42 = 0.63, Ia = 0.61, OX19 = 0.64, OX8 = 0.57, and W3/25 = 0.54.

Additional Immunohistochemical Studies

By indirect immunofluorescence, BSA was observed throughout the interstitium of experimental animals in a homogeneous, nonspecific pattern. This staining was 2 or 3+ in intensity until week 7 when the decreased intensity corresponded to the period when plasma BSA levels had declined. Within tubular epithelial cells, positive protein reabsorption droplets were frequently observed at 1 week but occurred considerably less frequently thereafter. Occasional foci of epithelial cells demonstrated bright cytoplasmic staining for BSA. Granular deposits suggestive

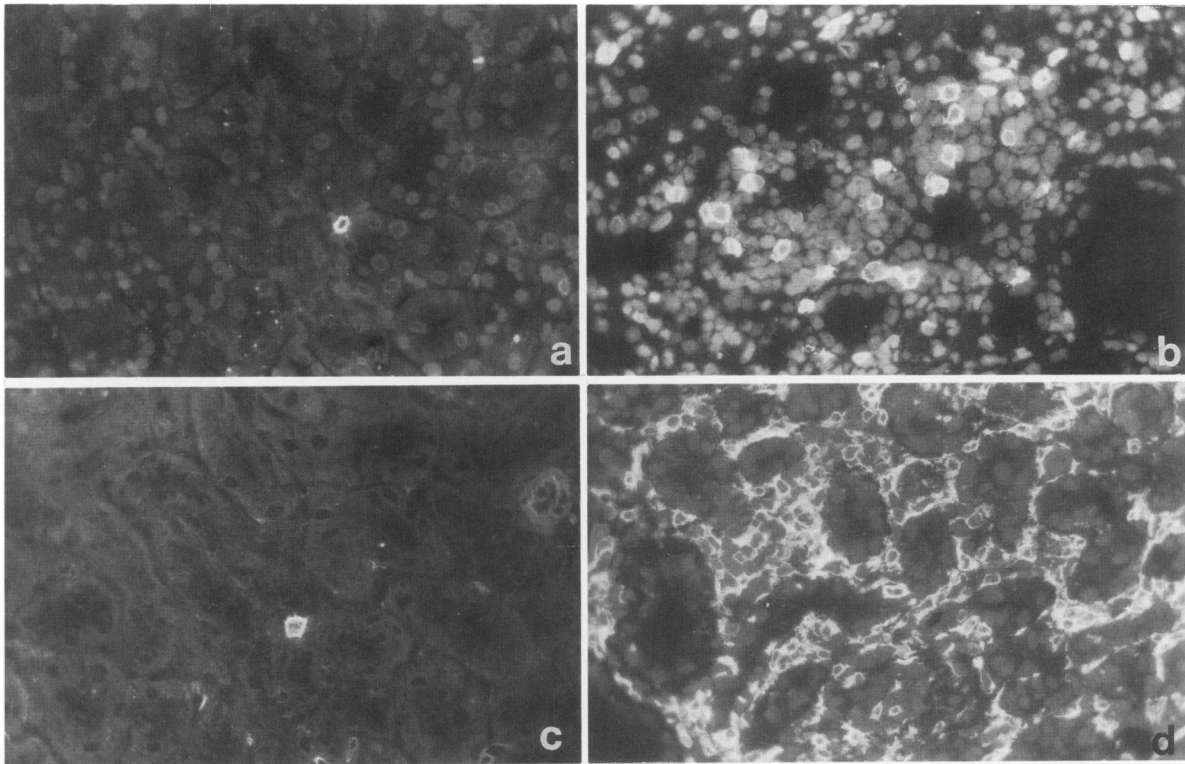


Figure 3. Immunofluorescence photomicrographs illustrating interstitial mononuclear cells. A single OX8-positive cytotoxic T cell (a) and OX42 positive macrophage (c) are seen in the renal cortical interstitium of a normal rat. After 4 weeks of BSA-induced overload proteinuria, a significant number of OX8⁺ (b) and OX42⁺ (d) mononuclear cells infiltrated the interstitium. Cell nuclei are faintly visible due to the nuclear stain ethidium bromide (a, $\times 250$; b, $\times 250$; c, $\times 270$; d, $\times 240$).

of immune complexes were never seen. Proteinaceous material within tubular lumina stained weakly for BSA but occasionally formed bright tubular casts. All control animals were negative for BSA staining.

As previously reported,³⁸ normal rat kidney tubular epithelial cells do not express vimentin intermediate filaments. In the kidney these filaments are normally expressed only in the cells of blood vessels, peritubular capillaries, and glomeruli (Figure 4). In rats given daily injections of BSA, tubular epithelial cells strongly express vimentin at all periods of study, although the early periods (weeks 1 and 2) were slightly more impressive than the later periods (weeks 4 and 7). Staining of tubular lumina for vimentin was always negative.

Rat C3 was present along some tubular basement membranes in a focal, interrupted linear pattern in both control and protein-overload animals (Figure 4). In addition, there was significant staining of tubular lumina of the experimental animals. Occasionally, the pattern of this latter reactivity was diffuse suggesting reactivity with proteinaceous casts. More frequently, C3 was observed in a coarse granular pattern along the luminal border of tubular epithelial cells (Figure 4). Neoantigens of the membrane attack complex of complement C5b-9 were similarly distributed in a coarse-granular pattern along the luminal bor-

der of many tubules (Figure 4). This pattern of deposition was evident at 1 week and persisted throughout all periods. In control animals, C5b-9 neoantigens were only present in an interrupted linear pattern along some tubular basement membranes (TBM). This pattern of TBM reactivity was preserved in experimental animals.

Light Microscopy

Significant changes in the renal interstitium could also be appreciated by light microscopy. The mean scores for acute changes at 1, 2, 4, and 7 weeks in the protein-overload animals were 1.0, 2.3, 2.3, and 2.3, respectively. Very occasional mitotic figures were observed in the epithelial cells of proximal tubules. Proteinaceous casts were more prevalent in the medulla than in the cortex. The cellular infiltrate within the interstitium consisted almost entirely of mononuclear cells (Figure 5); it was very unusual to find a polymorphonuclear cell. Overall, the interstitial changes were more marked in the deeper regions of the cortex than in the superficial cortical zone. Mild but definite chronic changes including evidence of interstitial fibrosis were evident in all animals after 2 weeks of overload proteinuria (Figure 5). The mean chronicity scores at 1, 2, 4, and 7 weeks were 0, 0.3, 1.5, and 1.1, respectively.

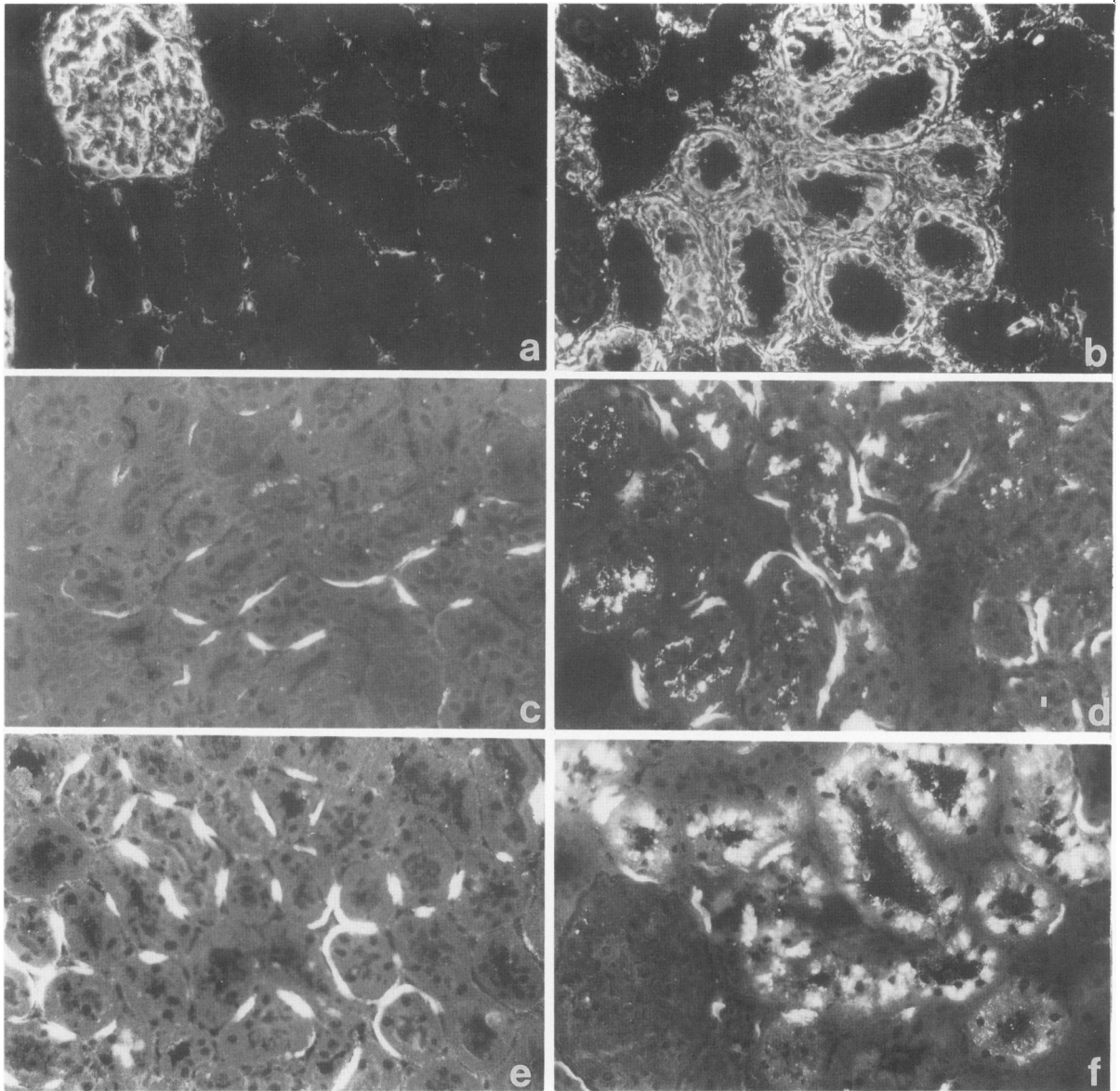


Figure 4. Photomicrographs demonstrating the deposition of vimentin intermediate filaments, rat C3 and rat C5b-9 neoantigens. By indirect immunofluorescent staining using a murine monoclonal antibody to vimentin, control kidneys show reactivity in glomeruli and peritubular capillaries whereas tubular cells are always negative (a). Not shown by this photomicrograph is the expression of vimentin filaments by normal renal arterioles. A kidney section obtained from a rat after 7 weeks of BSA-induced overload proteinuria shows strong staining of tubular epithelial cells for vimentin (b). This finding suggests that the epithelial cells are regenerating after tubular injury. Rat C5b-9 neoantigens (c) and C3 (e) are present along tubular basement membranes of control animals in a focal interrupted linear pattern. This distribution is preserved in protein-overload animals. In experimental animals, C5b-9 neoantigens (d) and C3 (f) were also deposited in a coarse granular pattern along the luminal border of tubular epithelial cells. This pattern was observed at all periods of study (a, $\times 250$; b, $\times 270$; c, $\times 280$; d, $\times 260$; e, $\times 250$; f, $\times 250$).

Glomerular Pathology

By routine light microscopy, glomeruli from BSA-injected rats were slightly enlarged. The epithelial cells were prominent and contained large PAS-positive granules. Glomerular hypercellularity and sclerosis were not observed. By immunofluorescence microscopy large droplets were seen in some glomeruli that stained for rat IgG, rat C3, BSA, and, less frequently, for rat IgM and C5b-9 neoantigens. Staining of normal rat glomeruli for IgG, IgM,

C3, and C5b-9 neoantigens varied from negative to a focal, segmental fine granular pattern in the mesangium and occasionally along the endothelial aspect of the glomerular basement membrane. In experimental animals a focal segment increase in mesangial staining was observed for all immune reactants. By electron microscopy the large glomerular droplets were identified as swollen cytoplasmic vesicles containing electron-dense material. No extracellular electron-dense deposits were seen.

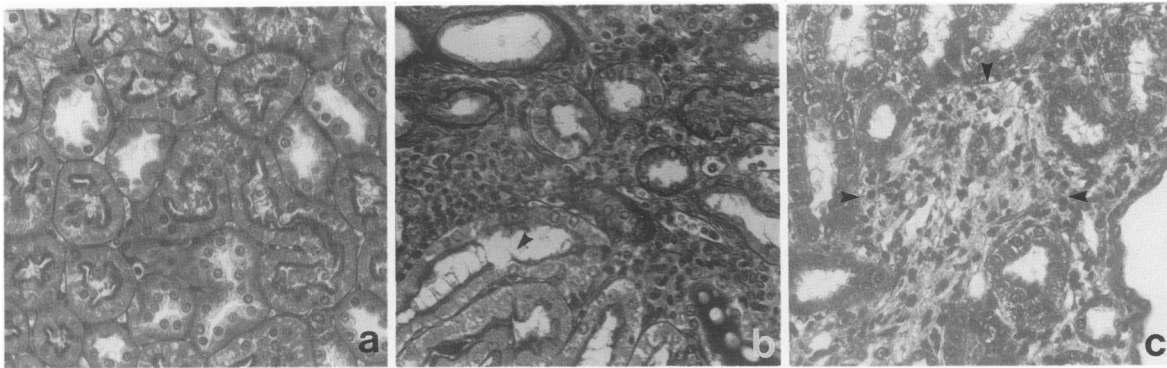


Figure 5. Light photomicrographs illustrating the histologic changes present in the renal interstitium of rats with BSA-induced overload proteinuria. In contrast to the normal rat kidney (a), by 4 weeks (b) an interstitial mononuclear cell infiltrate associated with foci of tubular epithelial disruption (arrow) is evident in sections stained with periodic acid-Schiff (c). Masson's trichrome stain at 7 weeks demonstrates a region of interstitial fibrosis (arrows) associated with a mononuclear cell infiltrate (a, $\times 260$; b, $\times 250$; c, $\times 270$).

Study II: Comparison of RSA and BSA Overload-Proteinuria

Due to the extreme difficulty in obtaining large quantities of RSA, it was necessary to modify the original protocol by reducing the protein dose to 0.7 g daily for 10 days, and only two rats could be studied. This sample size was inadequate to perform meaningful statistical analysis but the trends observed merit presentation and are summarized in Table 4. Compared with the saline control group, both the RSA- and BSA-injected groups developed important proteinuria, slightly elevated systemic blood pressure (day 8), and modestly increased total plasma proteins. An interstitial infiltrate of mononuclear cells was present in both experimental groups, although it was more focal than the interstitial disease observed in Study I. Vimentin-positive, regenerating tubular epithelial cells were present in both protein-overload groups, but they were observed more frequently in the BSA rats compared with the RSA rats. A region of tubular cell injury and interstitial nephritis in an RSA-treated rat is shown in Figure 6.

Study III: Effect of T Cell Depletion on BSA-Induced Interstitial Nephritis

OX19 treatment effectively depleted OX19⁺ cells from the circulation and the kidney (Table 5). Group A rats devel-

oped acute TI nephritis associated with a modest increase in OX19⁺ TI cells and a larger influx of macrophages. Although Group B rats did not develop an interstitial infiltrate of T cells, the TI influx of macrophages was not significantly different from that observed in the rats receiving BSA alone.

Study IV: The Effect of Renal Mass on the Severity of Tubulointerstitial Nephritis

Uninephrectomized, BSA-injected rats (Group I) divided into two subsets for unknown reasons. Two rats developed an unusually low degree of proteinuria not observed in the earlier studies, whereas the remaining three developed proteinuria consistent with the findings in Study I. This fortuitous division led to the striking observation that the severity of the interstitial infiltrate and the degree of tubular cell injury (assessed by vimentin expression) were strongly influenced by the extent of proteinuria (Table 6). By linear regression analysis using all of the animals in Study IV, a strong positive correlation was observed between the maximum urinary protein and the number of interstitial mononuclear cells. The correlation coefficients were OX42⁺ cells, $r = 0.89$ (Figure 7); Ia⁺ cells, $r = 0.86$; and OX19⁺ cells, $r = 0.77$.

Table 4. Comparison of Overload-Proteinuria Produced by RSA and BSA

Animal group	N	B.P. mm Hg	Plasma protein g/L	Maximum total urinary protein (mg/24 hour/ 100g BW)	Antibody-positive cells/1000 tubulointerstitial cells					Vimentin PTE cell positive (%)
					OX19	OX8	W3/25	Ia	OX42	
Rat albumin	2	113 ± 11*	82 ± 12	45.8 ± 1.6	7.0 ± 0.0	5.0 ± 2.8	119.5 ± 17.7	36.5 ± 2.1	42.0 ± 11.3	10-20
Bovine albumin	4	112 ± 5	80 ± 3	54.9 ± 15.7	12.3 ± 5.1	7.8 ± 1.5	98.5 ± 10.2	34.5 ± 10.0	99.8 ± 15.1	25-50
Saline	4	99 ± 5	69 ± 4	0.4 ± 0.3	5.0 ± 3.2	5.5 ± 3.1	81.3 ± 8.3	23.8 ± 7.6	26.5 ± 7.0	<5

* Results are expressed as mean ± 1 SD. PTE, cortical proximal tubular epithelial cells; BW: body weight.

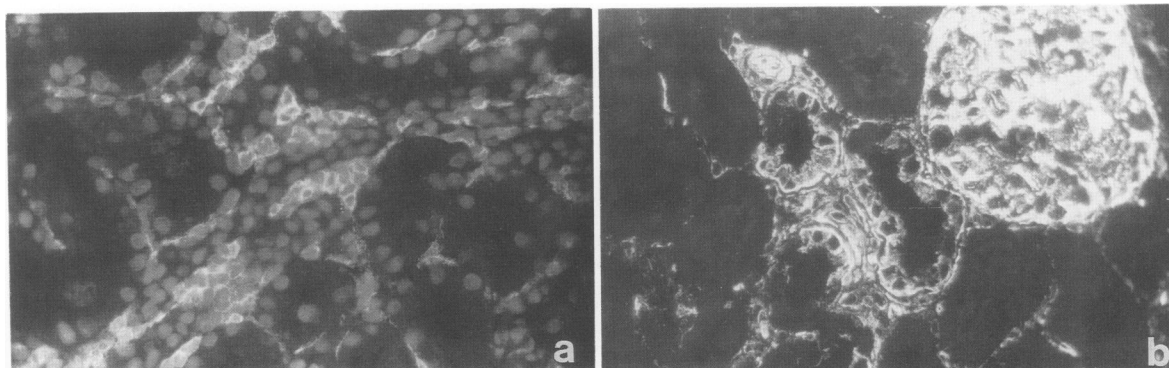


Figure 6. Immunofluorescence photomicrographs illustrating a focal area of tubulointerstitial disease in a uninephrectomized rat after daily parenteral injections of rat-albumin-enriched plasma. An influx of mononuclear cells expressing surface marker W3/25 is present (a). Foci of regenerating tubular epithelial cells adjacent to a glomerulus are identified by the positive staining for vimentin (b) (a, $\times 250$; b, $\times 340$).

Discussion

Rats with protein-overload proteinuria induced by the parenteral administration of heterologous albumin develop acute tubulointerstitial nephritis (Figure 8), a finding that has not been published previously. When first examined at 1 week, the interstitium of the renal cortex was infiltrated by a significant population of macrophages. By 2 weeks, interstitial macrophages increased to 5.9 \times controls and they remained constant at this level throughout the remainder of the study. Significant numbers of lymphocytes first appeared at 2 weeks and appeared to represent a mixed infiltrate of T cytotoxic cells and T helper cells. Thereafter, T cytotoxic cells accounted for most of the T cells present in the interstitial infiltrate. This composition of interstitial mononuclear cells, namely a large population of macrophages accompanied by lesser numbers of cytotoxic T lymphocytes, was similar to our findings in aminonucleoside nephrosis.¹² Cytotoxic T cells are emerging as an important mediator of tubulointerstitial nephritis. They represent the dominant lymphocyte subclass in interstitial nephritis associated with experimental renal allograft rejection⁴² and aminonucleoside nephrosis.¹² In addition, they account for 16% to 38% of the T lymphocyte population in Brown-Norway rats with anti-

TBM nephritis,⁴³ are present at 3.2 \times control numbers in rats with albuminuria 6 months after 5/6 nephrectomy,⁴⁴ are present in rats after acute ureteral obstruction,⁴⁵ and have recently been reported in patients with reflux nephropathy.⁴⁶ Whether this interstitial infiltrate of mononuclear cells plays a primary or secondary role in renal injury is presently unknown. However, it is noteworthy that mononuclear cells and macrophages in particular secrete a variety of soluble factors that have the potential to stimulate fibroblasts, including those resident within the renal interstitium.⁴⁷ The early infiltration of these cells into the interstitium may provide the vital link that leads to the development of interstitial fibrosis and the progressive deterioration of renal function associated with chronic renal disease.

Although the effects of chronic proteinuria on renal structure and function are generally unknown, additional studies support its association with tubulointerstitial pathology. Significant interstitial nephritis was reported in other models of experimental proteinuria induced by a variety of mechanisms including drugs such as aminonucleoside¹² and adriamycin,⁴⁸⁻⁵³ hyperfiltration after 5/6 nephrectomy,^{44,54,55} and antibody-complement-induced mesangial cell injury.⁵⁶ Proteinuria may intensify pre-existing tubular injury as demonstrated by the effect of infusion

Table 5. Effect of T Cell Depletion on BSA-Induced Tubulointerstitial Disease

Animal group	N	Proteinuria (mg/24 hour/ 100g BW)	Peripheral blood mononuclear cells		Antibody-positive cells/1000 tubulointerstitial cells			
			Total/ml blood $\times 10^6$	OX19 ⁺ /ml blood $\times 10^6$	OX19	OX8	Ia	OX42
A. BSA	5	117.7 \pm 74.9	18.2 \pm 2.7*	11.3 \pm 1.8	25.6 \pm 7.7	12.6 \pm 4.8	74.6 \pm 12.3	123.4 \pm 23.9
B. BSA plus OX19 Mab	5	77.3 \pm 50.3†	8.4 \pm 2.3†‡	0.04 \pm 0.06†‡	0.2 \pm 0.5†‡	3.8 \pm 2.9†	77.8 \pm 30.1‡	95.8 \pm 19.8‡
C. Saline control	5	0.2 \pm 0.2	16.6 \pm 3.6	10.6 \pm 2.1	5.6 \pm 3.6	5.0 \pm 2.3	34.4 \pm 10.6	14.0 \pm 5.9

* Mean \pm 1 SD.

† $P < 0.05$ Group B vs. Group A, Bonferroni's t -test.

‡ $P < 0.05$ Group B vs. controls (Group C).

Mab, Monoclonal antibody.

Table 6. Relationship Between Degree of Proteinuria and Severity of Tubulointerstitial Disease

Animal group	N	Maximum urinary protein mg/24 hours/100mg BW	Antibody-positive cells/1000 tubulointerstitial cells			Vimentin PTE cell positive (%)
			OX19	Ia	OX42	
I-A	2	46.7 ± 24.1	8.5 ± 2.1	30.5 ± 0.7	70.0 ± 0	10-25
I-B	3	435.0 ± 96.2	23.7 ± 3.1*	90.7 ± 15.9*	120.3 ± 16.5*	25-75
II	4	198.8 ± 54.1	7.5 ± 4.4	36.3 ± 11.8	75.6 ± 2.6	10-25
III	3	1.3 ± 0.4	7.0 ± 1.7	26.7 ± 6.4	18.0 ± 13.0	0
IV	3	3.1 ± 1.6	5.0 ± 1.0	29.3 ± 3.5	17.7 ± 5.5	0

* *P* < 0.05 Group I-B vs. Group II.

Group I, daily BSA, uninephrectomy. IA separated due to unusually low degree of proteinuria; Group II: daily BSA, two native kidneys; Group III: uninephrectomy controls; Group IV: two native kidney controls.

of low molecular weight proteins into rats with ischemic tubular injury.⁵⁷

In humans with chronic glomerular disease associated with renal insufficiency, tubulointerstitial changes are uniformly present. In this population of patients, significant persistent proteinuria is a clinical predictor of progressive renal failure⁵⁸⁻⁷⁸ and yet very few studies have attempted to directly correlate quantitative scores for interstitial histopathology with the severity of proteinuria. It has been shown that patients with nephrotic-range proteinuria are more likely to have chronic interstitial disease.^{63,66} Patients with lupus nephritis associated with interstitial disease are more likely to have significant proteinuria at the time of biopsy.⁷⁹ In a recent study of 145 renal biopsies from patients with glomerulonephritis, all patients except those with minimal lesion nephrotic syndrome had increased numbers of interstitial leukocytes.⁸⁰ In fact, minimal lesion nephrotic syndrome represents the one outstanding exception to this hypothesis because acute tubulointerstitial disease is only occasionally observed. However, this particular disease represents a unique situation in which there are minimal changes in glomerular morphology and the proteinuria is highly selective, consisting primarily of albumin and lesser quantities of low molecular weight proteins. These features may provide important clues for unraveling the basis of this apparent relationship.

The mechanism by which proteinuria possibly induces tubulointerstitial nephritis is a subject for speculation. In

the present study, overload proteinuria was produced by the daily administration of a heterologous protein (BSA), a finding raising the possibility that immunologic factors played a role in its genesis. However, this experimental model has been studied for at least 40 years^{81,82} and to date there is no compelling evidence to support immunopathologic mechanisms in the pathogenesis of proteinuria. Humoral mechanisms certainly seem unlikely. Native BSA is a poor immunogen in rats.⁸³ In the present study, deposits of rat IgG were not detected by direct immunofluorescence along the tubules or within the interstitium at any period, and circulating antibodies to BSA were not detected. Proteinuria begins within 24 hours of initiation of protein-overload, a timing that is inconsistent with classical humoral immune mechanisms in nonpresensitized animals. Studies of the glomerular lesions in these animals failed to demonstrate immune complex deposition. The inability of T cell depletion to inhibit tubular cell injury and the interstitial influx of macrophages argues against a significant role for cellular immune mechanisms in the patho-

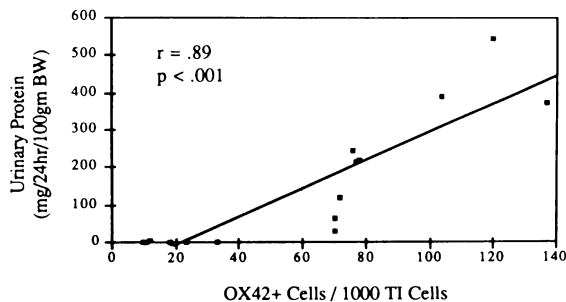


Figure 7. Relationship of maximum urinary protein excretion rates and severity of the interstitial influx of OX42⁺ mononuclear cells.

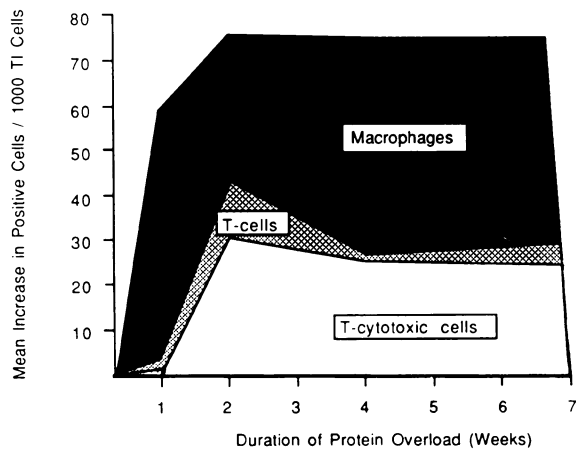


Figure 8. Schematic summary of the mononuclear cell infiltrate present in the renal interstitium of rats with protein-overload proteinuria. This graph illustrates the absolute increase in positive interstitial cells reactive with monoclonal antibodies OX42 (macrophages in black area), OX19 (T cells in hatched area), and OX8 (T cytotoxic cells in white area) calculated as the mean number of positive cells at each period minus the mean number of positive cells in control animals.

genesis of this disease. Finally, our limited studies of overload-proteinuria using homologous plasma confirmed the presence of tubulointerstitial inflammation providing additional evidence that classical immune mechanisms do not play a primary role. In the single published report of overload-proteinuria induced in rats by homologous albumin injections,⁶⁴ TIN was not observed by routine light microscopy. However, this was a two-kidney model and the severity of the proteinuria was less marked (peak of 131 mg/24 hours compared with a peak of 316 mg/24 hours in the present study). Because the degree of proteinuria correlates with the severity of the interstitial disease and monoclonal antibody analyses for interstitial cells were not performed, it is conceivable that mild interstitial disease was overlooked. It is noteworthy that rats with a transplantable pituitary tumor (Mit SA5) develop homologous protein-overload proteinuria due to growth hormone-induced liver hyperplasia and the overproduction of albumin.¹⁹ These animals develop impressive renal enlargement, and tubulointerstitial changes were evident in the published light photomicrograph.

Tubulointerstitial nephritis in the present model of overload-proteinuria does not appear to be secondary to significant proximal tubular obstruction or ischemia based on the findings on light microscopy. We speculate that the interstitial mononuclear cell infiltrate is a response to proteinuria-induced tubular epithelial cell injury. Several investigators described morphologic changes in tubular epithelial cells during protein-overload proteinuria, suggesting the presence of cell damage. The demonstration of vimentin intermediate filaments within renal tubular cells is consistent with epithelial cell regeneration after cell injury. The tubular epithelial cells of BSA-treated rats strongly expressed vimentin as opposed to control rats in which this was never observed. The absence of vimentin within luminal spaces makes it unlikely that this change represents reabsorption of vimentin from luminal surfaces. Based on the observation that the lysosomal enzyme activity of proximal tubular cells increases in response to glomerular proteinuria,^{17,18,85-90} and that excessive proteinuria causes leakage of lysosomal enzymes into the cytoplasm of tubular cells, Maack et al^{86,91-93} suggested that the excess concentration of absorbed proteins within tubular lysosomes may in itself lead to tubular epithelial cell damage. Using *in vivo* perfusion of rat proximal tubules, Sanders et al⁹⁴ demonstrated that certain low molecular weight proteins had a direct toxic effect on tubular cells. Although the toxic mechanism was not determined, these investigators also suggested a role for lysosome-induced cell injury. This is an attractive hypothesis that unifies several models of tubulointerstitial injury such as myeloma-associated nephropathy, severe toxic and ischemic nephropathy, chronic pyelonephritis, and proteinuria-induced tubulointerstitial nephritis with tubular epithelial cell

injury and disruption being the final common pathway leading to interstitial inflammation. The outcome of the interstitial injury largely depends on the severity and reversibility of the initial insult, with severe and prolonged injury progressing to chronic interstitial damage associated with interstitial fibrosis and tubular atrophy.

The results of the immunofluorescence studies suggest that the complement cascade may have a role to play in the pathogenesis of the tubulointerstitial lesion of heterologous protein-overload. Neoantigens expressed after the activation of the membrane attack complex of complement C5b-9 were frequently deposited along the luminal border of tubular epithelial cells. It is unlikely that these deposits represent absorption of complexes filtered at the level of the glomerulus due to the large size of the molecule.⁹⁵ *In vitro* studies using sections of frozen rat kidney showed that proximal tubular epithelial cells are capable of directly activating the alternative pathway of the complement system.⁹⁶ Complement activation may provide a mechanism for recruitment of mononuclear cells, whereas the terminal C5b-9 complex may directly induce tubular cell injury through its membranolytic actions.^{37,97}

In summary, in this study we found the development of tubulointerstitial nephritis to be associated with protein-overload proteinuria induced by heterologous albumin. The acute interstitial cellular lesion is characterized by an early and persistent influx of macrophages followed by the presence of T lymphocytes. Chronic interstitial injury is evident by 4 weeks. The severity of the cellular infiltrate correlates with the degree of proteinuria. The influx of macrophages appears to be independent of classical humoral and cellular immune reactions, and further studies are needed to delineate specific afferent and efferent pathways. These findings may strengthen the scientific rationale for clinical trials designed to slow the rate of progression to end-stage renal disease by the use of dietary protein restriction or angiotensin 1-converting enzyme inhibitors, both of which decrease the degree of proteinuria and alter intraglomerular hypertension.

References

1. Bohle A, vGise H, Mackensen-Haen S, Stark-Jakob B: The obliteration of the post glomerular capillaries and its influence upon the function of both glomeruli and tubuli. *Klin Wochenschr* 1981, 59:1043-1051
2. Heptinstall RH: Chronic glomerulonephritis, end-stage kidney and visceral changes in chronic renal failure. *Pathology of the Kidney*. Edited by RH Heptinstall. Boston, Little, Brown and Co 1983, pp 601-636
3. Haen M, Mackensen-Haen S, Klingebiel T, Stark-Jakob B, Christ H, Bohle A: Creatine clearance and renal interstitium in

- diffuse endocapillary proliferative glomerulonephritis. *Pathol Res Pract* 1985, 179:462-468
4. Hyman LR, Burkholder PM: Focal sclerosing glomerulopathy with segmental hyalinosis. A clinicopathologic analysis. *Lab Invest* 1973, 28:533-544
 5. Bohle A, Christ H, Grund KE, Mackensen S: The role of the interstitium of the renal cortex in renal disease. *Contrib Nephrol* 1979, 16:109-114
 6. Mackensen S, Grund KE, Sindjic M, Bohle A: Influence of the renal cortical interstitium on the serum creatinine concentration and serum creatinine clearance in different chronic sclerosing interstitial nephritides. *Nephron* 1979, 24:30-34
 7. Nagy J, Miltényi M, Dobos M, Burger T: Tubular proteinuria in IgA glomerulonephritis. *Clin Nephrol* 1987, 27:76-78
 8. Park MH, D'Agati V, Appel GB, Pirani CL: Tubulointerstitial disease in lupus nephritis: Relationship to immune deposits, interstitial inflammation, glomerular changes, renal function, and prognosis. *Nephron* 1986, 44:309-319
 9. Portman RJ, Kissane JM, Robson AM: Use of beta-2 microglobulin to diagnose tubulo-interstitial renal lesions in children. *Kidney Int* 1986, 30:91-98
 10. Schainuck LI, Striker GE, Cutler RE, Benditt EP: Structural-functional correlations in renal disease. Part II: The correlations. *Hum Pathol* 1970, 1:631-641
 11. Schwartz MM, Fennell JS, Lewis EJ: Pathologic changes in the renal tubule in systemic lupus erythematosus. *Hum Pathol* 1982, 13:534-547
 12. Eddy AA, Michael AF: Acute tubulointerstitial nephritis associated with aminonucleoside nephrosis. *Kidney Int* 1988, 33:14-23
 13. Anderson MS, Recant L: Fine structural alterations in the rat kidney following intraperitoneal bovine albumin. *Am J Pathol* 1962, 40:555-560
 14. Andrews PM: A scanning and transmission electron microscopic comparison of puromycin aminonucleoside-induced nephrosis to hyperalbuminemia-induced proteinuria with emphasis on kidney podocyte pedicel loss. *Lab Invest* 1977, 36:183-197
 15. Davies DJ, Brewer DB, Hardwicke J: Urinary proteins and glomerular morphometry in protein overload proteinuria. *Lab Invest* 1978, 38:232-243
 16. Fisher ER, Hellstrom HR: Mechanism of proteinuria: Functional and ultrastructural correlation of effects of infusion of homologous and heterologous protein (bovine serum albumin) in the rat. *Lab Invest* 1962, 11:617-637
 17. Gregoire F: Kidney enzyme changes in experimental proteinuria. *Lab Invest* 1971, 25:626-634
 18. Karl IE, Garcia P, White WL, Recant L, Kissane JM: Proteinuria induced by albumin injection: Effect on kidney and liver enzymes in the rat. *Lab Invest* 1964, 13:1600-1611
 19. Mori H, Yamashita H, Nakanishi C, Koizumi K, Makino S, Kishimota Y, Hayashi Y: Proteinuria induced by transplantable rat pituitary tumor MtT SA5: Model for homologous protein-overload proteinuria. *Lab Invest* 1986, 54:636-644
 20. Davies DJ, Brewer DB: Irreversible glomerular damage following heterologous serum albumin overload. *J Pathol* 1977, 123:45-52
 21. Marks MI, Drummond KN: Nephropathy and persistent proteinuria after albumin administration in the rat. *Lab Invest* 1970, 23:416-420
 22. Ouchterlong O: Diffusion-in-gel methods for immunological analysis II. *Prog Allergy* 1962, 6:30-154
 23. Eddy AA, Crary GS, Michael AF: Identification of lymphohemopoietic cells in the kidneys of normal rats. *Am J Pathol* 1986, 124:335-342
 24. Sunderland CA, McMaster WR, Williams AF: Purification with monoclonal antibody of a predominant leukocyte-common antigen and glycoprotein from rat thymocytes. *Eur J Immunol* 1979, 9:155-159
 25. Woollett GR, Barclay AN, Puklavec M, Williams AF: Molecular and antigenic heterogeneity of the rat leukocyte-common antigen from rat thymocytes. *Eur J Immunol* 1985, 15:168-173
 26. Dallman JM, Mason DW, Webb M: The role of host and donor cells in the rejection of skin allografts by T cell-deprived rats injected with syngenic T cells. *Eur J Immunol* 1982, 12:511-518
 27. Woda BA, McFadden ML, Welsh RM, Bain KM: Separation and isolation of rat natural killer (NK) cells from T cells with monoclonal antibodies. *J Immunol* 1984, 132:2183-2184
 28. Mason DW, Brideau RJ, McMaster WR, Webb M, White RAH, Williams AF: Monoclonal antibodies that define T-lymphocyte subsets in the rat. *Monoclonal Antibodies*. Edited by RH Kennett, TJ McKeam, KB Bechlol. New York, Plenum Publishing Corp 1980, pp 251-273
 29. Mason DW, Arthur RP, Dallman MJ, Green JR, Spickett GP, Thomas ML: Functions of rat T-lymphocyte subsets isolated by means of monoclonal antibodies. *Immunol Rev* 1983, 74:57-82
 30. Thomas ML, Green JR: Molecular nature of the W3/25 and MRC OX-8 marker antigens for rat T lymphocyte: Comparisons with mouse and human antigens. *Eur J Immunol* 1983, 13:855-858
 31. Williams AF, Galfre G, Milstein C: Analysis of cell surfaces by xenogeneic myeloma-hybrid antibodies: Differentiation antigens of rat lymphocytes. *Cell* 1977, 12:663-673
 32. Brideau RJ, Carter PB, McMaster WR, Mason DW, Williams AF: Two subsets of rat T lymphocytes defined with monoclonal antibodies. *Eur J Immunol* 1980, 10:609-615
 33. Green JR: Generation of cytotoxic T cells in the rat mixed lymphocyte reaction is blocked by monoclonal antibody MRC OX-8. *Immunology* 1984, 52:253-260
 34. Robinson AP, White TM, Mason DW: Macrophage heterogeneity in the rat as delineated by two monoclonal antibodies MRC OX-41 and MRC OX-42, the latter recognizing complement receptor type 3. *Immunology* 1986, 57:239-247
 35. McMaster WR, Williams AF: Identification of Ia glycoproteins in rat thymus and purification from rat spleen. *Eur J Immunol* 1979, 9:426-433
 36. Spickett GP, Brandon MR, Mason DW, Williams AF, Woollett GR: MRC OX-22: A monoclonal antibody that labels a new subset of T lymphocytes and reacts with the high molecular weight form of the leukocyte-common antigen. *J Exp Med* 1983, 158:785-810

37. Couser WG, Baker PJ, Adler S: Complement and the direct mediation of immune glomerular injury: A new perspective. *Kidney Int* 1985, 28:879-888
38. Grone H-J, Weber K, Grone E, Helmchen U, Osborn M: Coexpression of keratin and vimentin in damaged and regenerating tubular epithelia of the kidney. *Am J Pathol* 1987, 129:1-8
39. Holmdahl R, Olsson T, Moran T, Klareskog L: In vivo treatment of rats with monoclonal anti-T-Cell antibodies: Immunohistochemical and functional analysis in normal rats and in experimental allergic neuritis. *Scand J Immunol* 1985, 22: 157-169
40. Like AA, Biron CA, Weringer EJ, Byman K, Sroczynski E, Guberski DL: Prevention of diabetes in biobreeding/Worcester rats with monoclonal antibodies that recognize T lymphocytes or natural killer cells. *J Exp Med* 1986, 164: 1145-1159
41. Wallenstein S, Zucker CL, Fleiss JL: Some statistical methods useful in circulation research. *Circ Res* 1980, 47:1-9
42. Bradley JA, Mason DW, Morris PJ: Evidence that rat renal allografts are rejected by cytotoxic T cells and not by non-specific effectors. *Transplantation* 1985, 39:169-175
43. Mampaso FM, Wilson CB: Characterization of inflammatory cells in autoimmune tubulointerstitial nephritis in rats. *Kidney Int* 1983, 23:448-457
44. Hebert D, Michael AF: Characterization of infiltrating cells in the interstitium of the rat remnant kidney (abstr). *Clin Res* 1986, 34:730A
45. Schreiner GF, Harris KPG, Purkerson ML, Klahr S: Immunological aspects of acute ureteral obstruction: Immune cell infiltrate in the kidney. *Kidney Int* 1988, 34:487-493
46. Yoshioka K, Takemura T, Matubara K, Miyamoto H, Akano N, Maki S: Immunohistochemical Studies of Reflux Nephropathy: The role of extracellular matrix, membrane attack complex, and immune cells in glomerular sclerosis. *Am J Pathol* 1987, 129:223-231
47. Nathan CF: Secretory products of macrophages. *J Clin Invest* 1987, 79:319-326
48. Bertani T, Rocchi G, Sacchi G, Mecca G, Remuzzi G: Adriamycin-induced glomerulosclerosis in the rat. *Am J Kidney Dis* 1986, 7:12-19
49. Bertani T, Cutillo F, Zoja C, Brogini M, Remuzzi G: Tubulointerstitial lesions mediate renal damage in adriamycin glomerulopathy. *Kidney Int* 1986, 30:488-49
50. Giroux L, Smeesters C, Boury F, Faure MP, Jean G: Adriamycin and adriamycin-DNA nephrotoxicity in rats. *Lab Invest* 1984, 50:190-196
51. O'Donnell MP, Michels L, Kasiske B, Raji L, Keane WF: Adriamycin-induced chronic proteinuria: A structural and functional study. *J Lab Clin Med* 1985, 106:62-67
52. Okuda S, Oh Y, Tsuruda H, Onoyama K, Fujimi S, Fujishima J: Adriamycin-induced nephropathy as a model of chronic progressive glomerular disease. *Kidney Int* 1986, 29:502-510
53. Weening JJ, Rennke HG: Glomerular permeability and polyanion in adriamycin nephrosis in the rat. *Kidney Int* 1983, 24: 152-159
54. Morrison AB: Experimentally induced chronic renal insufficiency in the rat. *Lab Invest* 1962, 11:321-332
55. Nath KA, Hostetter MK, Hostetter TH: Pathophysiology of chronic tubulo-interstitial disease in rats: Interactions of dietary acid load, ammonia, and complement component C3. *J Clin Invest* 1985, 76:667-675
56. Bagchus WM, Hoedemaeker PhJ, Rozing J, Bakker WW: Glomerulonephritis induced by monoclonal anti-thy 1.1 antibodies. *Lab Invest* 1986, 55:680-687
57. Zager RA, Teubner EJ, Adler S: Low molecular weight proteinuria exacerbates experimental ischemic renal injury. *Lab Invest* 1987, 56:180-188
58. Antoine B, Faye C: The clinical course associated with dense deposits in the kidney basement membranes. *Kidney Int* 1972, 1:420-427
59. Austin III HA, Balow JE: Henoch-Schonlein nephritis: Prognostic features and the challenge of therapy. *Am J Kidney Dis* 1983, 2:512-520
60. Beaufrils H, Alphonse JC, Guedon J, Legrain M: Focal glomerulosclerosis: Natural history and treatment. A report of 70 cases. *Nephron* 1978, 21:75-85
61. Cameron JS, Turner DR, Ogg CS, Chantler C, Williams DG: The long-term prognosis of patients with focal segmental glomerulosclerosis. *Clin Nephrol* 1978, 10:213-218
62. Clarkson AR, Seymour AE, Thompson AJ, Haynes WDG, Chan Y-L, Jackson B: IgA nephropathy: A syndrome of uniform morphology, diverse clinical features and uncertain prognosis. *Clin Nephrol* 1977, 8:459-471
63. Crocker BP, Dawson DV, Sanfilippo F: IgA Nephropathy: Correlation of Clinical and Histologic Features. *Lab Invest* 1983, 48:19-24
64. Habib R, Gubler M-C, Loirat C, Maiz HB, Levy M: Dense deposit disease: A variant of membranoproliferative glomerulonephritis. *Kidney Int* 1975, 7:204-215
65. Hood SA, Velosa JA, Holley KE, Donadio JV Jr.: IgA-IgG nephropathy: Predictive indices of progressive disease. *Clin Nephrol* 1981, 16:55-62
66. Katz A, Walker JF, Landy PJ: IgA nephritis with nephrotic range proteinuria. *Clin Nephrol* 1983, 20:67-71
67. Kobayashi Y, Tateno S, Hiki Y, Shigematsu H: IgA nephropathy: Prognostic significance of proteinuria and histological alterations. *Nephron* 1983, 34:146-153
68. Lamb V, Tisher CC, McCoy RC, Robinson RR: Membranoproliferative glomerulonephritis with dense intramembranous alterations: A clinico-pathologic study. *Lab Invest* 1977, 36:607-617
69. Levy M, Broyer M, Arsan A, Levy-Bentolila A, Habib R: Anaphylactoid purpura nephritis in childhood: Natural history and immunopathology, *Advances in Nephrology*, Vol. 6. Edited by J Hamburger, J Crosnier, M Maxwell. Chicago, Year Book Medical Publishers 1976, pp 183-228
70. Levy M, Gubler M-C, Habib R: New concepts in membranoproliferative glomerulonephritis, *Progress in Glomerulonephritis*. Edited by P Kincaid-Smith, AJR D'Apice, RC Atkins. New York, Wiley 1979, pp 177-200
71. Magil AB, Price JDE, Bower G, Rance CP, Huber J, Chase WH: Membrano-proliferative glomerulonephritis Type I:

- Comparison of natural history in children and adults. *Clin Nephrol* 1979, 11:239-244
72. Noel LH, Zanetti M, Droz D, Barbanel C: Long-term prognosis of idiopathic membranous glomerulonephritis: Study of 116 untreated patients. *Am J Med* 1979, 66:82-90
 73. Nagy J, Brasch H, Trinn Cs, Burger T: Clinical features and course of IgA glomerulonephritis. *Acta Med Acad Sci Hung* 1982, 39:201-210
 74. Pierides AM, Kerr DNS: Idiopathic membranous nephropathy. *Nephron* 1978, 20:301-303
 75. Ponticelli C: Prognosis and treatment of membranous nephropathy. *Kidney Int* 1986, 29:927-940
 76. Row PG, Cameron JS, Turner DR, Evans DJ, White RHR, Ogg CS, Chantler C, Brown CB: Membranous nephropathy: Long-term follow-up and association with neoplasia. *Q J Med* 1975, 174:207-239
 77. Velosa JA, Holley KE, Torres VE, Offord KP: Significance of proteinuria on the outcome of renal function in patients with focal segmental glomerulosclerosis. *Mayo Clin Proc* 1983, 58:568-577
 78. Weiss MA, Daquiaoag E, Margolin EG, Pollak VE: Nephrotic syndrome, progressive irreversible renal failure, and glomerular "collapse": A new clinicopathologic entity? *Am J Kidney Dis* 1986, 7:20-28
 79. O'Dell JR, Hays RC, Guggenheim SJ, Steigerwald JC: Tubulointerstitial renal disease in systemic lupus erythematosus. *Arch Intern Med* 1985, 145:1996-1999
 80. Hooke DH, Gee DC, Atkins RC: Leukocyte analysis using monoclonal antibodies in human glomerulonephritis. *Kidney Int* 1987, 31:964-972
 81. Lippman RW: Mechanism of proteinuria: Effect of parenteral bovine albumin injections on hemoglobin excretion in rats. *Am J Physiol* 1948, 154:532-536
 82. Terry R, Hawkins DR, Church EH, Whipple GH: Proteinuria related to hyperproteinemia in dogs following plasma given parenterally: A renal threshold for plasma proteins. *J Exp Med* 1948, 87:561-573
 83. Muckerheide A, Apple RJ, Pesce AJ, Michael JG: Cationization of protein antigens. I. Alteration of immunogenic properties. *J Immunol* 1987, 138:833-837
 84. Schwartz MM, Bidani AK, Lewis EJ: Glomerular epithelial cell structure and function in chronic proteinuria induced by homologous protein-load. *Lab Invest* 1986, 55:673-679
 85. Van Liew JB, Brentjens JR, Noble B: Relationship of kidney function to immunopathology in chronic serum sickness of rats. *Kidney Int* 1983, 24:160-169
 86. Maack T, Park CH, Camargo MJF: Renal filtration, transport, and metabolism of proteins, *The Kidney: Physiology and Pathophysiology*. Edited by DW Seldin, G Giebisch. New York, Raven Press 1985, pp 1773-1803
 87. Kaysen GA, Myers BD, Couser WG, Rabkin R, Felts JM: Biology of Disease: Mechanisms and consequences of proteinuria. *Lab Invest* 1986, 54:479-498
 88. Olbricht CJ, Cannon JK, Tisher CC: Cathepsin B and L in nephron segments of rats with puromycin aminonucleoside nephrosis. *Kidney Int* 1987, 32:354-361
 89. Pesce AJ, Clyne DH, Pollak VE, Kant SK: Renal tubular interactions of proteins. *Clin Biochem* 1980, 13:209-215
 90. Olbricht CJ, Cannon JK, Garg LC, Tisher CC: Activities of cathepsins B and L in isolated nephron segments from proteinuric and nonproteinuric rats. *Am J Physiol* 1986, 250: F1055-F1062
 91. Maack T, Mackensie DDS, Kinter WB: Intracellular pathways of renal reabsorption of lysozyme. *Am J Physiol* 1971, 221: 1609-1616
 92. Maack T, Johnson V, Kau ST, Figueiredo J, Sigulem D: Renal filtration, transport, and metabolism of low-molecular-weight proteins: A review. *Kidney Int* 1979, 16:251-27
 93. Park CH, Maack T: Albumin absorption and catabolism by isolated perfused proximal convoluted tubules of the rabbit. *Clin Invest* 1984, 73:767-777
 94. Sanders PW, Herrera GA, Chen A, Booker BB, Galla JH: Differential nephrotoxicity of low molecular weight proteins including Bence Jones proteins in the perfused rat nephron in vivo. *J Clin Invest* 1988, 82:2086-2096
 95. Biesecker G: Biology of disease: Membrane attack complex of complement as a pathologic mediator. *Lab Invest* 1983, 49:237-249
 96. Camussi G, Rotunno M, Segoloni G, Brentjens JR, Andres GA: In vitro alternative pathway activation of complement by the brush border of proximal tubules of normal kidney. *J Immunol* 1982, 128:1659-1663
 97. Eddy AA, Michael AF: Immunopathogenic mechanisms of glomerular injury, *Renal Pathology*, 1st ed. Edited by CC Tisher, BM Brenner. Philadelphia, J. B. Lippincott Co. 1989, p 111-155

Acknowledgment

The authors appreciate the work of Ms. Eileen Barry and Julia Fischer in typing the manuscript and the technical assistance of Mr. Paul Sarkar and Dr. Gerald Ho.