

# Clinicopathologic Features of Young and Old $sph^{ha}/sph^{ha}$ Mice

## Mutants with Congenital Hemolytic Anemia

LILLIAN MAGGIO-PRICE, VMD, PhD,\*  
ROBERT RUSSELL, BVSc, MVS, PhD,†  
NORMAN S. WOLF, DVM, PhD,‡  
CHARLES E. ALPERS, MD,§ and  
DAVID ENGEL, DDS, PhD||

From the Division of Animal Medicine\*† and the Department of Pathology,\*‡§ School of Medicine and the Department of Periodontics,|| School of Dentistry, University of Washington, Seattle, Washington

A colony of mice with congenital hemolytic anemia,  $sph^{ha}/sph^{ha}$ , were evaluated over a 3-year period. Prominent findings included decreased survivability, reticulocytosis, increased peripheral blood leukocytes, extramedullary hematopoiesis in liver and spleen, lymphoid hyperplasia and membranoproliferative glomerulonephritis. Older (12 to 21 months) anemic animals had elevated serum levels of IgG1 and IgA. There was deposition of C3, IgG, IgM, and IgA in renal glomeruli of both control and anemic mice, but deposition of IgM and IgA was more prominent and widely

distributed in anemic animals and correlated with mesangial expansion and the presence of electron dense deposits in the mesangium and in glomerular capillary walls. Prominent renal tubular hemosiderosis was noted in young and old anemic mice. The relation between the hemolytic anemia and glomerular disease is unclear but these mice may be an animal model useful for exploration of changes attendant with chronic hemolysis and evaluation of renal disease that accompanies hemolytic anemia. (Am J Pathol 1988, 132:461-473)

SPONTANEOUS MUTATIONS that affect red blood cell spectrin and result in congenital hemolytic anemia have been described in the mouse.<sup>1-3</sup> The  $sph/sph$ ,  $sph^{ha}/sph^{ha}$ , and  $sph^{2BC}/sph^{2BC}$  mice have a deficiency in red blood cell membrane spectrin and spherocytic red blood cells.<sup>4-6</sup> Affected animals have a shortened red cell lifespan (1 to 2 days) and a marked hemolytic anemia, reticulocytosis, and extramedullary hematopoiesis.<sup>7-9</sup> These mice have been used in studies of hemoglobin metabolism,<sup>10</sup> for evaluation of heme oxygenase inhibitors to suppress hyperbilirubinemia,<sup>11,12</sup> and in studies involving perturbations of hematopoietic stem cells.<sup>13</sup> The authors have observed the clinicopathologic changes, attendant with chronic hemolysis, in a colony of  $sph^{ha}/sph^{ha}$  mice. In addition to the expected findings concomitant with chronic hemolysis, changes in lymphoid tissue and the development of a glomerulonephritis that was most prominent in older anemic animals also were noted. This animal model may be useful for exploration of those pathologic changes that accompany chronic hemolysis.

## Materials and Methods

### Mice

The mutant mice (WBB6F1— $sph^{ha}/sph^{ha}$ ) used in this study were produced by mating heterozygotes from two different inbred strains, WB/Re and C57B1/6J, originally obtained from the Jackson Laboratory, and reared at the University of Washington, School of Medicine. Control mice were WBB6F1—+/+. The origin of the mutant has been described previously.<sup>4</sup> Animals were housed under AAALAC conditions and maintained under specific pathogen free (SPF) barrier conditions. Mice were fed Wayne sterilizable rodent blox (Wayne Ped Food Division, Chicago, IL) and kept on bedding (1/8 inch diameter corn cob) that

Supported in part by NIH Grants RR01203, AG01751, RR05432, and RR00032.

Accepted for publication April 11, 1988.

Address reprint requests to L. Maggio-Price, Division of Animal Medicine SB-42, School of Medicine, University of Washington, Seattle, WA 98195.

Table 1—Hematologic Parameters in Young and Old *sph<sup>ha</sup>/sph<sup>ha</sup>* and +/- Mice

	Young +/-	Young <i>sph<sup>ha</sup></i>	Percent of control	Old +/-	Old <i>sph<sup>ha</sup></i>	Percent of control
Hct (%)	49.8* (± 0.4)	23.9 (± 0.3)	48	46.9 (± 0.7)	20.2 (± 0.5)	43
Retic (%)	0.9 (± 0.2)	94.4 (± 0.6)		0.7 (± 0.1)	89.7 (± 0.3)	
WBC (/mm <sup>3</sup> )	8256 (± 1067)	27,750 (± 1397)	335	5630 (± 1042)	26,240 (± 2266)	465
Neuts	720 (± 42)	2170 (± 379)	300	706 (± 171)	3909 (± 923)	555
Bands	38 (± 41)	181 (± 378)	475	54 (± 27)	260 (± 85)	480
Monos	183 (± 41)	2067 (± 378)	1130	286 (± 47)	1904 (± 402)	665
Eos	-	39 (± 23)		-	112 (± 66)	
Lymphs	4103 (± 1342)	22,624 (± 1429)	550	4221 (± 897)	15,675 (± 1778)	370

\* Mean (± SEM) derived from 7 to 21 mice.

Retic, percentage uncorrected reticulocyte count (100–200 cell count); Hct, hematocrit; WBC, white blood cell count; Neuts, neutrophils; Bands, unsegmented neutrophils; Monos, monocytes; Eos, eosinophils; Lymphs, lymphocytes.

was autoclaved according to manufacturer's instructions. Acidified water was given *ad libitum*. A quality assurance program at the University of Washington ascertained that this rodent colony was serologically negative for major rodent viral pathogens, and culture negative for 10 common bacterial pathogens. Mice were also free of rodent ecto- and endoparasites.

The age range for "young" and "old" mice was determined by animal availability. "Young" anemic and control mice were 4 to 7 months old. "Old" anemic mice were 12 to 21 months of age and "old" control mice were 14 to 32 months old. Male and female animals were evaluated in the four groups of mice.

### Blood Sampling

Blood was obtained from the retroorbital sinus of mice for hematocrits, reticulocyte counts, leukocyte counts, differential cell counts, serum chemistries, erythropoietin and immunoglobulin levels. Serum chemistry analysis included glutamic pyruvate transaminase, alkaline phosphatase, total bilirubin and direct bilirubin, total protein, albumin, globulin, cholesterol, glucose, blood urea nitrogen (BUN), creatinine, phosphorus, calcium, sodium, and potassium. Pooled sera from 10 young control, 10 acutely-bled, and 10 young anemic mice were assayed using the exhypoxic polycythemic mouse assay.<sup>14</sup> Levels of serum IgG1, IgG2b, IgG3, IgM, and IgA were assayed in five to seven young control and anemic mice and in three to seven old control and anemic mice using radial immunodiffusion (ICN Immunologicals, Lisle, IL).

### Urine and Fecal Analyses

Urine was collected from individual mice and evaluated with urine test reagent strips (Kytotest, Elkhart,

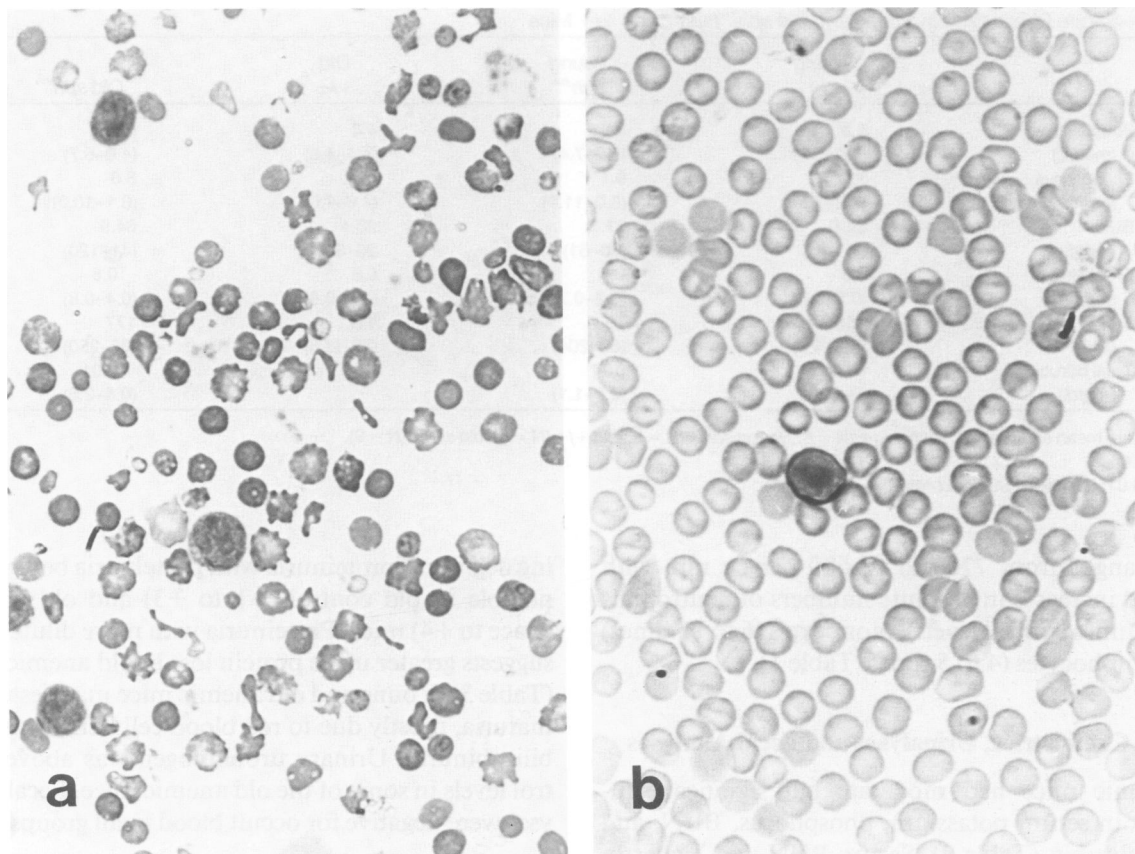
IN) for the presence of protein, bilirubin, urobilinogen, blood, and glucose. Specific gravity was determined with a refractometer (American Optical, Keene, NH). Feces were checked for occult blood by the guiac method.

### Samples for Microscopy

Mice were killed by cervical dislocation and tissues were placed in 10% buffered formalin. The following tissues were examined: thymus, heart, lung, inguinal, axillary or mesenteric lymph nodes, stomach, small and large intestine, liver, gallbladder, spleen, kidney, urinary bladder, and femoral bone marrow. Tissues for light microscopy were processed, embedded in paraffin and stained with hematoxylin and eosin (H & E). Methacrylate sections of kidney and marrow were made; marrow was stained with H & E and kidney was stained with H & E, periodic acid schiff (PAS), and methenamine silver. Gomori's iron stain was done on all tissue taken. Kidney tissue was also placed in Karnovsky's glutaraldehyde fixative for electron microscopy and one kidney was snap frozen with isopentane and liquid nitrogen for immunofluorescence. Specimens for electron microscopy were immersed in 2% osmium tetroxide for 1 hour, dehydrated in graded steps of acetone, and embedded in Epon-Araldite. Sections were cut on a Porter-Blum Ultratome, stained with uranyl acetate and lead citrate and examined with a Phillips 410 electron microscope.

### Immunofluorescence

Frozen kidney sections were made from five to eight mice in each of the four groups. Kidneys from



**Figure 1**—There is marked fragmentation of red blood cells in peripheral blood of *sph<sup>h</sup>/sph<sup>h</sup>* mice (a). Blood from normal *+/+* mice shown in b. ( $\times 3300$ , Wright-Giemsa stain)

two NZB mice (females, 6 and 8 months old) were used as positive controls. Frozen sections were cut at 4 to 6  $\mu$  in a  $-20$  C cryostat, fixed in absolute acetone at room temperature for 10 minutes, and washed in phosphate-buffered saline (PBS). Sections were stained for 10 minutes in moist chambers with 1) fluorescein conjugated rabbit anti-mouse C3 (Cooper Biomedical, Malvern, PA), 2) fluorescein conjugated rabbit anti-mouse albumin (Cappel, Malvern, PA), 3) fluorescein conjugated rabbit anti-mouse IgG (Bionetics, Charlestown, SC), 4) fluorescein conjugated rabbit anti-mouse IgM (Litton Bionetics, Kensington, MD), and 5) fluorescein conjugated rabbit anti-mouse IgA (Bionetics, Kensington, MD). Goat anti-dog IgG conjugated with fluorescein conjugated rabbit anti-goat immunoglobulin (Cappelab, Downingtown, PA) was used as a negative control. Sections were washed three times in PBS for 10 minutes, blotted dry, coverslipped with glycerol, and examined with a Zeiss immuno-fluorescent microscope. The amount of specific immunofluorescence in glomeruli was graded negative or trace to +4 positive and the staining pattern recorded (granular, linear, focal, diffuse, lobular, and segmental).

## Results

### Longevity of Mice

Spontaneous deaths of anemic mice in the colony were monitored and recorded over time. In a group of 50 mice that died spontaneously, 50% died between 2.5 and 6 months, 34% between 6.5 and 15 months, and 16% between 16 and 25 months of age. There were no spontaneous deaths in the control (*+/+*) mice until after 25 months of age.

### Hematologic Parameters

Hematocrits in anemic mice ranged from 16 to 28% with mean hematocrits of old anemic mice being slightly lower than young anemic mice (Table 1). Uncorrected reticulocyte counts were markedly elevated (89 to 98%) in both young and old anemic mice. Peripheral erythrocytes were spherocytic and polychromatophilic with blood smears containing many red blood cell fragments (Figure 1). Total white blood cell counts were elevated in the majority of old and young anemic mice. White blood cell counts in anemic ani-

Table 2—Serum Chemistries in Young and Old *sph<sup>ha</sup>/sph<sup>ha</sup>* and *+/+* Mice

	Young <i>+/+</i>	Young <i>sph<sup>ha</sup></i>	Old <i>+/+</i>	Old <i>sph<sup>ha</sup></i>
Potassium (meq/L)	5.8 (5.0–5.9)	6.5* (5.5–7.4)	4.4 (4.4–4.6)	5.6* (4.0–6.7)
Phosphorus (mg/dl)	7.2 (7.2–7.3)	9.1* (8.0–11.0)	5.8 (4.6–7.6)	8.6 (6.1–10.3)†
BUN (mg/dl)	24.6 (17–26)	37.7 (20–61)	28.4 (26–30)	64.9 (41–120)
Creatinine (mg/dl)	0.5 (0.5–0.6)	0.5 (0.2–0.7)	0.5 (0.4–0.8)	0.5 (0.4–0.8)
SGPT (IU/l)	158 (88–178)	79 (62–204)	117 (32–226)	177 (98–250)
Total bilirubin (mg/dl)	0.06 (0–0.1)	0.7† (0.2–1.1)	–	1.0† (0.5–2.6)

Values are mean and ranges. Young *+/+* (N = 8); young *sph<sup>ha</sup>* (N = 9); old *+/+* (N = 5); old *sph<sup>ha</sup>* (N = 9).

\*  $P < 0.05$ .

†  $P < 0.01$ ; two-tailed Student *t*-test.

mals ranged from 7700 to 58,600 per cu mm with marked increases in absolute numbers of neutrophils (3 to 5 times control levels), monocytes (6 to 11 times) and lymphocytes (4 to 5 times, Table 1).

### Serum Chemistries, Urinalyses and Fecal Analyses

Anemic mice had moderate but significant increases in serum potassium, phosphorus, BUN, and total bilirubin (Table 2). Serum BUN was higher in old anemic mice and both young and old anemic animals had elevated total bilirubin levels. Other serum chemistries did not differ significantly from control mice.

Urinalyses results are summarized in Table 3. Specific gravity was  $>1.035$  in all groups except old anemic mice, where urine specific gravity ranged from 1.016 to 1.025. All four groups of mice displayed vary-

ing degrees of proteinuria with proteinuria being most notable in old control (+1 to +3) and old anemic (trace to +4) mice. Proteinuria with more dilute urine suggests greater urine protein loss in old anemic mice (Table 3). Young and old anemic mice manifested hematuria, mostly due to red blood cell hemolysis, and bilirubinuria. Urinary urobilinogen was above control levels in some of the old anemic mice. Fecal analyses were negative for occult blood in all groups.

### Serum Immunoglobulin Levels

There were elevations in certain immunoglobulin isotypes in anemic mice (Figure 2). Old anemic mice had significantly increased levels of IgG1, IgG2b, and IgA; IgG1 and IgA were 3 to 5 times higher (IgG1 levels were  $7190 \pm 3645$  mg/l (mean  $\pm$  SD) and serum IgA levels were  $8367 \pm 750$  mg/l). Young anemic

Table 3—Urinalysis in Young and Old *sph<sup>ha</sup>/sph<sup>ha</sup>* and *+/+* Mice

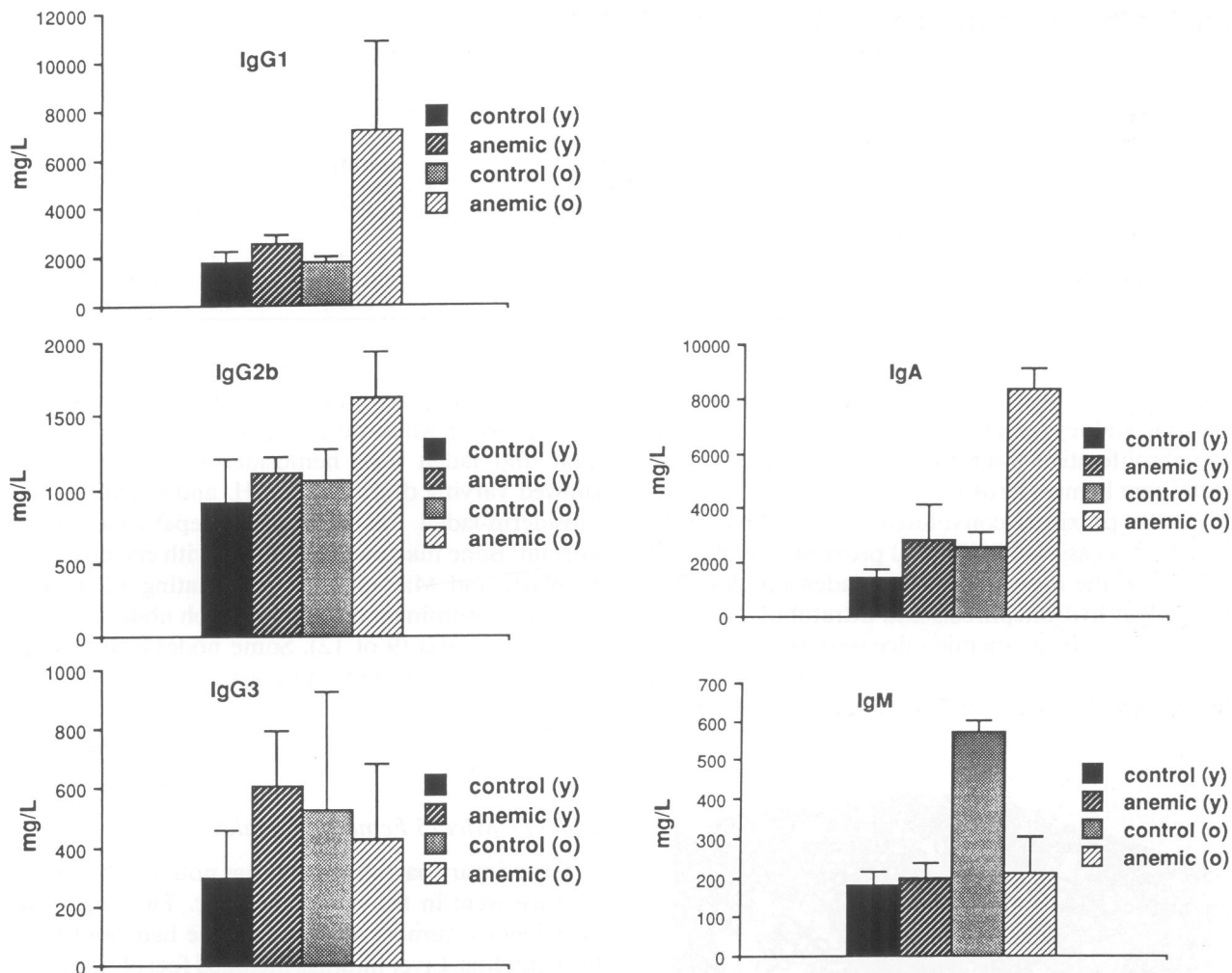
	Young <i>+/+</i> (n)*	Young <i>sph<sup>ha</sup></i> (n)	Old <i>+/+</i> (n)	Old <i>sph<sup>ha</sup></i> (n)
S.G.†	$>1.035$ (6)	$>1.035$ (4)	$>1.035$ (4)	1.016–1.025 (4)
pH	6.0–7.0 (8)	6–6.5 (5)	6.0–6.5 (2)	5.5–7.0 (9)
Bilirubin	Neg (13)	Neg+2 (11)	Neg (6)	Neg+3 (18)
Urobilinogen (mg/dL)	0.1–1 (11)	.1–2 (11)	0.1–1 (6)	0.1–8 (15)
Blood	Neg (12)	trace+3‡ (8)	Neg+1 (5)	Neg+2§ (14)
Protein (mg/dL)	+1+2 (10)	+1+2 (8)	+1+3 (8)	trace+4 (15)
Glucose	Neg (5)	Neg (4)	Neg (3)	Neg (8)

\* n = number of mice used for determination.

† Reported normal specific gravity in C57Bl/6J mice is 1.020–1.022 (38).

‡ Positives were hemolyzed.

§ Positives were hemolyzed (4) and nonhemolyzed (2).



**Figure 2**—Some immunoglobulin isotypes (RID assay) were altered in anemic mice particularly in older animals. Serum IgG1 levels were significantly ( $P < 0.05$ ) increased in both groups of anemic mice while serum IgG2b was increased ( $P < 0.05$ ) in old anemic mice and IgG3 was increased ( $P < 0.05$ ) in young anemic mice. Both young anemic ( $P < 0.05$ ) and old anemic ( $P < 0.001$ ) mice had elevations in serum IgA levels with old anemic mice having a striking increase. Old control mice had increased serum IgM levels ( $P < 0.001$ ) relative to young control mice and both groups of anemic mice. \*Two-tailed Student's *t*-test.

mice had elevated serum IgG1, IgG3, and IgA. Serum IgM levels ( $572 \pm 30$  mg/l) were increased in old control mice relative to the other groups of mice.

### Erythropoietin Levels

Serum erythropoietin (EP) levels were elevated in young anemic mice compared with control mice. While control mice had undetectable levels of EP, young anemic mice had levels that ranged from 70 to 712 mu/ml. Although this was elevated, normal mice made anemic by acute blood loss had EP levels that were 3 to 20 times higher (2100 to 16,900 mu/ml).<sup>15</sup>

### Necropsy Findings

Anemic mice weighed less than control mice (Table 4). Young anemic mice had a 32% lower body weight

relative to age-matched controls. Differences in weight decreased with age; old anemic animals were 16% lower in body weight than age-matched controls. Anemic mice had larger hearts and kidneys than control mice but the most remarkable differences were noted in spleen weights. Splenic weight ranged from 1.5 to 1.6 g in anemic mice, 11 to 17 times the weight of control spleens (0.087 to 0.11 g).

#### Young +/+ Mice (2 Females, 10 Males)

There were no pathologic changes noted in the 12 mice examined. One mouse had a focal area of hepatitis, two mice had focal mineralization in coronary vessels, and three mice had mild, focal, hepatic extramedullary hematopoiesis (EMH).

#### Young *sph*<sup>ha</sup>/*sph*<sup>ha</sup> Mice (6 Females, 6 Males)

The most dramatic differences between young control (+/+) and anemic (*sph*<sup>ha</sup>/*sph*<sup>ha</sup>) mice were noted

Table 4—Mean ( $\pm$ SEM) Body and Organ Weights in Young and Old  $sph^{ha}/sph^{ha}$  and  $+/+$  Mice

	Young $+/+$	Young $sph^{ha}$	Old $+/+$	Old $sph^{ha}$
Body weight	33.2	22.7	39.2	33
(g)	( $\pm 0.37$ )	( $\pm 1.9$ )	( $\pm 1.0$ )	( $\pm 1.1$ )
Heart	0.14	0.21	0.20	0.36
(g)	( $\pm 0.01$ )	( $\pm 0.02$ )	( $\pm 0.01$ )	( $\pm 0.04$ )
Kidney	0.22	0.31	0.30	0.53
(g)	( $\pm 0.002$ )	( $\pm 0.04$ )	( $\pm 0.01$ )	( $\pm 0.1$ )
Liver	1.36	1.51	1.74	2.28
(g)	( $\pm 0.09$ )	( $\pm 0.11$ )	( $\pm 0.13$ )	( $\pm 0.19$ )
Spleen	0.087	1.51	0.11	1.61
(g)	( $\pm 0.007$ )	( $\pm 0.16$ )	( $\pm 0.001$ )	( $\pm 0.26$ )

in the kidneys, liver, spleen, lymph nodes, and bone marrow. Kidneys exhibited histologically mild membranoproliferative glomerulonephritis (MPGN) with prominent hemosiderosis (Figure 3) confined primarily to the proximal convoluted tubules. Five of 12 mice had occasional individual proximal tubular cell necrosis in the most heavily iron-laden tubules. One mouse had hydronephrosis and intratubular concretions. Spleens from anemic mice were very much enlarged and contained remarkable expansion of the red pulp with EMH and a predominance of erythroid pre-

cursors; some spleens had apparent reduction in discrete areas of white pulp. Macrophages were abundant and laden with hemosiderin. The liver also showed varying degrees of EMH, and contained hemosiderin-laden macrophages. Hepatocytes were normal. Bone marrow was cellular with erythroid hyperplasia and M:E ratios approximating 1:2 to 1:3. The most prominent finding in lymph nodes was cortical hyperplasia (9 of 12). Some nodes also showed hyperplasia of stromal supporting cells (3 of 12), prominent sinusoidal reticular lining cells (1 of 12), and EMH in medullary cords (1 of 12). Other tissues were normal.

#### Old $+/+$ Mice (5 Females, 7 Males)

The primary pathologic findings noted in this group of mice were in the lungs and liver. Two mice had alveologenic tumors and one mouse had mild peribronchiolitis. Liver findings included foci of mononuclear cells (4 of 12), foci of EMH (2 of 12), nodular hyperplasia (1 of 12) and mixed lymphoma (1 of 12). There were mild to moderate degrees of EMH in the spleen. Two mice had amyloid deposition in small intestine, colon and caecum, and one animal had cardiac amyloidosis. Other tissues were normal.

#### Old $sph^{ha}/sph^{ha}$ Mice (11 Females, 13 Males)

Pathology noted in this group of mice involved the kidney, liver, spleen, heart, lymph nodes, and gall bladder. Mild to marked MPGN, occasionally lobular in appearance, with mesangial proliferation, capillary wall thickening, and focal splitting of peripheral basement membrane, was noted in 24 anemic mice (Figure 4). Six of the 24 mice examined had hydronephrosis with mild to marked cyst formation throughout the renal parenchyma. Cysts were focally lined by proximal tubular epithelial cells with brush borders, and occasionally showed features of glomerulocystic disease. Most often they were lined by nondescript, flattened epithelium. Bilirubin concretions were present in the renal pelvis and some of the cysts. No direct

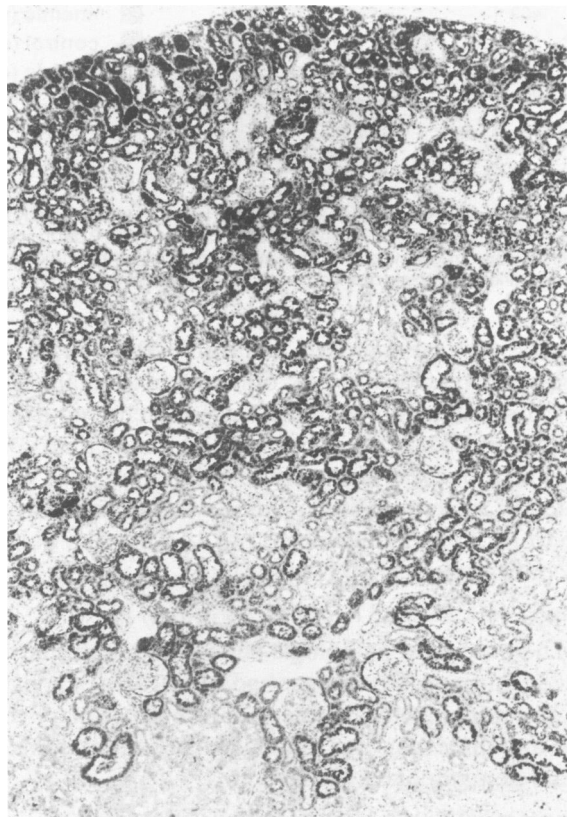
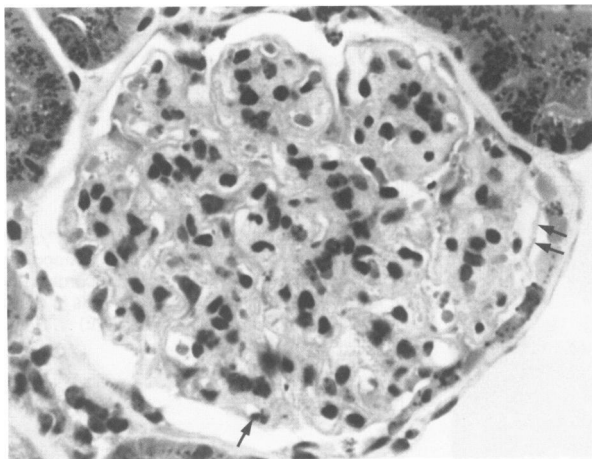


Figure 3—Widespread hemosiderin deposits in the proximal convoluted tubules in the renal cortex. Glomeruli and distal tubules are spared. (young  $sph^{ha}/sph^{ha}$  mouse,  $\times 40$ , Gomori stain)



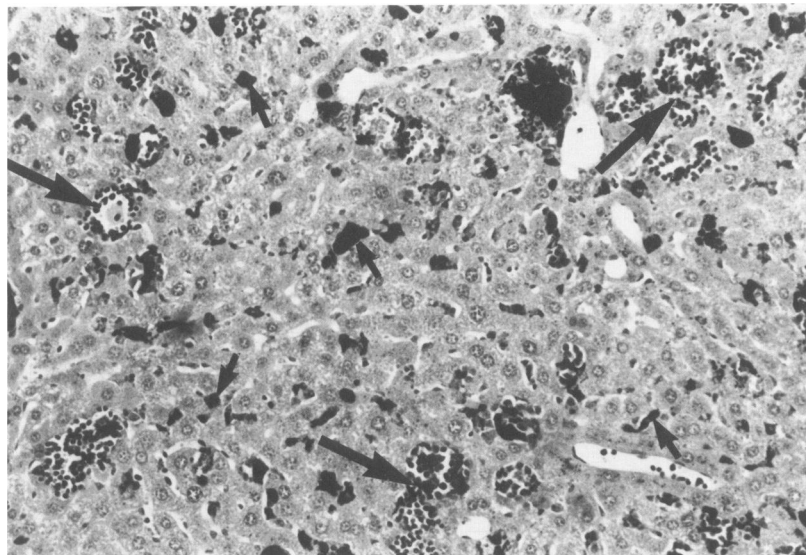
**Figure 4**—Glomerulus showing membranoproliferative glomerulonephritis with accentuated lobular architecture, pronounced mesangial hypercellularity, infiltration of capillary loops by neutrophils (arrow), and focal thickening of basement membranes (double arrows). (old *sph<sup>h</sup>/sph<sup>h</sup>* mouse,  $\times 400$ , H & E)

evidence of tubular obstruction or cell proliferation was identified. There was also marked hemosiderosis in proximal tubules, with lesser degrees present in some distal tubules in the most severely siderotic animals. There were focal areas of individual proximal tubular cell necrosis and mild interstitial fibrosis. Livers were heavier and contained moderate to marked EMH (Figure 5) with increased numbers of hemosiderin-laden macrophages. Seven of 24 mice had gallstones. Splenic changes were similar to young anemic mice with marked splenomegaly, EMH, hemosiderin-laden macrophages, and lymphoid depletion. Thrombosis of small vessels was noted in the spleen of one mouse. Hearts were heavier (Table 2), often had di-

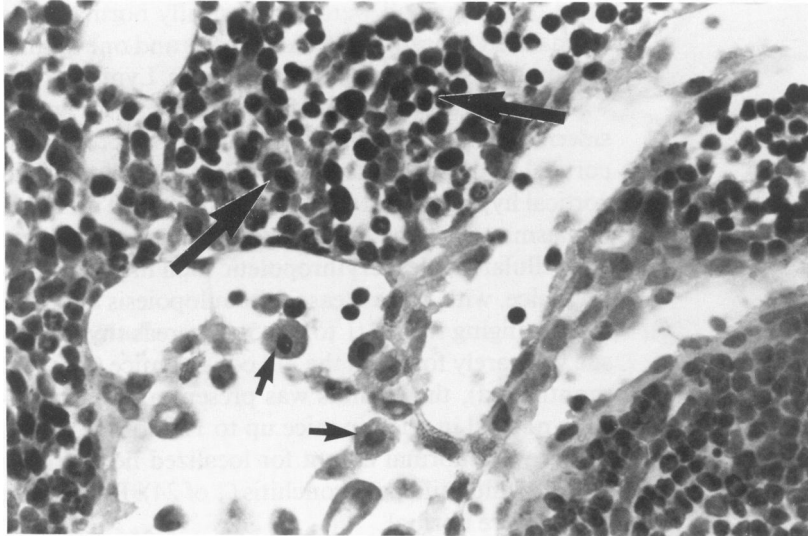
lated chambers and were histologically normal. One animal had a localized area of fibrosis and one animal had multiple thrombi in cardiac vessels. Lymph nodes were twice normal size and showed EMH with hemosiderin-laden macrophages (16 of 24) and prominent cortical and paracortical areas (7 of 24). Nodes had cortical hyperplasia (16 of 24) and increased numbers of plasma cells (6 of 24) (Figure 6). Bone marrow was less cellular and less erythropoietic than in young anemic mice, with more areas of granulopoiesis and M:E ratios ranging from 1:1 to 1:1.5. Whereas thymic tissue was rarely found in the old control mice (14 to 32 months old), the thymus was present and histologically normal in anemic mice up to 16 months of age. Lungs were normal except for localized hemorrhage (1 of 24) and mild peribronchitis (1 of 24). Remaining tissues were normal.

#### Presence of Stainable Iron

Differences in stainable iron were noted primarily in the kidney, liver, spleen, bone marrow, and lymph nodes (Table 5). Both young and old anemic mice had dramatic amounts of iron deposited predominantly in proximal convoluted tubules (Figure 3). The livers of anemic mice also had heavy deposition of iron, presumably due to increased handling of phagocytosized red blood cells. Control mice had moderate amounts of iron in the spleen but this probably was mobilized for accentuated erythropoiesis and was trace to negative in anemic mice. The bone marrow contained small amounts of iron in control mice but was negative in anemic animals. The lymph nodes contained moderate amounts of iron in anemic mice confined



**Figure 5**—Liver of old *sph<sup>h</sup>/sph<sup>h</sup>* mouse with marked extramedullary hematopoiesis in the medullary cords (large arrows) and nucleated red blood cells in the sinusoids (small arrows). ( $\times 400$ , H & E)



**Figure 6**—Lymph node from old *sph<sup>ha</sup>/sph<sup>ha</sup>* mouse showing extramedullary hematopoiesis and plasma cells in the medullary cords (large arrows) and nucleated red blood cells in the sinusoids (small arrows). ( $\times 400$ , H & E)

primarily to the trabecular and medullary sinuses. Presumably, anemic mice mobilize iron from the spleen and marrow and concentrate it in areas where red blood cells and hemoglobin are handled and metabolized, the kidney, liver, and lymph nodes.

### Immunofluorescence

Immunofluorescence findings are summarized in Table 6. In most cases glomerular staining seen was confined to mesangial areas; this was true of all control and young anemic animals studied. In the older anemic mice, a pattern of coarse, granular staining of peripheral capillary walls, frequently in a lobular pattern, was seen for both IgM and IgA, but not IgG (Figure 7). In general, there was stronger glomerular staining for all immunoglobulins in anemic animals when compared with similarly aged controls.

### Electron Microscopy

Ultrastructural findings in glomeruli showed no evidence of electron dense deposits in the young control animals studied; studies of morphologically normal glomeruli from an old control animal revealed rare, small mesangial electron dense deposits. In contrast, glomeruli in both young and older anemic animals showed changes consistent with MPGN. These included mesangial expansion with focal interposition into glomerular capillary walls and prominent mesangial and paramesangial electron dense deposits (Figure 8). Subendothelial deposits in peripheral capillary walls were less frequent but often present. Occasional leukocytes were present in capillary lumina. Visceral epithelial cell foot processes were generally well preserved. Occasional aggregates of iron were present in lysosomes of visceral epithelial cells or lying free in the urinary space; no intracapillary mesangial deposits of iron were seen. Tubules containing large amounts of

**Table 5**—Presence of Stainable Iron in Tissues of Young and Old *sph<sup>ha</sup>/sph<sup>ha</sup>* and *+/+* Mice

	Young <i>+/+</i>	Young <i>sph<sup>ha</sup></i>	Old <i>+/+</i>	Old <i>sph<sup>ha</sup></i>
Kidney	Neg	+4	Trace	+4
Liver	Neg	+3	Trace	+3 to +4
Spleen	+2 to +3	Neg to Trace	+2 to +3	Neg to trace
Bone marrow	Neg to +1	Neg	Trace to +2	Neg
Lymph node	Trace	+1 to +2	Trace to +2	+3
Heart	Neg	Neg	Neg	Trace
Thymus	Neg	Neg	Neg	Trace
Lung	Trace	Trace	Neg	Trace
Pancreas	Neg	Trace	Neg	Trace
Stomach				
intestine	Neg	Neg	Neg	Neg

Gomori's iron stain; amount scored negative, trace to +4; Neg, negative.



Table 6—Immunofluorescent Findings in Kidneys of Young and Old *sph<sup>ha</sup>/sph<sup>ha</sup>* and *+/+* mice

	Young <i>+/+</i>	Young <i>sph<sup>ha</sup></i>	Old <i>+/+</i>	Old <i>sph<sup>ha</sup></i>
Albumin	Neg	Neg	Neg	Neg to +3 <sup>†</sup>
C3	1+ to 3+ <sup>*†</sup>	2+ to 4+ <sup>*‡</sup>	+1 to +3 <sup>*†</sup>	Neg to +3 <sup>*†</sup>
IgG	Neg	Neg to 3+	+1 to +3 <sup>**</sup>	Neg to +3
IgM	1+ to 2+ <sup>*</sup>	+4 <sup>*§</sup>	+3 <sup>*</sup>	+2 to +3 <sup>*‡§</sup>
IgA	Neg	+3 to +4 <sup>*‡</sup>	+1 to +3 <sup>*</sup>	+3 to +4 <sup>†¶</sup>

\* mesangial.

† tubular basement membrane.

‡ segmental capillary wall.

§ afferent arterial vessels.

† tubular casts.

¶ lobular pattern.

\*\* focal, segmental.

iron in polyphagolysosomes showed preservation of brush borders and basolateral interdigitations and basement membranes of normal thickness.

### Discussion

The hemolytic anemic mutant mouse (*sph<sup>ha</sup>/sph<sup>ha</sup>*) must meet intense erythropoietic demands that begin when it is a fetus. Red cell lifespan is markedly shortened<sup>7,8</sup> and hematopoietic space is expanded to accommodate enhanced and persistent red blood cell production. Marked splenomegaly with extramedullary hematopoiesis and increased numbers of hematopoietic stem cells,<sup>13</sup> in addition to EMH in the liver, are the means by which this mouse attempts to accommodate increased peripheral blood cell needs. A gradually increasing heart size with eventual dilatation of chambers in older animals suggests cardiovascular compensations as well. Normal red blood cell mass is never achieved (hematocrit level is half that of controls) throughout the mouse's lifetime despite the

compensatory response of a near 100% reticulocytosis in peripheral blood.

Because spectrin deficient red cells are fragile and circulate for short periods of time,<sup>16</sup> mutant hemolytic mice must continually process large numbers of fragmented and sequestered red blood cells, resulting in changes in iron stores. Control mice have copious quantities of iron in their spleens with moderate amounts in bone marrow. In anemic mice, iron is mobilized from the spleen and bone marrow and becomes concentrated in sites where red cells and hemoglobin are processed: the liver, lymph nodes, and heavily within the kidney tubules. Renal hemosiderosis in humans has been associated with intravascular hemolysis.<sup>17</sup> As in humans, hemosiderin in anemic mice is abundant in cells of the proximal convoluted tubules and generally absent in distal tubules, glomerular tufts, and interstitial tissue. Renal hemosiderosis was noted in young anemic mice and was even more apparent in older anemic animals, but renal tubular function did not appear to be impaired to any significant degree. Older anemic animals still were able to concentrate urine and serum phosphorus levels were within normal range (Table 3).

Membranoproliferative glomerulonephritis (MPGN) was an unexpected finding in these anemic mutant mice. It was present in the young anemic animals but became more marked with age. Renal function may have been affected to some degree with mild to moderate elevations in BUN, but serum creatinine levels remained normal (Table 2). The glomerulonephritis noted was associated with the deposition of IgA, IgM, C3, and to some extent IgG in the anemic mice. Immune complex glomerulonephritis has been associated with viral infections in mice.<sup>18-20</sup> Mice evaluated in this study were free of known murine viruses and congenic controls did not exhibit this renal pathology. In a review of 12 strains of laboratory mice, immunoglobulin deposition (specifically IgG, IgM, IgA, and

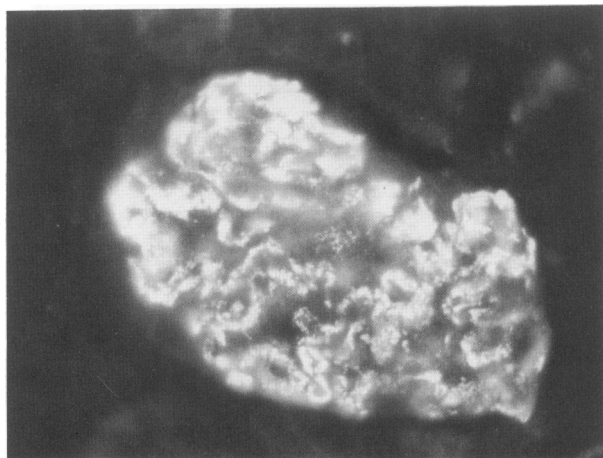
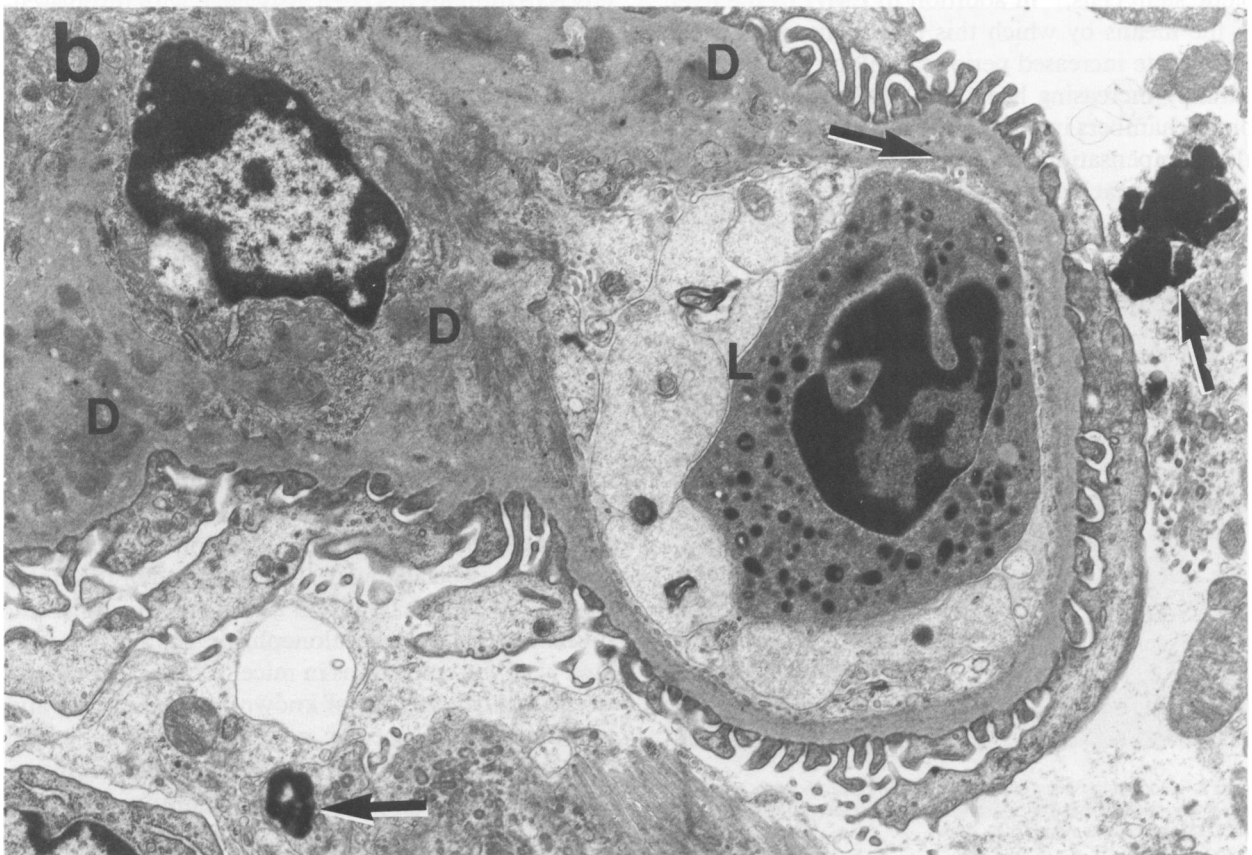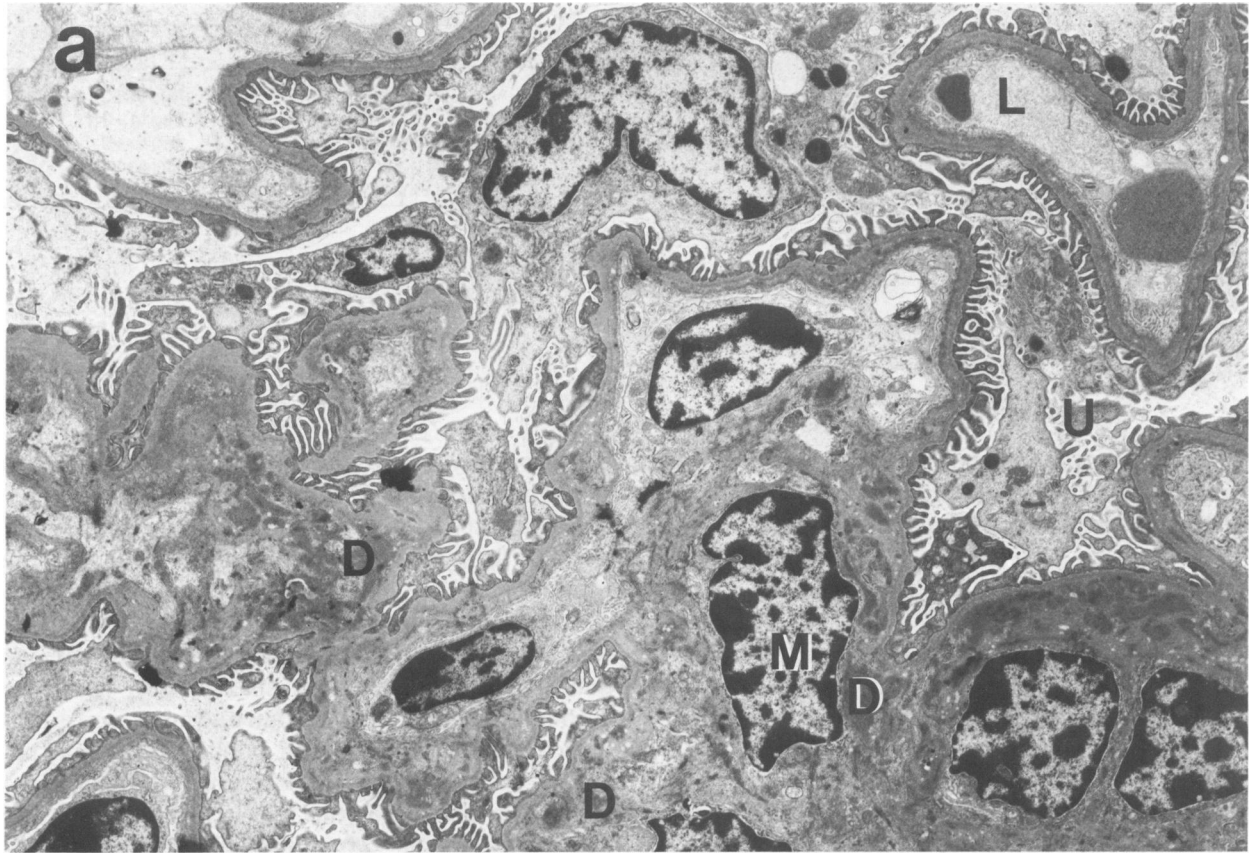


Figure 7—Glomerulus from old *sph<sup>ha</sup>/sph<sup>ha</sup>* mouse showing prominent granular deposition of IgA in mesangium and peripheral capillary walls. ( $\times 700$ , FITC rabbit anti-mouse IgA)



**Figure 8 a, b**—Membranoproliferative glomerulonephritis (MPGN). **a**—Low power ( $\times 3360$ ) electron micrograph showing mild increase in mesangial cells, numerous electron dense deposits (D) in mesangial (M) and paramesangial areas. Epithelial foot processes are well preserved. **b**—Higher power ( $\times 6160$ ) view of glomerulus showing paramesangial deposits with extension into inner basement membrane of capillary wall (arrow) and mesangial interposition into capillary walls. Some iron granules (arrowheads) are present in urinary space (U). There is a neutrophil in the capillary lumen (L). D, deposits; M, mesangial; U, urinary space; L, lumen.

C3) was reported in renal glomeruli in the absence of overt clinical disease.<sup>21</sup> Ultrastructural findings in these animals were not reported, and it is uncertain if organized immune deposits were present. The findings of positive immunofluorescence in kidneys of control mice with only rare mesangial deposits seen by electron microscopy agree with that previous study, and indicate a baseline background of glomerular Ig deposition of little clinical significance in these mice. However, both young and old anemic mice had more pronounced immunoglobulin deposition that was predominantly IgM and IgA, with organized immune deposits in mesangial areas and within capillary walls in areas of mesangial interposition that were identified by electron microscopy.

The relationship of the hemolytic anemia to the glomerulonephritis is unclear. There are other examples of hemolytic anemia associated with glomerular disease. Glomerulonephritis and hemolytic anemia have been reported in a rodent species, the Afghan Pika,<sup>22</sup> which was associated with an autoimmune disease. Nephritis and hemolytic anemia occur in owl monkeys,<sup>23</sup> but their cause is unknown. Malaria, a red-cell parasite resulting in hemolysis, has been associated with glomerulonephritis in humans<sup>24</sup> and in mice.<sup>25</sup> Mice infected with *Plasmodium berghei Yoelii* have deposition of C3, IgG1, IgM, and IgA in glomerular mesangium. The cause of membranoproliferative glomerulonephritis in the majority of human cases is unknown, but chronic antigenemia and/or circulating immune complexes has been suggested in cases associated with chronic bacteremia, chronic hepatitis, certain blood dyscrasias, and parasitic infections.<sup>26</sup> Continued red cell fragmentation noted in *sph<sup>ha</sup>/sph<sup>ha</sup>* mice may result in exposure of occult antigens, and elicit a persistent immune response.

Perhaps the most striking feature of this model is its similarity to the small proportion of human patients with sickle cell anemia who develop an immune complex glomerulonephritis.<sup>27</sup> In one study,<sup>28</sup> all seven patients had some degree of membranoproliferative glomerulonephritis. Electron microscopic changes noted in *sph<sup>ha</sup>/sph<sup>ha</sup>* mice share some morphologic similarities with those noted in affected sickle cell patients, including mesangial expansion, presence of mesangial dense deposits, and mesangial interposition into peripheral capillary basement membrane. The development of similar glomerular lesions in two

different species suggests that chronic hemolysis in some way produces glomerular injury.

Some serum immunoglobulin isotypes were higher in anemic mice relative to control animals. Although it has been noted that total serum immunoglobulin levels increase with age in mice,<sup>29</sup> old anemic mice had higher levels of IgG1 and much higher levels of IgA when compared with old control mice. Factors that regulate IgA responses are unclear but IgA responses are reduced in the absence of T cells. The murine spleen contains regulatory T cells suppressing IgA synthesis and Peyer's patches contain regulatory cells augmenting IgA synthesis.<sup>30</sup> In old anemic animals, EMH in the spleen may result in a reduced suppressor T cell population or altered suppressor cell function, which in turn results in excess production of IgA. Subsets of helper T cells may modulate immunoglobulin levels through production of lymphokines like B cell growth factor II (Interleukin 5)<sup>31</sup> and helper T cell subsets may be altered in number or activity in older anemic mice. Elevation in serum IgG, IgA, and IgM have been reported in children with sickle cell anemia<sup>32</sup> and patients with hereditary spherocytosis.<sup>33</sup>

*Sph<sup>ha</sup>/sph<sup>ha</sup>* mice manifested a leukocytosis that is three to four times the white cell count of control mice. Red cell breakdown may result in release of growth factors that stimulate granulocyte/monocyte progenitors and increase numbers of granulocytes and monocytes. While a precise mechanism for the observed monocytosis is not yet known, on a teleologic basis it is apparent that there are increased needs for subsets of macrophages to clear red cell debris and hemoglobin breakdown products, to accelerate erythropoiesis by elaborating growth factors,<sup>34</sup> or to act on hemopoietic progenitors,<sup>35,36</sup> and to deliver iron to developing erythroblasts in the marrow or spleen. The lymphocytosis manifested by the *sph<sup>ha</sup>/sph<sup>ha</sup>* mouse is not as well understood. Lymphocyte numbers generally are not regulated by any of the known factors that affect erythrocyte, granulocyte, or monocyte production. It is not known whether increased peripheral lymphocyte numbers is due to increased production in primary lymphoid tissue, proliferation of mature lymphocytes in secondary lymphoid tissue, or to persistence of long-lived lymphocytes. Histologically, some of the anemic mice showed lymphoid hyperplasia in paracortical areas of lymph nodes, however, no similar hyperplasia was present in the spleen. Instead,

the white pulp of the spleen was reduced in many of the anemic mice, with marked expansion of red pulp. Subsets of lymphocytes have been implicated in the control and regulation of hematopoiesis<sup>37</sup> and the lymphocytosis may in part be due to an increase in those accessory cells.

Anemic mice have a shorter lifespan than control mice. The hematologic and serum chemical values evaluated in this study in anemic mice have not suggested a reason for their demise. Despite a histologically progressive glomerulonephritis, the serum BUN, creatinine, and phosphorus values do not indicate significant renal dysfunction or a renal cause for their early mortality. Although the increased size of their hearts, along with dilatation of atrial and ventricular chambers, indicate the possibility of heart failure, the absence of pulmonary edema would not suggest a prominent role for congestive heart failure as a cause of death. The observed hepatomegaly most likely is due to a combination of extramedullary hematopoiesis and hemosiderosis, with possible additional contribution of passive congestion secondary to right heart failure.

The *sph<sup>ha</sup>/sph<sup>ha</sup>* mouse offers a unique opportunity to study multiple compensatory changes occurring with chronic anemia, effects of persistent breakdown of red cells, handling of iron by the kidney and liver, and the development of an immune complex glomerulonephritis possibly related to hemolytic anemia. The observed changes in lymphocyte numbers or lymphocyte populations in this animal model may be a useful tool for exploration of controls for regulation of immunoglobulin synthesis and lymphopoiesis.

## References

1. Stevens LC, Mackensen JA, Bernstein SE: A mutation causing neonatal jaundice in the house mouse. *J Hered* 1959, 50:35-39
2. Joe M, Teasdale JM, Miller JP: A new mutation (*sph*) causing neonatal jaundice in the house mouse. *Can J Genet Cytol* 1962, 4:219-225
3. Bernstein SE: Hereditary disorders of the rodent erythron, *Genetics in Laboratory Animal Medicine*. Edited by JR Lindsay. Washington, DC, National Academy of Sciences, 1969, pp. 9-33
4. Bernstein SE: Inherited hemolytic disease in mice: A review and update. *Lab Anim Sci* 1980, 30:197-205
5. Unger AE, Harris MJ, Bernstein SE, Falcone JC, Lux SE: Hemolytic anemia in the mouse. *J Hered* 1983, 74: 88-92
6. Bodine DM, Birkenmeier CS, Barker JE: Spectrin deficient inherited hemolytic anemias in the mouse: Characterization by spectrin synthesis and mRNA activity in reticulocytes. *Cell* 1984, 37:721-729
7. Landaw SA, Russell ES, Bernstein SE: Splenic destruction of newly-formed red blood cells and shortened erythrocyte survival in mice with congenital microcytosis. *Scand J Hematol* 1970, 7:516-524
8. Landaw SA: Kinetic aspects of endogenous carbon monoxide production in experimental animals. *Ann NY Acad Sci* 1970, 174:32-48
9. Brookoff D, Maggio-Price L, Bernstein SE, Weiss L: Erythropoiesis in *ha/ha* and *sph/sph* mice, mutants which produce spectrin-deficient erythrocytes. *Blood* 1982, 59:646-651
10. Kreimer-Birnbaum M, Bannerman RM, Russell ES, Bernstein SE: Pyrrole pigments in normal and congenitally anemic mice. *Comp Biochem Physiol* 1972, 43: 21-30
11. Sassa S, Drummond GS, Bernstein SE, Kappas A: Tin protoporphyrin suppression of hyperbilirubinemia in mutant mice with severe hemolytic anemia. *Blood* 1983, 61:1011-1013
12. Sassa S, Drummond GS, Bernstein SE, Kappas A: Long-term administration of massive doses of Sn-Protoporphyrin in anemic mutant mice. *J Exp Med* 1985, 162:864-876
13. Maggio-Price L, Wolf NS, Priestley GV, Pietrzyk M, Bernstein SE: Evaluation of stem cell reserve using serial bone marrow transplantation and competitive repopulation in a murine model of chronic hemolytic anemia. *Exp Hematol* 1988, 16:653-659
14. Shadduck R, Howard A, Stohlman F: A difference in erythropoietin production between anemic and hypoxic mice. *Proc Soc Exp Biol Med* 1968, 128:132-136
15. Maggio-Price L, Brookoff D, Weiss L: Changes in hematopoietic stem cells in bone marrow of mice with *Plasmodium berghei* malaria. *Blood* 1985, 66:1080-1085
16. Greenquist AC, Shohet SB, Bernstein SE: Marked reduction of spectrin in hereditary spherocytosis in the common house mouse. *Blood* 1978, 51:1149-1155
17. Leonardi P, Ruol A: Renal hemosiderosis in the hemolytic anemias: Diagnosis by means of needle biopsy. *Blood* 1960, 16:1029-1038
18. Hirsch MS, Allison AC, Harvey JJ: Immune complexes in mice infected neonatally with Moloney leukaemogenic and murine sarcomal viruses. *Nature (Lond)* 1969, 223:739-740
19. Markham RV, Sutherland JC, Cimino EF, Drake WP, Mardiney MR: Immune complexes localized in the renal glomeruli of AKR mice: The presence of MuLV *gs-12* and *Ctype* RNA tumor virus *gs-3* determinants. *Rev Eur Etud Clin Biol* 1972, 17:690-694
20. Wehner RW, Smith RD: Progressive cytomegalovirus glomerulonephritis. *Am J Pathol* 1983, 112:313-325
21. Markham RV, Sutherland JC, Mardiney MR: The ubiquitous occurrence of immune complex localization in the renal glomeruli of normal mice. *Lab Invest* 1973, 29:111-120
22. Okudaira H, Terada E, Ito T, Yamamoto K, Mizoguchi Y, Ogita T, Nomura T: Autoimmune glomerulonephritis and hemolytic anemia in a new laboratory animal, the Afghan Pika. *Clin Immunol Immunopathol* 1981, 21:375-386
23. Chalifoux LV, Bronson RT, Sehgal P, Blake BJ, King NW: Nephritis and hemolytic anemia in Owl monkeys (*Aotus trivirgatus*). *Vet Pathol* 1981, 18:23-37

24. White RHR: Quartan malarial nephrotic syndrome. *Nephron* 1973, 11:147-162
25. George CRP, Parbtani A, Cameron JS: Mouse malaria nephropathy. *J Pathol* 1976, 120:235-249
26. Jones DB: Membranoproliferative glomerulonephritis. *Arch Pathol Lab Med* 1977, 101:457-461
27. Strauss J, Pardo V, Koss MN, Griswold W, McIntosh RM: Nephropathy associated with sickle cell anemia: An autologous immune complex nephritis. I. Studies on nature of glomerular-bound antibody and antigen identification in a patient with sickle cell disease and immune deposit glomerulonephritis. *Am J Med* 1975, 58:382-387
28. Pardo V, Strauss J, Kramer H, Ozawa T, McIntosh RM: Nephropathy associated with sickle cell anemia: An autologous immune complex nephritis. *Am J Med* 1975, 59:650-659
29. Natsuume-Sakai S, Motonishi K, Migita S: Quantitative estimations of five classes of immunoglobulin in inbred mouse strains. *Immunology* 1977, 32:861-866
30. Elson CO, Heck JA, Strober W: T-cell regulation of murine IgA synthesis. *J Exp Med* 1979, 149:632-643
31. Kinashi T, Harada N, Severinson E, Tanabe T, Sideras P, Konishi M, Azuma C, Tominaga A, Bergstedt-Lindqvist S, Takahashi M, Matsuda F, Yasita Y, Takatsu K, Honjo T: Cloning of complementary DNA encoding T-cell replacing factor and identity with B-cell growth factor II. *Nature* 1986, 324:70-73
32. Evans HE, Reindorf C: Serum immunoglobulin levels in sickle cell disease and thalassemia major. *Am J Dis Child* 1968, 116:586-590
33. Schilling RF: Hereditary spherocytosis: A study of splenectomized persons. *Semin Hematol*, 1976, 13:169-176
34. Kurland JI, Meyers PA, Moore MAS: Synthesis and release of erythroid colony and burst-potentiating activities by purified populations of murine peritoneal macrophages. *J Exp Med* 1980, 151:839-852
35. Kurland JI: The mononuclear phagocyte and its regulatory interactions in hemopoiesis, *Experimental Hematology Today*. Edited by SJ Baum, GD Ledney. New York, Springer-Verlag, 1978, pp. 47-60
36. Murphy MJ JR, Urabe A: Modulatory effects of macrophages on erythropoiesis, *In Vitro Aspects of Erythropoiesis*. Edited by MJ Murphy Jr. New York, Springer-Verlag, 1979, pp. 189-191
37. Gordon MY, Gordon-Smith EC: Lymphocytes and haemopoiesis. *Brit J Haematol* 1981, 47:163-169
38. Bernstein SE: *Physiological Characteristics, Biology of the Laboratory Mouse*. Edited by EL Green. New York, McGraw-Hill, 1966, pp. 337-350

### Acknowledgments

The authors thank Mr. Brian Jaeger, Mr. E. Chuan Teh, and Ms. Faith Shiota for their expert technical assistance and support.