

# Short Communication

## *In Situ* Hybridization and Immunohistochemistry of p53 Tumor Suppressor Gene in Human Esophageal Carcinoma

Hironobu Sasano, Yuji Goukon,  
Tetsuro Nishihira, and Hiroshi Nagura

From the Department of Pathology and Surgery, Tohoku  
University School of Medicine, Sendai, Japan

*We have studied expression of p53, a tumor suppressor gene, by using both immunohistochemistry and in situ hybridization in 20 cases of squamous cell carcinoma of the esophagus. Immunohistochemical analysis was performed by using monoclonal antibody pAb1801. Immunoreactive p53 was observed in the nuclei of the tumor cells in 17 cases. We used <sup>35</sup>S-labeled anti-sense single-stranded synthetic oligonucleotide probe ON102, which hybridized with DNA sequence near the 5' end of p53, for in situ hybridization. In all the cases of invasive squamous cell carcinoma studied, no significant accumulation of p53 hybridization signals was observed in carcinoma cells. This result indicates that overexpression of p53 observed by immunohistochemical staining is not due to an increase in the steady-state level of p53 mRNA in frank carcinoma cells. In six cases of morphologically normal esophageal mucosa distant from carcinoma, accumulation of hybridization signals was observed in basal and parabasal cells of the mucosa. The mucosa of these cases was negative for p53 immunoreactivity except for one case showing sporadic positivity. Accumulation of hybridization signals was observed in foci of squamous dysplasia not associated with invasion in three cases. (Am J Pathol 1992, 141:545-550)*

p53 is a 53 kda nuclear phosphoprotein and is expressed by many normal cells.<sup>1</sup> The protein appears to be involved in the regulation of normal cellular prolifera-

tion but its role still remains obscure.<sup>2</sup> Intracellular level of p53 protein is regulated through normal cell cycle by two mechanisms<sup>3</sup>: 1) transcription of its mRNA increases by 10- to 20-fold late in the G1 phase<sup>4</sup> and 2) normal p53 protein is rapidly eliminated due to its short-half life (5-45 minutes).<sup>1,4</sup> Therefore, in normal cells, intracellular levels of p53 protein are low even in actively dividing cells. On the contrary, in cultured cells, increased levels of p53 protein are associated with a mutant p53 gene<sup>5</sup> and mutant p53 proteins can immortalize cells *in vitro*. A number of laboratory studies demonstrated that mutant p53 genes can cooperate with the *ras* oncogene to transform primary cultured fibroblasts.<sup>6</sup> In addition to cultured cells, the p53 mutations have been detected in a wide variety of human malignancies.<sup>7</sup> It is now considered that the p53 gene frequently acquires mutations during the development of many human malignancies including colon, breast, and lung cancers.<sup>7</sup> As described earlier, intracellular regulation of p53 expression can occur at the level of mRNA abundance or of p53 protein stability. Increasing evidence has indicated that elevated intracellular levels of p53 are due to increased stability and higher steady-state levels of the protein.

Mutant p53 proteins form stable complexes with heat shock protein (hsp) 70, a constitutively expressed member of the heat shock family.<sup>5</sup> As a result of this complex with hsp 70, mutant p53 proteins may have an increased intracellular half-life. If this hypothesis is correct, p53 mRNA overexpression is not present or is negligible in a majority of human malignancies in which p53 mutations have been reported. Northern blotting of p53 has demonstrated low expression of p53 mRNA in lung cancer cell lines<sup>8</sup> and in primary invasive human breast cancer.<sup>3</sup>

Accepted for publication June 29, 1992.

Address reprint requests to Dr. Hironobu Sasano, Department of Pathology, Tohoku University School of Medicine, 2-1 Seiryomachi, Aoba-ku, Sendai, Japan 980.

However, mRNA abundance of p53 in human malignancies is still in dispute.<sup>9</sup> Northern blotting analysis usually involves contamination by nonmalignant and nonviable cancer cells because the tissue is processed as a mass. Therefore, in this study, we examined mRNA expression of p53 in human esophageal malignancies by *in situ* hybridization analysis, which makes it possible to examine localization of mRNA expression. This is the first report, to the best of our knowledge, of *in situ* hybridization analysis of p53 in human malignancies.

## Materials and Methods

### Tissues

Twenty cases of squamous cell carcinoma of the esophagus were studied. All patients were Japanese. They were operated on at Tohoku University Hospital, Sendai, Japan, from 1990 to 1991. Among the cases examined, clinical and histopathologic findings of 14 cases were reported previously.<sup>10</sup> In five cases, invasion was observed up to the submucosa. In the other cases, carcinomas were associated with tumor invasion beyond the tunica muscularis. Foci of dysplasia were observed in three cases. These foci were not continuous with invasive carcinoma. Nonpathologic or grossly normal esophagus was obtained from the surgical margins of the specimen.

### Tissue Preparation

Tissue blocks of both grossly apparent carcinoma and nonpathologic esophagus were trimmed to approximately 1.5 × 1.5 × 0.3 cm and were fixed immediately in 4% paraformaldehyde in phosphate-buffered saline (PBS), pH 7.4. They were irradiated with microwaves for 10 to 15 seconds and postfixed for 2 hours at 4°C. They were then embedded in paraffin.

### Immunohistochemistry

Thin 2.5- $\mu$ m slices from paraffin-embedded specimens were deparaffinized routinely. They were then immersed in ethanol with 0.3% hydrogen peroxide for 30 minutes, followed by a wash in 0.01 mol/l PBS and treatment with 1% normal rabbit serum for 30 minutes at room temperature. The slides were incubated with the primary antibodies for 18 hours at 4°C in a moist chamber. The primary antibody used in this study was monoclonal antibody pAb1801 obtained from Novocastra Laboratory, Newcastle, U.K. The antibody recognizes a denatur-

ation-resistant epitope in human p53 located between aminoacids 32 and 79.<sup>11</sup> The optimal dilution was 1:50. Immunostaining was performed by the Histofine method (Nichirei Co Ltd, Tokyo, Japan) employing 3-3'-diaminobenzidine as chromogens. Specific staining was identified by the presence of brown reaction products. For the negative controls, sections were incubated with 0.01 mol/l PBS or non-immune mouse serum instead of the primary antibody.

### In Situ Hybridization

Hybridization procedures used in this study were based on those of Sasano et al<sup>12</sup> and Hayashi et al<sup>13</sup> with some modifications. In both methods, glassware was washed, rinsed with distilled deionized water, and autoclaved before use. Gloves were worn when handling the glassware and slides to prevent RNase contamination of the tissue.

Deparaffinized sections mounted on Denhardt-coated glass slides were treated with proteinase (0.25 mg/ml in 50 mmol/l Tris-HCl, pH 7.6 and 5 mmol/l ethylene diamine tetraacetic acid [EDTA]) for 30 minutes at room temperature and acetylated with a freshly diluted acetic anhydride (0.25% in 0.1 mol/l triethanolamine buffer, pH 8.0) for 10 minutes. The treated sections were then processed for *in situ* hybridization at 45°C for 18 hours. DNA probes employed in this study were oligonucleotide probe ON102 and its corresponding sense probe, which were obtained from Oncogene Science, Manhasset, New York. ON102 is a 40 base anti-sense single-stranded synthetic oligonucleotide, which hybridized with DNA sequence near the 5' end. p53 mutations may occur throughout the length of the gene including the 5' region<sup>14</sup> but none of the DNA mutations have been reported in the region to which the probe ON102 corresponds in human esophageal carcinoma. These oligonucleotides were then radiolabeled with <sup>35</sup>S-ATP by 3'-end labeling method. The hybridization mixture contained the radiolabeled oligonucleotide probe, 50% formamide, 10 mmol/l Tris-HCl, pH 7.0, 0.15 mol/l NaCl, 1 mmol/l EDTA, pH 7.0, 1 × Denhardt's mixture and 10% dextran sulfate. After hybridization and removal of the cover glass by immersing the slides in 2 × standard saline citrate (SSC) buffer (1 × SSC = 0.15 mol/l NaCl, 0.015 mol/l trisodium citrate, pH 7.0) for 1 hour at room temperature, sections were washed three times in 2 × SSC for 10 minutes each at room temperature, once in 0.5 × SSC for 10 minutes at 45°C, and three times in 0.1 × SSC for 10 minutes each at 45°C. Afterwards, the slides were developed in Kodak NTB-2 nuclear track emulsion (Eastman Kodak, Rochester, NY) and exposed for 72 hours at 4°C. The exposed slides were then developed and the sections were stained with hematoxyline.

## Results

Results of the immunohistochemistry including semi-quantitation of immunoreactivity and *in situ* hybridization are summarized in Table 1.

### Immunohistochemistry

Among the cases of esophageal carcinoma examined, 17 of 20 cases were positive for p53 (Figure 1a). Three cases were negative for immunostain. Cells in squamous dysplasia were positive for p53 in all three cases examined (Figure 2a). In normal esophageal mucosa, immunoreactivity of p53 was observed sporadically in basal and parabasal cells of the mucosa in three cases (Table 1). Immunoreactivity described earlier was not observed when incubating with 0.01 mol/l PBS or non-immune mouse serum instead of the primary antibody.

### In Situ Hybridization

Hybridization signals of p53 were observed as black silver dots on autoradiography. In all the cases of invasive squamous cell carcinoma, no significant accumulation of hybridization signals was observed over the carcinoma cells (Figure 1b). The number of hybridization signals in these carcinoma cells was almost equal to background signals and those in the sections incubated with sense

oligonucleotide probe. There were no significant differences of hybridization signals between p53 positive and negative cases of esophageal carcinoma.

In six cases of both macroscopically and histologically normal mucosa distant from the carcinoma, accumulation of hybridization signals was observed in basal and parabasal cells of the mucosa (Figure 3). Among these six cases, only one was positive for p53 immunoreactivity. Increased hybridization signals were also observed in morphologically normal mucosa adjacent to carcinoma in these cases. Accumulation of hybridization signals in these cells was not present in the sections hybridized with a sense oligonucleotide probe. Intense hybridization signals of p53 were observed in all the foci of esophageal squamous dysplasia (Figure 2b). Sections hybridized with an oligonucleotide probe of a sense orientation did not yield accumulation of hybridization signals in the foci of squamous dysplasia described earlier (Figure 2c).

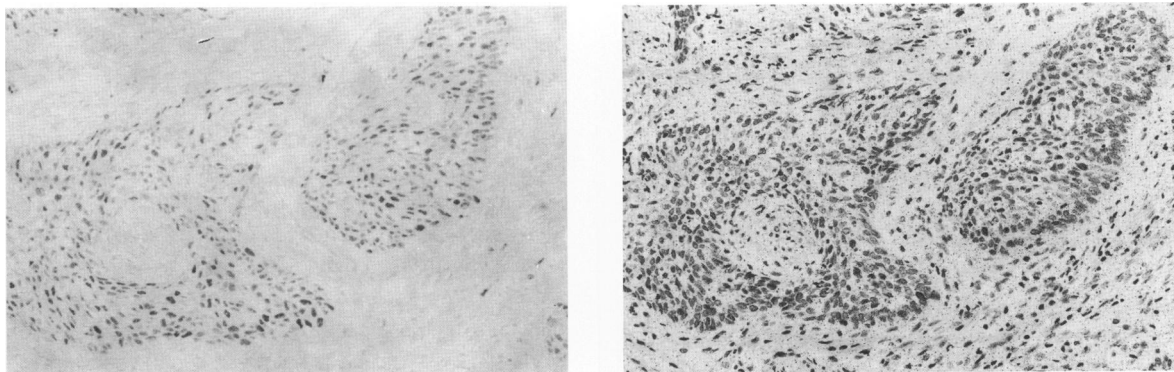
### Discussion

Correlation of overexpression of p53 with the presence of DNA mutations has been demonstrated in human epithelial ovarian cancer,<sup>15</sup> primary breast cancer,<sup>3</sup> lung cancer,<sup>16</sup> and others. Simple immunohistologic methods can detect overexpression of p53 without much difficulty and provide strong evidence of p53 DNA mutations in surgical pathology specimens.<sup>16,17</sup> Therefore, the basis of

**Table 1.** Summary of Immunohistochemistry and In Situ Hybridization

# Cases	Carcinoma		Dysplasia		Normal mucosa	
	IHC	ISH	IHC	ISH	IHC	ISH
1	-	-			-	-
2	++	-	+++	+	-	+
3	+	-			-	-
4	±	-			+	-
5	++	-	+++	+	-	-
6	+	-			-	+
7	++	-			-	+
8	+	-			-	-
9	-	-			+	-
10	+++	-			+	+
11	±	-			+	+
12	±	-			-	-
13	±	-			-	-
14	-	-			-	-
15	++	-			-	-
16	++	-			-	-
17	+	-			-	+
18	±	-			-	-
19	+	-			-	-
20	+++	-	+++	+	-	+

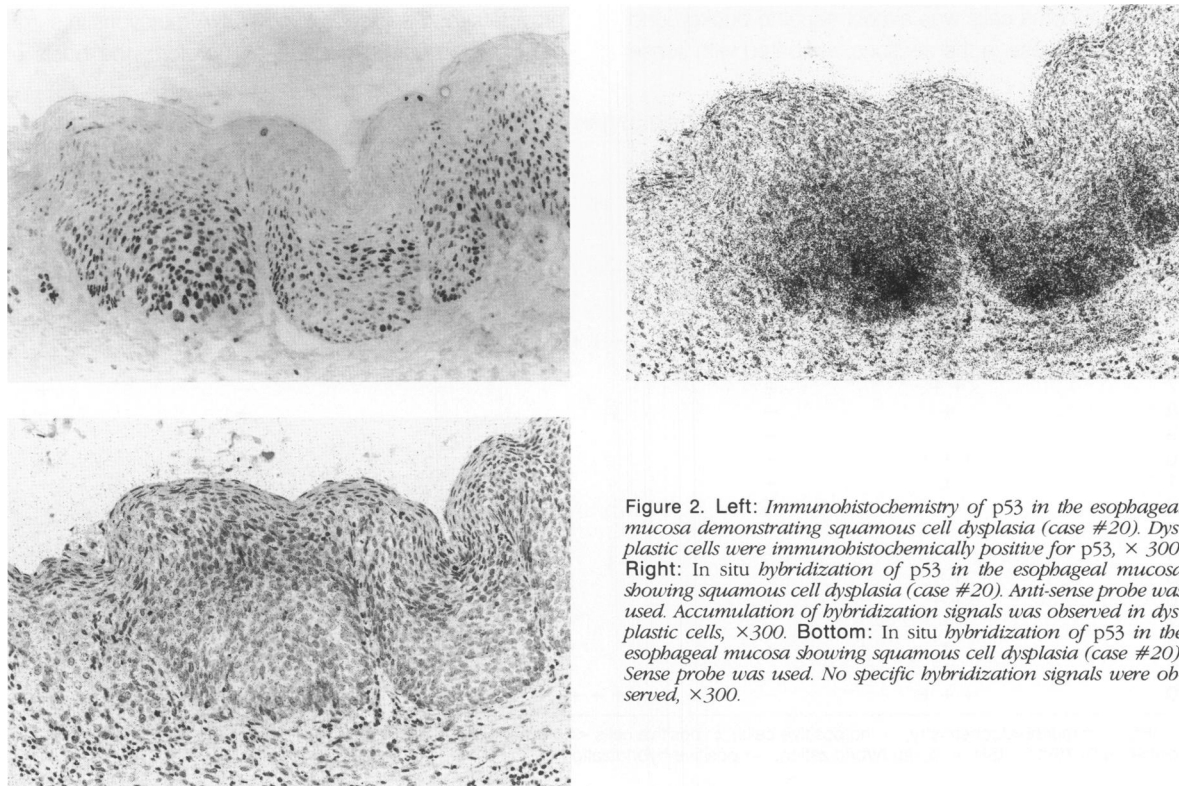
IHC = immunohistochemistry; -: no positive cells; ±: positive cells <25%; +: positive cells 25–50%; ++: positive cells 50–75%; +++: positive cells 75%+. ISH = *in situ* hybridization; +: positive hybridization; -: negative hybridization.



**Figure 1.** Left: Immunohistochemistry of p53 in invasive squamous cell carcinoma (case #17). Immunoreactivity was observed in carcinoma cells,  $\times 300$ . Right: In situ hybridization of p53 in invasive squamous cell carcinoma (case #17). Black dots, i.e., silver grains on autoradiogram represent hybridization signals. Accumulation of hybridization signals was not observed in the carcinoma cells,  $\times 300$ .

p53 overexpression in human malignancies should be examined. In this study, we have used *in situ* hybridization to examine mRNA expression of p53 in human esophageal cancers, in which a high frequency of p53 abnormalities were previously reported.<sup>10,18-21</sup> An analysis of p53 mRNA expression can indicate whether p53 mRNA and protein levels may correspond in the specimens in which overexpression of p53 was immunohistochemically observed.<sup>9</sup> Human carcinoma specimens are composed of both viable and nonviable carcinoma in addition to stromal cells. Therefore, when analyzing any

human materials, it is indispensable to correlate mRNA expression with morphologic features of the specimens studied. *In situ* hybridization may not provide quantitative information on mRNA expression but can demonstrate localization of mRNA expression. Human cancers commonly display mutations in the p53 gene and mutations are scattered over 100 different base pairs.<sup>22</sup> In human esophageal carcinoma, high frequency of point mutations in the p53 gene that result in amino-acid substitutions or chain termination was reported in the regions of exons 5-8.<sup>18,20</sup> We have employed an antisense single-



**Figure 2.** Left: Immunohistochemistry of p53 in the esophageal mucosa demonstrating squamous cell dysplasia (case #20). Dysplastic cells were immunohistochemically positive for p53,  $\times 300$ . Right: In situ hybridization of p53 in the esophageal mucosa showing squamous cell dysplasia (case #20). Anti-sense probe was used. Accumulation of hybridization signals was observed in dysplastic cells,  $\times 300$ . Bottom: In situ hybridization of p53 in the esophageal mucosa showing squamous cell dysplasia (case #20). Sense probe was used. No specific hybridization signals were observed,  $\times 300$ .

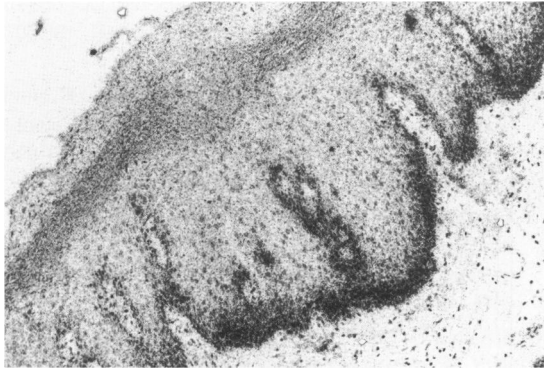


Figure 3. *In situ* hybridization of p53 in histologically normal esophageal mucosa. Accumulation of hybridization signals was observed in basal and parabasal cells. Anti-sense oligonucleotide probe was used,  $\times 300$ .

stranded synthetic oligonucleotide which hybridized with DNA sequence near the 5' end, in which none of the DNA mutations has been reported in human esophageal cancers. This probe can theoretically detect mRNA expression of both wild type and a great majority of mutant type p53, if transcriptionally active, because the oligonucleotide recognizes the DNA sequence near the 5' end in which mRNA transcription is considered to start. However, we did not perform DNA sequencing and therefore did not directly confirm the absence of the DNA mutations in the 5' region containing the ON102 hybridization site. In addition, mutations in the p53 gene were reported to be present outside exons 5–8 in human cancer.<sup>14</sup> Therefore, we cannot completely rule out the possibility that *in situ* hybridization study employing ON102 may not detect expression of some mutant p53 mRNAs. The application of synthetic oligonucleotides labeled with <sup>35</sup>S-nucleotides yields the following significant advantages compared with conventional approaches of *in situ* hybridization using cDNA or cRNA probes.<sup>23</sup> 1) A higher specific activity probe is obtained than when tritium-labeled probes are used, and 2) oligonucleotides permit greater specificity than cDNA or cRNA probes, in that redundant or conserved nucleotide sequences can be avoided during probe design and synthesis. Thus, despite the potential problems described earlier, the *in situ* hybridization approach we have undertaken in this study can successfully localize p53 mRNA expression in human esophageal carcinoma.

In all cases of invasive carcinoma examined, overexpression of mRNA was not observed in both immunohistochemically positive and negative cases. This result is consistent with the recent report of Davidoff et al who demonstrated low levels of p53 mRNA expression in primary invasive human breast cancers by Northern blotting.<sup>3</sup> The result in our study at least indicates that widespread overexpression of p53 in human esophageal

cancer observed by immunohistochemical staining is not due to an increase in the steady-state level of p53 mRNA of carcinoma cells. An interesting finding in this study is overexpression of p53 in foci of squamous dysplasia. Overexpression of p53 mRNA in the cells that exhibited squamous dysplasia and were positive for p53 immunoreactivity suggests that some quantitative differences of p53 mRNA expression exist between squamous carcinoma cells associated with both cell atypia and invasion and squamous dysplastic cells with cell atypia but not invasion. Recently, Ledinko and Costantino demonstrated that retinoid-mediated induction of suppression of cell invasion was accompanied by an increase in amounts of p53 mRNA.<sup>24</sup> In addition, they reported that expression of p53 was related to the degree of invasion-suppression in the A549 human lung carcinoma cell line.<sup>24</sup> Therefore, overexpression of p53 mRNA in the dysplastic cells, which are positive for p53 immunoreactivity, may be related to the absence of histologically observed invasion but it requires further investigations to clarify the biological significance of p53 mRNA overexpression in dysplastic cells in human esophageal mucosa.

## References

1. Rogel A, Popliker M, Webb CG, Oren M: p53 cellular tumor antigen; analysis of mRNA levels in normal adult tissues, embryos and tumors. *Mol Cell Biol* 1985, 5:2851–2855
2. Mercer WE, Avignolo C, Baserga R: Role of the p53 protein in cell proliferation as studied by microinjection of monoclonal antibodies. *Mol Cell Biol* 1984, 4:276–282
3. Davidoff AM, Humphrey PA, Iglehart JD, Marks JR: Genetic basis for p53 overexpression in human breast cancer. *Proc Natl Acad Sci USA* 1991, 88:5006–5010
4. Reich NC, Levine AJ: Growth regulation of a cellular tumor antigen, p53, in nontransformed cells. *Nature* 1984, 308:199–201
5. Finlay CA, Hinds PW, Tan T-H: Activating mutations for transformation by p53 produce a gene product that forms a hsc70-p53 complex with an altered half-life. *Mol Cell Biol* 1988, 8:531–539
6. Parada LF, Land H, Weinberg RA, Wolf D, Rotter V: Cooperation between gene encoding p53 tumor antigen and ras in cellular transformation. *Nature* 1984, 312:649–651
7. Nigro JM, Baker SJ, Preisinger AC, Jessup JM, Hostetter R, Cleary K, Bigner SH, Davidson N, Baylin S, Davilee P, Glover T, Collins FS, Weston A, Modali R, Harris CC, Vogelstein B: Mutations in the p53 gene occur in diverse human tumor types. *Nature* 1989, 342:705–708
8. Takahashi T, Nau MM, Chiba I, Birier MJ, Rosenberg RK, Vinocour M, Levitt M, Pass H, Gazdar AF, Minna JD: p53: a frequent target for generic abnormalities in lung cancer. *Science* 1989, 246:491–494
9. Thompson AM, Steel CM, Chetty U, Hawkins RA, Miller WR, Carter DC, Forrest APM, Evans HJ: p53 gene mRNA ex-

- pression and chromosome 17p allele loss in breast cancer. *Br J Cancer* 1990, 61:74-78
10. Sasano H, Miyazaki S, Gookon Y, Nishihira T, Sawai T, Nagura H: Expression of p53 in human esophageal carcinoma—An immunohistochemical study with correlation to PCNA expression—*Hum Pathol* 1992, in press
  11. Banks L, Matiaszewski C, Crawford L: Isolation of human p53-specific monoclonal antibodies and their use in human p53 expression. *Eur J Biochem* 1986, 155:529-534
  12. Sasano H, Miyazaki S, Sawai T, Sasano N, Nagura H, Funahashi H, Aiba M, Demura H: Primary pigmented adrenocortical disease (PPNAD): immunohistochemical and *in situ* hybridization analysis of steroidogenic enzymes in eight cases. *Mod Pathol* 1992, 5:23-39
  13. Hayashi M, Ninomiya Y, Parsons J, Hayashi K, Olson BR, Trelstad RL: Differential localization of mRNAs of collagen Types I and II in chick fibroblasts, chondrocytes, and corneal cells by *in situ* hybridization using cDNA probes. *J Cell Biol* 1986, 100:2302-2309
  14. D'Amico D, Carbone D, Mitsudomi T, Nau M, Fedorko J, Russel E, Johnson B, Buchhagen D, Bodner S, Phelps R, Gazdar A, Minna JD: High frequency of somatically acquired p53 mutations in small cell lung cancer cell lines and tumors. *Oncogene* 1992, 7:339-346
  15. Marks JR, Davidoff AM, Kerns BJ, Humphrey PA, Pence JC, Dodge RK, Clarke-Pearson DL, Iglehart JD, Bast Jr, RC, Berchuck A: Overexpression and mutation of p53 in epithelial ovarian cancer. *Cancer Res* 1991, 51:2979-2984
  16. Iggo R, Gatter K, Bartek KJ, Lanae D, Harris AL: Increased expression of mutant forms of p53 oncogene in primary lung cancer. *Lancet* 1990, 335:675-679
  17. Purdie CA, O'Grady J, Piris J, Wyllie AH, Bird CC: p53 expression in colorectal tumors. *Am J Pathol* 1991, 138:807-813
  18. Hollstein MC, Metcalf RA, Welsh JA, Montesano R, Harris CC: Frequent mutation of the p53 gene in human esophageal cancer. *Proc Natl Acad Sci USA* 1990, 87:9958-9961
  19. Meltzer SJ, Yin J, Huang Y, McDaniel TK, Newkirk C, Iseri O, Vogelstein B, Resau JH: Reduction of homozygosity involving p53 in esophageal cancers demonstrated by the polymerase chain reaction. *Proc Natl Acad Sci USA* 1991, 88:4976-4980
  20. Casson AG, Mukhopadhyay T, Cleary KR, Ro JY, Levin B, Roth JA: p53 gene mutations in Barrett's epithelium and esophageal cancer. *Cancer Res* 1991, 51:4495-4499
  21. Blount PL, Ramel S, Raskind WH, Haggitt RC, Sanchez CA, Dean PJ, Rabinovitch PS, Reid BJ: 17p allelic deletions and p53 protein overexpression in Barrett's adenocarcinoma. *Cancer Res* 1991, 51:5482-5486
  22. Puisieux A, Lim S, Groopman J, Ozturk M: Selective targeting of p53 gene mutational hotspots in human cancers by etiologically defined carcinogens. *Cancer Res* 1991, 51:6185-6189
  23. Couwenhoven RI, Luo W, Snead MI: Colocalization of EGF transcripts and peptides by combined immunohistochemistry and *in situ* hybridization. *J Histochem Cytochem* 1990, 38:1853-1857
  24. Ledinko N, Costantino RL: Modulation of p53 gene expression and cytokeratin 18 in retinoid-mediated invasion suppressed lung carcinoma cells. *Anticancer Res* 1990, 10:1335-1340